



OPEN ACCESS

Case report

Iatrogenic Cushing syndrome and multifocal osteonecrosis caused by the interaction between inhaled fluticasone and ritonavir

Joana Figueiredo,¹ Margarida Serrado,² Nikita Khmelinskii,^{3,4} Sónia do Vale ^{1,5}

¹Serviço de Endocrinologia, Universidade de Lisboa Faculdade de Medicina, Lisboa, Portugal

²Hospital de Santa Maria, Serviço de Doenças Infecciosas, Centro Hospitalar Lisboa Norte EPE, Lisboa, Portugal

³Hospital de Santa Maria, Serviço de Reumatologia e Doenças Ósseas Metabólicas, Centro Hospitalar Lisboa Norte EPE, Lisboa, Portugal

⁴Unidade de Investigação em Reumatologia, Instituto de Medicina Molecular, Lisboa, Portugal

⁵Hospital de Santa Maria, Serviço de Endocrinologia, Centro Hospitalar Lisboa Norte EPE, Lisboa, Portugal

Correspondence to

Professor Sónia do Vale;
sonia.vale@chln.min-saude.pt

Accepted 23 April 2020

SUMMARY

Inhaled corticosteroids are generally considered safe and do not usually lead to systemic adverse events since their plasma concentrations are low due to hepatic metabolism by the cytochrome P450 3A4. However, when associated with inhibitors of this cytochrome, such as ritonavir, they may lead to iatrogenic Cushing syndrome by the systemic accumulation of corticosteroids and consequent suppression of the hypothalamic-pituitary-adrenal axis. We present a case of iatrogenic Cushing syndrome complicated by multifocal osteonecrosis in a patient with HIV infection on antiretroviral therapy with protease inhibitors boosted with ritonavir, after the association of inhaled fluticasone. This clinical case highlights a relevant interaction between corticosteroids and inhibitors of the cytochrome P450 and the severe consequences that may occur.

BACKGROUND

Ritonavir is a protease inhibitor that is often used in combination with other antiretrovirals in the treatment of HIV infection. It is a potent inhibitor of the hepatic cytochrome P450 3A4 (CYP3A4) acting as a booster and allowing other antiretroviral agents metabolised by this cytochrome to reach higher plasma concentrations. This enables a decrease in pill burden and an increase of the dosing intervals, improving patient adherence and decreasing treatment failure.¹

Inhaled corticosteroids are drugs widely used in the treatment of asthma, allergic rhinitis and chronic obstructive pulmonary disease (COPD). They are considered safe due to the low plasma concentrations they reach after metabolism by the CYP3A4. When combined with potent inhibitors of this cytochrome, there may be a significant increase in plasma corticosteroid levels.¹ This may cause iatrogenic Cushing syndrome, suppression of the hypothalamic-pituitary-adrenal (HPA) axis, acute adrenal insufficiency in case of abrupt corticosteroid withdrawal, as well as hypertension, osteoporosis and avascular necrosis.¹⁻⁵

We report a case of iatrogenic Cushing syndrome and multifocal osteonecrosis in a patient with HIV1 infection on a ritonavir-boosted antiretroviral therapy (ART) and COPD treated with fluticasone. It is intended to emphasise the importance of the interaction between inhaled corticosteroids

and cytochrome P450 (CYP450) inhibitors and its potential severe consequences.

CASE PRESENTATION

A 40-year-old man with well-controlled HIV1 infection (CD4+ T cell count of 518 cells/mm³ and undetectable HIV1 RNA) presented to the Endocrinology Department due to weight gain and abdominal and limb striae. His medical background included COPD and alcohol, tobacco and past intravenous heroin abuse. HIV1 infection was diagnosed when he was 25 years old and treatment with lopinavir/ritonavir 400 mg/100 mg two times per day, saquinavir 1000 mg two times per day and tenofovir 300 mg one time a day was started at the age of 33 years (CD4+ T cell count of 78 cells/mm³ and HIV1 RNA viral load of 2300 copies, log₁₀ 3.38, before ART). At 35 years of age inhaled therapy with fluticasone/salmeterol 250 µg/50 µg two times per day and tiotropium bromide 18 µg one time a day was added for COPD. One year later, he developed avascular necrosis of the right femoral head and underwent total hip arthroplasty.

The patient was first observed in January 2013, 5 years after the initiation of inhaled corticosteroid therapy. He reported a gradual increase in abdominal and cervical volume, 15 kg weight gain over the

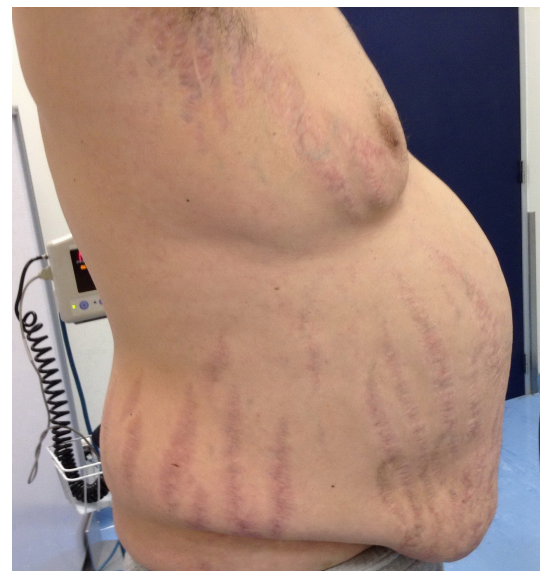
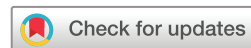

Figure 1 Centripetal obesity and wide and divergent purpuric striae.



© BMJ Publishing Group Limited 2020. Re-use permitted under CC BY-NC. No commercial re-use. See rights and permissions. Published by BMJ.

To cite: Figueiredo J, Serrado M, Khmelinskii N, et al. *BMJ Case Rep* 2020;**13**:e233712. doi:10.1136/bcr-2019-233712

Table 1 Laboratory findings evolution

	Normal range	With corticosteroids		Without corticosteroids (since Jul 2013)					
		January 2013, 40 years old*	May 2013	September 2013	February 2014, 41 years old	September 2014	March 2015, 42 years old	December 2015	April 2017, 44 years old
ACTH (pg/mL)	0–46	<5	<5	10.5	21.4	16	17.9	26.4	
Serum cortisol (µg/dL)	4.3–23	0.4	0.4	2.6	12.2	9.1	10.4	20.5	
Urinary cortisol (µg/24 hours)	55.5–286	10	9	13	84		194		
FSH (U/L)	1.4–18.1		36.6	26.3	25.0		27.2		30.0
LH (U/L)	1.5–9.3		12.7	12.7	13.7		15.9		13.0
Total testosterone (ng/dL)	240–830			465	309		290		337
Free testosterone (pg/mL)	6.6–23		2.0	5.4	5.1		5.6		9.3
SHBG (nmol/L)	10–57			64.2	67.6		54.9		69.0

*At this time the diagnosis of exogenous Cushing syndrome was made, and the patient started reducing the dose of corticosteroids. ACTH, adrenocorticotropic hormone; FSH, follicle-stimulating hormone; LH, luteinising hormone; SHBG, sexhormone-binding globulin.

previous 6 months, appearance of abdominal and limb striae, gynecomastia, ankle oedema, erectile dysfunction and humoral lability. On physical examination he was noted to have a plethoric 'full moon' facies, centripetal obesity (body mass index (BMI) of 35 kg/m²), dorsocervical fat pads, proximal muscular atrophy, wide and divergent purpuric striae in the abdomen, arms and thighs (figure 1) and high blood pressure.

INVESTIGATIONS

Laboratory evaluation revealed low serum and urinary cortisol with low serum adrenocorticotropic hormone (ACTH) concentrations, indicating suppression of the HPA axis. Furthermore, dyslipidaemia and hypergonadotropic hypogonadism were detected (table 1). A bone density scan (BDS) revealed low bone mineral density (Z-score of the lumbar spine of –3.6), compatible with osteoporosis.

DIFFERENTIAL DIAGNOSIS

Presented with these findings, a diagnosis of exogenous/iatrogenic Cushing syndrome secondary to inhaled fluticasone was made.

Regarding the differential diagnosis of Cushing syndrome in patients undergoing ART, it is important to consider ART-related lipodystrophy. In lipodystrophy, there is a metabolic dysregulation that leads to weight gain, central fat distribution and dorsocervical fat pads. In the case at hand, the presence of rapid weight gain, purpuric abdominal striae and facial plethora all point to the Cushing syndrome. In contrast, HIV-associated lipodystrophy is associated with more evident peripheral muscular atrophy than Cushing syndrome.^{1–3} Laboratory evaluation clarifies the diagnosis since there are abnormal concentrations of cortisol and ACTH in the Cushing syndrome.

We must also distinguish between iatrogenic and endogenous Cushing syndrome. When Cushing syndrome is iatrogenic, the endogenous synthesis of cortisol is suppressed due to the negative feedback exerted by the excess of exogenous corticosteroids on the hypothalamus and the pituitary gland. Suppressed ACTH and cortisol concentrations mean that the source of corticosteroids is exogenous, representing therefore an iatrogenic Cushing syndrome. However, if the patient is taking hydrocortisone, the cortisol measurements do not distinguish whether the source of

cortisol is endogenous or administered. Other corticosteroids may also interfere with these measurements.

TREATMENT

After the diagnosis, the dose of fluticasone was progressively reduced. The patient also started antihypertensive and statin therapy.

OUTCOME AND FOLLOW-UP

After 4 months of corticosteroids at a halved dose, the patient continued to demonstrate HPA axis suppression and the decision was made to continue weaning fluticasone. Eventually the fluticasone/salmeterol was totally ceased and replaced by indacaterol 150 µg one time a day in July 2013.

In September 2013, after 3 months without corticosteroids, the patient had a less 'full moon' facies, no oedema, less purpuric striae and a 6 kg weight loss over a 9 month period (BMI of 33 kg/m²). He reported an improvement of erectile dysfunction. From the respiratory point of view, the patient remained stable without the need of steroid therapy. Serum and urinary cortisol were closer to reference values and ACTH was not suppressed (table 1).

Approximately 1 year after corticosteroid cessation, the patient complained of left knee pain and claudication. Plain radiography of the knees revealed bilateral sclerotic lesions in a serpiginous pattern and the diagnosis of aseptic necrosis with subchondral bone collapse of the medial left femoral condyle was confirmed by magnetic resonance imaging (figure 2). Conservative treatment that included protected weightbearing with crutches, non-steroidal anti-inflammatory drugs and alendronate 70 mg weekly for 2 years ensured full symptomatic relief and no radiographic progression on long-term follow-up.

There was a gradual improvement of the Cushing syndrome signs as well as laboratory abnormalities, with normalisation of the HPA axis function. Reassessment BDS revealed improvement of the bone mineral density. Laboratory tests performed at the same time revealed total testosterone and free testosterone levels within normal range, while maintaining high follicle-stimulating hormone and luteinising hormone (table 1).

DISCUSSION

The presented clinical case describes an iatrogenic Cushing syndrome complicated by multifocal osteonecrosis resulting

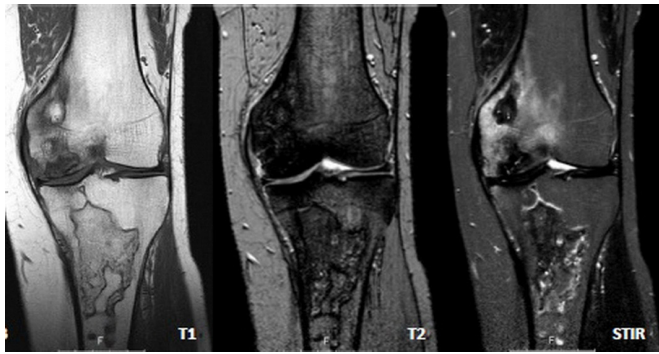


Figure 2 Resonance imaging of the left knee demonstrating aseptic necrosis with subchondral bone collapse of the medial left femoral condyle.

from a drug interaction between ritonavir and fluticasone. There are already a number of published articles describing the consequences of the interaction between these two drugs.³ In 2013, a Review article found 51 published case reports regarding adverse effects with the use of inhaled or/and intranasal corticosteroids and protease inhibitors, most of which (approximately 86%) were related to the association between fluticasone and ritonavir.³ The most common reported symptoms were ‘full moon’ facies, facial hirsutism, central obesity and weight gain, dorsocervical fat pads, striae and easy bruising.³ There were five cases of osteoporosis and one case of osteonecrosis of both hips.^{3,5} However, despite the presence of these well-documented cases of iatrogenic Cushing syndrome, similar reports continue to emerge.^{2,6,7}

Ritonavir, being a potent inhibitor of the hepatic CYP3A4, increases the concentration of other protease inhibitors included in the combined ART and enhances HIV treatment success. However, ritonavir can also increase corticosteroids concentrations, as they are substrates of the CYP3A4. Therefore, this interaction can result in impaired metabolism and systemic corticosteroid accumulation, adrenal suppression and Cushing syndrome.^{1,2}

Compared with other inhaled corticosteroids, fluticasone exhibits the most suppressive impact on the HPA axis. This is due to its pharmacokinetic properties, such as higher glucocorticoid receptor binding affinity, longer half-life and higher lipophilicity, allowing a greater volume of distribution. These characteristics facilitate the systemic accumulation of fluticasone and make it more susceptible to drug interactions.^{1–3}

The most common clinical feature of the Cushing syndrome is weight gain with central fat distribution. Other typical manifestations include, ‘full moon’ facies, facial plethora, dorsocervical fat pads (‘buffalo hump’), skin atrophy, acne, easy bruising and purple striae. Hirsutism (in women), proximal myopathy, insulin resistance, dyslipidaemia, hypertension, immunosuppression, psychiatric disorders and osteopenia or osteoporosis are also common.^{2,8,9} Given the reported clinical case, it is also important to note that hypogonadism, HIV infection, ART and tobacco and alcohol abuse may also contribute to a decrease in bone mineral density.^{10,11}

There are other important consequences of hypercortisolism, namely gonadal dysfunction and aseptic osteonecrosis. Gonadal dysfunction occurs in more than 75% of patients with Cushing syndrome and is usually hypogonadotropic.^{9,11} However, the patient presented with hypergonadotropic hypogonadism and several contributing factors transpire: chronic alcoholism, the use of certain illicit drugs and HIV infection.^{11,12}

As mentioned, the patient developed avascular necrosis of the right femoral head and, approximately 5 years after, of both knees. Although infrequent, avascular necrosis may have been the first manifestation of the Cushing syndrome.¹³ Multiple other risk factors for avascular necrosis were also present: alcoholism, hypertriglyceridemia, HIV infection and smoking.^{4,5,13} Therefore, we cannot conclude that hypercortisolism was an isolated cause of multifocal osteonecrosis, but it probably was a significant contributing factor. To our knowledge, only two other cases of avascular necrosis have been reported as being attributed to the interaction between fluticasone and ritonavir.^{4,5}

After the diagnosis of iatrogenic Cushing syndrome due to the interaction between inhaled corticosteroids and ritonavir, treatment involves either replacing ritonavir with another antiretroviral that does not inhibit the CYP3A4 or changing fluticasone while maintaining ritonavir. Fluticasone can be substituted for another less potent inhaled corticosteroid and less dependent on CYP450 metabolism (eg, beclomethasone), a leukotriene antagonist (eg, montelukast) or an anticholinergic agent (eg, tiotropium). It is unclear if significant dose reductions of the intranasal/inhaled corticosteroid will result in the complete resolution of the clinical picture since accounts of this interaction have been reported at low doses.^{2,3}

If treatment with another inhaled corticosteroid is started, the lowest possible dose should always be administered and the clinical course should be closely monitored considering case reports of iatrogenic Cushing syndrome due to other inhaled corticosteroids.^{1,3}

If corticosteroid therapy is to be suspended, this should always be done progressively because of the risk of acute adrenal insufficiency. The exogenous corticosteroids suppress the HPA axis. With an abrupt cessation of exogenous corticosteroids, the HPA axis is incapable of rapidly producing endogenous cortisol, which results in acute adrenal insufficiency.⁶

In conclusion, corticosteroid therapy even in ‘non-systemic’ formulations, namely intranasal or inhaled, should be avoided in patients receiving ritonavir (or another CYP3A4 inhibitor). If treatment with an inhaled corticosteroid is imperative, fluticasone should not be the first therapeutic option.

Learning points

- ▶ Ritonavir is a potent cytochrome P450 3A4 inhibitor acting as a booster of other drugs metabolised via this cytochrome, such as corticosteroids.
- ▶ Co-administration of ritonavir (or other potent cytochrome P450 (CYP450) inhibitors) with corticosteroids, including intranasal or inhaled formulations, may induce systemic corticosteroid accumulation, Cushing syndrome, adrenal insufficiency, hypertension, osteoporosis and avascular necrosis.
- ▶ Compared with other inhaled corticosteroids, fluticasone is the most susceptible to drug interactions with CYP450 inhibitors while beclomethasone is probably the safest option.
- ▶ Treatment options for the iatrogenic Cushing syndrome induced by this interaction include replacing ritonavir with another antiretroviral or slow tapering of fluticasone and replacing it with beclomethasone, a leukotriene antagonist or an anticholinergic agent.

Contributors MS, NK and SdV were involved in the treatment of the presented patient. JF wrote the manuscript with the help from SdV, NK and MS. All authors contributed to the final version of the manuscript.

Funding The authors have not declared a specific grant for this research from any funding agency in the public, commercial or not-for-profit sectors.

Competing interests None declared.

Patient consent for publication Obtained.

Provenance and peer review Not commissioned; externally peer reviewed.

Open access This is an open access article distributed in accordance with the Creative Commons Attribution Non Commercial (CC BY-NC 4.0) license, which permits others to distribute, remix, adapt, build upon this work non-commercially, and license their derivative works on different terms, provided the original work is properly cited and the use is non-commercial. See: <http://creativecommons.org/licenses/by-nc/4.0/>.

ORCID iD

Sónia do Vale <http://orcid.org/0000-0001-9287-4095>

REFERENCES

- 1 Mahlab-Guri K, Asher I, Gradstein S, et al. Inhaled fluticasone causes iatrogenic Cushing's syndrome in patients treated with ritonavir. *J Asthma* 2011;48:860–3.
- 2 Epperla N, McKiernan F. Iatrogenic Cushing syndrome and adrenal insufficiency during concomitant therapy with ritonavir and fluticasone. *Springerplus* 2015;4:455.
- 3 Saberi P, Phengrasamy T, Nguyen DP. Inhaled corticosteroid use in HIV-positive individuals taking protease inhibitors: a review of pharmacokinetics, case reports and clinical management. *HIV Med* 2013;14:519–29.
- 4 Pollett S, Graves B, Richards B, et al. Avascular necrosis in a HIV patient receiving ritonavir and inhaled fluticasone. *Int J STD AIDS* 2014;25:458–60.
- 5 Kaviani N, Bukberg P, Manassis A, et al. Iatrogenic osteoporosis, bilateral hip osteonecrosis, and secondary adrenal suppression in an HIV-infected man receiving inhaled corticosteroids and ritonavir-boosted highly active antiretroviral therapy. *Endocr Pract* 2011;17:74–8.
- 6 Wood BR, Lacy JM, Johnston C, et al. Adrenal insufficiency as a result of ritonavir and exogenous steroid exposure: report of 6 cases and recommendation for management. *J Int Assoc Provid AIDS Care* 2015;14:300–5.
- 7 Azevedo L, Pêgo H, Souto Moura T, et al. Iatrogenic Cushing's syndrome and osteoporosis due to an interaction between fluticasone and ritonavir. *BMJ Case Rep* 2015;2015:bcr2015211080.
- 8 Ntali G, Grossman A, Karavitaki N. Clinical and biochemical manifestations of Cushing's. *Pituitary* 2015;18:181–7.
- 9 Alves M, Neves C, Medina JL. Diagnóstico Laboratorial de Síndrome de Cushing. *Acta Médica Portuguesa* 2008;23:063–76.
- 10 Ashby J, Goldmeier D, Sadeghi-Nejad H. Hypogonadism in human immunodeficiency virus-positive men. *Korean J Urol* 2014;55:9–16.
- 11 Darby E, Anawalt BD. Male hypogonadism : an update on diagnosis and treatment. *Treat Endocrinol* 2005;4:293–309.
- 12 Ponte CMM, Gurgel MHC, Montenegro RM. Disfunção do eixo gonadotrófico em homens com infecção pelo HIV/AIDS. *Arq Bras Endocrinol Metab* 2009;53:983–8.
- 13 Koch CA, Tsigos C, Patronas NJ, et al. Cushing's disease presenting with avascular necrosis of the hip: an orthopedic emergency. *J Clin Endocrinol Metab* 1999;84:3010–2.

Copyright 2020 BMJ Publishing Group. All rights reserved. For permission to reuse any of this content visit <https://www.bmj.com/company/products-services/rights-and-licensing/permissions/>
BMJ Case Report Fellows may re-use this article for personal use and teaching without any further permission.

Become a Fellow of BMJ Case Reports today and you can:

- ▶ Submit as many cases as you like
- ▶ Enjoy fast sympathetic peer review and rapid publication of accepted articles
- ▶ Access all the published articles
- ▶ Re-use any of the published material for personal use and teaching without further permission

Customer Service

If you have any further queries about your subscription, please contact our customer services team on +44 (0) 207111 1105 or via email at support@bmj.com.

Visit casereports.bmj.com for more articles like this and to become a Fellow