



University of  
Zurich<sup>UZH</sup>

Zurich Open Repository and  
Archive

University of Zurich  
Main Library  
Strickhofstrasse 39  
CH-8057 Zurich  
[www.zora.uzh.ch](http://www.zora.uzh.ch)

---

Year: 2021

---

## Thyroid cartilage asymmetry as a potential diagnostic finding for occult cartilaginous fractures for the evaluation of nonfatal manual strangulation

Heimer, Jakob ; Chatzaraki, Vasiliki ; Pameijer, Frank A ; Schweitzer, Wolf ; Thali, Michael J ; Ampanozi, Garyfalia

**Abstract:** Objective: This study is based on the hypothesis that occult cartilaginous fractures of the thyroid cartilage (TC) may result in asymmetry of the thyroid cartilage framework. Justification of this hypothesis was provided by an estimation of the prevalence of TC asymmetry based on a consecutive postmortem study group. The findings were then compared to three cases of nonfatal manual strangulation and one case of survival of blunt trauma to the neck. Methodology: TC images from a consecutive two-year sample from the institutional postmortem computed tomography database (N= 1187) were assessed. Cases with acute TC injury were excluded. TC asymmetry, signs of prior TC trauma, sex and age, were retrieved. Results: TC asymmetry was present in 72 cases (6.2%, 67 males). In 40 cases (3.5%), old TC fractures could be identified. The derived odds ratios were 7.48 for male sex and 1.02 for (each year of) age ( $p < 0.001$ ). Asymmetry of the TC laminae was observed significantly more often on the left side (N= 53, 73.6%,  $p < 0.001$ ). Cases 1 and 2 showed TC asymmetries following nonfatal manual strangulation. Cases 3 and 4 illustrated the limited visibility of cartilaginous fractures on computed tomography. Conclusion: TC asymmetry is associated with male sex and older age and is typically located on the left side. TC asymmetry in young and female cases is rare. TC asymmetry in young and/or female cases may result from occult cartilaginous fractures, as cases 1 and 2 indicated. Further research is needed to validate this hypothesis.

DOI: <https://doi.org/10.1016/j.fri.2021.200445>

Posted at the Zurich Open Repository and Archive, University of Zurich

ZORA URL: <https://doi.org/10.5167/uzh-201900>

Journal Article

Accepted Version



The following work is licensed under a Creative Commons: Attribution 4.0 International (CC BY 4.0) License.

Originally published at:

Heimer, Jakob; Chatzaraki, Vasiliki; Pameijer, Frank A; Schweitzer, Wolf; Thali, Michael J; Ampanozi, Garyfalia (2021). Thyroid cartilage asymmetry as a potential diagnostic finding for occult cartilaginous fractures for the evaluation of nonfatal manual strangulation. *Forensic Imaging*, 25:200445.

DOI: <https://doi.org/10.1016/j.fri.2021.200445>

## Journal Pre-proof

Thyroid cartilage asymmetry as a potential diagnostic finding for occult cartilaginous fractures for the evaluation of nonfatal manual strangulation

Jakob Heimer MD , Vasiliki Chatzaraki , Frank A. Pameijer ,  
Wolf Schweitzer , Michael J. Thali , Garyfalia Ampanozi

PII: S2666-2256(21)00016-6  
DOI: <https://doi.org/10.1016/j.fri.2021.200445>  
Reference: FRI 200445



To appear in: *Forensic Imaging*

Received date: 21 December 2020  
Revised date: 4 March 2021  
Accepted date: 12 March 2021

Please cite this article as: Jakob Heimer MD , Vasiliki Chatzaraki , Frank A. Pameijer , Wolf Schweitzer , Michael J. Thali , Garyfalia Ampanozi , Thyroid cartilage asymmetry as a potential diagnostic finding for occult cartilaginous fractures for the evaluation of nonfatal manual strangulation, *Forensic Imaging* (2021), doi: <https://doi.org/10.1016/j.fri.2021.200445>

This is a PDF file of an article that has undergone enhancements after acceptance, such as the addition of a cover page and metadata, and formatting for readability, but it is not yet the definitive version of record. This version will undergo additional copyediting, typesetting and review before it is published in its final form, but we are providing this version to give early visibility of the article. Please note that, during the production process, errors may be discovered which could affect the content, and all legal disclaimers that apply to the journal pertain.

© 2021 Published by Elsevier Ltd.

**Highlights:**

- Asymmetry of the thyroid cartilage is a morphologic variant of unknown etiology associated with male sex and older age.
- Asymmetry of the TC laminae was observed significantly more often on the left side.
- Trauma to the thyroid cartilage may result in fractures, but (micro-)fractures of the cartilaginous parts are difficult to detect on computed tomography.
- Trauma to cartilaginous parts of the thyroid cartilage may result in asymmetry.
- In two cases of nonfatal manual strangulation, TC asymmetry likely resulted from the assault.

**Thyroid cartilage asymmetry as a potential diagnostic finding for occult cartilaginous fractures for the evaluation of nonfatal manual strangulation**

Jakob Heimer<sup>1</sup>, Vasiliki Chatzaraki<sup>1</sup>, Frank A. Pameijer<sup>2</sup>, Wolf Schweitzer<sup>1</sup>, Michael J. Thali<sup>1</sup>,  
Garyfalia Ampanozi<sup>1</sup>

<sup>1</sup>Institute of Forensic Medicine, Department of Forensic Medicine and Imaging, University of Zurich, Winterthurerstrasse 190/52, CH-8057 Zurich, Switzerland

<sup>2</sup>Department of Radiology, University Medical Center Utrecht, 3508 GA Utrecht, The Netherlands

**Corresponding author**

Jakob Heimer MD / ORCID: 0000-0003-3499-8801

University of Zurich / Winterthurerstrasse 190/52 / CH-8057 Zurich, Switzerland /

Phone: +41 79 783 64 85, Email: Jakob.Heimer@irm.uzh.ch;

**Word Count**

2430

Journal Pre-proof

**Abstract**

**Objective:** This study is based on the hypothesis that occult cartilaginous fractures of the thyroid cartilage (TC) may result in asymmetry of the thyroid cartilage framework. Justification of this hypothesis was provided by an estimation of the prevalence of TC asymmetry based on a consecutive postmortem study group. The findings were then compared to three cases of nonfatal manual strangulation and one case of survival of blunt trauma to the neck.

**Methodology:** TC images from a consecutive two-year sample from the institutional postmortem computed tomography database (N= 1187) were assessed. Cases with acute TC injury were excluded. TC asymmetry, signs of prior TC trauma, sex and age, were retrieved.

**Results:** TC asymmetry was present in 72 cases (6.2%, 67 males). In 40 cases (3.5%), old TC fractures could be identified. The derived odds ratios were 7.48 for male sex and 1.02 for (each year of) age ( $p < 0.001$ ). Asymmetry of the TC laminae was observed significantly more often on the left side (N= 53, 73.6%,  $p < 0.001$ ). Cases 1 and 2 showed TC asymmetries following nonfatal manual strangulation. Cases 3 and 4 illustrated the limited visibility of cartilaginous fractures on computed tomography.

**Conclusion:** TC asymmetry is associated with male sex and older age and is typically located on the left side. TC asymmetry in young and female cases is rare. TC asymmetry in young and/or female cases may result from occult cartilaginous fractures, as cases 1 and 2 indicated. Further research is needed to validate this hypothesis.

**Keywords** Laryngeal Trauma; Nonfatal Strangulation; Postmortem Computed Tomography;  
Thyroid Cartilage

### **Acknowledgements**

The authors express their gratitude to Emma Louise Kessler, MD for her generous donation to the Zurich Institute of Forensic Medicine, University of Zurich, Switzerland.

**Abstract**

**Objective:** This study is based on the hypothesis that occult cartilaginous fractures of the thyroid cartilage (TC) may result in asymmetry of the thyroid cartilage framework. Justification of this hypothesis was provided by an estimation of the prevalence of TC asymmetry based on a consecutive postmortem study group. The findings were then compared to three cases of nonfatal manual strangulation and one case of survival of blunt trauma to the neck.

**Methodology:** TC images from a consecutive two-year sample from the institutional postmortem computed tomography database (N= 1187) were assessed. Cases with acute TC injury were excluded. TC asymmetry, signs of prior TC trauma, sex and age, were retrieved.

**Results:** TC asymmetry was present in 72 cases (6.2%, 67 males). In 40 cases (3.5%), old TC fractures could be identified. The derived odds ratios were 7.48 for male sex and 1.02 for (each year of) age ( $p < 0.001$ ). Asymmetry of the TC laminae was observed significantly more often on the left side (N= 53, 73.6%,  $p < 0.001$ ). Cases 1 and 2 showed TC asymmetries following nonfatal manual strangulation. Cases 3 and 4 illustrated the limited visibility of cartilaginous fractures on computed tomography.

**Conclusion:** TC asymmetry is associated with male sex and older age and is typically located on the left side. TC asymmetry in young and female cases is rare. TC asymmetry in young and/or female cases may result from occult cartilaginous fractures, as cases 1 and 2 indicated. Further research is needed to validate this hypothesis.



**Keywords** Laryngeal Trauma; Nonfatal Strangulation; Postmortem Computed Tomography;  
Thyroid Cartilage

**Abbreviations**

**TC** Thyroid Cartilage

**NFS** Nonfatal Strangulation

**CT** Computed Tomography

**PMCT** Postmortem Computed Tomography

Journal Pre-proof

## Introduction

The thyroid cartilage (TC), the largest single component of the larynx, is made up of two laminae, which join anteriorly to form the laryngeal prominence and have superior and inferior horns posteriorly. The male larynx and vocal cords grow significantly more than those in females during puberty, creating pronounced sexual dimorphism [1]. The TC is subject to continuous ossification and calcification with increasing age, and this process is more pronounced in males than in females [1]. While incidental trauma to the TC is rare due to its protected location, targeted application of pressure to the neck is common in the forensic setting and is called manual strangulation (or ligature strangulation if a tool is used) [2].

Due to the high variability in both action and outcome and the frequent absence of external findings, the clinical-forensic assessment of nonfatal strangulation (NFS) has been identified as a current problem in forensic medicine [3,4]. Radiologic imaging is a helpful tool for the forensic interpretation of NFS. To exclude life-threatening complications such as carotid dissections [5], computed tomography (CT) with angiography is often applied in severe cases of NFS. The application of magnetic resonance imaging has been investigated with mixed results [6-9]. Overall, the need for sharply defined findings for the evaluation of NFS remains.

In homicidal manual strangulation, fractures of the TC, and in particular of the superior cornua, are common [10,11]. Fractures of the TC laminae in cases of NFS appear to be less common and have been reported for both ossified and cartilaginous parts of the TC [12,13]. In cartilaginous parts of the TC, application of external force can result in microfractures and intracartilaginous hemorrhages [14,15]. A laryngeal microfracture that appeared to be below the resolution of CT was identified by micro-CT in a report by Fais et al. [16]. Occult fractures that are not visible in clinical CT following blunt trauma have been repeatedly

described in pediatric populations with an entirely cartilaginous laryngeal skeleton [17,18]. This study aimed to investigate the assumption that asymmetry of the TC framework can be a consequence of occult cartilaginous fractures.

TC asymmetry, particularly a pronounced inward bending of the left thyroid lamina, has been noted in multiple studies including anatomic essays, autopsy specimens, and clinical studies applying laryngoscopy and CT [19-24]. Potentially due to the scarce literature on TC asymmetry, numerous descriptions of the thyrohyoid complex and its anatomic variations from a forensic perspective do not mention TC asymmetry, and prevalence data are missing [25-29].

This study intended to (1) investigate the prevalence and associations of sex, age, and sidedness of TC asymmetry on postmortem CT (PMCT) within a consecutive sample of deceased individuals, and (2) to present cases in which TC asymmetry was likely the result of NFS based on the prevalence data.

## **Methodology**

All PMCT-scans from September 2016 to September 2018 of cases with an age-at-death of 16 years or older were retrieved from our database, and the sex and age were noted. Whole-body PMCT was performed on a 128-slice scanner (Somatom Definition Flash, Siemens Healthineers, Erlangen, Germany). From the PMCT datasets, each TC scan was inspected on slices parallel to the vocal cords (Fig. 1). Cases with acute TC injury were not included for further analysis. For the remaining cases, old and/or healed fractures (signs of bone healing, pseudarthrosis) as described by Becker et al. were noted [30]. Two residents in forensic pathology, each with two years of experience with PMCT, determined asymmetry of the TC laminae and symmetric inward bending. TC asymmetry was defined as one-sided bending of

a thyroid lamina that was not present on the contralateral side. Divergent findings were discussed, and a consensus was reached. Cohen's kappa was computed to assess interrater agreement of the presence of TC asymmetry.

Three cases of individuals who survived manual strangulation and one case of blunt trauma to the neck were selected from the institutional database. Cases 1 and 2 presented TC asymmetry, which was likely a result of external force, and cases 3 and 4 illustrated the different presentations of TC fractures, which are dependent on the fracture location. In all of these cases, clinical CT angiography was performed to exclude carotid dissections. The case histories were retrieved from the database.

Basic statistical analysis was performed with R [31]. A logistic regression with TC asymmetry as the response and sex, age, and the presence of prior trauma as predictors was modeled to compute odds ratios. The distribution of left- and right-sided asymmetries was tested with  $H_0: p=0.5$  for a left/right-sided asymmetry (binomial test).

## Results

### Study Population

In total, 1187 cases were reviewed. Six cases were excluded due to absence of the larynx because of a laryngectomy (N= 1), complete extracorporeal dislocation of the larynx (N= 3), and insufficient image quality (N= 2). In one unique case of advanced putrefaction, the body was found in a prone position with the right clavicle exerting constant pressure on the thyroid cartilage, which showed a pronounced, right-sided inward bending. Due to this likely postmortem artifact, this case was excluded (N = 1). In 25 cases, an acute injury of the laryngeal framework following hanging (N= 8), gunshot injury (N= 2) or blunt trauma (N=15) was observed. These cases were not included in the study. The remaining 1155 cases were

reviewed for asymmetry and evidence of prior trauma. An overview of the study population and results is presented in Table 1.

### TC Asymmetry

From the 1155 cases, 72 cases (6.2%; 95% CI: 4.9-7.8%) showed distinct asymmetry of the thyroid laminae. Cohen's Kappa was 0.892, translating to a strong agreement [32]. In 100 cases (8.7%; 95% CI: 7.1-10.5%), a bilateral, symmetrical inward bending of the thyroid laminae was observed. Despite bilateral inward bending, these cases were not rated as asymmetric. An overview of left-sided bending is shown in Fig. 2. Fig. 3 shows right-sided bending and examples of asymmetry in female cases. Inward bending of the thyroid laminae was significantly more often observed on the left side (N= 53, 73.6%) than on the right side (N= 19, 26.4%,  $p < 0.001$ , binomial test with  $H_0: p = 0.5$  for left/right-sided asymmetry). The predictors age and male sex were found to be highly significant covariates in the logistic regression model ( $p < 0.001$ ). The derived odds ratios were 7.48 for male sex and 1.02 for (every year of) age.

### Evidence of Prior TC Trauma

Of the 1155 cases, 40 (3.5%; 95% CI: 2.5%-4.7%) showed distinctive signs of prior TC trauma, as either signs of bone healing or pseudarthrosis. The cause of death did not involve trauma to the neck. In 31 of these cases (Fig. 4 a-d), a defect was identified in the lower part of the thyroid cartilage at the level of the vocal cords. In 9 cases (Fig. 4 e), the defect was found in close proximity to the laryngeal prominence. In all cases of previously acquired TC trauma, the defects were identified in ossified or calcified areas. Five of these cases (14.3%) showed TC asymmetry in addition, but evidence of trauma to calcified/ossified parts of the TC was not a significant predictor of asymmetry in the logistic regression model ( $p = 0.12$ ). Cases with signs of prior trauma had the lowest mean age (52.7 years) of all subgroups.

## Case Series

### Case 1

A 26-year-old woman was manually strangled (both-hands, frontal) for an estimated duration of 10 seconds. During the assault, she experienced optical sensations ("seeing stars"). There was no involuntary loss of urine or feces and no reported unconsciousness. At the clinical-forensic examination 8 hours after the assault, she presented with bilateral cervical hematoma and abrasions and reported trouble swallowing and hoarseness. The angio-CT was found to be unremarkable by clinical radiologists. A forensic review of the clinical images revealed a distinct asymmetry of the left TC lamina (Fig. 5 – 1). In addition, the cartilage appeared mildly disjoined.

### Case 2

A 25-year-old man was put in a choke-hold from behind in a physical confrontation with another man. The choke-hold lasted for 10 seconds, during which the victim experienced optical sensations ("blackness"). No involuntary loss of urine or feces or unconsciousness were reported. During the external examination 3 hours after the assault, a singular right-sided cervical hematoma was observed. The victim complained of an onset of hoarseness and recurrent coughing since the assault. The angio-CT showed a left-sided TC asymmetry in conjunction with a cartilaginous hypodensity at the maximum point of the inward bending (Fig. 5 - 2).

### Case 3

A 49-year-old woman was repeatedly strangled (both-hands, frontal) over a period of 5 minutes. During the attack, she experienced an involuntary loss of urine and optical sensations ("blackness"). No unconsciousness was reported. During the forensic clinical examination 2

hours after the attack, bilateral cervical hematoma and abrasions were observed. She described an onset of trouble swallowing and breathing, hoarseness, and a bloody cough following the assault. The clinical CT scan showed a left-sided, vertical fracture of the TC including ossified and cartilaginous parts with a prominent impression and deformation of the right-sided TC lamina (Fig. 5, 3 a/b).

#### Case 4

A 51-year-old man was kicked in the right face, jaw, and neck and fell to the ground unconscious. The clinical CT scan showed a vertical right-sided fracture of the TC as a direct consequence of the kick. The fracture included both ossified and cartilaginous parts with different presentations. In addition, the TC showed a marked left-sided inward bending and a right-sided irregularity at the location of the cartilaginous fracture (Fig. 5, 4 a/b).

#### Discussion

This study introduces the hypothesis of TC asymmetry resulting from occult cartilaginous fractures as a potential diagnostic criterion for the evaluation of NFS. To enable long-term validation of this mechanism, data on the prevalence of TC asymmetry and associations with sex, age and sidedness were collected, and cases of NFS with observed asymmetries were presented.

TC asymmetry is a morphologic variation of currently unknown etiology. While the nomenclature of this finding differs among authors, all prior studies found an overwhelming male and left-sided predominance, as well as a higher mean age associated with TC asymmetry [21-24]. Assumptions of the etiology of TC asymmetry vary greatly among the previous studies; Luschka assumed tight clothing to be its cause [33]. According to Nemai, TC asymmetry is a result of the two laminae not fusing in the midline during growth, forcing

one lamina to recede behind the other [20]. Friedrich et al. discussed whether the left-sided predominance is associated with the predominance of right-handedness in the general population [22]. Last, the possibility of (occult) traumatic etiology has been proposed without clear evidence [34,35].

In this study, distinct signs of prior trauma were detected in 40 cases, which is close to the rate of 3.9% of old fractures identified in the thyroid laminae by Khoklov et al. [36]. The absence of an association between prior TC fractures and TC asymmetry may appear incoherent at first glance, but it illustrates a diagnostic dilemma. All findings related to prior fractures were found in ossified and calcified parts of the TC. If the cartilaginous parts of the TC are more likely to bend instead of fracture, then cases of prior cartilaginous trauma cannot be identified, and the cartilaginous equivalent of prior fractures would be asymmetry. Recently, a case with a monocausal relationship of inward bending of a cartilaginous lamina leading to permanent asymmetry was demonstrated by Lim et al. [37]. From that case alone, it seems likely that permanent asymmetry is a possible outcome of TC trauma, particularly when the TC is not ossified to a degree where a bone fracture results on a macroscopic scale.

It was shown that TC asymmetry exists as an anatomical variation (with possible traumatic origin) associated with male sex, higher age and left-sidedness. These associations allow for conclusions for the forensic interpretation of TC asymmetry. In cases of survived manual strangulation with victims who are young and female, TC asymmetry as an anatomical variation is highly unlikely. In fact, all cases of female asymmetries were older than 70 years in this sample. The population of young women is also the largest group of victims of manual strangulation, which makes this finding relevant for the assessment of NFS.

It remains to show that the proposed mechanism has actually been observed in forensic casework. Cases 1 and 2 serve this purpose. Both cases showed localized hypodensities of the cartilage, which coincided with the presence of TC-asymmetry at the same location. Both



cases likely showed occult fractures of the cartilaginous parts of the TC, which resulted in mild clinical symptoms and distinct asymmetries of the TC. Based on the prevalence data, an anatomical variation is highly unlikely, especially in case 1 (young, female). Cases 3 and 4 serve a different purpose. The radiologic diagnosis in these cases is trivial, as the displaced vertical fractures are identified without difficulty in the lower, ossified parts. Case 3 shows a complete dislocation of the cartilaginous part. It appears valid to assume that the TC laminae would remain asymmetric unless reconstructed surgically (no data on follow up available). Case 3 makes the possibility of permanent TC asymmetry derived from prior trauma likely. In case 4, the cartilaginous fracture presented with irregularity and left-sided inward bending but was almost impossible to detect without the obvious fracture in the ossified parts below.

The hypothesis that manual strangulation may lead to occult cartilaginous fractures, bending, and ultimately, TC-asymmetry appears to be reinforced. For a strong inference, much more case-related data with evidence of recent trauma to the neck in conjunction with observed asymmetries are needed. To our knowledge, this study is the first to introduce the hypothesis of a relationship between cartilaginous fractures and TC asymmetry and provides a potential starting point for further research. The comparison of imaging results obtained before and after an assault is would provide strong evidence, but such data is rare. Should this study's hypothesis hold, the diagnosis of TC asymmetry may become a crucial piece evidence for the interpretation of cases of manual strangulation.

## **Conclusion**

TC asymmetry was observed in 6.2% of cases in a two-year consecutive sample of a forensic PMCT database comprising 1887 cases. TC asymmetry was highly associated with male sex and older age, and asymmetry was significantly more often observed as an inward bending of the left lamina. The presented cases of survived injury show that mild asymmetries may form as a consequence of acute manual strangulation in conjunction with cartilaginous

hypodensity. The possibility of an anatomical variation appears to be low in these cases. The hypothesis of TC asymmetry resulting from occult cartilaginous fractures was proposed. Additional data are needed to verify this hypothesis.

Journal Pre-proof

### **Conflict of Interest**

The authors declare that they have no conflict of interest.

The study did not receive external funding.

### **Compliance with ethical standards**

Ethical approval was obtained by BLINDED.

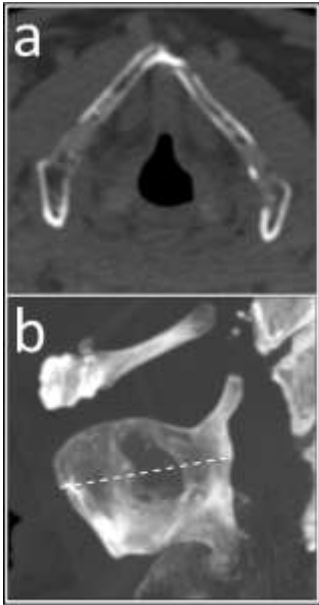
### **References**

1. Pressman JJ, Kelemen G (1955) Physiology of the larynx. *Physiol Rev* 35 (3):506-554
2. Di Maio VJ, Di Maio D (2001) Asphyxia. In: *Forensic Pathology*. Second Edition edn. CRC Press, Boca Raton, London, New York, Washington D.C., pp 230-245
3. De Boos J (2019) Non-fatal strangulation: Hidden injuries, hidden risks. *Emerg Med Australas* 31 (3):302-308
4. Pritchard AJ, Reckdenwald A, Nordham C (2017) Nonfatal strangulation as part of domestic violence: A review of research. *Trauma, Violence, & Abuse* 18 (4):407-424
5. Clarot F, Vaz E, Papin F, Proust B (2005) Fatal and non-fatal bilateral delayed carotid artery dissection after manual strangulation. *Forensic Sci Int* 149 (2):143-150
6. Yen K, Vock P, Christe A, Scheurer E, Plattner T, Schön C, Aghayev E, Jackowski C, Beutler V, Thali MJ (2007) Clinical forensic radiology in strangulation victims: forensic expertise based on magnetic resonance imaging (MRI) findings. *International journal of legal medicine* 121 (2):115-123
7. Christe A, Oesterhelweg L, Ross S, Spendlove D, Bolliger S, Vock P, Thali MJ (2010) Can MRI of the neck compete with clinical findings in assessing danger to life for survivors of manual strangulation? A statistical analysis. *Legal medicine* 12 (5):228-232

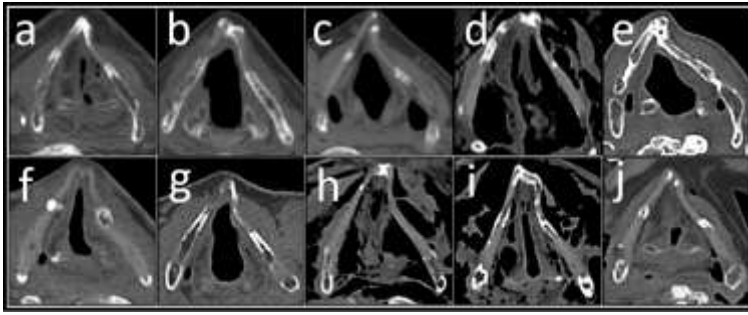
8. Bruguier C, Genet P, Zerlauth J-B, Dédouit F, Grimm J, Meuli R, Fracasso T, Grabherr S (2019) Neck-MRI experience for investigation of survived strangulation victims. *Forensic Sciences Research*:1-6
9. Heimer J, Tappero C, Gascho D, Flach P, Ruder TD, Thali MJ, Franckenberg S (2019) Value of 3T craniocervical magnetic resonance imaging following nonfatal strangulation. *European radiology*:1-9
10. DiMaio VJM (2000) Homicidal Asphyxia. *The American Journal of Forensic Medicine and Pathology* 21 (1):1-4
11. Decker LA, Hatch GM, Lathrop SL, Nolte KB (2018) The role of postmortem computed tomography in the evaluation of strangulation deaths. *Journal of forensic sciences* 63 (5):1401-1405
12. Austin JR, Stanley RB, Cooper DS (1992) Stable internal fixation of fractures of the partially mineralized thyroid cartilage. *Annals of Otolaryngology, Rhinology & Laryngology* 101 (1):76-80
13. Stanley RB, Hanson DG (1983) Manual strangulation injuries of the larynx. *Archives of Otolaryngology* 109 (5):344-347
14. Pollanen MS, McAuliffe DN (1998) Intra-cartilaginous laryngeal haemorrhages and strangulation. *Forensic Sci Int* 93 (1):13-20
15. Pollanen MS (2000) A triad of laryngeal hemorrhages in strangulation: a report of eight cases. *Journal of Forensic Science* 45 (3):614-618
16. Fais P, Giraud C, Viero A, Miotto D, Bortolotti F, Tagliaro F, Montisci M, Cecchetto G (2016) Micro computed tomography features of laryngeal fractures in a case of fatal manual strangulation. *Leg Med* 18:85-89
17. Strychowsky JE, Adil E, Licameli G, Rahbar R (2015) Vocal fold avulsion in the pediatric population: Presentation and management. *Int J Pediatr Otorhinolaryngol* 79 (7):959-964

18. Shires CB, Preston T, Thompson J (2011) Pediatric laryngeal trauma: A case series at a tertiary children's hospital. *Int J Pediatr Otorhinolaryngol* 75 (3):401-408
19. Zuckerkandl (1887) Über Asymmetrie des Kehlkopfgerüsts. *Monatsschr Ohrenheilkd Laryngorhinol* (21):347
20. Nemai J (1931) Minderwertige Stimmorgane. *Monatsschrift Ohrenheilkunde* 65:1451-1459
21. Honjo I, Tanaka S, Tanabe M (1985) Pathogenesis of protruded false vocal fold. *Arch Otolaryngol* 111 (6):398-399
22. Friedrich G, Kainz J, Schneider G (1988) Die Impression der Schildknorpelplatte-Eine Differentialdiagnose zur Taschenfaltenhyperplasie. *Laryngologie, Rhinologie, Otologie und ihre Grenzgebiete* 67 (05):232-239
23. Hirano M, Yukizane K, Kurita S, Hibi S (1989) Asymmetry of the laryngeal framework: a morphologic study of cadaver larynges. *Ann Otol Rhinol Laryngol* 98 (2):135-140
24. Chang BA, Luu K, Newton EK, Morrison MD (2018) Buckled Thyroid Cartilage: An Anatomic Variant. *J Voice* 32 (5):621-624
25. Soerdjbalie-Maikoe V, van Rijn RR (2008) Embryology, normal anatomy, and imaging techniques of the hyoid and larynx with respect to forensic purposes: a review article. *Forensic Sci Med Pathol* 4 (2):132-139
26. Di Nunno N, Lombardo S, Costantinides F, Di Nunno C (2004) Anomalies and alterations of the hyoid-larynx complex in forensic radiographic studies. *The American journal of forensic medicine and pathology* 25 (1):14-19
27. Pinheiro J, Cascallana JL, Lopez de Abajo B, Otero JL, Rodriguez-Calvo MS (2018) Laryngeal anatomical variants and their impact on the diagnosis of mechanical asphyxias by neck pressure. *Forensic Sci Int* 290:1-10
28. Advenier A, De La Grandmaison GL, Cavard S, Pyatigorskaya N, Malicier D, Charlier P (2014) Laryngeal anomalies: Pitfalls in adult forensic autopsies. *Med Sci Law* 54 (1):1-7

29. Naimo P, O'Donnell C, Bassed R, Briggs C (2013) The use of computed tomography in determining developmental changes, anomalies, and trauma of the thyroid cartilage. *Forensic Sci Med Pathol* 9 (3):377-385
30. Becker M, Leuchter I, Platon A, Becker CD, Dulguerov P, Varoquaux A (2014) Imaging of laryngeal trauma. *Eur J Radiol* 83 (1):142-154
31. Core TR (2017) R: A language and environment for statistical computing. Vienna, Austria: R Foundation for Statistical Computing; 2017. ISBN3-900051-07-0 <https://www.R-project.org>,
32. McHugh ML (2012) Interrater reliability: the kappa statistic. *Biochemia medica: Biochemia medica* 22 (3):276-282
33. von Luschka H (1871) *Der Kehlkopf des Menschen. Mit zehn Tafeln Abbildungen.* Laupp,
34. Hanson DG, Mancuso AA, Hanafee WN (1982) Pseudomass lesions due to occult trauma of the larynx. *The Laryngoscope* 92 (11):1249-1253
35. Maxeiner H (1999) Healed laryngo-hyoid fractures in forensic autopsies. *Arch Kriminol* 203 (5-6):175-183
36. Khokhlov VD (1999) Knitted fractures of the laryngopharynx framework as a medico-legal matter. *Forensic Sci Int* 104 (2):147-162
37. Lim SH, Kim SW (2018) A Case of Protrusion of False Vocal Fold Resulting from the Deformed Thyroid Cartilage. *Journal of The Korean Society of Laryngology, Phoniatics and Logopedics* 29 (1):47-50

**Figure Captions**

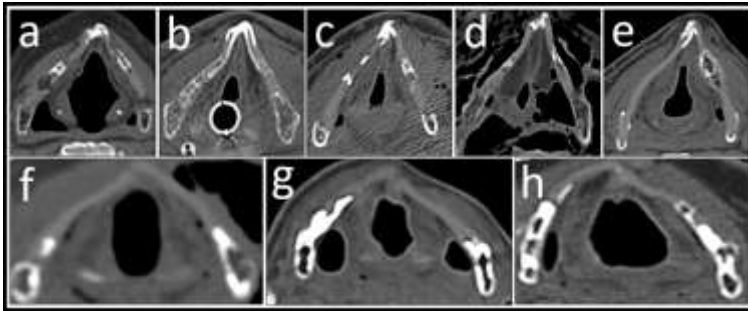
**Fig. 1:** a: PMCT transverse slice at the level of the prominentia laryngea. b: Maximum intensity projection of the same case; the cross-section in (a) is indicated by the white, dashed line.



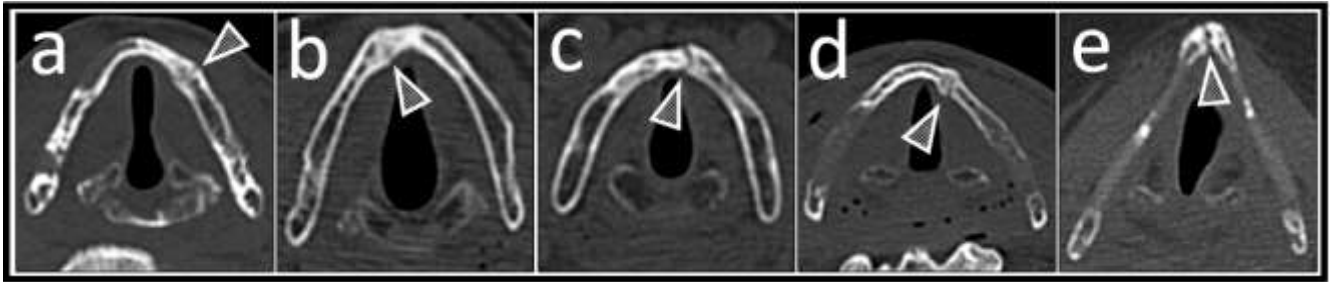
**Fig. 2:** Overview of left-sided TC asymmetry

Journal Pre-proof

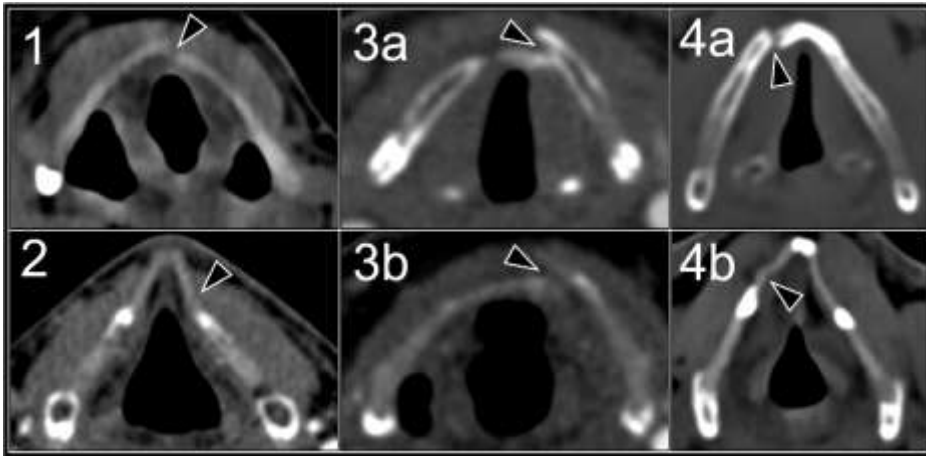




**Fig. 3:** Overview of right-sided TC asymmetry (a-e) and examples of female cases with TC asymmetry (f-h), f: right-sided, g, h: left-sided, b: cross-section with an endotracheal tube



**Fig. 4:** Examples of old TC fractures. The arrow tips depict signs of bone healing (a-d) and a pseudarthrosis (e). In 31 cases, old fractures were found in the lower parts of the TC (a-d). In 9 cases, old trauma was identified in the frontal, median part (e). Image e shows both previous trauma and minor right-sided TC inward bending



**Fig. 5:** Case series. The arrow tips depict the findings in each case, Case 1: left-sided asymmetry following NFS, Case 2: left-sided asymmetry following NFS, Case 3 a and b: displaced vertical fracture of both osseous (a) and cartilaginous parts (b) following NFS, Case 4 a and b: mildly displaced vertical fracture of osseous (a) and cartilaginous parts (b) following blunt trauma

**Table Caption**

**Table 1:** Overview of the study population and counts; SD: standard deviation; sym: symmetric; asym: asymmetric;

Journal Pre-proof

**Declaration of interests**

The authors declare that they have no known competing financial interests or personal relationships that could have appeared to influence the work reported in this paper.

The authors declare the following financial interests/personal relationships which may be considered as potential competing interests: