



University of  
Zurich<sup>UZH</sup>

Zurich Open Repository and  
Archive

University of Zurich  
Main Library  
Strickhofstrasse 39  
CH-8057 Zurich  
[www.zora.uzh.ch](http://www.zora.uzh.ch)

---

Year: 2021

---

## Cow-hitch-suture cerclage for fixation of the greater tuberosity in fracture RTSA

Grubhofer, Florian ; Bachmann, Elias ; Gerber, Christian ; Wieser, Karl ; Ernstbrunner, Lukas ;  
Warner, Jon Jp ; Bouaicha, Samy

**Abstract:** Background The treatment of complex proximal humerus fractures in the elderly with reverse total shoulder arthroplasty is an established treatment option. Healing of the greater tuberosity (GT) is associated with better outcomes. It was the aim of this cadaver study to compare the stability of GT refixation obtained with the so-called "cow hitch" cerclage fixation with that of the recommended standard suture cerclage technique. Methods A 4-part proximal humerus fracture was created in 10 fresh-frozen, human cadaveric shoulders. A CT was performed preoperatively to ensure the comparability of bone density and fracture patterns. In the experimental group the GT was reattached to the stem of the reverse total shoulder arthroplasty with the "cow hitch" suture cerclage (CH) technique, the conventional (CON) technique recommended for the tested implant was used in the control group. Humeri were tested with a uniaxial material testing machine. In total, 5000 loading cycles with forces from 250 to 350N were applied while motion (in mm) of the tuberosities was recorded with a telecentric camera. Results After 5000 loading cycles, the CH group showed a significantly smaller displacement of the bone fragment ( $0.74 \pm 0.31$  mm) than the CON group [ $2.29 \pm 1.08$  mm ( $P < .05$ )]. After the first three cycles the mean displacement was 0.14 mm ( $\pm 0.12$ ) in the CH and 1.42 mm ( $\pm 0.21$ ) in the CON ( $P < .0001$ ) groups. Conclusions GT reattachment with the "cow hitch" suture cerclage showed a significantly more stable fixation compared with the currently for the used prosthetic system recommended suture cerclage technique in an in vitro 4-part proximal humeral fracture model.

DOI: <https://doi.org/10.1016/j.jseint.2020.10.016>

Posted at the Zurich Open Repository and Archive, University of Zurich

ZORA URL: <https://doi.org/10.5167/uzh-201271>

Journal Article

Published Version



The following work is licensed under a Creative Commons: Attribution-NonCommercial-NoDerivatives 4.0 International (CC BY-NC-ND 4.0) License.

Originally published at:

Grubhofer, Florian; Bachmann, Elias; Gerber, Christian; Wieser, Karl; Ernstbrunner, Lukas; Warner, Jon Jp; Bouaicha, Samy (2021). Cow-hitch-suture cerclage for fixation of the greater tuberosity in fracture RTSA. *JSES International*, 5(2):270-276.

DOI: <https://doi.org/10.1016/j.jseint.2020.10.016>



ELSEVIER

Contents lists available at ScienceDirect

JSES International

journal homepage: [www.jseinternational.org](http://www.jseinternational.org)

## Cow-hitch-suture cerclage for fixation of the greater tuberosity in fracture RTSA

Florian Grubhofer, MD <sup>a,\*</sup>, Elias Bachmann, PhD <sup>a</sup>, Christian Gerber, MD, FRCS <sup>a</sup>,  
Karl Wieser, MD <sup>a</sup>, Lukas Ernstbrunner, MD <sup>a</sup>, Jon JP. Warner, MD <sup>b</sup>, Samy Bouaicha, MD <sup>a</sup>

<sup>a</sup> Balgrist University Hospital, Department of Orthopedics, University of Zürich, Zürich, Switzerland

<sup>b</sup> Massachusetts General Hospital, Department of Orthopedics, Harvard Medical School, Boston, MA, USA

### ARTICLE INFO

#### Keywords:

Proximal humerus fracture  
reverse total shoulder arthroplasty  
greater tuberosity fixation technique  
cow hitch cerclage  
Cadaver study  
in vitro stability testing of the greater tuberosity

Level of evidence: Basic Science Study;  
Biomechanics

**Background:** The treatment of complex proximal humerus fractures in the elderly with reverse total shoulder arthroplasty is an established treatment option. Healing of the greater tuberosity (GT) is associated with better outcomes. It was the aim of this cadaver study to compare the stability of GT re-fixation obtained with the so-called “cow hitch” cerclage fixation with that of the recommended standard suture cerclage technique.

**Methods:** A 4-part proximal humerus fracture was created in 10 fresh-frozen, human cadaveric shoulders. A CT was performed preoperatively to ensure the comparability of bone density and fracture patterns. In the experimental group the GT was reattached to the stem of the reverse total shoulder arthroplasty with the “cow hitch” suture cerclage (CH) technique, the conventional (CON) technique recommended for the tested implant was used in the control group. Humeri were tested with a uniaxial material testing machine. In total, 5000 loading cycles with forces from 250 to 350N were applied while motion (in mm) of the tuberosities was recorded with a telecentric camera.

**Results:** After 5000 loading cycles, the CH group showed a significantly smaller displacement of the bone fragment ( $0.74 \pm 0.31$  mm) than the CON group [ $2.29 \pm 1.08$  mm ( $P < .05$ )]. After the first three cycles the mean displacement was 0.14 mm ( $\pm 0.12$ ) in the CH and 1.42 mm ( $\pm 0.21$ ) in the CON ( $P < .0001$ ) groups.

**Conclusions:** GT reattachment with the “cow hitch” suture cerclage showed a significantly more stable fixation compared with the currently for the used prosthetic system recommended suture cerclage technique in an in vitro 4-part proximal humeral fracture model.

© 2020 The Author(s). Published by Elsevier Inc. on behalf of American Shoulder and Elbow Surgeons. This is an open access article under the CC BY-NC-ND license (<http://creativecommons.org/licenses/by-nc-nd/4.0/>).

Reverse total shoulder arthroplasty (RTSA) has become an established treatment option for elderly patients with complex proximal humeral fractures.<sup>9</sup> Greater tuberosity (=GT) healing in patients treated with RTSA is associated with better clinical outcome than if the GT does not heal.<sup>3,4,6–8,14</sup> For this reason, various GT re-fixation techniques have been studied and applied to improve the mechanical fixation of the GT, with the ultimate goal of achieving increased bony healing of the GT.<sup>1,10,15</sup>

There is currently no standard fixation technique. Depending on the implant system, various techniques are recommended. Baumgartner has provided a comprehensive compilation of the existing fixation methods.<sup>1</sup> The technique of tuberosity fixation differs

between authors, but heavy, nonabsorbable single stranded suture loops or single wire cerclage are constantly used for fixation of the tuberosities.

Double suture loop cerclage techniques achieve higher fixation strength than single-stranded loops in vitro.<sup>11</sup> Different double loop suture cerclage techniques (“cow hitch”, “nice knot”, half hitch,) were compared in a biomechanical study regarding stability properties and the “cow hitch” cerclage showed superior results.<sup>11</sup> The use of the cow hitch cerclage for GT fixation during the implantation of a fracture RTSA has never been investigated biomechanically regarding GT fragment stabilization.

The aim of this study was to investigate whether the “cow hitch” cerclage technique could improve the biomechanical stability of greater tuberosity fixation over the conventional (CON) fixation technique described originally by Frankle et al<sup>5</sup> and which is also recommended for the tested implant (ZimmerBiomet® Anatomical Shoulder™ Fracture System).

This study was approved by the Ethical Committee Zürich (Cantonal Ethical Committee no. ZH-Nr.2018-00588).

\* Corresponding author: Florian Grubhofer, MD, Balgrist University Hospital, University of Zürich, 8008 Zürich, Switzerland.

E-mail address: [florian.grubhofer@balgrist.ch](mailto:florian.grubhofer@balgrist.ch) (F. Grubhofer).

<https://doi.org/10.1016/j.jseint.2020.10.016>

2666-6383/© 2020 The Author(s). Published by Elsevier Inc. on behalf of American Shoulder and Elbow Surgeons. This is an open access article under the CC BY-NC-ND license (<http://creativecommons.org/licenses/by-nc-nd/4.0/>).

## Methods

After IRB approval of the study (Cantonal Ethical Committee number: ZH-Nr.2018-00588), 10 fresh frozen human forequarter shoulder specimen which were purchased from Science Care®, Phoenix, AZ, USA, were used for this study. The number of cadavers used for this study is based on a comparable study in which 8 cadavers were used to compare achieved GT fragment stability of different fixation techniques.<sup>10</sup> The experiment of each shoulder was divided into three parts. In the first part, the 4 part proximal humerus fracture was created, followed by the computer tomography (CT) examination. The second part consisted of the implantation of the RTSA and the reattachment of the greater tuberosity. These two surgical parts were performed by FG with assistance of the authors LE and CG. In the third part, the proximal Humeri were tested biomechanically by the second author (EB).

### *Creation of the 4-part fracture (first surgical part)*

To simulate the surgical condition as realistically as possible, the human cadaveric shoulders with muscle, ligaments, soft tissue, and skin were used to perform the experiments. The deep-frozen shoulder specimens were thawed over 12 hours in a 4°C refrigerator. The specimens were fixated in beach chair position. Through a deltopectoral approach a four-part humerus fracture was created with a chisel. The greater tuberosity was fractured first by using the chisel as a lever arm so that a typical irregular fracture margin was created. The lesser tuberosity was fractured in the same way as the greater tuberosity. In the last step, the humeral neck fracture was created resulting in a 4-part fracture.

### *CT scan and randomization*

All fractures were CT scanned (see Fig. 1). The bone density of the proximal Humeri was measured in accordance with the method described by Rho et al.<sup>13</sup> The greater tuberosity fracture fragments were measured in the CT examination and paired by size. In total, 5 shoulder pairs were created. To reduce a selection bias, each pair has been randomly allocated by the use of lots to the two different GT fixation techniques before the RTSA was implanted.

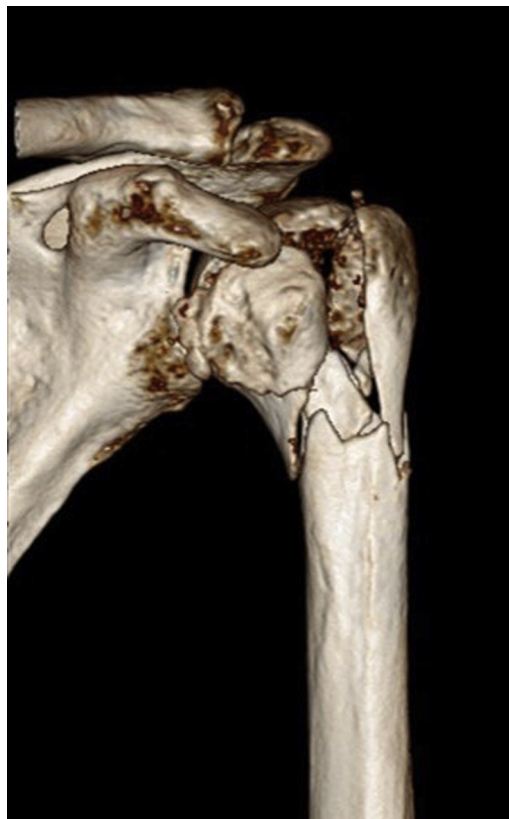
### *Implantation of the RTSA and reattachment of the GT*

The greater and the lesser tuberosity fragments were mobilized and grasped with MaxBraid sutures #5 (ZimmerBiomet, Warsaw, IN, USA) sutures. The supraspinatus tendon was released from the greater tuberosity leaving the infraspinatus tendon alone on the greater tuberosity. The fracture stem assembled with the reverse humeral base plate carrying a 10mm polyethylene inlay (Anatomical Shoulder Reverse Fracture, Zimmer Biomet®, Warsaw, IN, USA) was cemented (Refobacin Bone cement R, Zimmer Biomet®, IN, USA) in 20° of retroversion into the humeral shaft. The height of the prosthetic stem was determined by using the upper border of the pectoralis major tendon insertion as a reference.<sup>12</sup>

### *Reattachment of the greater tuberosity*

#### *Conventional reattachment technique*

The for the tested implant system recommended fixation technique (ZimmerBiomet® Anatomical Shoulder™ Fracture System's Manual) was used to serve as the control group (see Fig. 2). For each shoulder specimen of this group 4 MaxBraid sutures #5 were used for the fixation of the greater tuberosity. The first suture was passed around the greater tuberosity and through the lateral prosthetic stem hole; the second suture was passed around the greater

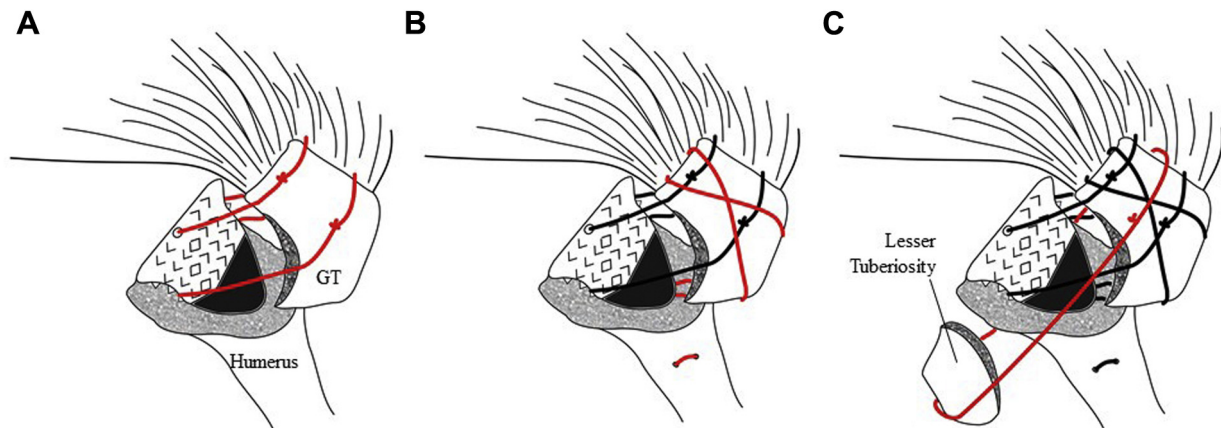


**Figure 1** CT 3D reconstruction of a created proximal 4 part fracture.

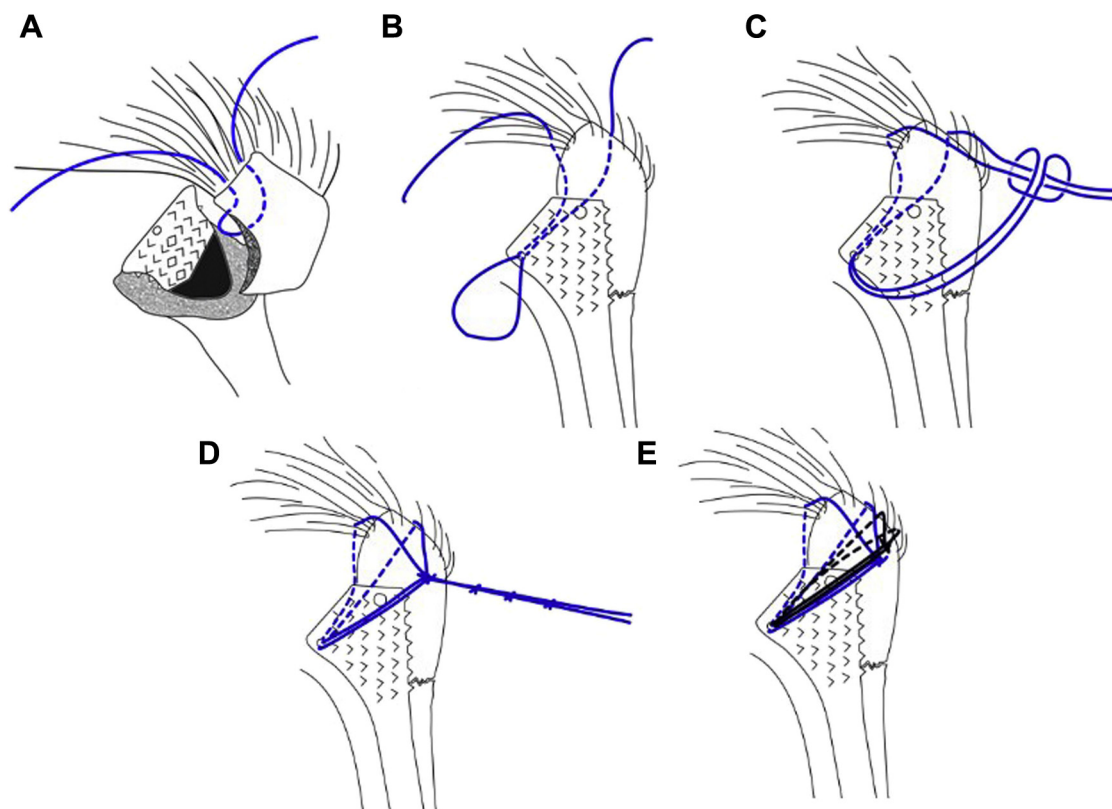
tuberosity and through the medial prosthetic stem hole (see Fig. 2A). The third suture was passed around the greater tuberosity in a vertical fashion and through humeral bone drill holes of the prosthesis. The suture was passed through the drill holes before the prosthesis was implanted (see Fig. 2B). The fourth suture was passed around the greater and lesser tuberosity (see Fig. 2C). To reduce the GT, the proximal humerus was reduced into the glenohumeral joint capsule. The reduction of the greater tuberosity fragment was secured using a grasper. The sutures were then knotted manually with seven half hitches with maximal adjustable tension. To prevent loosening of the knot's tension, a needle holder was used to secure the tension after setting the first knot. Even though the lesser tuberosity stabilization was not the purpose of this study, the lesser tuberosity was reattached with 2 MaxBraid sutures #5 to create a rotational counter force for the tested GT-infraspinatus unit.

#### *Cow hitch technique*

The greater tuberosity was fixed using 2 MaxBraid sutures #5 (ZimmerBiomet, Warsaw, IN, USA) in a double-loop cerclage fashion for this group: The stitches were made at the infraspinatus—greater tuberosity tendon-bone junction (see Fig. 3). For the first stitch, the needle is brought from the extracapsular space into the intracapsular space; the second stitch of the first suture was passed from the intra-articular space to the subacromial space (Fig. 3A). The created loop was passed through the medial prosthetic stem (Fig. 3B). Two loops are created out of the major loop and the free suture limbs are then passed through the double loop (Fig. 3C). Herewith a cerclage mechanism is created which allows developing tension on the suture by pulling on the free limbs. The self-blocking mechanism of the cerclage prevents tension loss of the construct. No hemostats are necessary to secure the knots.



**Figure 2** Illustration of the conventional knotting technique: The first suture is passed around the greater tuberosity (GT) and through the lateral prosthetic shaft hole; the second suture was passed around the greater tuberosity and through the medial prosthetic shaft hole (A). The third suture was passed around the greater tuberosity in a vertical fashion and through humeral bone drill holes of the shaft. The suture was passed through the drill holes before the shaft was implanted (B). The fourth suture was passed around the greater and lesser tuberosity (C).



**Figure 3** Illustration of the cow hitch knotting technique. The infraspinatus tendon is armed at the tendon-bone interface with an outside-in and in-outside stitch so that a suture loop is created intra-articularly (A). The loop is channeled through the medial calcar hole of the prosthetic stem (B). The loop is folded twice so that two loops are created within the loop part. These two loops are placed next to each other so that the two free limbs can be shuttled through both loops (C). The cow hitch is secured with three knots (D). A second “cow hitch” is mounted inferiorly to the first cow hitch cerclage (E).

Maximal tension was adjusted and then the cerclage was secured with three half hitches (Fig. 3D). The second suture is placed inferiorly to the first cerclage at the interphase between the greater tuberosity and the infraspinatus tendon in the same way (Fig. 3E) as the first suture was set. No vertical humeral shaft sutures were set in this group.


The lesser tuberosity was fixed in the cow hitch group using one MaxBraid #5 suture for one cow hitch cerclage.

#### Experiment apparatus

Each humerus together with the implanted fracture prosthesis and the attached greater tuberosity/infraspinatus and lesser tuberosity/subscapularis tendon-muscle unit were dissected from the shoulder. The muscle tissue was dissected and the remaining infraspinatus and subscapularis tendons were mounted each with two MaxBraid #5 sutures for the purpose of biomechanical testing.

The Humeri were potted in cylinders using SCS-Beracryl D-28 (Suter Kunststoffe AG, Fraubrunnen, Switzerland). During potting, care was taken to center and perpendicularly align the shaft to the ground plate.

Potted specimens were mounted in a custom-made testing cage on a universal material testing machine (Zwick 1456, Zwick GmbH, Ulm, Germany). To simulate daily forces, acting on the prosthesis and remaining rotator cuff muscles a previously described testing setup was used<sup>2</sup> (Fig. 4). Pull sutures of the infraspinatus and subscapularis tendons were guided via a series of pulleys and attached to a suture receiving device which is connected to the machine cross arm (Fig. 5). Pullout testing was initiated with a preload of 50N and a constant displacement rate of 0.5mm/sec. Data were recorded using TestXpert 10 software (Zwick-Roell, Zwick GmbH, Ulm, Germany) and maximum pullout force was quantified as well as failure mode. In addition, a piezo load cell 9001A (Kistler Instrumente AG, Winterthur, Switzerland) which was attached behind the glenoid component measured maximum joint reaction forces. 5000 tension cycles of 250-350N with 0.5 Hz were applied on these sutures in line with the physiologic action of the two respective muscles.



**Figure 5** Test set up with the potted humerus. The infraspinatus and subscapularis tendon is each mounted with one MaxBraid #5 suture to make testing of the greater tuberosity possible. The movement of the greater tuberosity fragment is monitored with a telecentric camera.

*Measurement of fracture displacement*

The greater tuberosity displacement of each specimen was measured in millimeter as the primary outcome parameter. To measure displacement of the bone fragments, a telecentric lens was used (Telecentric lens: Techspec large format 62-921, Edmund Optics, Barrington, NJ, USA) and images from orthogonal view of the greater tuberosity were taken. Images were taken at 0, 3, 250, 500, 1000, 2000, 3000, 4000, and 5000 cycles, both in cyclic loaded (350N) and unloaded (250N) states. For that, optical measurement of relative displacement between the greater tuberosity fragment and the prosthesis was done by an automated script after manually selecting the bone contours using image processing software ImageJ 1.52 (National Institutes of Health, USA). The joint reaction force was measured at the glenosphere in both groups to be sure that the forces acting on the greater tuberosity via the tendons were transmitted to the same extent in both groups.

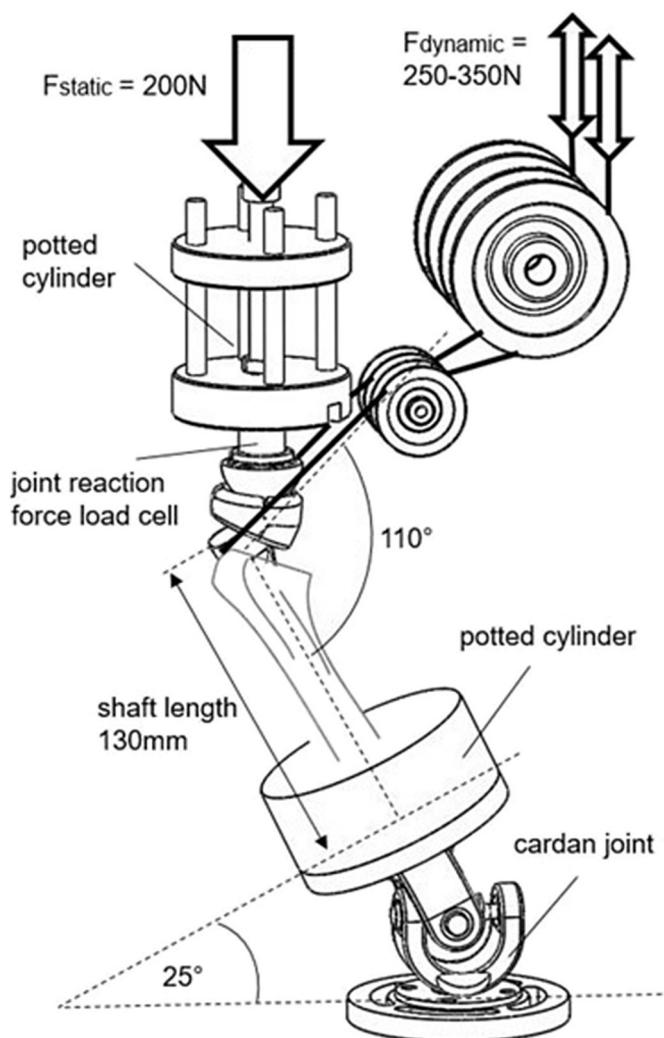
*Statistical analysis*

Data obtained in each group were analyzed statistically by F-tests to compare variances followed by unpaired, two-tailed t-tests with statistical software GraphPad Prism 7.03 (GraphPad Software, San Diego, CA, USA). Results are reported with means and whiskers showing the 95% confidence interval. A P value of <.05 was considered to be statistically significant.

**Results**

The mean age of the cadaveric shoulders was 78 ± 4.5 years in the control group and 83 ± 2.3 years in the cow hitch group (P = .138). The distribution of female/male and dexterity was equal in both groups (3 female/ 2 male, 2 right and 3 left shoulders). The bone density of the greater tuberosity in both groups showed no significant differences (cow hitch: 0.181g/cm<sup>3</sup> ± 0.0068 vs. control group: 0.194g/cm<sup>3</sup> ± 0.0093, P = .387).

One shoulder of a 78-year-old female specimen in the conventional group showed gross comminution after creating the fracture so that this shoulder was excluded from the study. In total, 4 shoulders were used for the testing of the control group technique and 5 shoulders were used for the testing of the cow hitch technique.



**Figure 4** Schematic biomechanical test set up.

The initial fragment displacement during cyclic loading between the first and the third cycle showed a mean displacement of 0.14mm ( $\pm 0.12$  mm) in the cow hitch group and a mean displacement of 1.42 mm ( $\pm 0.21$ )  $P < .0001$  in the control group—Figure 6. After 5000 loading cycles, the cow hitch group showed a mean displacement distance of  $0.73 \pm 0.33$  mm and the conventional group showed a mean displacement of  $2.28 \pm 1.08$  mm ( $P < .05$ )—Figure 7.

The mean greater tuberosity displacement in the cow hitch group of less than one millimeter was not visible with the naked eye, whereas the displacement in the conventional group was easily visible (see Video, Supplemental Digital Content which demonstrates the greater tuberosity movement after reattachment with the two different techniques). In both groups, the main displacement appears during the first 500 loading cycles (cow hitch:  $0.46 \pm 0.30$  mm, conventional:  $1.94 \pm 0.42$  mm) and was stable between the cycles 1000 and 5000—Figure 8.

The ultimate failure force was  $1302 \pm 259$ N in the cow hitch group and  $1121 \pm 301.2$ N in the conventional group ( $P = .337$ )—Figure 9A. The failure occurred after application of the maximum failure force either at the suture anchorage in the area of the infraspinatus or subscapularis tendon or the tendon was torn out from the tendon to bone insertion. The greater tuberosity was not displaced in any of the 9 shoulders when the maximum failure force was applied.

The mean joint reaction force of the cow hitch group was  $797 \pm 307$ N and  $858 \pm 376$ N in the conventional group ( $P = .381$ ) which proves that the applied forces were equally distributed to the proximal humerus in both groups—Figure 9B.

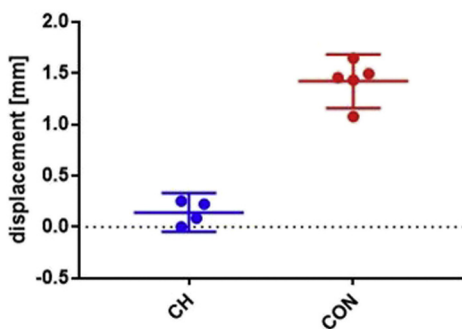


Figure 6 Fragment movement in millimeters depending after the first 3 cyclic loads. CH, cow hitch GT fixation technique represented in the figure as ●; and CON, conventional or control GT fixation technique represented in the figure as ●. Scatterplots with means and 95% CI whiskers.

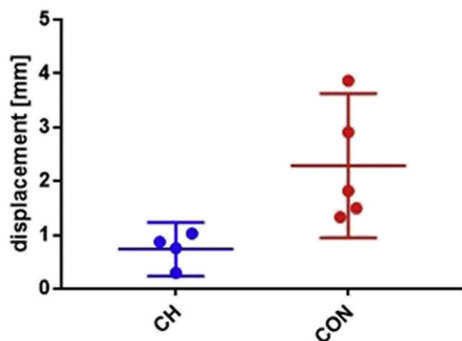


Figure 7 Fragment movement in millimeters depending after 5000 cyclic loads. CH, cow hitch GT fixation technique represented in the figure as ●; and CON, conventional or control GT fixation technique represented in the figure as ●. Scatterplots with means and 95% CI whiskers.

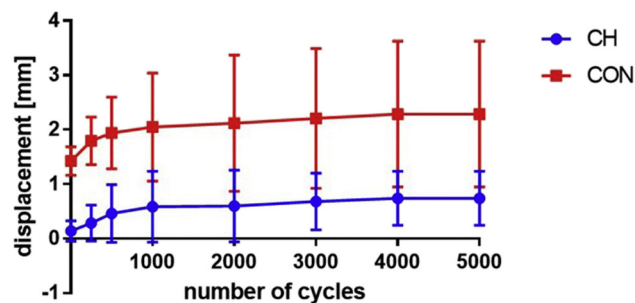


Figure 8 Fragment movement in millimeters of both groups from 1<sup>st</sup> to last (5000) cyclic load. CH, cow hitch GT fixation technique represented in the figure as ●; and CON, conventional or control GT fixation technique represented in the figure as ●. Scatterplots with means and 95% CI whiskers.

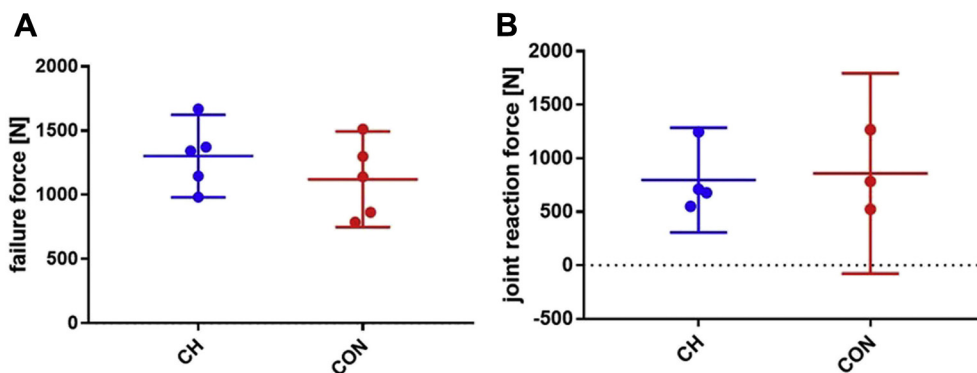
Discussion

Greater tuberosity reattachment with the “cow hitch” suture cerclage showed significantly less movement of the greater tuberosity upon experimental loading compared with a currently recommended suture cerclage in an in vitro 4-part proximal humeral fracture model. As the main difference in stability was already observed within the first three loading cycles, clinical differences in displacement rates would be expected to become evident early after greater tuberosity reattachment. Knots typically settle within the first load cycles. Even though the settlement of the knotted sutures is less than few millimeters, this can explain the displacement of the fragments especially during the first loading cycles. One of the main advantages of the cow hitch cerclage knot is that the applied tension can be better secured by the self-locking mechanism, resulting in significantly less tension loss of the knot.

Whether this higher fixation strength results in less secondary displacement and failure to heal of the greater tuberosity and therefore better clinical outcome, needs to be investigated in clinical studies.

The healing of the greater tuberosity not only depends on the stability of the fixation, biological factors, which could not be assessed in this study, can also influence the healing rate. Nevertheless, the mechanical stabilization of fracture fragments is a basic prerequisite for bone healing. In this context, it should be mentioned that this study was initiated by our institution because reliable healing of the GT was observed in patients treated with fracture RTSAs in which the GT was reattached with the cow hitch technique. The clinical impression of a more stable GT stabilization by using the cow hitch technique could be confirmed in this in vitro study, and accordingly we have switched from the conventional fixation technique to the cow hitch fixation method in our facilities.

In the in vitro experiment, we intentionally used only 2 double-loop cerclage sutures to investigate whether even using half the amount of suture material the higher stabilization effect is achieved than the conventional method where 4 single-loop sutures are used. The cow hitch fixation technique with 2 sutures was mechanically more stable than the conventional technique with 4 sutures. One possible explanation for this is the cerclage mechanism of the cow hitch node, which secures the applied tension by a self-locking mechanism, thus contributing to increased continuous maintenance of the fixation tension. (see Video, Supplemental Digital Content which demonstrates the greater tuberosity movement after reattachment with the two different techniques). The study has two major limitations: 1) The sutures were manually knotted with the use of needle holder for the first knot of the



**Figure 9** Ultimate failure force (A) and maximum joint reaction forces (B) during pull-out. CH, cow hitch GT fixation technique represented in the figure as ●; and CON, conventional or control GT fixation technique represented in the figure as ●. Scatterplots with means and 95% CI whiskers.

conventional cerclage technique to secure the tension of the first knot. The applied tension to the conventional and the cow hitch cerclage was not assessed which represents a limitation of the study. Nevertheless, in both cerclage techniques, the cerclages were tied with the most adjustable tension. 2) In this study, only one control fixation technique, which is, however, recommended for the tested implant, was compared with the new fixation technique although a variety of different fixation techniques exist. The different, currently recommended techniques differ little from the “standard technique” used in the study<sup>1,10,15</sup> because only single sutures are used in the respective techniques. Nevertheless, the conventional fixation technique, which was described by M. Frankle<sup>5</sup> and also adopted by Gerber C. and Warner JJP in the manual of the implant used, is established and also recommended by the American Academy of Orthopaedic Surgeons as a fixation technique of greater tuberosity in the implantation of the fracture RTSA.<sup>9</sup> The use of wire cerclages for greater tuberosity fixation was described and showed interesting in vitro findings.<sup>10</sup> Nevertheless, wire cerclage can cause rotator cuff damage in case of wire breakage or wear and therefore the wire cerclage refixation techniques does not seem to be an ideal control technique for this study. Application of absolute failure forces resulted either in tearing of the infraspinatus tendon at the tendon-bone interphase or pullout of the sutures. Accordingly, the absolute pullout force for the conventionally and the cow hitch fixed greater tuberosities could not be determined. Nevertheless, the dislocation of the greater tuberosity, which is clinically relevant because it typically causes nonunion of the fragment with concomitant poorer clinical results, could be reproduced by the cyclic loading.

In addition, the similar joint reaction forces in the two groups served to prove that the test forces applied in both groups were transferred in a similar fashion to the tested shoulder.

The substantial and significant improvement of greater tuberosity stability using the “cow hitch” technique invites to study its value for greater tuberosity fixation in hemiarthroplasty as for this type of fracture arthroplasty greater tuberosity displacement is an even bigger clinical problem and if for this arthroplasty a successful refixation of the greater tuberosity could be developed, it might actually become a game changer. This hypothesis question is currently tested in a further study.

**Conclusion**

The cow hitch cerclage technique yields significantly higher stability of greater tuberosity fixation in reverse total shoulder replacement than a conventional fixation technique. The greatest displacement can be found very early, after the first loading cycles.

These findings suggest that a comparative clinical study could reveal differences in secondary displacement of the greater tuberosity very early postoperatively, so that clinical studies should be planned accordingly.

**Disclaimer**

Zimmer Biomet GmbH, a company duly organized and existing under the laws of Switzerland with registered office at Sulzerallee 8, 8404 Winterthur, Switzerland (hereinafter “Zimmer Biomet”) provided the materials used for the study. No payments were made to an author or his family.

CG received royalties and consultant payments from Zimmer Biomet, which is not related to the subject of this work.

JJW is a consultant for Wright Medical Group, which is not related to the subject of this work.

The other authors (FG, EB, LE, KW, ARMM, SB) certify that he or she has no commercial associations (eg, consultancies, stock ownership, equity interest, patent/licensing arrangements, etc.) that might pose a conflict of interest in connection with the submitted article.

**Acknowledgments**

This study is dedicated to Dominik C. Meyer, who unfortunately passed away much too early on 15 December 2019. The Cow Hitch Knot is one of many ideas that Professor Meyer has implemented in shoulder surgery and has helped so many patients and also doctors with their treatment.

The biomechanical testing was performed at the Department of Orthopedics, University of Zürich, Balgrist University Hospital, Forchstrasse 340, CH-8008 Zürich, Switzerland, and at the Balgrist Campus AG, Lengghalde 8, 8008 Zürich, Switzerland. The data analysis and completion of the manuscript was performed at Massachusetts General Hospital, Harvard Medical School, Boston, MA, USA.

**Supplementary data**

Supplementary data to this article can be found online at <https://doi.org/10.1016/j.jseint.2020.10.016>.

**References**

1. Baumgartner D, Lorenzetti SR, Mathys R, Gasser B, Stussi E. Refixation stability in shoulder hemiarthroplasty in case of four-part proximal humeral fracture. Med Biol Eng Comput 2009;47:515-22. <https://doi.org/10.1007/s11517-009-0483-7>.

2. Brianza S, Plecko M, Gueorguiev B, Windolf M, Schwieger K. Biomechanical evaluation of a new fixation technique for internal fixation of three-part proximal humerus fractures in a novel cadaveric model. *Clin Biomech (Bristol, Avon)* 2010;25:886-92. <https://doi.org/10.1016/j.clinbiomech.2010.06.015>.
3. Cazeneuve JF, Cristofari DJ. Grammont reversed prosthesis for acute complex fracture of the proximal humerus in an elderly population with 5 to 12 years follow-up. *Orthop Traumatol Surg Res* 2014;100:93-7. <https://doi.org/10.1016/j.otsr.2013.12.005>.
4. Ernstbrunner L, Rahm S, Suter A, Imam MA, Catanzaro S, Grubhofer F, et al. Salvage reverse total shoulder arthroplasty for failed operative treatment of proximal humeral fractures in patients younger than 60 years: long-term results. *J Shoulder Elbow Surg* 2020;29:561-70. <https://doi.org/10.1016/j.jse.2019.07.040>.
5. Frankle MA, Ondrovic LE, Markee BA, Harris ML, Lee WE 3rd. Stability of tuberosity reattachment in proximal humeral hemiarthroplasty. *J Shoulder Elbow Surg* 2002;11:413-20. <https://doi.org/10.1067/mse.2002.126098>.
6. Gallinet D, Adam A, Gasse N, Rochet S, Obert L. Improvement in shoulder rotation in complex shoulder fractures treated by reverse shoulder arthroplasty. *J Shoulder Elbow Surg* 2013;22:38-44. <https://doi.org/10.1016/j.jse.2012.03.011>.
7. Grubhofer F, Wieser K, Meyer DC, Catanzaro S, Beeler S, Riede U, et al. Reverse total shoulder arthroplasty for acute head-splitting, 3- and 4-part fractures of the proximal humerus in the elderly. *J Shoulder Elbow Surg* 2016;25:1690-8. <https://doi.org/10.1016/j.jse.2016.02.024>.
8. Grubhofer F, Wieser K, Meyer DC, Catanzaro S, Schurholz K, Gerber C. Reverse total shoulder arthroplasty for failed open reduction and internal fixation of fractures of the proximal humerus. *J Shoulder Elbow Surg* 2017;26:92-100. <https://doi.org/10.1016/j.jse.2016.05.020>.
9. Jobin CM, Galdi B, Anakwenze OA, Ahmad CS, Levine WN. Reverse shoulder arthroplasty for the management of proximal humerus fractures. *J Am Acad Orthop Surg* 2015;23:190-201. <https://doi.org/10.5435/JAAOS-D-13-00190>.
10. Knierzinger D, Heinrichs CH, Hengg C, Konschake M, Kralinger F, Schmoelz W. Biomechanical evaluation of cable and suture cerclages for tuberosity reattachment in a 4-part proximal humeral fracture model treated with reverse shoulder arthroplasty. *J Shoulder Elbow Surg* 2018;27:1816-23. <https://doi.org/10.1016/j.jse.2018.04.003>.
11. Meyer DC, Bachmann E, Ladermann A, Lajtai G, Jentzsch T. The best knot and suture configurations for high-strength suture material. An in vitro biomechanical study. *Orthop Traumatol Surg Res* 2018;104:1277-82. <https://doi.org/10.1016/j.otsr.2018.08.010>.
12. Murachovsky J, Ikemoto RY, Nascimento LG, Fujiki EN, Milani C, Warner JJ. Pectoralis major tendon reference (PMT): a new method for accurate restoration of humeral length with hemiarthroplasty for fracture. *J Shoulder Elbow Surg* 2006;15:675-8. <https://doi.org/10.1016/j.jse.2005.12.011>.
13. Rho JY, Hobatho MC, Ashman RB. Relations of mechanical properties to density and CT numbers in human bone. *Med Eng Phys* 1995;17:347-55.
14. Simovitch RW, Roche CP, Jones RB, Routman HD, Marczuk Y, Wright TW, et al. Effect of Tuberosity Healing on Clinical Outcomes in Elderly Patients Treated With a Reverse Shoulder Arthroplasty for 3- and 4-Part Proximal Humerus Fractures. *J Orthop Trauma* 2019;33:e39-45. <https://doi.org/10.1097/BOT.0000000000001348>.
15. Valenti P, Aliani D, Maroun C, Werthel JD. A New Stem Guide and a Tuberosity Anchoring "Lasso" System for Shoulder Hemiarthroplasty in the Treatment of Complex Proximal Humerus Fractures. *Tech Hand Up Extrem Surg* 2017;21:131-6. <https://doi.org/10.1097/BTH.0000000000000172>.