



Year: 2020

Distal Femoral Cortical Irregularity at Knee MRI: Increased Prevalence in Youth Competitive Alpine Skiers

Stern, Christoph ; Galley, Julien ; Fröhlich, Stefan ; Peterhans, Loris ; Spörri, Jörg ; Sutter, Reto

Abstract: Background Tumor-like cortical irregularities at the posterior distal femur are common incidental findings in adolescents, but the origin of these irregularities is debated. Purpose To compare the prevalence of distal femoral cortical irregularities (DFCIs) at different tendon attachment sites in youth competitive alpine skiers with that in young adults. Materials and Methods In this secondary analysis of a prospective trial, unenhanced 3-T knee MRI scans obtained in youth competitive alpine skiers were compared with images in control participants of the same age from 2014 to 2019 (Cantonal Ethics Committee Zurich registry number: KEK-ZH-2017-01395) for presence of DFCIs at the femoral attachment of the medial head of the gastrocnemius muscle (MHG) and/or lateral head of the gastrocnemius muscle (LHG) and adductor magnus tendon by two radiologists. DFCI size and tendon attachment position were measured. Tendon attachment position and associated MRI findings (meniscus, cartilage, bone marrow edema, joint effusion, ligaments, tendons) were examined for an association with DFCI. Pearson², Student t test, logistic regression, and statistics were applied. Results Unilateral knee MRI scans obtained in 105 skiers (mean age, 14.8 years \pm 0.6 [standard deviation]; 66 boys) and in 105 control participants (mean age, 14.6 years \pm 0.5; 59 boys) were evaluated. DFCIs were found in 61 of 105 skiers (58%; 95% confidence interval [CI]: 48.5%, 67.2%) compared with 28 of 105 control participants (27%; 95% CI: 18.9%, 35.7%) ($P < .001$). Two skiers had more than one DFCI. Distribution of DFCIs for skiers and control participants was 60 of 63 (95.2%) and 26 of 28 (92.8%) at the MHG, three of 63 (4.8%) and one of 28 (3.6%) at the LHG, and zero of 63 (0%) and one of 28 (3.6%) at the adductor magnus attachment site, respectively. Interreader agreement was almost perfect ($\kappa = 0.87$; 95% CI: 0.80, 0.93). The mean size of MHG-related DFCIs in skiers (3.7 mm) was not different compared to the size of those in control participants (3.4 mm) ($P = .32$), nor was a difference found for the MHG tendon attachment position in knees with DFCI (63.9 mm vs 63.0 mm, $P = .83$) or without DFCI (63.6 mm vs 62.8 mm, $P = .86$). Regarding associated MRI findings, increased signal intensity of the MHG tendon showed a significant association with MHG-related DFCI in both groups ($P = .01$ for both). Conclusion A distal femoral cortical irregularity at the attachment sites of tendons was a frequent incidental finding on knee MRI scans, with an increased prevalence in youth competitive alpine skiers. © RSNA, 2020 Online supplemental material is available for this article.

DOI: <https://doi.org/10.1148/radiol.2020192589>

Posted at the Zurich Open Repository and Archive, University of Zurich

ZORA URL: <https://doi.org/10.5167/uzh-199298>

Journal Article

Published Version



The following work is licensed under a Creative Commons: Attribution 4.0 International (CC BY 4.0) License.

Originally published at:

Stern, Christoph; Galley, Julien; Fröhlich, Stefan; Peterhans, Loris; Spörri, Jörg; Sutter, Reto (2020). Distal Femoral Cortical Irregularity at Knee MRI: Increased Prevalence in Youth Competitive Alpine Skiers. *Radiology*, 296(2):411-419.

DOI: <https://doi.org/10.1148/radiol.2020192589>



Distal Femoral Cortical Irregularity at Knee MRI: Increased Prevalence in Youth Competitive Alpine Skiers

Christoph Stern, MD • Julien Galley, MD • Stefan Froehlich, MD • Loris Peterhans • Joerg Spoerri, PhD • Reto Sutter, MD

From the Department of Radiology (C.S., J.G., R.S.), Sports Medical Research Group, Department of Orthopedics (S.F., L.P., J.S.), and University Centre for Prevention and Sports Medicine (S.F., L.P., J.S.), Balgrist University Hospital, Forchstrasse 340, CH-8008, Zürich, Switzerland; and Faculty of Medicine, University of Zurich, Zurich, Switzerland (C.S., J.G., R.S.). Received November 22, 2019; revision requested December 31; revision received April 15, 2020; accepted April 27. **Address correspondence** to C.S. (e-mail: christoph.stern@balgrist.ch).

Parts of this research project, the knee MRI of youth competitive alpine skiers as part of an observational sports medicine trial focused on injury prevention (called Injury Screening and Prevention Alpine Skiing [ISPA]), was supported by grants from the Balgrist Foundation, Swiss-Ski, the Stiftung Passion Schneesport, and the Stiftung zur Foerderung des alpinen Skisportes in der Schweiz.

Conflicts of interest are listed at the end of this article.

Radiology 2020; 00:1–9 • <https://doi.org/10.1148/radiol.2020192589> • Content codes:  

Background: Tumor-like cortical irregularities at the posterior distal femur are common incidental findings in adolescents, but the origin of these irregularities is debated.

Purpose: To compare the prevalence of distal femoral cortical irregularities (DFCIs) at different tendon attachment sites in youth competitive alpine skiers with that in young adults.

Materials and Methods: In this secondary analysis of a prospective trial, unenhanced 3-T knee MRI scans obtained in youth competitive alpine skiers were compared with images in control participants of the same age from 2014 to 2019 (Cantonal Ethics Committee Zurich registry number: KEK-ZH-2017-01395) for presence of DFCIs at the femoral attachment of the medial head of the gastrocnemius muscle (MHG) and/or lateral head of the gastrocnemius muscle (LHG) and adductor magnus tendon by two radiologists. DFCI size and tendon attachment position were measured. Tendon attachment position and associated MRI findings (meniscus, cartilage, bone marrow edema, joint effusion, ligaments, tendons) were examined for an association with DFCI. Pearson χ^2 , Student *t* test, logistic regression, and κ statistics were applied.

Results: Unilateral knee MRI scans obtained in 105 skiers (mean age, 14.8 years \pm 0.6 [standard deviation]; 66 boys) and in 105 control participants (mean age, 14.6 years \pm 0.5; 59 boys) were evaluated. DFCIs were found in 61 of 105 skiers (58%; 95% confidence interval [CI]: 48.5%, 67.2%) compared with 28 of 105 control participants (27%; 95% CI: 18.9%, 35.7%) ($P < .001$). Two skiers had more than one DFCI. Distribution of DFCIs for skiers and control participants was 60 of 63 (95.2%) and 26 of 28 (92.8%) at the MHG, three of 63 (4.8%) and one of 28 (3.6%) at the LHG, and zero of 63 (0%) and one of 28 (3.6%) at the adductor magnus attachment site, respectively. Interreader agreement was almost perfect ($\kappa = 0.87$; 95% CI: 0.80, 0.93). The mean size of MHG-related DFCIs in skiers (3.7 mm) was not different compared to the size of those in control participants (3.4 mm) ($P = .32$), nor was a difference found for the MHG tendon attachment position in knees with DFCI (63.9 mm vs 63.0 mm, $P = .83$) or without DFCI (63.6 mm vs 62.8 mm, $P = .86$). Regarding associated MRI findings, increased signal intensity of the MHG tendon showed a significant association with MHG-related DFCI in both groups ($P = .01$ for both).

Conclusion: A distal femoral cortical irregularity at the attachment sites of tendons was a frequent incidental finding on knee MRI scans, with an increased prevalence in youth competitive alpine skiers.

© RSNA, 2020

Online supplemental material is available for this article.

A cortical irregularity at the posterior aspect of the distal femoral metaphysis is a frequent and usually incidental finding at imaging of children and adolescents (1,2). With an increasing number of MRI examinations performed in young patients, it is likely that these changes will be detected even more frequently, as sensitivity of lesion detection is higher with MRI than with radiography (3). Several case reports have described the typical changes of these lesions in active adolescents, commonly without symptoms (4,5); however, the pathogenesis of this benign condition is debated.

The most common theory is that of a “tug lesion” as a result of repetitive mechanical stress at the tendinous attachment sites of skeletal muscle (1,6–9). Most of the lesions described in the literature are located at the posteromedial

distal femur at the attachment site of the medial head of the gastrocnemius muscle (MHG) or the aponeurosis of the adductor magnus muscle (6,7,10). Despite radiologic similarity and histologic identical appearance of lesions with or without relationship to an adjoining tendon (8,10), several names have been interchangeably used for its description, including distal femoral cortical irregularity (DFCI), cortical desmoid, periosteal desmoid, nonossifying fibroma, and avulsive cortical irregularity (6,8,10). We decided to use the term *DFCI* to describe alterations at the distal femur that are associated with the attachment of tendons.

To our knowledge, no study has investigated an association between mechanical stress to the knee joint and the occurrence of DFCIs. Therefore, we set out to investigate

Abbreviations

CI = confidence interval, DFCI = distal femoral cortical irregularity, LHG = lateral head of the gastrocnemius muscle, MHG = medial head of the gastrocnemius muscle

Summary

A distal femoral cortical irregularity at the attachment sites of tendons was a frequent incidental finding on knee MRI scans, with an increased prevalence in youth competitive alpine skiers; this finding should not be mistaken for malignancy.

Key Results

- A distal femoral cortical irregularity (DFCI) was more common in youth competitive alpine skiers (58%) compared with control participants (27%) ($P < .001$).
- DFCIs were observed at the attachment sites of tendons, predominantly at the medial head of the gastrocnemius muscle (MHG) in both skiers (95%) and control participants (93%).
- No difference was observed for the mean size of MHG-related DFCI in skiers (3.7 mm) versus control participants (3.4 mm) ($P = .32$).

the prevalence of DFCIs in a large homogeneous group of adolescent athletes with periodic high physical activity and loading patterns to the knee joint to better understand the pathogenesis of DFCI and to reduce uncertainty in correct diagnosis of this benign condition. Our hypothesis was that competitive skiers with unique motion patterns and skiing-specific loading exhibit more bony lesions at the femoral attachment sites of tendons.

The purpose of this study was to investigate the prevalence of DFCI at the femoral tendon attachment of the MHG and lateral head of the gastrocnemius muscle (LHG) and of the adductor magnus muscle in youth competitive alpine skiers compared with young adults of the same age.

Materials and Methods

This single-center secondary analysis of a prospective trial was approved by the cantonal ethics committee and was conducted according to the Declaration of Helsinki. Written informed consent was obtained from all participants or their parents or legal guardians.

Study Participants

As part of an observational sports medicine trial focused on injury prevention, youth competitive alpine skiers were prospectively included (Cantonal Ethics Committee Zurich registry number: KEK-ZH-2017-01395). For the prospective trial, skiers underwent MRI of the knee between November 2018 and February 2019. Inclusion criteria for skiers included boys and girls aged 13–16 years who were competitive athletes (part of a certified regional performance center of Swiss-Ski, more than five training units per week, >8 years of competitive sports participation). The exclusion criterion for the skiers was previous knee surgery.

For the control group, a search of the picture archiving and communication system and the hospital information system of Balgrist University Hospital was conducted to find patients who underwent knee MRI because of trauma, pain, patellofemoral

instability, or chronic pain between January 2014 and April 2019. Eligible patients were of the same age (± 1 year), resulting in 142 control participants (random series). The inclusion criterion for the control group was normal physical activity. Exclusion criteria for the control group were previous knee surgery and frequent participation in high-impact sports (more than three training units per week) or competitive athletics.

MRI Technique

All youth competitive alpine skiers were scanned with a 3-T MRI scanner (Magnetom Prisma; Siemens Healthineers, Erlangen, Germany) using a dedicated knee coil at the Swiss Center for Musculoskeletal Imaging. Knees were scanned with an unenhanced isotropic fat-suppressed T2-weighted three-dimensional sequence, or SPACE, with the following parameters: repetition time msec/echo time msec, 1000/108; slice thickness, 0.63 mm; field of view, 160×160 ; matrix, 256×256 ; receiver bandwidth, 415 Hz per pixel; parallel imaging acceleration factor, four; and duration, 4 minutes 42 seconds.

Control group participants were scanned per routine clinical protocol at Balgrist University Hospital with either a 3-T MRI scanner (Magnetom Skyra, Siemens Healthineers) or a 1.5-T MRI scanner (Magnetom Avanto, Siemens Healthineers) using a dedicated knee coil. Our standard unenhanced MRI protocol for examination of the knee includes a coronal T1-weighted turbo spin-echo sequence (1.5 T: 511/14; 3 T: 700/9.4) and coronal short inversion time inversion-recovery sequence (1.5 T: repetition time msec/echo time msec/inversion time msec, 4000/39/160; 3 T: 4200/34/210), a sagittal proton density-weighted turbo spin-echo sequence acquired in Dixon technique (1.5 T: 3080/27; 3 T: 3780/39) as well as an axial fat-suppressed proton density-weighted turbo spin-echo sequence (1.5 T: 3370/31; 3 T: 3900/40). Slice thickness was 3 mm for all sequences except the axial fat-suppressed proton-density-weighted turbo spin-echo sequence, which used a slice thickness of 2.5 mm.

MRI Analysis

MRI scans were interpreted independently by two musculoskeletal radiologists using a picture archiving and communication system workstation (C.S. and J.G., with 6 and 7 years of experience, respectively). Readers were blinded to clinical indication for the examination and to clinical and imaging results. Reader 1 (C.S.) first read the images of the control participants and then of the skiers, whereas reader 2 (J.G.) read the images in the opposite order. The interval between the readout of images from skiers and control participants was 2 months for both readers. Readers were blinded to each other's findings.

Cortical irregularity of the distal femur.—A distal femoral cortical irregularity was defined as a circumscribed, usually oval area of high signal intensity expanding into bone on fat-suppressed proton density- or T2-weighted MRI scans, usually with a thin dark rim at the periphery representing sclerosis (Fig 1) (1,2,6). The attachment site of the tendon of the MHG and LHG at the posteromedial and posterolateral aspect of

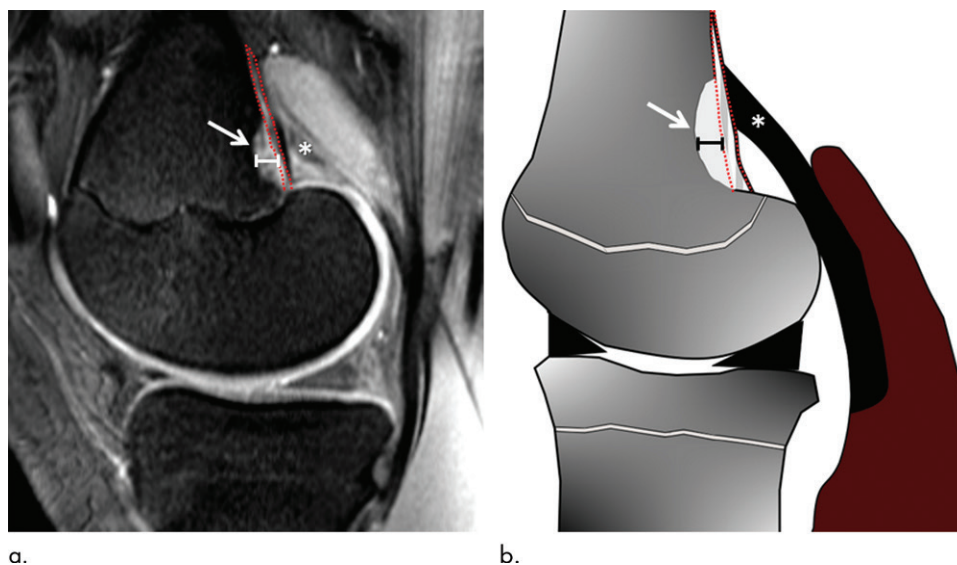


Figure 1: (a) Sagittal fat-suppressed proton density-weighted MRI scan in a 14-year-old male control participant with distal femoral cortical irregularity (DFCI) (arrow) at the level of the tendon attachment of the medial head of the gastrocnemius muscle (MHG) (*). (b) Sagittal illustration with DFCI (arrow) at the MHG attachment (*). The size of the DFCI is determined as the greatest anteroposterior diameter (solid line in a and b). Note that the bandlike hyperintense periosteal stratum osteogenicum (in between red dotted lines in a and b) is not included in the measurement.

the distal femur as well as of the adductor magnus tendon at the adductor tubercle were investigated for the presence of a DFCI in the sagittal and axial image planes. It is known that a thin bandlike hyperintensity is an expected finding at the enthesis due to a prominent periosteal stratum osteogenicum of the juvenile knee (11); therefore, only cortical irregularities exceeding 2 mm in anteroposterior diameter were included as DFCI in our analysis. DFCI size was measured on sagittal fat-suppressed proton density- or T2-weighted MRI scans as the greatest anteroposterior diameter of the cortical hyperintensity; for the measurement of DFCI size, any bandlike hyperintensity of the periosteal stratum osteogenicum was excluded, if present (Fig 1).

Location of tendon attachment of the MHG and LHG.—The proximal tendon attachment of the gastrocnemius muscle (MHG and LHG) was assessed on sagittal and axial images. Craniocaudal position was defined as the distance from the joint space to the most cranial attachment point of tendon slips (Fig 2) and was measured at sagittal MRI.

Associated articular and periarticular findings.—Knee MRI scans were investigated for the presence or absence of meniscal tear and degeneration; cartilage defects; bone marrow edema; anterior cruciate ligament, posterior cruciate ligament, and collateral ligament tear; joint effusion; and tendon changes (MHG, LHG, and adductor magnus).

Statistical Analysis

We used software (REDCap, version 9.3.4; Vanderbilt University, Nashville, Tenn) to enter, store, and manage data. For every study participant, an electronic case report form was generated for data entry. All results were reported for reader 1

in the results section, and the agreement between readers 1 and 2 was reported. The prevalence of DFCI at the different tendon attachment sites (MHG, LHG, and adductor magnus) was calculated in skiers and in the control group. The Pearson χ^2 test was used to compare groups. Interreader agreement was calculated using κ statistics, and agreement was interpreted as slight (κ , 0–0.20), fair (κ , 0.21–0.40), moderate (κ , 0.41–0.60), substantial (κ , 0.61–0.80), or almost perfect (κ , 0.81–1.00) (12). Descriptive statistics were used for the craniocaudal position of the tendon attachment of the MHG and LHG. The Student *t* test for independent samples was used for comparison of DFCI size and MHG tendon

attachment positioning measurements.

Furthermore, for both groups, a subanalysis was performed for the prevalence of MHG-related DFCI in regard to side of involvement and sex (cross tabulation and Pearson χ^2 test).

Associated MRI findings were investigated for a relationship with DFCI (binary logistic regression).

Data generated or analyzed during the study are available from the corresponding author by request.

Software (SPSS, version 23; IBM, Armonk, NY) was used for statistical analysis. A statistically significant difference was assumed for $P < .05$.

Results

Unilateral knee MRI scans in 108 youth competitive alpine skiers were included. Three skiers were excluded due to previous knee surgery, resulting in a study group of 105 participants (66 boys, 39 girls; mean age, 14.8 years \pm 0.6 [standard deviation]). Unilateral knee MRI scans in 142 control participants were included. Two participants were excluded because of previous knee surgery, and 35 were excluded because they were competitive athletes, leaving 105 control participants of the same age (59 boys, 46 girls; mean age, 14.6 years \pm 0.5). Figure 3 shows the eligibility criteria of the study participants and the control participants.

In total, 63 DFCIs were identified in 61 knees of 105 youth competitive alpine skiers (58%; 95% confidence interval [CI]: 48.5%, 67.2%) at the femoral tendon attachment sites (reader 1). Of the 63 DFCIs, 60 (95.2%; 95% CI: 87.8%, 98.6%) were located at the MHG attachment and three (4.8%; 95% CI: 1.4%, 12.2%) were located at the LHG attachment; no lesions were found at the adductor magnus attachment site. In two of the three knees with an LHG-related DFCI, an additional

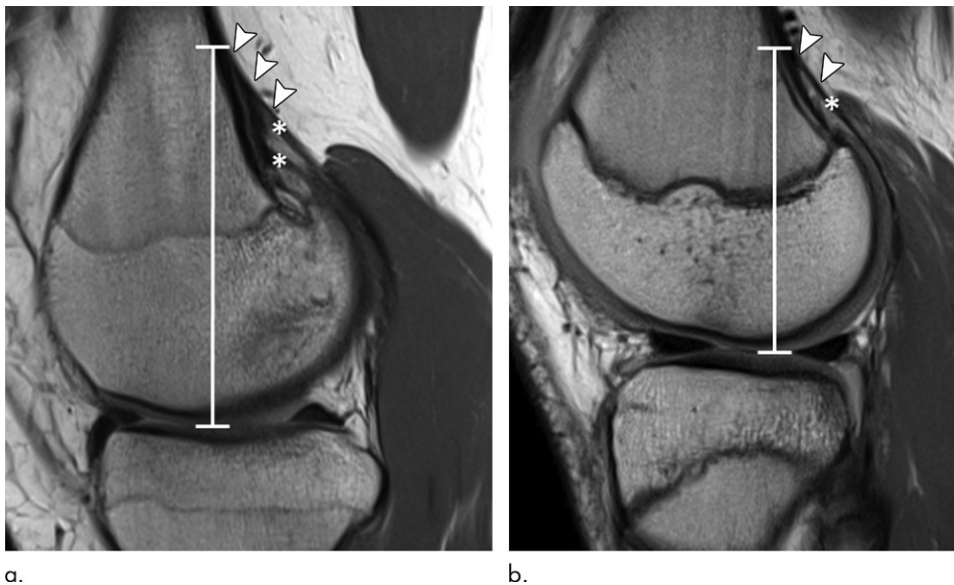

Figure 2: Sagittal proton density-weighted MRI scans in two 15-year-old female control participants without a distal femoral cortical irregularity demonstrate measurement of the tendon attachment position. Images show the craniocaudal position (white line) of the tendon attachment, which is defined as the distance from the level of the joint space to the most cranial attachment of tendon slips (arrowheads) for the (a) medial and (b) lateral head of the gastrocnemius muscle (*). Note that the tendon of the medial gastrocnemius head in a shows two prominent tendon slips.

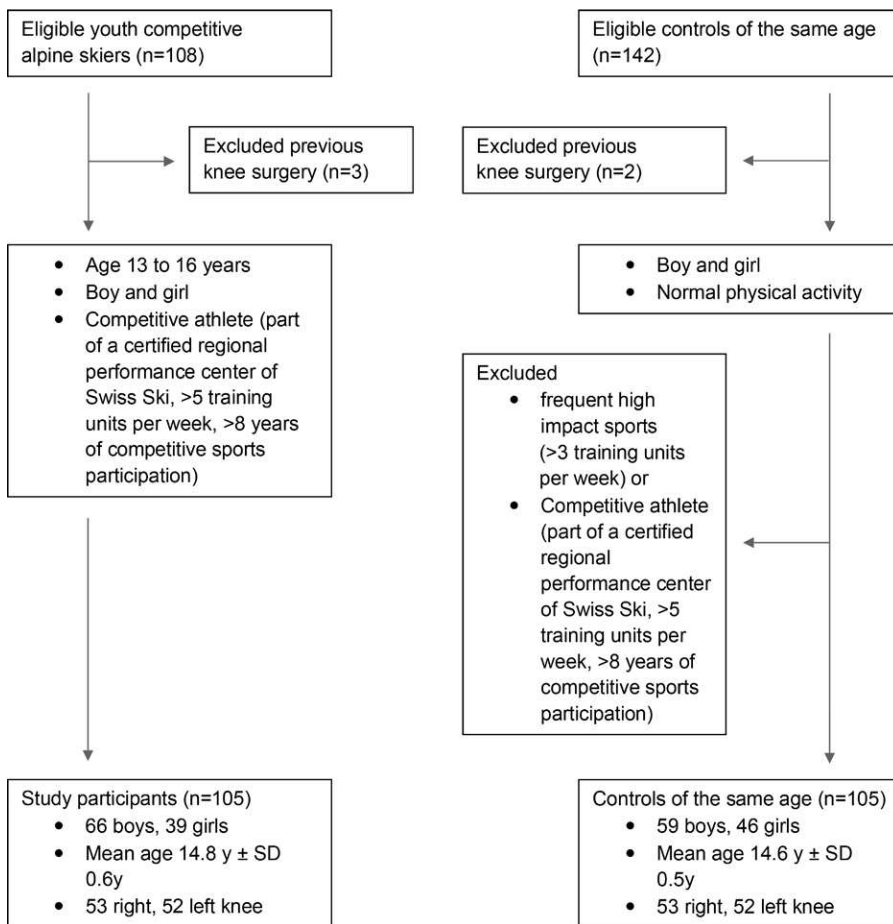


Figure 3: Flowchart shows eligibility criteria of study participants and control participants. SD = standard deviation.

DFCI at the MHG location was identified. Twenty-eight DFCIs were found in 28 knees among the 105 control participants (27%; 95% CI: 18.9%, 35.7%; $P < .001$). Twenty-six of the 28 DFCIs (92.8%; 95% CI: 79.0%, 98.5%) were located at the MHG, one (3.6%; 95% CI: 0.4%, 15.5%) was located at the LHG, and one (3.6%; 95% CI: 0.4%, 15.5%) was located at the adductor magnus attachment site (Figs 4–6). Table E1 (online) shows results of reader 2. Interreader agreement for DFCI detection was almost perfect for the two musculoskeletal radiologists ($\kappa = 0.87$; 95% CI: 0.80, 0.93).

As the number of DFCIs was too small at the LHG and adductor magnus insertion in both groups, no statistical analysis was possible for these locations. No difference was observed in the size of the MHG-related DFCIs in the youth competitive alpine skiers and the control group (mean, 3.7 mm vs 3.4 mm, respectively; $P = .32$). Table 1 shows the craniocaudal position of the tendon attachment of the MHG and LHG for skiers and the control group. For both groups, no difference was found regarding the craniocaudal position of the MHG tendon attachment in knees with DFCI (63.9 mm for skiers and 63.0 mm for control group) or without DFCI (63.6 mm for skiers and 62.8 mm for control group) ($P = .83$ and $P = .86$ for skiers and control group, respectively) (Table 2).

In youth competitive alpine skiers, subanalysis revealed more DFCIs at the MHG tendon attachment in the right knee (36 of 53 skiers [68%]; 95% CI: 54.7%, 79.3%) than in the left knee (24 of 52 skiers [46%]; 95% CI: 33.1%, 59.6%) ($P = .02$). The right leg was dominant in 94 of the 105 skiers (90%); however, the prevalence of MGH-related DFCI was not higher in the dominant leg (33 of 54 skiers [61%]; 95% CI: 47.8%, 73.3%) compared with the nondominant leg (27 of 51 skiers

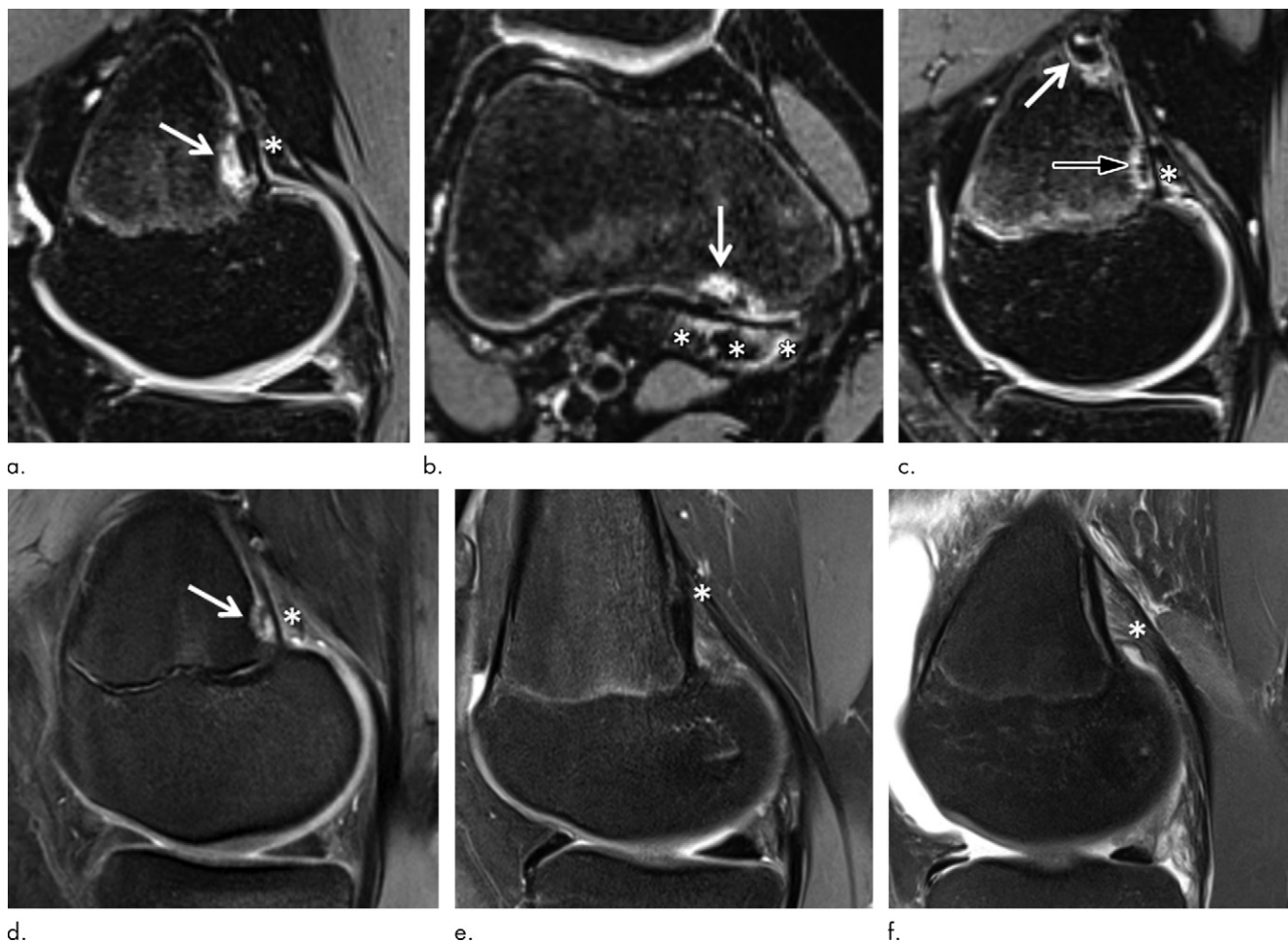


Figure 4: Images show examples of (a–d) distal femoral cortical irregularity (DFCI) at the tendon attachment of the medial head of the gastrocnemius muscle (MHG) and (e, f) knees without DFCI. (a, b) Sagittal (a) and axial (b) fat-suppressed T2-weighted MRI scans in 14-year-old female competitive skier show a 5-mm DFCI (arrow) at the distal MHG attachment (*). (c) Sagittal fat-suppressed T2-weighted MRI scan in another 14-year-old female competitive skier shows simultaneous DFCIs at the proximal (8 mm; white arrow) and distal (4 mm; black arrow) part of the MHG tendon attachment (*). (d) Sagittal fat-suppressed proton density-weighted MRI scan in 14-year-old female control participant shows a 4-mm DFCI (arrow) at the distal MHG attachment (*). (e, f) Sagittal fat-suppressed proton density-weighted MRI scans in 15-year-old female control participant (e) and 15-year-old male control participant (f) without a DFCI for comparison. The broad and fan-shaped appearance of the proximal MHG tendon (*) is especially well visualized in f because of edematous demarcation after knee trauma.

[53%]; 95% CI: 39.4%, 66.2%) ($P = .40$). For the control group, no difference in DFCI was observed between the right knee (12 of 53 control participants [23%]; 95% CI: 13.0%, 35.2%) and the left knee (14 of 52 control participants [27%]; 95% CI: 16.3%, 40.0%; $P = .61$) (Table 3). Furthermore, for skiers and control participants, occurrence of MHG-related DFCI was not different in boys (35 of 66 and 18 of 59, respectively; $P = .27$) and girls (25 of 39 and eight of 46, respectively; $P = .12$).

Associated intraarticular findings for skiers and control participants were as follows: one of 105 (1%) and 13 of 105 (12%), respectively, had medial meniscus tear, two of 105 (2%) and 17 of 105 (16%) had medial meniscus degeneration, two of 105 (2%) and seven of 105 (7%) had lateral meniscus tear, two of 105 (2%) and one of 105 (1%) had lateral meniscus degeneration, 10 of 105 (10%) and 28 of 105 (27%) had cartilage defects, 19 of 105 (18%) and 39 of 105 (37%) had bone marrow edema, and five of 105 (5%) and 24 of 105 (23%) had

joint effusion. In the control group, a tear of the anterior cruciate ligament was found in seven of the 105 participants (7%), and a tear of the medial collateral ligament was found in two (2%). However, no tears were found in skiers. No association was found for any intraarticular finding and DFCI in skiers ($P = .22$ to $P > .99$) and control participants ($P = .07$ to $P > .99$) (Table 4).

Regarding tendons, an increased signal intensity of the MHG tendon was observed in 40 of the 105 skiers (38%; 95% CI: 29.2%, 47.6%) and in 15 of the 105 control participants (14%; 95% CI: 8.6%, 21.9%) (Fig 7). For skiers and control participants, an increased tendon signal intensity was significantly associated with MHG-related DFCI ($P = .01$ for both), with an odds ratio of 3.7 (95% CI: 1.4, 9.3) in skiers and 5.6 (95% CI: 1.6, 19.6) in control participants. However, there was no significant association between cystic MHG tendon changes in skiers (seven of 105 [7%]; 95% CI: 3.0%, 12.6%) or control participants (three of 105 [3%]; 95%

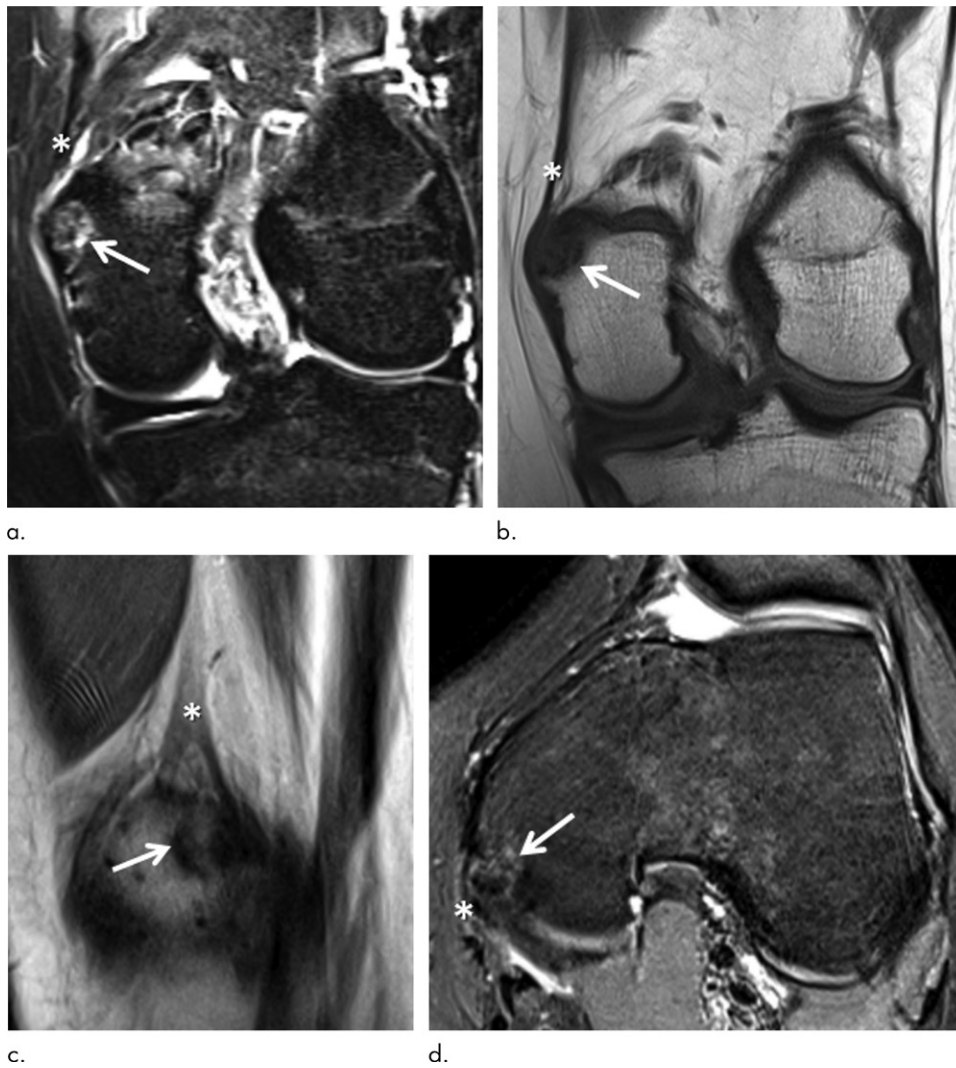


Figure 5: (a) Coronal short inversion time inversion-recovery, (b) coronal T1-weighted, (c) sagittal proton density-weighted, and (d) axial fat-suppressed proton density-weighted MRI scans in a 15-year-old female control participant show a distal femoral cortical irregularity (DFCI) (arrow) at the attachment of the adductor magnus tendon (*) at the adductor tubercle. The DFCI is 9 mm in diameter and shows a slightly expansive character.

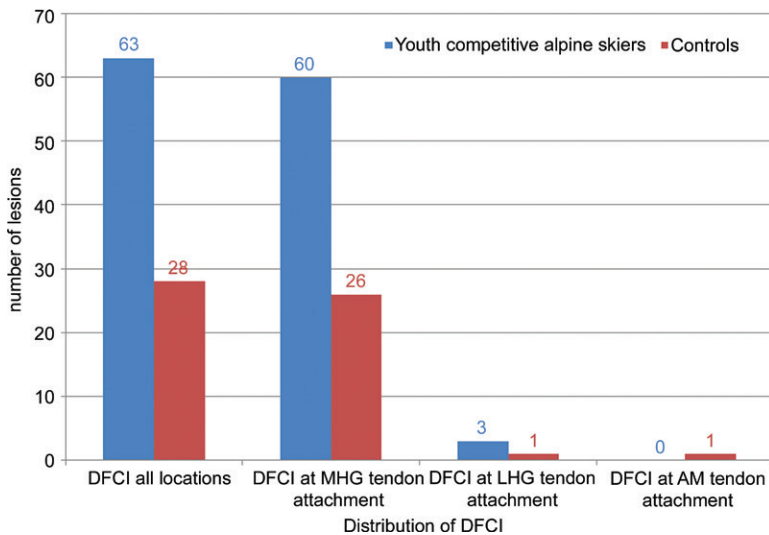


Figure 6: Bar chart shows distribution of distal femoral cortical irregularity (DFCI) in 105 youth competitive alpine skiers and 105 control participants. AM = adductor magnus, LHG = lateral head of the gastrocnemius muscle, MHG = medial head of the gastrocnemius muscle.

CI: 0.8%, 7.4%) (Fig 7) and MHG-related DFCI ($P = .81$ and $P = .45$). In skiers, no signal intensity or cystic change was observed for the LHG (0 of 105 participants) and adductor magnus (0 of 105 participants) tendon. In control participants, one of 105 LHG tendons (1.0%; 95% CI: 0.1%, 4.4%) and two of 105 adductor magnus tendons (2%; 95% CI: 0.4%, 6.0%) showed an increased signal intensity, but neither tendon showed any cystic changes.

Discussion

We compared a large homogeneous group of youth competitive alpine skiers with characteristic mechanical loading patterns of the knee to a heterogeneous group of young adults of the same age without high-impact physical activity.

Our results showed that DFCIs at the tendinous attachment sites were significantly more common in highly active youth competitive alpine skiers (61 of 105, 58%) ($P < .001$). The majority of DFCIs were associated with the MHG muscle for both skiers (95%) and the control group (93%). Regarding DFCI size, no difference was observed between skiers (mean,

3.7 mm) and control participants (mean, 3.4 mm) ($P = .32$). Furthermore, no association was found between the occurrence of a DFCI and the position of the MHG tendon attachment at the distal femur, nor were DFCIs correlated with associated intra-articular MRI findings.

The predominance of DFCI at the attachment of the MHG tendon in our study was in accordance with the literature. Suh et al (3) found all 58 distal femoral cortical irregularities at the MHG attachment, which could be well-distinguished from the adductor magnus attachment at the adductor tubercle farther medial. This distinction was also possible in our study, which revealed only a single adductor magnus-associated DFCI in the control group, and none in the skiers.

Goldin et al (10) evaluated 68 cortical lesions of the distal femur, of which 53.7% were located at the MHG attachment, 29.3% at the LHG

Table 1: Craniocaudal Position of the Attachment of the MHG and LHG Tendons

Group	Attachment Position of MHG Tendon (mm)	Attachment Position of LHG Tendon (mm)
Youth competitive alpine skiers (<i>n</i> = 105)	63.8 (50–78)	55.7 (46–74)
Control group (<i>n</i> = 105)	62.9 (52–75)	52.5 (42–66)

Note.—Data are means, with ranges in parentheses. Craniocaudal position of the MHG and LHG tendon attachment was measured relative to the level of the joint space. LHG = lateral head of the gastrocnemius muscle, MHG = medial head of the gastrocnemius muscle.

Table 2: Craniocaudal Position of the Attachment of the MHG Tendon in Individuals with and Individuals without DFCI

Individuals	Youth Competitive Alpine Skiers (<i>n</i> = 105)		Control Group (<i>n</i> = 105)	
	Attachment Position of MHG Tendon (mm)*	No. of Participants†	Attachment Position of MHG Tendon (mm)*	No. of Participants†
With MHG-associated DFCI	63.9	60 (57.1)	63.0	26 (24.7)
Without MHG-associated DFCI	63.6	45 (42.9)	62.8	79 (75.3)

Note.—Craniocaudal position of the MHG tendon attachment was measured relative to the level of the joint space. There was no difference for MHG tendon attachment position in knees with and knees without DFCI in skiers and the control group ($P = .83$ and $P = .86$, respectively). DFCI = distal femoral cortical irregularity, MHG = medial head of the gastrocnemius muscle.

* Data are means.

† Numbers in parentheses are percentages.

Table 3: Prevalence of DFCI at the Attachment of the MHG Tendon in Regard to Extremities

Group	Right Knee (<i>n</i> = 53)	Left Knee (<i>n</i> = 52)	<i>P</i> Value
Youth competitive alpine skiers (<i>n</i> = 105)	36 (67.9) [54.7, 79.3]	24 (46.2) [33.1, 59.6]	.02
Control group (<i>n</i> = 105)	12 (22.6) [13.0, 35.2]	14 (26.9) [16.3, 40.0]	.61

Note.—Data are numbers of participants, with percentages in parentheses and 95% confidence intervals in brackets. DFCI = distal femoral cortical irregularity, MHG = medial head of the gastrocnemius muscle.

Table 4: Associated Intraarticular MRI Findings

Finding	Youth Competitive Alpine Skiers (<i>n</i> = 105)			Control Group (<i>n</i> = 105)		
	Knee without DFCI (<i>n</i> = 44)	Knee with DFCI (<i>n</i> = 61)	<i>P</i> Value*	Knee without DFCI (<i>n</i> = 77)	Knee with DFCI (<i>n</i> = 28)	<i>P</i> Value*
Medial meniscus tear	0 (0)	1 (1.6)	>.99	8 (10.4)	5 (17.9)	.50
Medial meniscus degeneration	1 (2.3)	1 (1.6)	.82	10 (13)	7 (25)	.07
Lateral meniscus tear	2 (4.6)	0 (0)	>.99	6 (7.8)	1 (3.6)	.62
Lateral meniscus degeneration	2 (4.6)	0 (0)	>.99	0 (0)	1 (3.6)	>.99
Cartilage defect	6 (13.6)	4 (6.6)	.41	22 (28.6)	6 (21.4)	.45
Bone marrow edema	10 (22.7)	9 (14.8)	.22	30 (39)	9 (32.1)	.47
Joint effusion	3 (6.8)	2 (3.3)	.40	18 (23.4)	6 (21.4)	.69
Anterior cruciate ligament tear	0 (0)	0 (0)	NA	5 (6.5)	2 (7.2)	.59
Medial collateral ligament tear	0 (0)	0 (0)	NA	2 (2.6)	0 (0)	>.99
Posterior cruciate ligament tear	0 (0)	0 (0)	NA	0 (0)	0 (0)	NA
Lateral collateral ligament tear	0 (0)	0 (0)	NA	0 (0)	0 (0)	NA

Note.—Data are numbers of findings, with percentages in parentheses. DFCI = distal femoral cortical irregularity, NA = not applicable.

* *P* values calculated with binary logistic regression.

attachment, and 9.8% at the adductor magnus attachment site. However, three of the lesions did not show any relationship with tendinous structures.

In contrast, Muramatsu et al (13) found MHG-related DFCIs on only 5% of 197 knee radiographs while adductor magnus-associated DFCIs were observed on 15%. However,

detection of DFCI is less sensitive with radiography compared with MRI (3). Further, identifying the exact anatomic location is more difficult on radiographs than on MRI or CT scans, both of which provide tomographic visualization of tendon structures, thus making them a more reliable tool for detection and localization of DFCI.

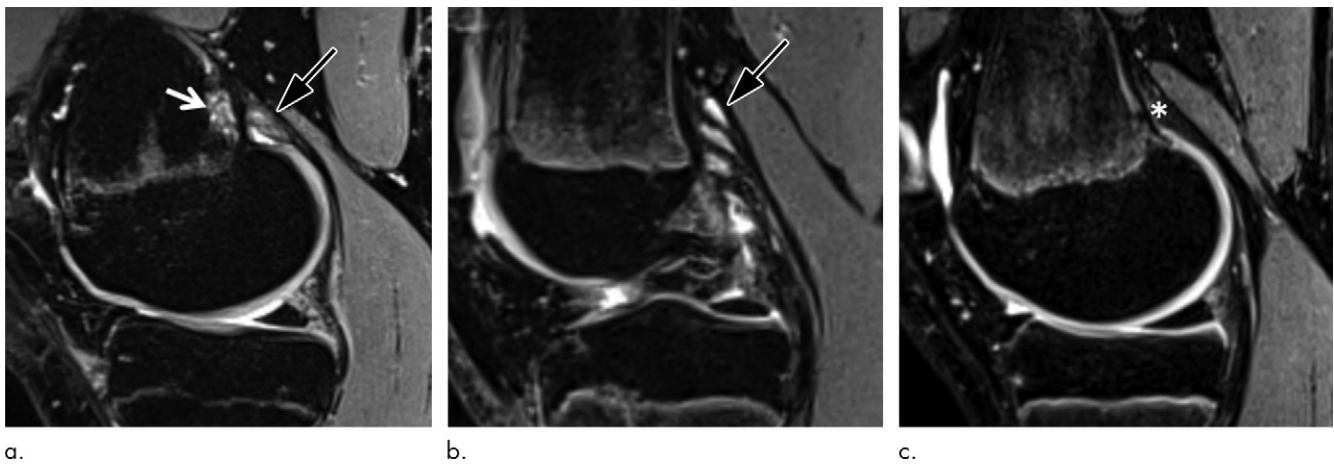


Figure 7: (a) Sagittal fat-suppressed T2-weighted MRI scan in a 14-year-old male competitive skier shows a distal femoral cortical irregularity (DFCI) (white arrow) at the level of the tendon attachment of the medial head of the gastrocnemius muscle (MHG), which shows increased signal intensity (black arrow). (b) Sagittal fat-suppressed T2-weighted MRI scan in 15-year-old male competitive skier with a small DFCI (not shown) and cystic changes of the proximal MHG tendon (arrow). (c) Sagittal fat-suppressed T2-weighted MRI scan in 15-year-old male competitive skier with no DFCI and no signal intensity or cystic changes of the MHG tendon (*) for comparison.

Our study results, which showed a higher prevalence of DFCIs in youth competitive alpine skiers, support the “tug lesion” theory of Ritschl et al (9) that DFCIs may originate as a result of repetitive stress at tendon attachments at the distal femur due to extensive mechanical load.

Competitive alpine skiing is a sport with unique motion patterns and equipment-induced limitations, most likely intensifying the injury-inducing distraction forces acting on the proximal compartments of the MHG muscle. Due to the use of forward-tilted skiing boots with high rear stiffness (14), competitive alpine skiers are permanently forced into ankle positions with extensive dorsiflexion (ie, substantially stretching the gastrocnemius muscles). In this pretension state, gastrocnemius muscles are then further eccentrically strained while damping low-frequency, skiing-induced vibrations and shocks (15) or by additional compression when bouncing against the stiff boot rear while skiing. As the ankles are tightly fixed by the boots and the knee of the outer leg is typically exposed to abduction with external rotation during a ski turn (16), it is likely that eccentric loads are primarily applied to the proximal tails and to the medial heads of the gastrocnemius muscles. Thus, the accumulation of such adverse loading patterns over time might serve as a potential explanation for the higher prevalence of DFCI in youth competitive alpine skiers than in control participants of the same age. Another explanation approach might be found in the off-snow conditioning characteristics of competitive alpine skiers, which often include large amounts of jump training (17).

DFCIs at the tendinous attachment sites of skeletal muscle should be regarded as “do not touch” lesions, as those benign alterations appear almost exclusively in children and adolescents and are usually asymptomatic (2,6). Several studies with histologic correlation from biopsy, curettage, or resected specimens have identified a reactive process with increased osteoclastic activity and proliferating fibrous and osteocartilaginous tissue, but no tumor cells have been found (2,6,8,13). As the histologic appearance of DFCIs is similar to a fibrous cortical defect or a nonossifying fibroma, debate surrounds whether those entities should be regarded the same (10). In accordance with Goldin

et al (10), we suggest avoiding the terms *cortical desmoid* or *periosteal desmoid*, as DFCI does not show features of a desmoid tumor (18,19). In contrast to their suggestion to use the terms *nonossifying fibroma* or *fibrous cortical defect*, we prefer the term *distal femoral cortical irregularity* to describe alterations at the distal femur associated with the attachment of tendons.

Due to the benign, usually asymptomatic, and, over time, self-limiting character of typical DFCIs at the attachment sites of tendons, invasive diagnostic procedures, such as biopsies, should be avoided. However, follow-up with MRI might be justified, especially in the rare case of a symptomatic presentation. In contrast, periosteal osteoblastoma, parosteal osteosarcoma, fibrosarcoma, or osteomyelitis must be ruled out, some of which require biopsy.

A prominent stratum osteogenicum of the periosteum (also known as posterior metaphyseal stripe) at the posterior distal femur is a frequently observed normal variant and should not be mistaken for a DFCI (8,11).

For cortical lesions associated with acute knee trauma, Vieira et al (8) observed additional signal intensity or cystic changes in the adjoining tendon. We also found signal intensity and cystic MHG tendon changes and a significant association for an increased signal intensity of the MHG tendon and MHG-related DFCI in skiers and control participants ($P = .01$ for both). However, DFCIs were not associated with any intraarticular structural damage. Still, skiers showed a high prevalence of cartilage defects (10%) and bone marrow edema (18%). These findings were less common than in control participants (27% and 37%, respectively). Control participants also had a substantially higher prevalence of meniscal tears, joint effusion, and anterior cruciate ligament and medial collateral ligament tears, which to some extent can be explained because of trauma history.

The limitations of our study were the retrospective design of the control group and the use of different MRI protocols for the skier group and the control group. This occurred because the group of 105 skiers was part of a larger sports medicine trial with a focus on injury prevention that did not employ the clinical standard sequences at Balgrist University Hospital. However, as

both MRI protocols included high-quality sequences, the MRI data for both groups are suitable for accurate depiction of the DFCI and tendinous attachments (20,21). Furthermore, control participants were scanned with a 1.5-T or 3-T MRI scanner. However, the protocols for the 1.5-T magnet were optimized to be equivalent to a 3-T magnet in diagnostic performance.

In summary, a distal femoral cortical irregularity at the femoral tendon attachment sites is a frequent incidental finding at MRI, with a significantly increased prevalence in youth competitive alpine skiers, supporting the theory of a mechanical stress-related and most likely loading-specific origin. These irregularities should be regarded as “do not touch” lesions and should not be mistaken for malignancy.

Acknowledgment: We thank the Swiss Center for Musculoskeletal Imaging, Balgrist Campus AG, Zurich, Switzerland, for conducting the 3-T MRI knee examinations of the youth competitive alpine skiers.

Author contributions: Guarantors of integrity of entire study, C.S., R.S.; study concepts/study design or data acquisition or data analysis/interpretation, all authors; manuscript drafting or manuscript revision for important intellectual content, all authors; approval of final version of submitted manuscript, all authors; agrees to ensure any questions related to the work are appropriately resolved, all authors; literature research, C.S., J.G., S.E., L.P., J.S.; clinical studies, C.S., J.G.; experimental studies, J.S.; statistical analysis, C.S., L.P., J.S.; and manuscript editing, C.S., J.G., L.P., J.S., R.S.

Disclosures of Conflicts of Interest: C.S. Activities related to the present article: institution received grant funding from the Balgrist Foundation and other organizations. Activities not related to the present article: disclosed no relevant relationships. Other relationships: disclosed no relevant relationships. J.G. disclosed no relevant relationships. S.F. disclosed no relevant relationships. L.P. disclosed no relevant relationships. J.S. Activities related to the present article: institution received grant funding from the Balgrist Foundation and other organizations. Activities not related to the present article: disclosed no relevant relationships. Other relationships: disclosed no relevant relationships. R.S. Activities related to the present article: institution received grant funding from the Balgrist Foundation and other organizations. Activities not related to the present article: disclosed no relevant relationships. Other relationships: disclosed no relevant relationships.

References

- Mellado JM, Ramos A, Salvadó E, Camins A, Calmet J, Saurí A. Avulsion fractures and chronic avulsion injuries of the knee: role of MR imaging. *Eur Radiol* 2002;12(10):2463–2473.
- Yamazaki T, Maruoka S, Takahashi S, et al. MR findings of avulsive cortical irregularity of the distal femur. *Skeletal Radiol* 1995;24(1):43–46.
- Suh JS, Cho JH, Shin KH, et al. MR appearance of distal femoral cortical irregularity (cortical desmoid). *J Comput Assist Tomogr* 1996;20(2):328–332.
- Kirkpatrick JA, Wilkinson RH. Case report 52. *Skeletal Radiol* 1978;2(3):189–190.
- Tscholl PM, Biedert RM, Gal I. Cortical desmoids in adolescent top-level athletes. *Acta Radiol Open* 2015;4(5):2058460115580878.
- Kontogeorgakos VA, Xenakis T, Papachristou D, et al. Cortical desmoid and the four clinical scenarios. *Arch Orthop Trauma Surg* 2009;129(6):779–785.
- Resnick D, Greenway G. Distal femoral cortical defects, irregularities, and excavations. *Radiology* 1982;143(2):345–354.
- Vieira RL, Bencardino JT, Rosenberg ZS, Nomikos G. MRI features of cortical desmoid in acute knee trauma. *AJR Am J Roentgenol* 2011;196(2):424–428.
- Ritschl P, Karmel F, Hajek P. Fibrous metaphyseal defects—determination of their origin and natural history using a radiomorphological study. *Skeletal Radiol* 1988;17(1):8–15.
- Goldin A, Muzykewicz DA, Dwek J, Mubarak SJ. The aetiology of the non-ossifying fibroma of the distal femur and its relationship to the surrounding soft tissues. *J Child Orthop* 2017;11(5):373–379.
- Laor T, Chun GF, Dardzinski BJ, Bean JA, Witte DP. Posterior distal femoral and proximal tibial metaphyseal stripes at MR imaging in children and young adults. *Radiology* 2002;224(3):669–674.
- Kundel HL, Polansky M. Measurement of observer agreement. *Radiology* 2003;228(2):303–308.
- Muramatsu K, Tominaga Y, Hashimoto T, Taguchi T. Distal Femoral Cortical Irregularity in children. *Acta Orthop Belg* 2015;81(3):392–397.
- Senner V, Michel FI, Lehner S, Brügger O. Technical possibilities for optimising the ski-binding-boot functional unit to reduce knee injuries in recreational alpine skiing. *Sports Eng* 2013;16(4):211–228.
- Spörri J, Kröll J, Fasel B, Aminian K, Müller E. The Use of Body Worn Sensors for Detecting the Vibrations Acting on the Lower Back in Alpine Ski Racing. *Front Physiol* 2017;8:522.
- Yoneyama K, Okamoto S. Joint motion and reacting forces in the carving ski turn compared with the conventional ski turn. *Sports Eng* 2000;3(3):161–176.
- Gilgien M, Reid R, Raschner C, Supej M, Holmberg HC. The Training of Olympic Alpine Ski Racers. *Front Physiol* 2018;9:1772.
- Lee JC, Thomas JM, Phillips S, Fisher C, Moskovic E. Aggressive fibromatosis: MRI features with pathologic correlation. *AJR Am J Roentgenol* 2006;186(1):247–254.
- Shinagare AB, Ramaiya NH, Jagannathan JP, et al. A to Z of desmoid tumors. *AJR Am J Roentgenol* 2011;197(6):W1008–W1014.
- Fritz J, Fritz B, Thawait GG, Meyer H, Gilson WD, Raithel E. Three-Dimensional CAIPIRINHA SPACE TSE for 5-Minute High-Resolution MRI of the Knee. *Invest Radiol* 2016;51(10):609–617.
- Fritz J, Ahlawat S, Fritz B, et al. 10-Min 3D Turbo Spin Echo MRI of the Knee in Children: Arthroscopy-Validated Accuracy for the Diagnosis of Internal Derangement. *J Magn Reson Imaging* 2019;49(7):e139–e151.