



**University of
Zurich**^{UZH}

**Zurich Open Repository and
Archive**

University of Zurich
Main Library
Strickhofstrasse 39
CH-8057 Zurich
www.zora.uzh.ch

Year: 2020

SARS-CoV-2 and Norovirus Co-Infection after Lung Transplantation

Steinack, Carolin ; Hage, René ; Benden, Christian ; Schuurmans, Macé M

Abstract: Coronavirus disease 2019 (COVID-19) is caused by severe acute respiratory syndrome coronavirus 2 (SARS-CoV-2), which is spreading as a pandemic in 2020. Few reports on infections in thoracic transplantation have been published so far. We present a case of COVID-19 in a 55-year old female lung transplant recipient infected 5 months posttransplant, who additionally was co-infected with a Norovirus. Respiratory and gastrointestinal symptoms were observed without need of therapeutic escalation except for antibiotic therapy. We observed a moderate disease evolution likely due to triple immunosuppression.

DOI: <https://doi.org/10.3390/transplantology1010002>

Posted at the Zurich Open Repository and Archive, University of Zurich

ZORA URL: <https://doi.org/10.5167/uzh-195028>

Journal Article

Published Version



The following work is licensed under a Creative Commons: Attribution 4.0 International (CC BY 4.0) License.

Originally published at:

Steinack, Carolin; Hage, René; Benden, Christian; Schuurmans, Macé M (2020). SARS-CoV-2 and Norovirus Co-Infection after Lung Transplantation. *Transplantology*, 1(1):16-23.

DOI: <https://doi.org/10.3390/transplantology1010002>



Case Report

SARS-CoV-2 and Norovirus Co-Infection after Lung Transplantation

Carolin Steinack^{1,2,*} , René Hage^{1,2} , Christian Benden^{2,3}  and Macé M. Schuurmans^{1,2} 

¹ Division of Pulmonology, University Hospital Zurich, Raemistrasse 100, 8091 Zurich, Switzerland; rene.hage@usz.ch (R.H.); mace.schuurmans@usz.ch (M.M.S.)

² Faculty of Medicine, University of Zurich, Raemistrasse 71, 8006 Zurich, Switzerland; christian_benden@yahoo.de

³ Swisstransplant, Effingerstrasse 1, Postfach, 3011 Bern, Switzerland

* Correspondence: carolin.steinack@usz.ch

Received: 5 May 2020; Accepted: 27 May 2020; Published: 29 May 2020



Abstract: Coronavirus disease 2019 (COVID-19) is caused by severe acute respiratory syndrome coronavirus 2 (SARS-CoV-2), which is spreading as a pandemic in 2020. Few reports on infections in thoracic transplantation have been published so far. We present a case of COVID-19 in a 55-year old female lung transplant recipient infected 5 months posttransplant, who additionally was co-infected with a Norovirus. Respiratory and gastrointestinal symptoms were observed without need of therapeutic escalation except for antibiotic therapy. We observed a moderate disease evolution likely due to triple immunosuppression.

Keywords: Lung Transplantation; COVID-19; SARS-CoV-2; Coronavirus; norovirus

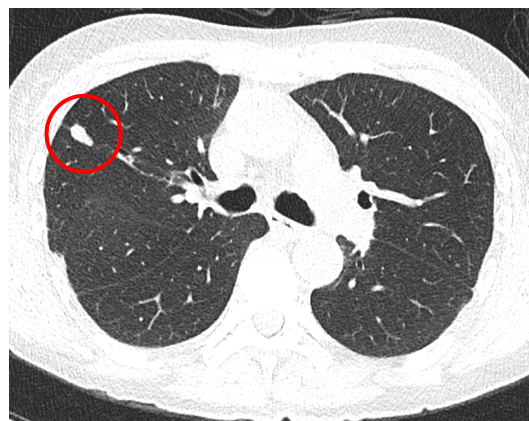
1. Introduction

In late 2019, a novel coronavirus, caused by severe acute respiratory syndrome coronavirus-2 (SARS-CoV-2) emerged from Wuhan, China [1]. This virus leads to the coronavirus disease 2019 (COVID-19), currently causing a pandemic with worldwide severe economic and healthcare consequences [2]. Among the most dominant clinical characteristics are fever, cough and fatigue, whereas gastrointestinal symptoms are rather uncommon. Critical disease conditions may be caused by severe and sustained systemic inflammatory responses (hyperinflammation or “cytokine storm”) and a cytopathic effect, leading to acute respiratory distress syndrome (ARDS), septic shock, metabolic acidosis that is hard to correct, coagulation dysfunction and multiple organ failure. The exact viral host factors that influence the pathogenesis are still being investigated. The SARS-CoV-2 infection binds to human host cell receptors, using human angiotensin-converting enzyme 2 (hACE2), although there are more factors influencing susceptibility to infection and disease progression. Elderly people (>65 years of age) with underlying diseases such as hypertension, chronic obstructive pulmonary disease (COPD), diabetes and cardiovascular disease seem more susceptible to an infection and prone to serious outcomes of this viral disease [3]. Since the spread of SARS-CoV-2 around the world, there have only been a few case reports describing COVID-19 in patients after solid organ transplantation (SOT).

We present a case of COVID-19 in a lung transplant (LTX) recipient presenting with fever and gastrointestinal symptoms in our emergency department.

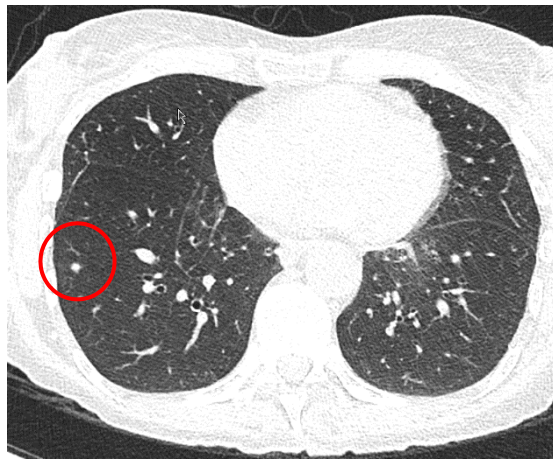
2. Case Report

A 55-year-old female with advanced chronic obstructive pulmonary disease (COPD) underwent a successful bilateral LTX 5 months earlier. Induction therapy (basiliximab) was used, and the patient was started on a standard immunosuppressive regime (cyclosporine—C2 target level 1200–1500 µg/L after 48 h), 1.0 g bid mycophenolate mofetil, and i.v. methylprednisolone according to our standard protocol. In March 2020 she presented with vomiting, diarrhea and a 38.9 °C fever in our emergency department. In the recent months and weeks, she had an uneventful post-transplant course except for a switch from cyclosporine to tacrolimus because of strongly variable trough levels. A recent surveillance bronchoscopy showed no evidence of acute cellular rejection and a stable allograft function with an FEV1 of 104% predicted based on standard triple immunosuppressive therapy (tacrolimus, mycophenolate and prednisolone). At the time of presentation, she had a new onset of mild respiratory symptoms consisting of a dry cough and rhinorrhea. Due to the fever, respiratory symptoms and ongoing SARS-CoV-2 pandemic, diagnostic sampling included blood, feces, and urine and a nasal swab for SARS-CoV-2. The nasopharyngeal swab for SARS-CoV-2 was positive, prompting hospitalization on a special isolation ward. Feces were positive for norovirus after having been negative 2 months earlier. The stool specimen tested negative for SARS-CoV-2. The serological antibody test for SARS-CoV-2 IgG und IgM was negative 14 days after the positive nasopharyngeal swab test. The main results at presentation included CRP 77 mg/L, leukocytosis (9.9 g/L), neutrophilia (8.96 g/L) and a marked declining lymphocytopenia (0.52 g/L, previously 1.3 g/L). The arterial blood gas analysis was within normal limits, thus no oxygen supplementation was given initially. Initial serum interleukin (IL-)6 was slightly elevated 4.5 pg/mL (Ref < 3.1) and decreased subsequently. Soluble IL-2-receptor (sIL-2R) was 394 pg/mL (Ref < 477) at presentation, increased up to 2778 on day 6 and decreased to normal levels (327) on day 15. IgG was in the lower normal range with 7.1 g/L (7–16). Five days after admission, CRP dropped to 5.7 mg/L (Ref < 5 mg/L). Bronchoalveolar lavage was not performed due to the favorable clinical evolution and the lack of respiratory deterioration. Chest computed tomography (CT) imaging revealed, at initial presentation, three small new solid nodular consolidations without predominant ground-glass opacities or pleural effusions (Figure 1a–c). These findings had not been observed 3 months earlier in a routine CT examination. The consolidations diminished over time and some of them disappeared completely in a follow up chest CT 6 weeks later (Figure 1d–f).

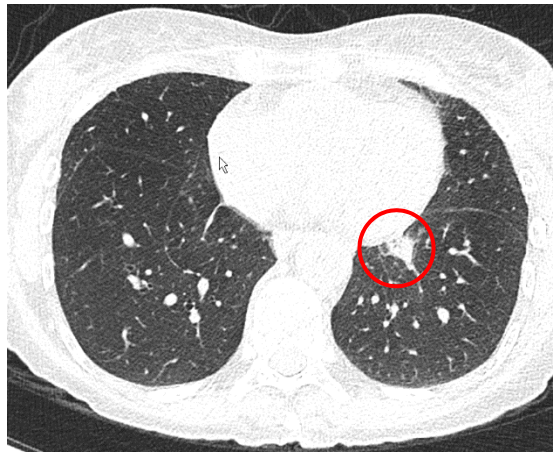


(a)

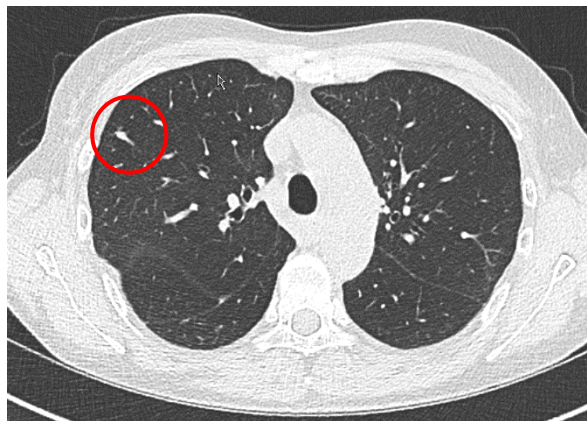Figure 1. Cont.



(b)

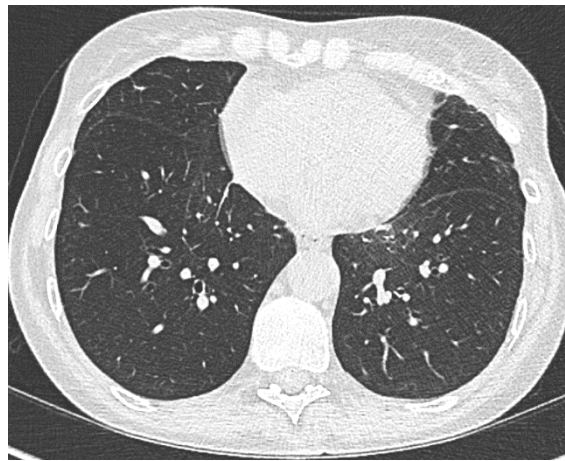


(c)

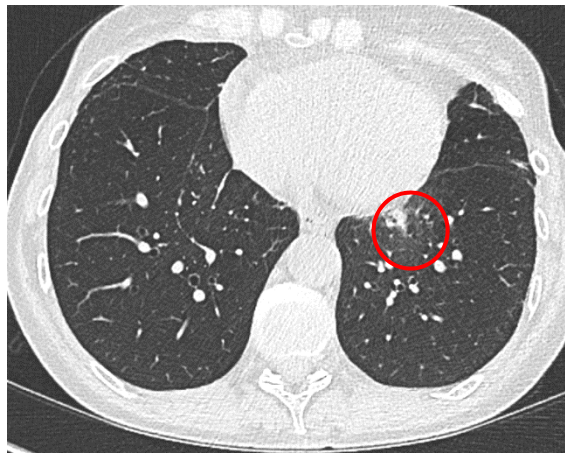


(d)

Figure 1. Cont.



(e)



(f)

Figure 1. (a–c) new pulmonary consolidations in the chest computed tomography (CT) on March 18th that were not visible in a chest CT 3 months before. (d–f): All of the consolidations resolved partially or completely in the follow-up chest CT 6 weeks later.

The patient was treated empirically with intravenous piperacillin/tazobactam 4.5 g every 8 h for 10 days. We administered neither lopinavir/ritonavir nor hydroxychloroquine, the drug regimen for COVID-19 used predominantly in China and Italy at that time and also the drug regimen for severe cases at our hospital then. This treatment was withheld due to the fairly stable condition of the patient without signs of respiratory deterioration in the first hours of hospitalization and due to concerns about potential drug interactions in this LTX recipient. The clinical evolution was favorable, with the normalization of temperature, stool frequency and no further vomiting. The dry cough and rhinorrhea were resolved within a week. Spirometry remained stable throughout. After three consecutive negative nasal and pharyngeal swabs for SARS-CoV-2, the patient was discharged on day 12 and quarantined at home, with additional empiric amoxicillin/clavulanic acid for 7 days. Lung function continues with steadily increasing allograft function with an FEV1 of 113% predicted on day 201 posttransplant.

3. Discussion

We observed a SARS-CoV-2 infection presenting with fever, respiratory and gastrointestinal symptoms in a severely immunosuppressed LTX recipient with good evolution during hospitalization on intravenous empiric antibiotics. We did not administer the drug regimen for COVID-19 recommended

at that time, which included lopinavir/ritonavir and hydroxychloroquine due to potential drug–drug interactions and absence of deterioration during hospitalization and also because of emerging evidence of the antiviral combination lacking therapeutic benefits [4]. The special features of this SARS-CoV-2 infection in this LTX recipient were: (1) predominant gastrointestinal symptoms at presentation with a diagnosis of norovirus co-infection and fairly mild respiratory symptoms, despite some new and atypical findings on chest imaging that showed regression in the follow-up chest CT 6 weeks later, (2) a moderately elevated pro-inflammatory response (no “cytokine storm” or hyperinflammation) during early infection, probably blunted by immunosuppression, and (3) a delayed increase in sIL-2R, which normalized after admission.

We assume the positive outcome in this case was due to profound immunosuppression, probably because this averted most inflammatory responses, with an initially reduced cytokine storm and a lack of progression of pulmonary infiltrates, both of which are typically observed in SARS-CoV infection of immunocompetent patients [5,6]. The inflammatory immune reaction was limited to a mildly increased IL-6 at presentation and a sIL-2R peak after 1 week, which returned to reference values one week later. The observed inflammation markers were only slightly raised when compared to the reported cytokine data in immunocompetent COVID-19 patients. This modified inflammatory response correlates with the mild clinical course, since cytokines like IL-6 and sIL-2R are described as useful markers to estimate the severity of COVID-19 [7]. The pathogenetical role of IL-6 in COVID-19 manifestations is still not fully understood and there is currently a lack of evidence of the beneficial therapeutic impact of IL-6 inhibitors. The current multicenter randomized controlled trial of tocilizumab (IL-6 receptor blockade, licensed for cytokine release syndrome) in patients with severe pneumonia due to SARS-CoV-2 and elevated IL-6 may shed more light on this topic. The N-protein of SARS-CoV seems responsible for the cytokine dysbalance and for the inflammatory-mediated acute lung injury [8]. The lower inflammatory response relies on glucocorticoids mitigating the N-protein of SARS-CoV-2-induced pulmonary inflammation and modulating the involved cytokines. In the future, the harm and benefit of corticosteroid treatment needs to be carefully considered in patients after SOT with SARS-CoV-2 infection. In immunocompetent patients, the routine administration of high doses of corticosteroids are currently discussed controversially due to concerns that steroids might even exacerbate lung injury by facilitating viral replication in patients with SARS-CoV-2-associated lung injury [9], as previously shown in influenza pneumonia [10]. Another therapeutic approach supports immunosuppressive therapy by aiming to reduce hyperinflammation in particular by using the mechanisms of action observed for tacrolimus in similar settings. It targets the inhibition of viral replication and, accordingly, leads to a reduction of virus titer [11,12]. Anti-inflammatory and anti-cytokine drugs seem to be a promising therapeutic approach in controlling viral damage, assuming that SARS-CoV-2 invades endothelial cells and induces endothelial inflammation, resulting in microvascular dysfunction with a subsequent pro-coagulant state and ischemia in essential organs like the heart, lung, kidney, liver and intestine, which also explains the worse clinical outcome of patients with pre-existing cardiovascular disease [13]. In LTX recipients, respiratory viral infections have been shown to play a major role in acute and chronic allograft dysfunction. Higher sIL-2R levels released from activated B-cells and monocytes have been found in patients suffering from neoplastic, infectious and autoimmune diseases, but also in SOT recipients affected by allograft rejection [14]. Although these results are suggestive of imminent allograft dysfunction in our patient, the most recent results from the follow-up visit 6 weeks after hospital discharge demonstrated a continuously increasing lung function and the chest CT scan showed no evidence of chronic allograft dysfunction, as judged by the lack of detection of air trapping in expiration images. Of course, a longer follow-up of the patient is needed to allow for a final assessment of this aspect, since the onset of complications may be delayed by months. This case of COVID-19 has an atypical pulmonary presentation in the initial chest CT, showing three small nodular consolidations without predominant ground-glass opacities, which is in contrast to the already published cases in the literature (Figure 1a–c). We attribute this to the suppressed immune system and the thereby modified or reduced cytokine storm, which might explain the mild clinical course of the disease, as mentioned

above. The follow-up chest CT showed diminished or completely dissolved consolidations as a sign of recovery from the modified pulmonary involvement of COVID-19 (Figure 1d–f).

In order to understand the disease evolution and to choose the optimal time point in the disease course for initializing therapy, COVID-19 illness was classified recently into Stages I–III, representing increasing grades of severity [15]. Our patient would be placed between early infection (Stage I: mild symptoms, lymphocytopenia, dry cough and diarrhea) and the beginning of the pulmonary phase (Stage II A: abnormal chest imaging).

Viral diseases can have atypical presentations, as has been observed for the different clinical manifestations of SARS-CoV-2 infection and COVID-19 [2,16,17]. SOT recipients should therefore remain cautious avoiding infection [6,18]. Due to atypical presentations, an infection with SARS-CoV-2 may also lead to delay in diagnosis if there is not a high index of suspicion initially for SARS-CoV-2. A kidney transplant recipient, initially suffering from gastrointestinal symptoms, but then developing respiratory symptoms within 48 h, has recently been described [18].

An important feature was the clinical presentation with vomiting, diarrhea and fever up to 38.9 °C. Fever and diarrhea seem to be common initial symptoms in SOT, which has also been reported in SOT recipients under immunosuppressive therapy [19–21]. Until today, SARS-CoV-2-infected patients after SOT are scarce compared to the worldwide incidence of COVID-19 [22–25]. We suspect an underestimated number of SARS-CoV-2 infections in SOT due to atypical clinical presentations thus often not qualifying the patient for SARS-CoV-2 testing in many centers. Moreover, the prudent behavior of LTX recipients and other SOT recipients due to the fear of infectious disease may also explain the low number of COVID-19 cases among these patients.

The stool specimen of our patient was positive for norovirus. Norovirus might increase gastrointestinal wall permeability, resulting in diarrhea and leading to a secondary SARS-CoV-2 infection by fecal–oral transmission [26]. However, this hypothesis cannot be proven, especially since diarrhea is a common manifestation of COVID-19 in immunocompetent and solid organ transplant recipients. Based on the current knowledge we cannot determine the route of infection of this patient since no index patient could be found, and because the patient presented with both gastrointestinal and respiratory symptoms.

4. Conclusions

We describe a fairly mild COVID-19 case in a severely immunosuppressed LTX recipient with good evolution on empiric intravenous antibiotics only. Immunosuppressive therapy might have averted the cytokine storm and the progression of pulmonary disease typically observed in some SARS-CoV-2 infections of immunocompetent patients. Diarrhea is described as a common symptom, even as an isolated manifestation in COVID-19. We assume that immunosuppression may modify the clinical presentation of COVID-19 after SOT. Immunosuppression, in particular tacrolimus, may avert the strong immunological reactions and therefore prevent some of the sequelae of SARS-CoV-2. For this reason, typical respiratory symptoms consisting of a cough and shortness of breath may not always be observed in these patients, thus creating new challenges for infection control and preventing the spread of the disease. This is the beginning of a new infectious era, leading to a global health crisis wherein potential harms need to be anticipated as soon as possible. The increasing SARS-CoV-2 transmission and resultant emerging pandemic are still beyond human control because of the altered biologic characteristics that provide SARS-CoV-2 its virulence and thus this virus poses a real challenge for future drug development. Physicians treating COVID-19 should be encouraged to include their patients in randomized controlled trials in order to gain the clinical evidence so urgently needed in the care of patients suffering from severe COVID-19. Further studies are required to confirm the abovementioned hypothesis before immunosuppression may be safely proposed as a supportive treatment approach in immunocompetent and SOT recipients.

Author Contributions: All authors were equally involved in planning the study, collecting the information and drafting the manuscript and figures. All authors have read and agreed to the published version of the manuscript.

Funding: This research received no external funding.

Conflicts of Interest: The authors declare no conflict of interest.

Abbreviations

| | |
|------------|---|
| SARS-CoV-2 | Severe Acute Respiratory Syndrome Coronavirus 2 |
| COVID-19 | Coronavirus Disease 2019 |
| SOT | Solid Organ Transplantation |
| LTX | Lung Transplantation |
| COPD | Chronic Obstructive Pulmonary Disease |
| IL-6 | Interleukin 6 |
| sIL-2R | Soluble Interleukin 2-Receptor |
| CT | Computed Tomography |

References

1. Epidemiology, Genetic Recombination, and Pathogenesis of Coronaviruses. *Trends Microbiol.* **2016**, *24*, 490–502. Available online: [https://www.who.int/news-room/detail/30-01-2020-statement-on-the-second-meeting-of-the-international-health-regulations-\(2005\)-emergency-committee-regarding-the-outbreak-of-novel-coronavirus-\(2019-nCoV\)](https://www.who.int/news-room/detail/30-01-2020-statement-on-the-second-meeting-of-the-international-health-regulations-(2005)-emergency-committee-regarding-the-outbreak-of-novel-coronavirus-(2019-nCoV)) (accessed on 14 March 2020). [CrossRef] [PubMed]
2. Huang, T.; Yq, W.; Liang, Y.; Tb, H. 2019 novel coronavirus patients' clinical characteristics, discharge rate and fatality rate of meta-analysis. *J. Med. Virol.* **2020**. [CrossRef]
3. Zhou, F.; Yu, T.; Du, R.; Fan, G.; Liu, Y.; Liu, Z.; Xiang, J.; Wang, Y.; Song, B.; Gu, X.; et al. Clinical course and risk factors for mortality of adult inpatients with COVID-19 in Wuhan, China: A retrospective cohort study. *Lancet* **2020**, *395*, 1054–1062. [CrossRef]
4. Cao, B.; Wang, Y.; Wen, D.; Liu, W.; Wang, J.; Fan, G.; Ruan, L.; Song, B.; Cai, Y.; Wei, M.; et al. A Trial of Lopinavir-Ritonavir in Adults Hospitalized with Severe Covid-19. *N. Engl. J. Med.* **2020**. [CrossRef]
5. Aslam, S.; Mehra, M.R. COVID-19: Yet another coronavirus challenge in heart transplantation. *J. Heart Lung Transplant* **2020**. [CrossRef]
6. Li, F.; Cai, J.; Dong, N. First cases of COVID-19 from China. *J. Heart Lung Transplant.* **2020**. [CrossRef]
7. Russell, B.; Moss, C.; George, G.; Santaolalla, A.; Cope, A.; Papa, S.; Van Hemelrijck, M. Associations between immune-suppressive and stimulating drugs and novel COVID-19—a systematic review of current evidence. *Ecancelmedicalscience* **2020**, *14*, 1022. [CrossRef]
8. Hao, D.; He, L.X.; Qu, J.M.; Pan, J.; Hu, B.J.; Zhang, J.; Li, Z.Z. A study of pulmonary inflammatory reaction induced by N-protein of SARS-CoV in rat models and effects of glucocorticoids on it. *Zhonghua Nei Ke Za Zhi* **2005**, *44*, 890–893.
9. Russell, C.D.; Millar, J.E.; Baillie, J.K. Clinical evidence does not support corticosteroid treatment for 2019-nCoV lung injury. *Lancet* **2020**, *395*, 473–475. [CrossRef]
10. Ni, Y.N.; Chen, G.; Sun, J.; Liang, B.M.; Liang, Z.A. The effect of corticosteroids on mortality of patients with influenza pneumonia: A systematic review and meta-analysis. *Crit Care* **2019**, *23*, 99. [CrossRef]
11. Mehta, P.; McAuley, D.F.; Brown, M.; Sanchez, E.; Tattersall, R.S.; Manson, J.J. COVID-19: Consider cytokine storm syndromes and immunosuppression. *Lancet* **2020**, *395*, 1033–1034. [CrossRef]
12. Carbajo-Lozoya, J.; Müller, M.A.; Kallies, S.; Thiel, V.; Drosten, C.; von Brunn, A. Replication of human coronaviruses SARS-CoV, HCoV-NL63 and HCoV-229E is inhibited by the drug FK506. *Virus Res.* **2012**, *165*, 112–117. [CrossRef] [PubMed]
13. Varga, Z.; Flammer, A.J.; Steiger, P.; Haberecker, M.; Andermatt, R.; Zinkernagel, A.S.; Mehra, M.R.; Schuepbach, R.A.; Ruschitzka, F.; Moch, H. Endothelial cell infection and endotheliitis in COVID-19. *Lancet* **2020**. [CrossRef]
14. Caruso, C.; Candore, G.; Cigna, D.; Colucci, A.T.; Modica, M.A. Biological significance of soluble IL-2 receptor. *Mediat. Inflamm.* **1993**, *2*, 3–21. [CrossRef]
15. Siddiqi, H.K.; Mehra, M.R. COVID-19 Illness in Native and Immunosuppressed States: A Clinical-Therapeutic Staging Proposal. *JHLT* **2020**, in press. [CrossRef]

16. Dong, X.; Cao, Y.-Y.; Lu, X.-X.; Zhang, J.-J.; Du, H.; Yan, Y.-Q.; Akdis, C.A.; Gao, Y.-D. Eleven Faces of Coronavirus Disease 2019. *Allergy* **2020**. [[CrossRef](#)]
17. Yang, X.; Yu, Y.; Xu, J.; Shu, H.; Xia, J.; Liu, H.; Wu, Y.; Zhang, L.; Yu, Z.; Fang, M.; et al. Clinical course and outcomes of critically ill patients with SARS-CoV-2 pneumonia in Wuhan, China: A single-centered, retrospective, observational study. *Lancet Respir Med.* **2020**. [[CrossRef](#)]
18. Guillen, E.; Pineiro, G.J.; Revuelta, I.; Rodriguez, D.; Bodro, M.; Moreno, A.; Campistol, J.M.; Diekmann, F.; Ventura-Aguiar, P. Case report of COVID-19 in a kidney transplant recipient: Does immunosuppression alter the clinical presentation? *Am. J. Transplant.* **2020**. [[CrossRef](#)]
19. Akalin, E.; Azzi, Y.; Bartash, R.; Seethamraju, H.; Parides, M.; Hemmige, V.; Ross, M.; Forest, S.; Goldstein, Y.D.; Ajaimy, M.; et al. Covid-19 and Kidney Transplantation. *N. Engl. J. Med.* **2020**. [[CrossRef](#)]
20. Pereira, M.R.; Mohan, S.; Cohen, D.J.; Husain, S.A.; Dube, G.K.; Ratner, L.E.; Arcasoy, S.; Aversa, M.M.; Benvenuto, L.J.; Dadhania, D.M.; et al. COVID-19 in Solid Organ Transplant Recipients: Initial Report from the US Epicenter. *Am. J. Transplant.* **2020**. [[CrossRef](#)]
21. Fernández-Ruiz, M.; Andrés, A.; Loinaz, C.; Delgado, J.F.; López-Medrano, F.; Juan, R.S.; González, E.; Polanco, N.; Folgueira, M.D.; Lalueza, A.; et al. COVID-19 in solid organ transplant recipients: A single-center case series from Spain. *Am. J. Transplant.* **2020**. [[CrossRef](#)] [[PubMed](#)]
22. Bhoori, S.; Rossi, R.E.; Citterio, D.; Mazzaferro, V. COVID-19 in long-term liver transplant patients: Preliminary experience from an Italian transplant centre in Lombardy. *Lancet Gastroenterol. Hepatol.* **2020**. [[CrossRef](#)]
23. Fix, O.K.; Hameed, B.; Fontana, R.J.; Kwok, R.M.; McGuire, B.M.; Mulligan, D.C.; Pratt, D.S.; Russo, M.W.; Schilsky, M.L.; Verna, E.C.; et al. Clinical Best Practice Advice for Hepatology and Liver Transplant Providers During the COVID-19 Pandemic: AASLD Expert Panel Consensus Statement. *Hepatology* **2020**. [[CrossRef](#)]
24. Hage, R.; Steinack, C.; Benden, C.; Schuurmans, M.M. COVID-19 in Patients with Solid Organ Transplantation: A Systematic Review. *Transplantology* **2020**, *1*, 1–15. [[CrossRef](#)]
25. Huang, J.-F.; Zheng, K.I.; George, J.; Gao, H.-N.; Wei, R.-N.; Yan, H.-D.; Zheng, M.-H. Fatal Outcome in a Liver Transplant Recipient With COVID-19. *Am. J. Transplant.* **2020**. [[CrossRef](#)] [[PubMed](#)]
26. Gu, J.; Han, B.; Wang, J. COVID-19: Gastrointestinal manifestations and potential fecal-oral transmission. *Gastroenterology* **2020**. [[CrossRef](#)]



© 2020 by the authors. Licensee MDPI, Basel, Switzerland. This article is an open access article distributed under the terms and conditions of the Creative Commons Attribution (CC BY) license (<http://creativecommons.org/licenses/by/4.0/>).