

5-23-1986

Embryonic Development of the Chicken External Cloaca and Phallus

M. R. Bakst

U. S. Department of Agriculture

Follow this and additional works at: <https://digitalcommons.usu.edu/electron>



Part of the [Biology Commons](#)

Recommended Citation

Bakst, M. R. (1986) "Embryonic Development of the Chicken External Cloaca and Phallus," *Scanning Electron Microscopy*. Vol. 1986 : No. 2 , Article 35.

Available at: <https://digitalcommons.usu.edu/electron/vol1986/iss2/35>

This Article is brought to you for free and open access by the Western Dairy Center at DigitalCommons@USU. It has been accepted for inclusion in Scanning Electron Microscopy by an authorized administrator of DigitalCommons@USU. For more information, please contact digitalcommons@usu.edu.



EMBRYONIC DEVELOPMENT OF THE CHICKEN EXTERNAL CLOACA AND PHALLUS

M. R. Bakst

U.S. Department of Agriculture
Agricultural Research Service
Avian Physiology Laboratory
Beltsville, Maryland 20705
Phone: 301 344 2545

(Received for publication March 22, 1986; revised paper received May 23, 1986)

Abstract

The use of the scanning electron microscope has provided new detailed information about the embryonic development of the chicken external cloaca and phallus and has consequently clarified the origin of the differences between the anatomy of the chicken and turkey phallus. At Day 6 (of incubation), the genital (g.) tubercle is formed in the ventral aspect of the embryo between the caudal fold of the amnion and the tail bud. On the ventral surface of the tail bud are paired g. swellings which flank the g. tubercle. Originating at the midline between the g. swellings is the g. crest which is joined cranially to the g. tubercle and later in development forms the ventral floor of the proctodeum (the most caudal cloacal compartment). By Day 8 the base of the g. tubercle has expanded caudolaterally to merge with the craniolateral extensions of the g. swellings. The g. swellings have likewise merged medially thus completing a collar-like structure around the g. tubercle. By Day 16, the dorsal and ventral lips of the cloaca have differentiated from the collar-like structure and the rounded, apical region of the g. tubercle gives rise to the primitive phallus. Further development of the external cloaca and phallus is limited primarily to the rotation of the phallus toward the ventral floor of the proctodeum and the concurrent shortening (longitudinally) of the proctodeum. Additional differentiation of the phallus occurs after hatching.

Introduction

In the course of investigating the mechanisms of erection, ejaculation, and semen dilution in the chicken, it was found necessary to determine the embryonic origin of the structures in the cloaca which form the chicken *Phallus nonprotrudens* (phallus). Studies addressing this subject are limited to a few from light microscopists of the late nineteenth and early twentieth century. Romanoff (1960) summarized and modified observations from these authors and presented the most recent comprehensive account of the embryonic development of the avian cloaca.

Published studies describing the topographic events associated with the embryonic development of the external cloaca and phallus do not exist for the chicken. Furthermore, the observations included in this study do not always agree with corresponding observations presented by Romanoff (1960). The following study is a topographical assessment of the embryonic development of the chicken external cloaca and the phallus. In addition, observations from this study are compared to Romanoff's description of cloacal development in birds and to observations describing the embryonic development of the turkey external cloaca and phallus (Bakst and Cecil, 1986).

Materials and Methods

Mature broiler chickens were caged individually in an environmentally-controlled house and kept on a lighting schedule and diet necessary to maintain egg-production. Hens were artificially inseminated weekly and eggs were collected daily and stored in a cool-room. Eggs were placed in an incubator (Day 1) between 0830 and 0900 h twice a week. Starting at Day 5 of incubation and daily thereafter (unless otherwise noted) between 0830 and 0900 h, cloacae were excised and washed briefly in Hank's Balanced Salt Solution. Washed specimens were placed in 2% formaldehyde and 1% glutaraldehyde in 0.15 M cacodylate buffer (pH 7.2) and refrigerated for a minimum of two days. Embryos were sexed at the time of fixation by identifying the gonads located at the anterior end of the kidneys. (Days 5 through 7 could not be sexed.) To provide an unobstructed view of the cloacal region, the hindlimbs and tails were removed from embryos up to Day 8. Thereafter, isolated cloacae were either left intact, cut midsagittally, or the dorsal wall of the proctodeum (the most caudal compartment in the

KEY WORDS: Avian, Chicken, Cloaca, Phallus, Embryo, Sex Differentiation

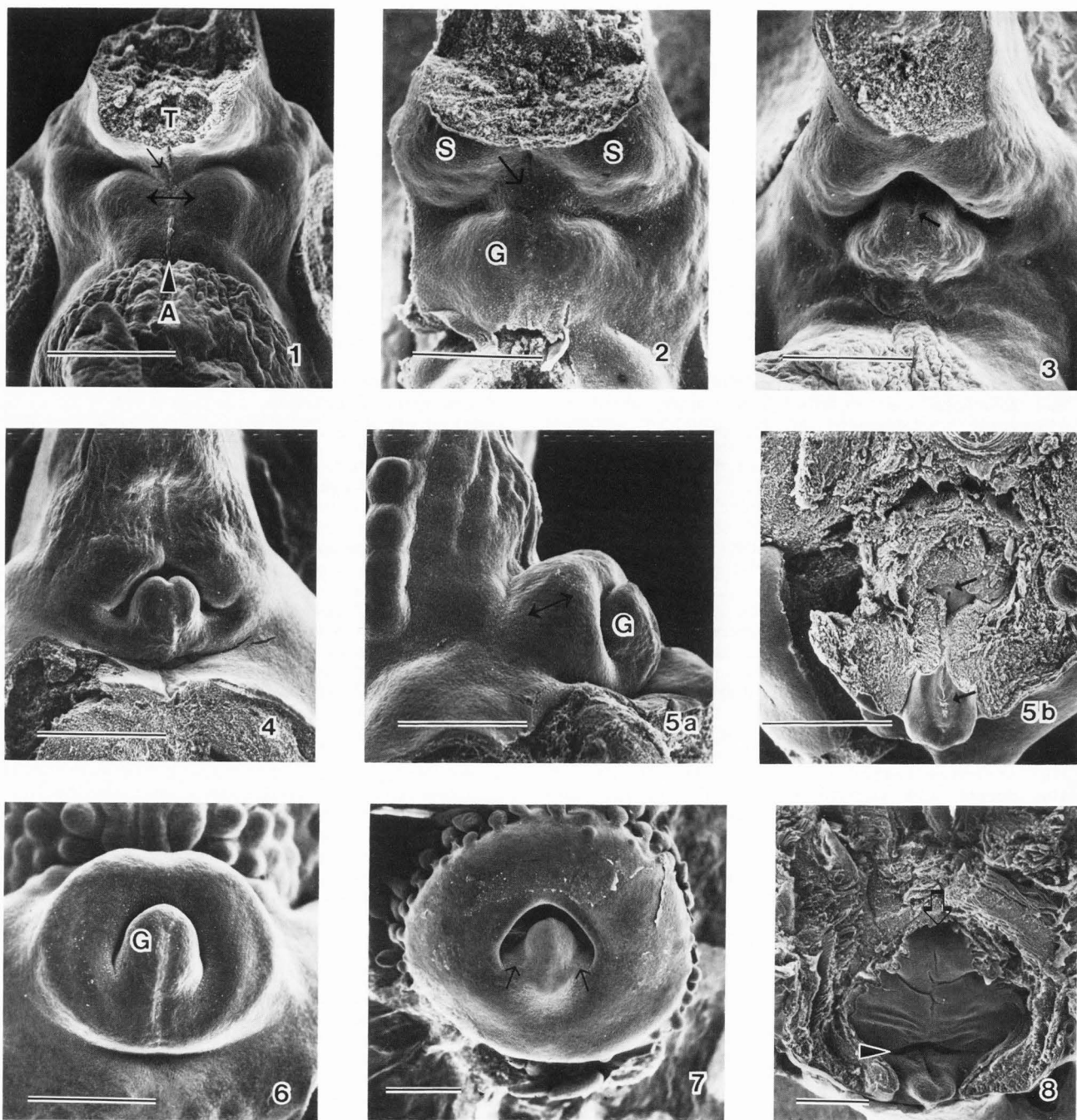


Figure 1. Day 5. Between the fractured tail bud (T) and the amnion (A) is the cloacal plate. This region is highlighted in its caudolateral aspect by two knob-like g. eminences (double-headed arrow) flanking the midline of the embryo. The g. crest (arrow) originates from the base of the tail bud and merges with the cloacal plate between the g. eminences. An epithelial tag (arrowhead) is in the midline of the cranial aspect of the cloacal plate.

Figure 2. Day 5.5. Joining the g. tubercle (G) to the tail bud is the g. crest (arrow). Here the g. crest is flanked by two swellings on the ventral aspect of the tail bud, the g. swellings (S). The Sulcus phalli is barely discernible in the midline of the caudal surface of the g. tubercle.

Figure 3. Day 6. On the caudal aspect of the g. tubercle, which now has a slightly rounded apical aspect, is the Sulcus phalli (arrow). The g. swellings overhang the g. tubercle giving the first indication of a proctodeal cavity.

Embryonic Chicken Cloaca

Figure 4. Day 7. The apex of the g. tubercle has a distinct, bud-like appearance. Its base has expanded laterally and merged with the craniolateral extensions of the g. swellings.

Figure 5. Day 8. This lateral view (Fig. 5a) of the cloaca shows the elevated nature of the collar surrounding the g. tubercle (G). If the dorsal aspect of this collar is removed at the plane indicated by the double-headed arrow in Fig. 5a, the Sulcus phalli (arrows) on the ventral floor of the proctodeum is revealed (Fig. 5b).

Figure 6. Day 9. The collar totally envelops the g. tubercle (G). From this view there is no indication of the bilateral origin of the collar.

Figure 7. Day 12. Slightly elevated regions (arrows) between the g. tubercle and the dorsolateral margins of the vent represent the primordia to the lateral phallic bodies. These primordia together with the g. tubercle constitutes the primitive phallus. The conical projections around the periphery of the cloaca develop into the feathers of the cloaca circlet feather tract.

Figure 8. Day 14. A deep transverse groove (arrowhead) separates the phallus from the ventral floor of the proctodeum. The latter has formed several transverse folds. The opening of the duct to the bursa (arrow) is located on the cranial surface of the proctodeum.

cloaca) was removed. All trimmed specimens were fixed again in 1% osmium tetroxide in 0.1 M cacodylate buffer (pH 7.2), dehydrated in ethanol, and critical-point dried. Specimens were attached to aluminum stubs with silver conducting paste and sputter coated with gold/palladium. Twelve or more specimens representing each day of incubation were examined. Analyses and photographic records were made with a Hitachi S-430 microscope operated at 15 kV.

Observations

Unless otherwise specified, all micrographs are of the ventral surface between the tail bud and the origin of the caudal fold of the amnion. In the four to five day embryo this region has been referred to as the anal plate, cloacal membrane, or cloacal plate (Romanoff, 1960; Bodemer, 1968; Patten and Carlson, 1974). The last name will be used here. Otherwise the nomenclature used in this study follows the recommendations presented in Nomina Anatomica Avium (Baumel, 1979). Micrographs are arranged with the tail bud oriented toward the top of the page. Magnification bars equal 500 micrometers.

Day 5. Flanking the midline of the embryo in the caudolateral aspect of the cloacal plate is a pair of knob-like genital (g.) eminences (Fig. 1). An elevated region, the g. crest, is in the midline and appears to originate from the base of the tail bud and merge cranially between the g. eminences. Also in the midline in the cranial aspect of the cloacal plate is an epithelial tag.

Day 5.5. The g. eminences merge at the midline and are more cranially displaced, forming a central prominence, the g. tubercle (Fig. 2). A slight depression (Sulcus phalli) forms on the caudal aspect

of the g. tubercle. The g. tubercle is joined to the tail bud by the g. crest. At the base of the tail bud and lateral to the g. crest are the paired g. swellings.

Day 6. The g. crest has merged completely with the g. tubercle. The apical aspect of the g. tubercle is rounded and more distinct from its base and only the Sulcus phalli gives an indication of the bilateral origin of this structure (Fig. 3). The g. swellings have become more voluminous and slightly overhang the g. tubercle, creating the first indication of a proctodeal cavity.

Day 7. The apex of the g. tubercle has a definitive, raised, bud-like appearance and is now clearly distinct from its base (Fig. 4). The apical diameter of the g. tubercle (about 350 μ m) does not change significantly during the remaining incubation period. The base of the g. tubercle has extended laterally and merged with the craniolateral extensions of the g. swellings, which have increased in volume.

Days 8-10. By Day 8, the g. swellings have become confluent both with each other dorsally and with the base of the g. tubercle craniolaterally thus forming an elevated, round, collar-like structure enveloping the g. tubercle (Figs. 5a, 5b, 6). With these events the most caudal compartment of the cloaca (and the only compartment of ectodermal origin), the proctodeum, is formed as is the external opening to the cloaca, the Ventus (vent). Removal of the dorsal aspect of this "collar" exposes the cranial face of the g. tubercle and the Sulcus phalli (Fig. 5b). The latter extends nearly the full length of the g. crest which now forms the ventral surface or floor of the proctodeum.

Days 11-14. By Day 11 the external cloaca has numerous conical elevations around its periphery which represent the first indication of the "cloaca circlet" (Knight, 1967) feather tract (Fig. 7). The base of the vent has widened and its dorsolateral margins are slightly angular, giving the vent a triangular appearance. The increased space between the g. tubercle and the dorsolateral margins of the vent appears to be due to a lateral extension of the basal region of the g. tubercle. This slightly elevated region constitutes the primordia of the Corpora laterale phallicum (lateral phallic bodies) and the Plicae lymphaticae (lymph folds). Together, the g. tubercle (now referred to as the Corpus phallicum medianum, medial phallic body) and the primordia of the lateral phallic bodies and lymph folds form the primitive Phallus nonprotrudens (phallus).

A deep transverse groove transects the ventral floor of the proctodeum partitioning the phallus from the remainder of the ventral floor of the proctodeum (Fig. 8). The Sulcus phalli is retained in the cranial aspect of the phallus. However, the Sulcus phalli is nearly lost in the more cranial region of the ventral floor of the proctodeum which has now formed several shallow transverse grooves. At the cranial juncture of the dorsal wall of the proctodeum and ventral floor of the proctodeum is the opening to the duct to the bursa of Fabricius.

Days 15-16. Starting at the periphery of the external cloaca are regularly spaced radial folds (Pars rugae) which extend toward but do not yet reach the vent (Fig. 9). The formation of the right and left commissures, which are only slight creases

on the lateral walls of the external cloaca on Day 15 and deep folds by Day 16, establish the division between the cloacal Labium venti dorsale (dorsal lip) and Labium venti ventrale (ventral lip). The folds and grooves on the ventral floor of the proctodeum progress gradually from a transverse orientation near the phallus to a longitudinal orientation at the opening of the duct to the bursa (Fig. 10).

A midsagittal view of the cloaca reveals that the proctodeum and urodeum (the central cloacal compartment of endodermal origin which receives the allantoic duct during embryonic development) remain separated by the ventral floor of the proctodeum which, shortly before hatching, becomes patent and then constitutes the Plica uroproctodealis (uroproctodeal fold) (Fig. 11). Similarly, the tissue separating the urodeum from the coprodeum (the most cranial cloacal compartment) becomes patent shortly before hatching and constitutes the Plica coprourodealis (coprourodeal fold). By Day 16, the external appearance of the embryonic cloaca resembles that of a chick which, in its resting state, consists of the smaller dorsal lip projecting slightly over the larger ventral lip, and all surfaces characterized by the conspicuous Pars rugae (Fig. 12).

The deep infolding at the commissures creates a concealed region of the cloacal lips, the Pars plana, which lacks the radial furrows and is relatively smooth. The Pars plana extends from the concealed folds of the commissures to the underside of the dorsal lip (Fig. 11).

Days 17-20. Continued invagination of the left and right commissures and the concurrent movement medially of the left and right inner lateral margins of the dorsal lip result in the phallus being rotated toward the ventral floor of the proctodeum (Figs. 13, 14). Completion of this internalization of the phallus is achieved when the inner lateral margins of the dorsal lip (Pars plana) are tightly apposed, masking the phallus.

Removal of the dorsal wall of the proctodeum only exposes a small portion of the ventral floor of the proctodeum and fails to expose fully the phallus (Fig. 13). Movement of the ventral floor of the proctodeum from a cranial-caudal to a dorsal-ventral orientation (compare Fig. 11 to Fig. 14) brings the opening to the bursa closer to the vent (Fig. 13).

A more complete exposure of the phallus is possible only by excising the ventral lip. Once enveloped by the Pars plana the medial phallic body loses its distinct knob-like appearance and is only discernible from the more lateral folds by its medial location (Fig. 15). The structures known to comprise the phallus in the mature male chicken could not be identified definitively, but a series of folds lateral to the medial phallic body probably represent the primitive lateral phallic bodies and lymph folds (Fig. 15).

Discussion

The observations presented here are somewhat different from those reported by Romanoff (1960). Romanoff observed two protuberances on the ventral

Figure Captions

Figure 9. Day 15. The external cloaca has formed radial folds (Pars rugae) around its periphery. Slight creases (the left and right commissures) (arrows) delineate the junction of the dorsal and ventral cloacal lips.

Figure 10. Day 15. The dorsal wall of the proctodeum has been removed at the level of the left and right commissures exposing the ventral floor of the proctodeum. Here the more cranial transverse folds assume an orientation which is nearly in line with the longitudinal orientation of the folds at the opening of the bursal duct (B). The Sulcus phalli remains distinct on the cranial aspect of the phallus (P). Between Days 17 and 20, the inner lateral margins of the dorsal lip (arrows) move medially and eventually become apposed, masking the phallus from the exterior.

Figure 11. Day 15. This is a midsagittal view of the three compartments of the cloaca and the folds separating each compartment. The phallus (P) is associated with the ventral lip and projects into the vent. If the plane of the dorsal wall of the proctodeum (double-headed arrow) is followed cranially it leads to the bursa of Fabricius (B). The ventral floor of the proctodeum, which shortly before hatching becomes patent and forms the uroproctodeal fold (UF), separates the proctodeum from the urodeum (U), the central cloacal compartment. A wall, which shortly before hatching becomes patent and forms the coprourodeal fold (CF), separates the urodeum which receives the allantoic duct (A), from the coprodeum (C) the most cranial cloacal compartment. The arrowhead indicates the Pars plana on the underside of the dorsal lip.

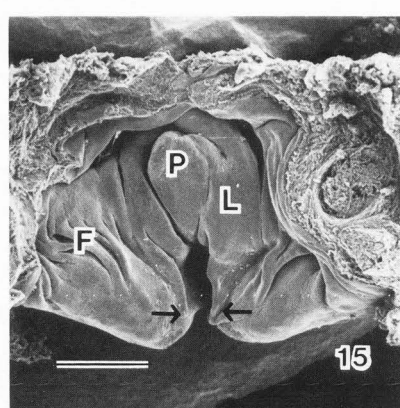
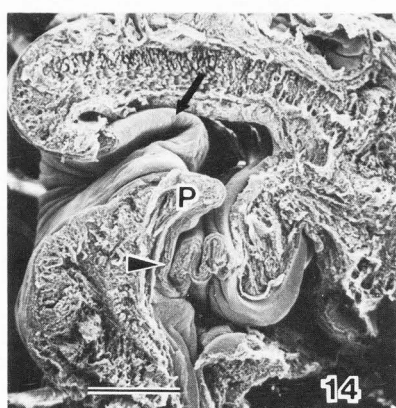
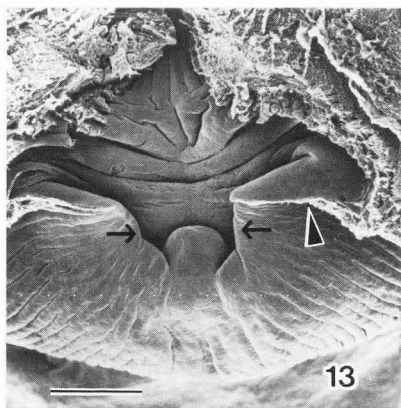
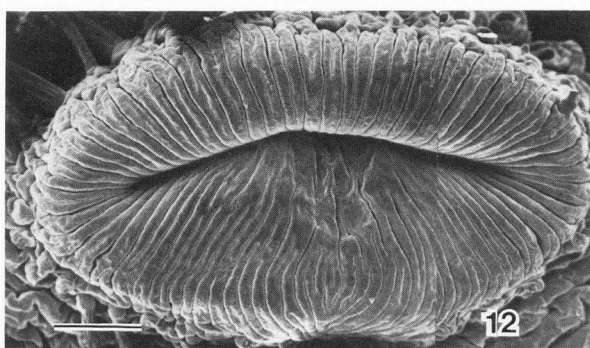
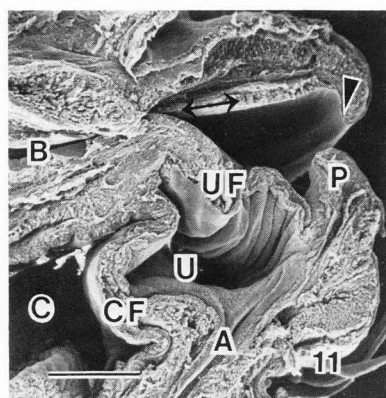
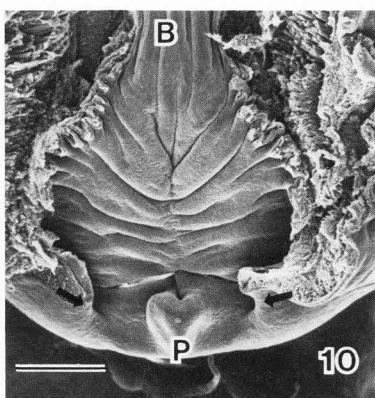
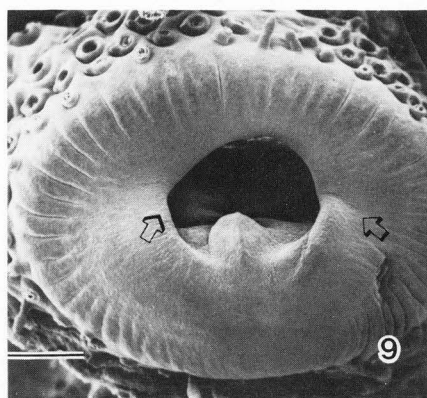
Figure 12. Day 16. The radially oriented Pars rugae are observed on both cloacal lips. The smaller dorsal lip projects slightly over the larger ventral lip giving the vent a slit-like appearance.

Figure 13. Day 17. The phallus is only visible when the dorsal lip and dorsal wall of the proctodeum are removed. The continued invagination of the commissures (arrowhead) and the movement medially of the inner aspects of the dorsal lip (arrows) have resulted in the phallus rotating toward the ventral floor of the proctodeum. Concurrent with this rotation is the shortening of the cranial-caudal extent of the ventral floor of the proctodeum (compare this figure with Fig. 10).

Figure 14. Day 17. This parasagittal view of the cloaca shows the deep invagination of the left commissure (arrow) and the Pars plana portion of the dorsal lip caudal to the phallus (P). The proctodeum appears to have increased depth, and the folds comprising the future uroproctodeal fold (arrowhead) are deeper than the corresponding folds observed on Day 15 (Fig. 11).

Figure 15. Day 18. The excised ventral lip has been positioned on its external aspect in order to view the phallus. The Pars plana portion of the inner margins of the dorsal lip are closely apposed (arrows) and caudal to the medial phallic body (P). Lateral to the medial phallic body are folds which probably represent the lateral phallic body (L) and lymph folds (F).

Embryonic Chicken Cloaca



body surface of the Day 5 chick embryo, the anterior and posterior anal lips, and noted (with no time reference) that they became confluent and formed the "circular anal papilla or genital tubercle." The increased resolution afforded by scanning electron microscopy shows that at Day 5 the ventral body surface in the region of the cloacal plate forms the g. eminences which by Day 6 have merged medially giving rise to the g. tubercle. By Day 8, the g. tubercle is enveloped by the primordium of the cloacal lips which arise dorsally from the g. swellings and ventrally from the lateral extensions of the base of the g. tubercle.

The development of the proctodeum and phallus in the chicken differs somewhat from that in the turkey (Bakst and Cecil, 1986). The major difference is that the Sulcus phalli on the cranial surface of

the turkey g. tubercle establishes a bilateral symmetry which persists both throughout the incubation period and post-hatch maturation. In the turkey, the g. tubercle gives rise to the prominent lateral phallic bodies and lymph folds. At no time in the pre- or post-hatch development of the turkey phallus is there any indication of a medial phallic body (King, 1981; Bakst and Cecil, 1983). In contrast, the chicken g. tubercle persists as the central medial phallic body with no definitive lateral phallic bodies or lymph folds formed during incubation. At maturity, the chicken phallus consists of the median phallic body, lateral phallic bodies, and the lymph folds, all of which are most conspicuous during tumescence (King, 1981).

The absence of a clear differentiation of the lateral phallic bodies and lymph folds during the

latter stages of embryonic development may be due to the lack of sufficient hormonal stimulation, presumably from one of the androgens. It has been noted that in chickens, the phallus atrophies following castration (Nishiyama, 1950) but parts of the phallus exhibit a positive growth response following androgen administration (Nishiyama, 1954). Another example of hormone-dependent differentiation of a cloacal structure is found in the Japanese quail. Secretion from the *glandula proctodealis dorsalis* (foam gland) is only found in sexually active males (McFarland et al., 1968).

Acknowledgements

I thank A. Kimrey, N. Chaney, and C. Pooley for their technical support.

References

- Bakst MR, Cecil HC. (1983). Gross appearance of turkey cloacae before and after single or multiple manual semen collections. *Poultry Sci.* 62, 683-689.
- Bakst MR, Cecil HC. (1986). Embryonic development of the turkey male genitalia. *Poultry Sci.* In press.
- Baumel JJ. (1979). *Nomina Anatomica Avium*. Academic Press, NY, 304-309.
- Bodemer CW. (1968). *Modern Embryology*. Holt, Rinehart, and Winston, Inc., NY, 268-270.
- King AS. (1981). Phallus. In: *Form and Function in Birds*, Vol. 2, Eds. King AS, McLelland J, Academic Press, NY, 107-147.
- Knight CE. (1967). Gross and microscopic anatomy of the structures involved in the production of seminal fluid in the chicken. Dissertation, Michigan State University, East Lansing.
- McFarland LZ, Warner RL, Wilson WO, Mather FB. (1968). The cloacal gland complex of the Japanese quail. *Experientia* 24, 941-943.
- Nishiyama H. (1950). Studies on the physiology of reproduction in the male fowl. I. On the accessory organs of the phallus. *Sci. Bull. Fac. Agric. Kyushu* 12, 27-36.
- Nishiyama H. (1954). Studies on the reproductive physiology of the cock. V. The influence of androgen on the accessory organs of the phallus. *The Department of Agriculture for Scotland, Proc. Xth World's Poultry Cong., Sect. A: 88-90.*
- Patten BM, Carlson BM. (1974). *Foundations of Embryology*. McGraw-Hill Book Company, NY, 512-521.
- Romanoff AL. (1960). *The Avian Embryo*. The Macmillan Company, NY, 497-507 and 839-841.

Discussion with Reviewers

W. P. Jollie: Is the proctodeum properly the caudal portion of the cloaca (which is the caudal portion of the hindgut) or is it not an ectodermal depression over the cloacal membrane (anal plate) and separated by this membrane from the cloaca proper? Do not most avian embryologists regard the coprodeum, not the proctodeum, as the terminal unoccluded segment of the hindgut (cloaca) after formation of the urodeum?

Author: King (1981, text reference, p. 63) defines the cloaca as "... a chamber which opens externally after receiving two or more organ systems, these

organ systems in vertebrates being the caudal end of the intestine and the urogenital ducts." In the context of the above definition a true cloaca is not seen in the chicken and turkey until shortly before hatching when the two walls separating the three cloacal compartments become patent. At that time a true cloaca is formed and the proctodeum is its most caudal compartment. There appears to be general agreement amongst avian embryologists that in the chicken at about 4 days of incubation the primitive cloaca is formed when the caudal portion of the hindgut (endoderm) dilates slightly and receives the mesonephric (Wolffian) ducts. The ectodermal depression formed about the same time as the primitive cloaca and separated from the latter by the cloacal membrane (anal plate) is (or will be) the primitive proctodeum. The coprodeum is derived, in part, from the terminal segment of the hindgut and, as can be seen in Fig. 11, is the terminal unoccluded segment of the hindgut until shortly before hatching.

F. C. Monson: In what way could others working with chicken and turkey embryos determine stages comparable to your days using standard developmental sequences as found in the literature? Author: Hamburger and Hamilton (J. Morphol. 88:49-92, 1951) noted the shortcomings of classifying the stage of embryo development on chronological age (i.e., the number of hours or days the egg has been incubated). Unfortunately all structures used by Hamburger and Hamilton to define the different phases of morphological development were discarded during tissue processing. However, future workers should be able to correlate Stages 34-36 (of Hamburger and Hamilton) with the appearance of the collar-like structure enveloping the genital tubercle (around Days 8-10) and Stages 42-43 with the formation and closure of the cloacal lips (around Days 16-17).

B. Howarth, Jr.: Is there anything comparable to genital folds in the embryonic development of the genitalia in the male chick? In the human embryo, the urethral groove and urogenital sinus is surrounded by the genital folds (also called urethral folds). The counterpart of the urethral groove in the chick embryo would appear to be the *Sulcus phalli* on the genital tubercle. If one looks at Figure 3, the folds on either side of the *Sulcus phalli* could be construed as representing genital folds.

Author: Morphologically the *Sulcus phalli* is flanked by a pair of folds which may be homologous to the genital folds observed in the early human embryos (see Fallon and Simandl, *Am. J. Anat.* 152: 111-130, 1978). However, developmentally and functionally the fate of the folds flanking the *Sulcus phalli* in the chicken and turkey embryo is considerably different from that of the genital folds of the human embryo. In the former they form the ventral floor of the proctodeum. In the human the genital folds eventually fuse ventrally over the urethral groove to establish the penile portion of the urethra.

C. E. Knight: Based on your findings, what do you think Romanoff (1960) was referring to when he described the presence of two protuberances on the

Embryonic Chicken Cloaca

ventral body surface of the 5 day chick embryo (p. 505)?

Author: The exact chronology of the appearance of the "...two protuberances [which] appear in succession on the ventral body surface, the first one anterior to the anal plate and the second one posterior to it," and Romanoff's subsequent descriptions of the development of the external genitalia is somewhat ambiguous. Since he refers to figures representing Days 5 and 6 of incubation, he possibly was referring to the genital tubercle and the genital swellings which, by Romanoff, represent the anterior and posterior anal lips.

C. E. Knight: When does the Sulcus phalli form in the turkey and how similar are the genital eminences of the turkey and chicken prior to the development of the Sulcus phalli?

Author: The Sulcus phalli forms in the midline of the turkey genital tubercle around Day 8 of incubation. We (Bakst and Cecil, 1986) have observed a single knob-like genital eminence in the midline cranial to the tail fold on Day 7 turkey embryos which had yet to form a Sulcus phalli. We have no information regarding earlier development of the turkey genital eminence.

C. E. Knight: Were the lymph folds found in the developing turkey embryo during pre-hatch development? Are these folds not also under hormonal control?

Author: The lymph folds (Plicae lymphaticae) of the turkey embryo appear as cranio-lateral extensions of the paired phallus (the Corpora phallica lateralia) on Day 17 of incubation (Bakst and Cecil, 1986). Together the phallus and lymph folds constitute the turkey's Phallus nonprotrudens. We did note that the Phallus nonprotrudens was slightly larger in the male than female embryos. This size difference, which is the criterion of sexing one day old poults, is probably androgen dependent. In mature turkeys the female Phallus nonprotrudens is poorly developed compared to the males' which would also indicate a role of the androgens in growth and differentiation of this organ.

