



THE AGA KHAN UNIVERSITY

eCommons@AKU

---

Medical College Documents

Medical College, Pakistan

---

3-1-2021

## COVID-19 and adult acute lymphoblastic leukemia: Presentation and management

Ayesha Butt

*Aga Khan University*, [ayesha.butt@scholar.aku.edu](mailto:ayesha.butt@scholar.aku.edu)

Natasha Bahadur Ali

*Aga Khan University*, [natasha.ali@aku.edu](mailto:natasha.ali@aku.edu)

Follow this and additional works at: [https://ecommons.aku.edu/pakistan\\_fhs\\_mc\\_mc](https://ecommons.aku.edu/pakistan_fhs_mc_mc)



Part of the [Hematology Commons](#), and the [Oncology Commons](#)

---

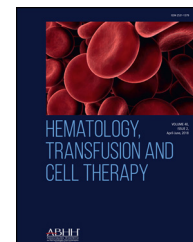
### Recommended Citation

Butt, A., Ali, N. B. (2021). COVID-19 and adult acute lymphoblastic leukemia: Presentation and management. *Hematology, Transfusion and Cell Therapy*.

Available at: [https://ecommons.aku.edu/pakistan\\_fhs\\_mc\\_mc/191](https://ecommons.aku.edu/pakistan_fhs_mc_mc/191)



## HEMATOLOGY, TRANSFUSION AND CELL THERAPY

[www.htct.com.br](http://www.htct.com.br)

## Case Report

# COVID-19 and adult acute lymphoblastic leukemia: Presentation and management

Ayesha Butt <sup>a,\*</sup>, Natasha Ali <sup>b</sup><sup>a</sup> Aga Khan University, Medical College, Karachi, Pakistan<sup>b</sup> Aga Khan University, Section of Hematology Oncology, Department of Oncology, Karachi, Pakistan

## ARTICLE INFO

## Article history:

Received 18 August 2020

Accepted 27 January 2021

Available online xxx

## Introduction

Infection with SARS-CoV-2, the cause of coronavirus infectious disease-19 (COVID-19), has caused a pandemic after first being reported in Wuhan, China in December 2019.<sup>1</sup> An over-representation of patients with cancer has been seen in the COVID-19 cohort in the Chinese National Database Repository.<sup>2</sup> Patients with cancer have been reported to have COVID-19-related case fatality rates of approximately 5–6%,<sup>1</sup> and a 3 to 5-fold higher risk of severe COVID-19, compared to the general population.<sup>2</sup> Moreover, patients with hematological malignancies and COVID-19 have been reported to have case fatality rates of up to 37%.<sup>3</sup> Another study delineated higher mortality in hospitalized patients with hematological cancers who developed COVID-19 than in hospitalized health-care providers with COVID-19.<sup>4</sup>

Severe and prolonged immunosuppression is a corollary of treatment for acute lymphocytic leukemia (ALL), which heightens the risk of complications associated with COVID-

19. Much remains to be known about incidence, management and outcomes of COVID-19 in patients with cancer in general, and leukemias in particular. We report on a case of a young adult male with T-ALL, who was receiving chemotherapy and developed COVID-19.

## Case report

A 24-year-old male, presented in August 2019 with dyspnea and loss of appetite during the previous 2 months. On examination, he was pale and had bilateral cervical and axillary lymphadenopathy along with splenomegaly. The complete blood count (CBC) showed hemoglobin at 2.8gm/dl, hematocrit at 8.8%, white blood cells (WBCs) at  $313.7 \times 10^9/L$  and platelets at  $166 \times 10^9/L$ . Subsequently, a bone marrow biopsy was performed, which was consistent with ALL. Immunophenotyping by flow cytometry was performed and the gated population showed reactivity with Pan-T-cell markers, i.e., CD7 and cCD3, along with CD45, terminal deoxynucleotidyl transferase (TdT) and CD34, with an aberrant expression of CD33. His conventional cytogenetic results were 46 XY chromosomes, while the BCR-ABL transcript (p210/p190) was not detected. Tumor lysis markers were within normal limits.

\* Corresponding author at: Medical College, Aga Khan University, Stadium Road, Karachi, Pakistan.

E-mail address: [ayeshabutt21@outlook.com](mailto:ayeshabutt21@outlook.com) (A. Butt).

<https://doi.org/10.1016/j.htct.2021.01.006>

2531-1379/© 2021 Associação Brasileira de Hematologia, Hemoterapia e Terapia Celular. Published by Elsevier Editora Ltda. This is an open access article under the CC BY-NC-ND license (<http://creativecommons.org/licenses/by-nc-nd/4.0/>).

The patient was diagnosed as T-ALL and was started on the Medical Research Council (MRC) UKALL XII protocol. On day 17 of his induction protocol, the patient developed fever with dyspnea. Baseline lab results were sent and the abnormal findings were the beta-d-glucan at  $>523.4$  pg/mL (negative  $<60$  ng/mL) and galactomannan at 8.06 (cutoff  $>0.7$ ). These findings, along with bilateral infiltrates in the chest X-ray were consistent with *Aspergillus* infection. The patient was intubated after 24 h due to worsening tachypnea and tachycardia. He was started on voriconazole 200 mg twice a day. After 48 h, his condition improved and he was shifted out of intensive care. Though he did not receive chemotherapy on day 28 due to complications, his bone marrow was in morphological remission and the minimal residual disease investigation showed less than 0.01% T-lymphoblasts.

The patient remained in regular follow-up by a specialist in infectious diseases, along with the hematology team, and re-started chemotherapy with induction phase 2. He then received intensification with high-dose methotrexate and cranial irradiation, followed by consolidation.

While he was receiving consolidation block 4 chemotherapy, he developed febrile neutropenia and was prescribed granulocyte-colony stimulating factor (G-CSF) 300 micrograms ( $\mu$ g) daily for 3 days at the hospital daycare unit. After receiving three doses in hospital daycare, he presented to the emergency department with complaints of abdominal pain, fever and cough for 3 days. On examination, he was febrile and tachycardic. Due to the emerging pandemic of COVID-19, a nasopharyngeal swab for SARS-CoV-2 by PCR was performed, which was reported as detected. His CBC showed hemoglobin at 10.2 gm/dl, hematocrit at 27.4%, WBCs at  $<0.5 \times 10^9/L$  and platelets at  $5 \times 10^9/L$ . For febrile neutropenia, he was started on broad-spectrum antibiotics and amphotericin and the G-CSF dosage was increased to 300  $\mu$ g twice daily. His procalcitonin was at 0.97 ng/mL (cut off  $<0.5$  ng/mL) and ferritin was 22,078 ng/mL (the normal range being 22–322 ng/mL). The blood chemistry was within normal limits, except for the serum potassium, which was at 3.1 mmol/L. He received platelet transfusions to maintain his platelet count above  $10 \times 10^9/L$ .

After 48 h, the patient responded to this treatment. He became afebrile, did not require mechanical ventilation and his CBC parameters improved. On the fourth day of his admission, his counts were as follows: hemoglobin at 11.1 gm/dl, hematocrit at 31.5%, WBCs at  $2.4 \times 10^9/L$ , absolute neutrophil count at 1310 and platelets at  $35 \times 10^9/L$ . His potassium level was at 2.7 mmol/L and he continued to receive potassium replacement. He was discharged in stable condition and advised to repeat the CBC and PCR for SARS-CoV-2.

A week later, on repeat testing, the PCR for COVID-19 was negative and the CBC showed hemoglobin at 10.9 gm/dl, hematocrit at 31.5%, WBCs at  $7.3 \times 10^9/L$  and platelets at  $94 \times 10^9/L$ , while the potassium level was at 3.5 mmol/L. He was afebrile and stable. All family members and hospital staff who had been exposed to this patient tested negative for COVID-19.

He received his next cycle of chemotherapy two months later. However, a week after receiving vincristine, he presented with right-sided weakness and headache. Magnetic Resonance Venography (MRV) and magnetic resonance imaging (MRI) showed extensive cerebral venous sinus thrombosis

and hemorrhagic venous infarct in left parietal lobe. The CBC at that time showed hemoglobin at 9.6 gm/dl, hematocrit at 28.8%, WBCs at  $4.2 \times 10^9/L$ , platelets at  $65 \times 10^9/L$  and blasts at 59%. The investigations were consistent with disease relapse (chronic neuroimmune disease (CND) and systemic). Thereafter, the patient opted for palliative care only.

A month later, he presented with complaints of sudden onset shortness of breath after blood product transfusion on the previous day, along with mild cough and hemoptysis. On arrival, he was in severe respiratory distress and his oxygen saturation was at 77%. He was managed using noninvasive ventilation (NIV), but his condition deteriorated rapidly and he developed bradycardia and later pulseless electrical activity (PEA). Advanced directives by the patient were do-not-resuscitate (DNR) and he expired thereafter.

## Discussion

Few cases of concomitant occurrence of ALL with COVID-19 have been reported so far and the course of the infection has been generally mild.<sup>5</sup> However, even in the midst of a deadly pandemic, ALL itself remains a huge threat to those that it afflicts, even when they are in remission, as was seen in our case.<sup>6</sup>

Zeidan et al. recently reported recommendations from a panel of international experts about the management of hematological malignancies in adults in the COVID-19 pandemic.<sup>7</sup> It was suggested to consider delaying treatment for ALL, given the risk of severe COVID-19 with chemotherapy.<sup>8</sup> Antitumor treatment  $<14$  days previously has been reported as a risk factor for severe COVID-19. All patients should be tested for SARS-CoV-2 before starting therapy and, in case of a positive test, treatment should be delayed by 10–14 days, except intrathecal therapies for central nervous system (CNS) symptoms. Similar recommendations were put forward by the French Society for the Fight against Cancers and Leukemias in Children and Adolescents (SFCE).<sup>6</sup>

In the situation that a patient is positive for SARS-CoV-2, but requires urgent initiation of induction treatment, it is recommended to treat while monitoring vigilantly for COVID-19 symptoms and disease course. If symptoms develop, therapy should be discontinued and early initiation of cytokine modulators should be considered.<sup>9</sup> For induction, it is recommended to consider minimizing steroid exposure and reducing the dose of daunorubicin and PEGylated asparaginase in older patients and to delay using anti-CD20 monoclonal antibodies.<sup>7</sup> Second-generation tyrosine kinase inhibitors with reduced dose steroids should be used in the Philadelphia chromosome-positive disease.<sup>7,10</sup>

If patients are positive for minimal residual disease after two cycles of chemotherapy, using blinatumomab is recommended, whereas if patients are negative for minimal residual disease and have already received most of their treatment, moving on to maintenance therapy is suggested. In the maintenance phase, reducing the dose of steroids and avoiding vincristine is recommended and using blinatumomab for minimal residual disease in the Philadelphia chromosome-negative B-cell ALL remains standard.<sup>7</sup>

In addition, patients without COVID-19, should receive abundant growth factor support to hasten the recovery of the neutrophil count and to maintain an absolute neutrophil count of more than 1000 cells per  $\mu\text{L}$  across all phases of therapy. However, in moderate-to-severe COVID-19, the benefit of growth factor support should be weighed against the potential risk of exacerbating the pulmonary complications related to COVID-19.<sup>7</sup> Use of G-CSF in our patient could be one of the factors that resulted in a faster recovery. At the time of the patient's COVID-19 diagnosis, the pandemic was in its initial stages and guidelines on chemotherapy with concomitant COVID-19 were evolving. However, with the passage of time the guidelines have developed as mentioned above.<sup>6,7</sup>

## Conclusion

We present a case of COVID-19 recovery in a patient with underlying leukemia who presented with concomitant febrile neutropenia (FN) and COVID-19. COVID-19 should be suspected in FN even in the absence of other symptoms and G-CSF can be used in these patients for WBC recovery. In our case, the patient was able to survive COVID-19, but, unfortunately, had a relapse of ALL. Managing hematological malignancies effectively while trying to minimize the risk of severe COVID-19 due to immunosuppression secondary to chemotherapy is a challenging clinical situation, with evolving guidelines aiding clinical decision making.

## Conflicts of interest

The authors declare no conflicts of interest.

## REFERENCES

1. Wu Z, McGoogan JM. Characteristics of and important lessons from the coronavirus disease 2019 (COVID-19) outbreak in China: summary of a report of 72314 cases from the Chinese Center for Disease Control and Prevention. *JAMA*. 2020;323(13):1239–42.
2. Liang W, Guan W, Chen R, Wang W, Li J, Xu K, et al. Cancer patients in SARS-CoV-2 infection: a nationwide analysis in China. *Lancet Oncol*. 2020;21:335–7.
3. Mehta V, Goel S, Kabarriti R, Cole D, Goldfinger M, Acuna-Villaorduna A, et al. Case fatality rate of cancer patients with COVID-19 in a New York hospital system. *Cancer Discov*. 2020;10(7):935–41.
4. He W, Chen L, Chen L, Yuan G, Fang Y, Chen W, et al. COVID-19 in persons with haematological cancers. *Leukemia*. 2020;34:1637–45.
5. Lu X, Zhang L, Du H, Zhang J, Li YY, Qu J, et al. SARS-CoV-2 infection in children. *N Engl J Med*. 2020; 382(17):1663–5.
6. Baruchel A, Bertrand Y, Boissel N, Brethon B, Ducassou S, Gandemer V, et al. COVID-19 and acute lymphoblastic leukemias of children and adolescents: first recommendations of the Leukemia committee of the French Society for the fight against Cancers and Leukemias in children and adolescents (SFCE). *Bull Cancer*. 2020;107(6):629–32.
7. Zeidan AM, Boddu PC, Patnaik MM, Bewersdorf JP, Stahl M, Rampal RK, et al. Special considerations in the management of adult patients with acute leukaemias and myeloid neoplasms in the COVID-19 era: recommendations from a panel of international experts. *Lancet Haematol*. 2020;7(8):e601–12.
8. Chen Z, Xiong H, Li JX, Li H, Tao F, Yang YT, et al. COVID-19 with post-chemotherapy agranulocytosis in childhood acute leukemia: a case report. *Zhonghua Xue Ye Xue Za Zhi*. 2020;41:341–3 (in Chinese).
9. Mehta P, McAuley DF, Brown M, Sanchez E, Tattersall RS, Manson JJ. COVID-19: consider cytokine storm syndromes and immunosuppression. *Lancet*. 2020;395: 1033–4.
10. Ravandi F. How I treat Philadelphia chromosome-positive acute lymphoblastic leukemia. *Blood*. 2019; 133:130–6.
1. Wu Z, McGoogan JM. Characteristics of and important lessons from the coronavirus disease 2019 (COVID-19) outbreak in