

Title	The Surgical Treatment of Congenital Aortic Stenosis
Author(s)	MINAMI, KAZUAKI; TATSUTA, NORIKAZU; KONISHI, YUTAKA; MATSUDA, KATSUHIKO; YAMASATO, ARIO; CHIBA, YUKIO; ISHIHARA, HIROSHI; SHIRAISHI, YOSHISADA; MURAGUCHI, TOMOHIKO; NISHIWAKI, NOBORU; HIKASA, YORINORI; UEDA, TADASHI; TAMURA, TOKIO
Citation	日本外科宝函 (1982), 51(5): 761-773
Issue Date	1982-09-01
URL	http://hdl.handle.net/2433/208969
Right	
Type	Departmental Bulletin Paper
Textversion	publisher

臨 床

The Surgical Treatment of Congenital Aortic Stenosis

KAZUAKI MINAMI, NORIKAZU TATSUTA, YUTAKA KONISHI, KATSUHIKO MATSUDA,
ARIO YAMASATO, YUKIO CHIBA, HIROSHI ISHIHARA, YOSHISADA SHIRAISHI
TOMOHIKO MURAGUCHI, NOBORU NISHIWAKI and YORINORI HIKASA

The 2nd Department of Surgery, Faculty of Medicine, Kyoto University
(Director: Prof. Dr. YORINORI HIKASA)

TADASHI UEDA

Department of Pediatrics, Faculty of Medicine, Kyoto University

TOKIO TAMURA

Department of Pediatric Circulation, Tenri Hospital
Received for Publication, July 12, 1982.

Introduction

Congenital aortic stenosis (AS) is usually classified into three categories: supra-
valvular and subvalvular. Some of the problems in the surgical treatment of congenital AS,
especially in the valvular and subvalvular types, are: determination of optimal age for operation,
indication for various techniques, consideration for aortic commissurotomy, anticipation of sudden
cardiac arrest and safety of myocardial protection, and accurate knowledge concerning etiology or
long-term follow-up.

Currently, the most common technique performed for congenital AS is aortic valve replace-
ment (AVR) instead of commissurotomy because in open commissurotomy there is a possibility
that aortic regurgitation and/or aortic re-stenosis may develop, and thus reoperation may be
necessary. Commissurotomy for AS with a narrow annulus is not advisable.

Recently, in congenital AS with a narrow annulus, the following methods are usually per-
formed: aortoventriculoplasty, MANOUGUIAN's method and apico-aortic bypass. However,
these methods need safe myocardial protection.

Problems arising in our 29 cases with congenital AS will be described herein.

Key words: Congenital Aortic Stenosis, Supra-
valvular Aortic Stenosis, Valvular Aortic Stenosis, Subvalvular
Aortic Stenosis, Konno's Operation.

索引語: 先天性大動脈狭窄症, 大動脈弁上狭窄症, 大動脈弁狭窄症, 大動脈弁下狭窄症, 今野の手術.

Present address: The 2nd Department of Surgery, Faculty of Medicine, Kyoto University, Sakyo-ku, Kyoto,
Japan 606.

Materials and Methods

1) Patients

Twenty-nine patients (22 males and 7 females) with congenital AS have been operated upon since 1966 (Tables I-VI). The age range at operation was from 11 months to 43 years (mean age 14.7 years, Fig. 1).

2) Classification of AS

These cases are classified into 3 groups: 3 cases of supravalvular AS, 20 cases of valvular AS and 6 cases of subvalvular AS.

In the 3 cases of supravalvular AS, all were male with a mean age of 5.3 years (Table I). The supravalvular AS were all of a localized type and associated with Williams elfin facies syndrome²⁹⁾. In these cases, serum calcium values were within normal ranges at the time of operation.

In 20 cases of valvular AS, 16 patients were male and 4 were female (Tables II-IV). The mean age was 16.8 years. This group included a case in which a tumor was found on the right coronary cusp of the aortic valve (Case 23). In these patients, valvular AS was associated with the following heart diseases: single coronary artery (1), mitral regurgitation (MR) and coarctation of the aorta (1), patent ductus arteriosus (PDA) and single coronary artery (1), and mitral stenosis (MS) (2). The MS in these two cases was thought not to be congenital; the patients' ages were 23 and 41 years.

Subvalvular AS was seen in 6 patients, 3 males and 3 females, with a mean age of 12.3 years (Tables V, VI). Among the 6 cases, there was 1 case of solitary idiopathic hypertrophic sub-aortic stenosis (IHSS) (Case 27), 1 case of IHSS-tetralogy of Fallot (T/F) in which the T/F was corrected 9 years prior to the operation of IHSS (Case 29), and 1 case of IHSS-atrial septal defect (ASD) secundum type (II)-MR in which the ASD (II) was closed 5 months prior to the operation of IHSS and MR (Case 28). In addition, Case 29 had a membranous discrete type of subvalvular AS.

3) Surgical Procedures

Table I. Patients with Supravalvular AS (n=3)

Patient	Age · Sex	Signs · Symptoms	Chest X-P CTR	ECG SV ₁ + RV _s (Strain pattern)	OP date	Surgical Procedures	Duration of Ao. clamping	Myocardial Protection	Ao-LV Pressure gradient (mmHg)	IABP	Results
1	4 yo m	none	0.49	2.7 mV (-)	1974	Patch *	5 min	ℓ-CP (29C)	6.6 → 1.0	-	survived
2	8 yo m	none	0.49	2.4 mV (-)	1977	Patch *	25 min	Hypothermia (29.6C)	2.0 → 0.5	-	survived
3	4 yo m	none	0.47	3.2 mV (-)	1978	Extended **, Aortoplasty	69 min	Cardioplegia Ice slush (<15C)	8.4 → 0	performed	survived

* McGoon's method ** Doty's method

The supravalvular AS were all of a localized type and associated with Williams elfin facies syndrome.

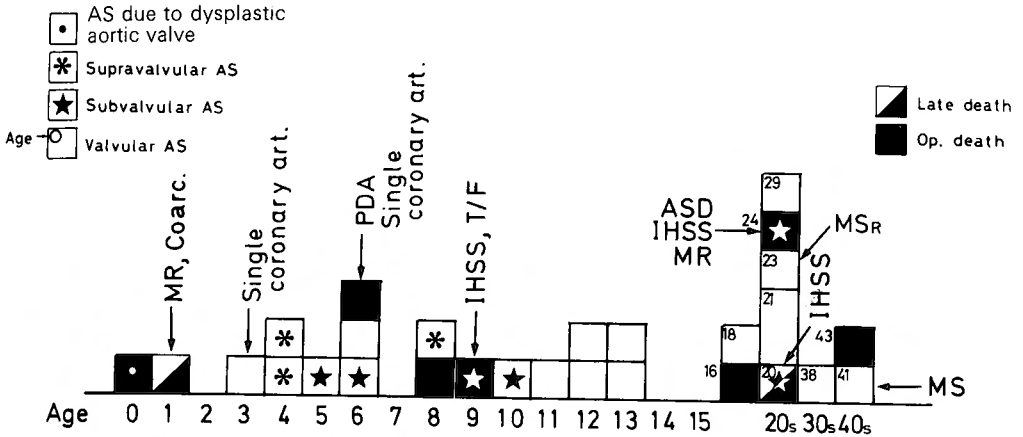


Fig. 1. Classification of AS. Age Distribution, Associated Cardiac Disease and Postoperative Results.

MR: Mitral Regurgitation, Coarc: Coarctation of the Aorta, PDA: Patent Ductus Arteriosus, IHSS: Idiopathic Hypertrophic Subaortic Stenosis. T/F: Tetralogy of Fallot, ASD: Atrial Septal Defect, MS: Mitral Stenosis

All the supravalvular AS were treated with a Dacron patch graft, as performed by McGoon²⁰ and Doty⁹.

Surgical procedures for valvular AS were as follows: commissurotomy (12) (Fig. 2), aortic valve replacement (AVR) (4), aortoventriculoplasty (3), and Manouguian's method (1) (Tables

Table II. Patients with Valvular AS Treated by Open Commissurotomy (n=12)

Patient	Age-Sex	Signs-Symptoms	Chest X-P CTR	ECG SV ₁ +RV _s (Strain pattern)	OP. date	Associated Cardiac disease	Changes in MVO before and after commissurotomy	Duration of Ao. clamping	Myocardial Protection	Ao-LV Press Gradient (mmHg)	IABP	Results
4	16 m	LHF	0.61	4.8mV (+)	1966		7→12mm	35 min		?	-	died of LHF
5	18 f	Palpitation Easy Fatigability	0.60	9.6 (+)	1966	AR (2/4)	?→16mm	36 min	Ice slush CP (20min)	?	-	
6	21 m	Dizziness	0.50	7.2 (-)	1967	AR (1/4)	dilated 7 mm	10 min	CP (27min)	102→?	-	
7	21 m	Dyspnea Palpitation Chest oppress.	0.45	4.1 (-)	1968		12→20mm	10 min	CP (50min)	70→30	-	
8	1 m	Dyspnea Syncope	0.69	7.7 (+)	1972	Congenital MR Coarctation of the aorta	7.5→12mm	-		54→15	-	died of Hepatitis
9	13 m	none	0.44	4.8 (+)	1972		7→15mm	22 min		120→0	-	
10	29 m	Chest oppression	0.42	5.8 (+)	1972		dilated 7 mm	23 min		90→10	-	
11	6 m	none	0.56	7.2 (-)	1975		20→22mm	18 min		30→30	-	
12	11 m	none	0.47	4.8 (+)	1976		7→14mm	25 min		100→15	-	
13	41 m	Orthopnea Hemoptysis	0.51	2.2 (+)	1976	Rheumatic MS	dilated 3 mm	-		35→5	-	
14	12 m	Dyspnea	0.51	4.9 (+)	1977		dilated 6 mm	18 min	Hypothermia (25°C)	150→60	+	
15	3 f	Easy Fatigability	0.58	3.7 (-)	1977	Single coronary Artery	dilated 10mm	16.5 min	Hypothermia (25°C)	?→40	+	

MVO: Mitral Valve Orifice

Table III. Patients with Valvular AS Treated by Aortic Valve Replacement (n=4)

Patient	Age-Sex	Sign. Symptoms	Chest X-P CTR	ECG SV ₁ +RV ₅ (Strain pattern)	OP. date	Valve orifice (Prosthesis used)	Duration of Ao. clamping	Myocardial Protection	IABP	Ao-LV Pressure Gradient (mmHg)	Results
16	8 m	Syncope	0.55	8.7 (+)	1973	5 mm (ID) (B-S 17A)	114min	CP (120min)	-	?→	died (Stone heart)
17	23 f	Syncope Dyspnea Dizziness Palpitation	0.49	2.5 (-)	1974	8 mm (ID) (S-E 8A)	16min	CP (70min)	-	90→10	
18	43 m	Dyspnea Chest oppression Palpitation	0.51	7.8 (+)	1976	0.3cm ² (B-S 21ABP)	64.5min	CP (50min)	-	95→	died (Stone heart)
19	38 m	Edema Dyspnea	0.68	6.0 (-)	1977	8 mm (ID) (L-K 18A)	12min	CP (100min)	+	70→5	

CP : Coronary Perfusion

II-IV). Aortoventriculoplasty was performed in 3 cases with valvular AS (Table IV).

Cases 20 and 21 survived the operation, but Case 22, having PDA and a single coronary artery, died of low cardiac output syndrome (LOS). Retrograde cold blood cardioplegia was performed on Case 22, but the contraction of the right ventricle (RV) was too poor to decrease central venous pressure. The duration of aortic cross-clamping was 108 minutes. In Case 21,

Table IV. Patients with Valvular AS Treated by AVR Combined with Annular Enlargement (n=4)

Patient (age, sex)	20 (13yo. m)		21 (12yo. f)		22 (6 yo. m)		23 (11yo. m)			
Diagnosis	Valvular AS R(1*)		Valvular AS R(2*)		Valvular AS R(1*). PDA Single coronary artery		Valvular AS R(1*) due to dysplasia, MR, PH			
Symptoms	none		none		dizziness		LHF			
CTR	0.51		0.58		0.58		0.74			
G.C.M.	SV ₁ +RV ₅ (mV)		7.5		8.5		5.7		8.1	
	Strain pattern		+		+		+		+	
Cardiac Catheterization		preop	postop	preop	postop	preop	postop	preop	postop	
	LV	198/0, 18		240/0, 14		240/0, 20		175/0, 20		
	Ao	100/70	100/60 (80)	85/65	124/88	110/60 (85)	-	80/45 (63)	-	
	m-PA	31/15 (21)	30/20 (25)	22/12 (17)	40/20 (30)	36/17 (22)		70/15 (38)		
RV inf	45/5, 15	48/-8, 8	32/0, 5	60/2, 20	36/0, 8		70/0, 10			
OP date	1977		1979		1981		1981			
Surgical procedure	Konno's method		Konno's method		Konno's method		Manouguian's method			
Prosthesis	Bjork-Shiley 21 AB		Bjork-Shiley 23 ABP		Omni-Science 21 A		Bjork-Shiley 17 ABP			
Myocardial protection	Coronary perfusion (115 min)		Cardioplegia (MIK) Topical cooling		Cardioplegia (Cold Blood) Topical cooling		Cardioplegia (MIK) Topical cooling			
Duration of Aortic clamping	25 min		100 min		108 min		116 min			
IABP	Performed		Performed		Performed		Not performed			
Postop. course	RHF		RHF, TR (3*). Residual VSD (Shunt 41.5%)		RHF, Contraction of RV: poor		LHF			
Results	Survived		Survived		Died (4 days postop)		Died (16 days postop.)			

Table V. Patients with Subvalvular AS (n=3)

Patient	Age-Sex	Signs-Symptoms	Chest X-P CTR	ECG SV ₁ +RV ₅ (Strain)	OP. date	Type of Subvalv. AS	Surgical Procedure	Duration of Aortic clamping	Myocardial protection	Ao-LV Press. Gradient	Results
24	5 m	none	0.51	7.4 (+)	1976	Discrete (Kelly I-II)	transaortic resection 7 → 14mm	24 min	Hypothermia by H-L bypass (28 °C)	130→40	survived
25	6 m	syncope	0.53	8.3 (-)	1977	Membranous discrete (Kelly I)	transaortic resection 6.5→13mm	22 min	Hypothermia by H-L bypass (32 °C)	70→32	survived
26	10 f	none	0.48	8.2 (+)	1977	Discrete (Kelly I)	transaortic resection 8 → 20mm	20 min	Hypothermia by H-L bypass (32 °C)	50→22	survived

moderate tricuspid regurgitation and residual ventricular septal defect (VSD) remained post-operatively. All three of these cases suffered from LOS due to right heart failure, to which intra-aortic balloon pumping (IABP) was performed postoperatively. The size of the prosthesis for Cases 20-22 were adequate (Björk-Shiley valve 21 and 23, and Omni-Science 21, respectively). Myocardial protection was respectively performed using the following techniques: coronary perfusion (115 min)., cardioplegia using MIK solution²¹⁾ (100 min.), and cold blood cardioplegia (108 min).

In Case 23, AVR (Björk-Shiley 17 A) was performed, enlarging the aortic annulus by the

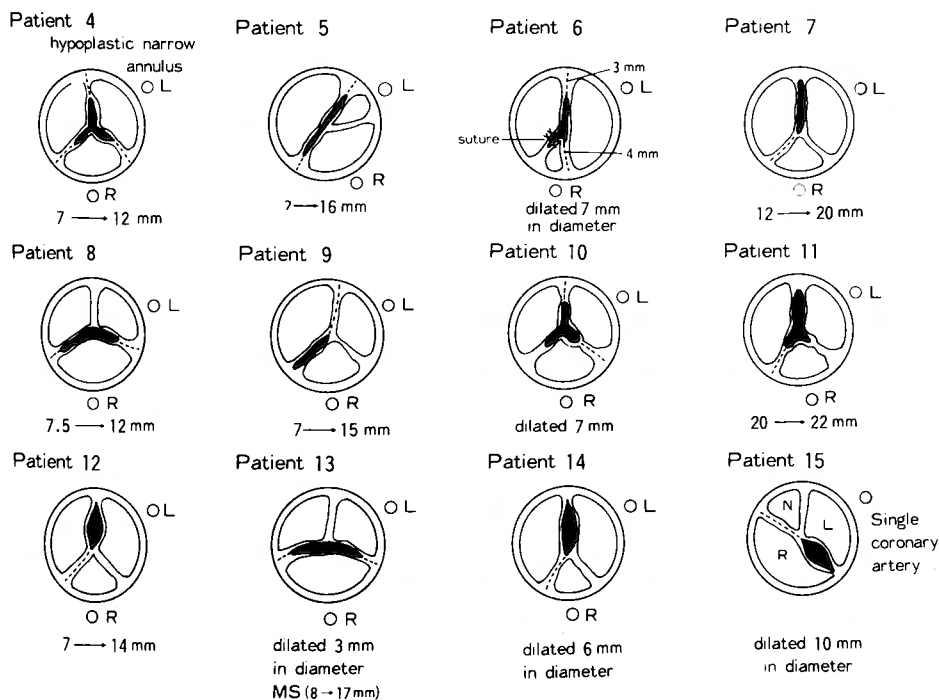


Fig. 2. Patients with Valvular AS Treated by Open Commissurotomy (n=12)

Table VI. Patients with IHSS (n=3)

Patient	Age-Sex	Signs-Symptoms	Chest X-P CTR	ECG SV ₁ +RV ₅ (Strain pattern)	OP. date	Surgical procedures	Duration of Ao. clamping	Myocardial Protection	IABP	Ao-LV Press. Gradient	Results
27	20 f	Syncope Dyspnea	0.65	7.8 (+)	1968	Myotomy through RV	75 min	CP (65min)	—	64→16	Late death 5 years postop
28	24 f	Palpitation Dyspnea			1972 (5)	Closure of ASD (II)	*	*			
		Palpitation	0.53	4.2 (-)	1972 (9)	1) MVR (S-E 3M) 2) Myotomy through RV	66 min	—	—	100→	OP. death
29	9 m	Anoxic Spell			1968	Total correction for T/F	*	*			
		Dyspnea chest oppression	0.56	6.5 (-)	1977	1) Transaortic resection of subvalvular membrane 2) Myotomy through RV	80 min	CP (34min) Ice slush	+	135→	OP. death

MANOUGUIAN's¹⁹⁾ method. This size of the prosthesis was the smallest one which we could obtain at that time. As MR (Grade 2-3) had been detected preoperatively, damage to the mitral valve was avoided. Cardioplegia using MIK solution²¹⁾ was performed, with a duration of aortic cross-clamping of 116 min. However, the patient did not survive the operation due to left heart failure resulting from residual MR.

In all cases with subvalvular AS, myotomy was performed (Tables V, VI), and when subvalvular AS was associated with the other heart diseases, total repair was performed.

Results

All patients with supravalvular AS survived the operation, however, in valvular AS and subvalvular AS, 6 patients (30%) and 3 patients (50%), respectively, died; total mortality was 9 of 29 (31.0%). In valvular AS, 6 patients died of the following causes: left heart failure (2), hepatitis (1), stone heart (2) and LOS (1). All three patients with subvalvular stenosis associated with IHSS died; 2 operative death and 1 late death. In valvular AS, the surgical procedures for the cases which did not survive were: commissurotomy (2), AVR (2), aortoventriculoplasty (1) and MANOUGUIAN's¹⁹⁾ method (1). Case 4 had a severe narrow annulus and slight regurgitation; he underwent an insufficient commissurotomy in 1966, but subsequently died of left heart failure. Case 8 had severe mitral regurgitation, coarctation of the aorta and slight aortic regurgitation; he underwent aortic commissurotomy and mitral annuloplasty, but died of acute hepatitis 3.5 months postoperatively. Except for these 2 cases, all patients who underwent commissurotomy survived the operation. The duration of aortic cross-clamping, in which commissurotomy was performed, was less than 40 minutes. However, AVR required aortic clamping of more than 60 minutes. Therefore, cold coronary perfusion, topical cooling (ice slush), and cardioplegia were performed for myocardial protection. The two patients who died of AVR required more than

Table VII. Patients Who Did Not Survived the Operation (n=9)

Patient (age, sex)	Diagnosis	Operation		Cause of Death	Time of Death	Duration of Ao. clamping
		Procedures	Date			
4 (16yo. m)	AS _R (1*) severe narrow annulus	Comm.	1966	LHF	OP. day	35 min
8 (1 yo. m)	AS Bicuspid MR Coarctation of the aorta	Comm. MAP	1972	Hepatitis	3.5 mo postop.	24 min
16 (8 yo. m)	AS LV cavity small LV wall 20mm	AVR (B-S 17)	1973	"Stone heart"	Table death	80 min CP 45min intermittent
18 (43yo. m)	AS Bicuspid Calcified	AVR (B-S 21)	1976	"Stone heart"	Table death	70 min CP 50min intermittent
22 (6 yo. m)	AS _R (1*) PDA Single coronary artery	Konno's OP. (O-S 21) Ligation of PDA	1981	LOS	4 days postop.	116 min MIK Cardioplegia
23 (11mo. m)	AS _R (1*) Valvular dysplasia MR, PH	Manouguian's OP. (B-S 17)	1981	RHF	16 days postop.	75 min CP 65min
27 (20yo. f)	IHSS	Myotomy through RV	1968	LHF (?)	5 years postop.	—
28 (25yo. f)	ASD (I)	Closure of ASD (I)	1972 5			
	IHSS, MR	1) Myotomy through RV 2) MVR S-E 3M.	1972 10	LOS	Op. day	66 min
29 (9 yo. m)	T/F	Total repair	1968			
	IHSS	1. Transaortic resection of discrete membrane 2 Myotomy through RV	1977	LOS	Table death	80 min CP 34min intermittent

Comm : Commissurotomy LHF : Left Heart Failure CP : Coronary Perfusion
MAP : Mitral Annuloplasty B-S Björk-Shiley S-E Starr-Edwards

120 minutes of aortic cross-clamping, with coronary perfusion of 45 minutes (Case 16) and 50 minutes (Case 18).

Concerning postoperative changes in the LV-Ao pressure gradient, supravalvular AS was superior to subvalvular AS (Fig. 3). In all 3 types of AS, a decrease was seen in the LV-Ao pressure gradient (mmHg) between the pre- and postoperative values. In supravalvular AS, it decreased from 56.6 ± 26.9 to 5.0 ± 4.1 ; in valvular AS, from 88.9 ± 33.8 to 17.9 ± 16.5 ; in sub-valvular AS, from 91.5 ± 32.6 to 27.0 ± 9.5 .

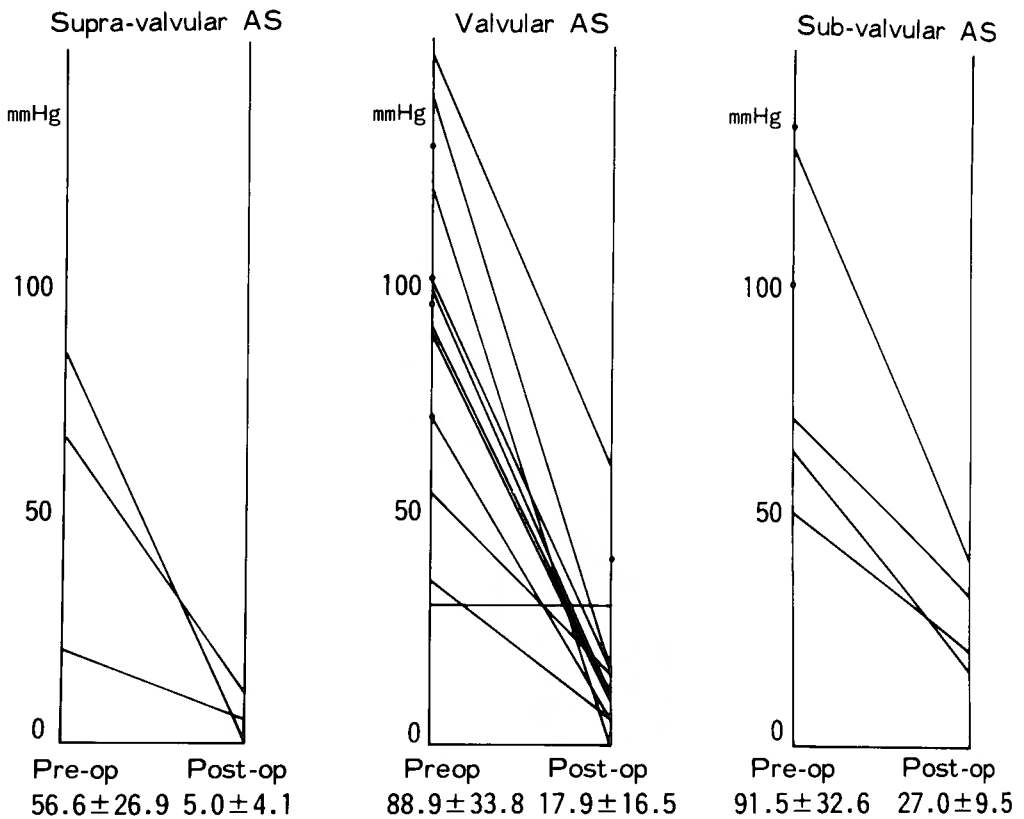


Fig. 3. Postoperative Changes in the Left Ventriculo-Aortic Pressure Gradient

Discussion

Accurate knowledge as to the etiology of congenital AS and hemodynamic change while the patient grows is an important problem in the surgical treatment of congenital AS. The incidence of congenital AS is 2.5–3% of congenital heart diseases^{1,6)}. EL-SAID¹¹⁾ and COHEN⁷⁾ reported that severity of AS is progressive while the patient grows. However, HURWITZ¹⁴⁾ reported that no hemodynamic changes could be found in several long-term studies.

As to the age distribution of congenital AS, there are no characteristic features between the ages of 1 year and 15 years. However, in patients over 20 years old, it is possible that congenital AS may be associated with acquired valvular diseases, for example rheumatic mitral stenosis or subacute bacterial endocarditis. The majority of the patients with valvular AS can survive infancy without symptoms, or, with only slight symptoms, however, there is a great possibility of sudden cardiac arrest before the occurrence of symptoms. Therefore, the presence of symptoms is of little value in the determination of operation time.

1) Supravalvular AS

EDWARDS¹⁰⁾ classified supravalvular AS into 3 groups, namely 1) membranous, 2) hourglass type and 3) hypoplastic type. Our three cases were of the hourglass type, and were treated by

a Dacron patch, as described by McGOON²⁰⁾ and DOTY⁹⁾; the results were good. The hypoplastic type of supravalvular AS should be treated by apico-aortic bypass^{3, 25)}.

2) Valvular AS

There are five basic types of congenital aortic valvular stenosis: unicuspid, bicuspid, tricuspid (dome-shaped), undifferentiated, and membranous. LILLEHEI¹³⁾ stated that from the surgical viewpoint, the infantile group (under 1 year of age) presents different problems from the remaining groups. The cases that require surgery in the first year of life are usually characterized by two features: the valves are almost always unicuspid and, except for endocardial fibroelastosis, associated anomalies such as aortic valvular tumor (Case 23) are rarely encountered. Histological studies revealed that the tumor was a dysplasia of the aortic valve. Usually, the operative criteria²⁾ for congenital AS are: 1) LV-Ao pressure gradient more than 50 mmHg; 2) a valvular orifice area less than $0.5 \text{ cm}^2/\text{BSA}(\text{M}^2)$; 3) a strain pattern by electrocardiography; and 4) recurring anginal or syncopal attacks.

The key point for achieving good results with open commissurotomy is whether the aortic valve has a wide annulus and no calcium deposits. Postoperative results of open commissurotomy are not always good, because slight regurgitation and/or a small LV-Ao pressure gradient may still remain. Follow-up studies with electrocardiography have not shown good late results¹⁷⁾. However, open commissurotomy is the safest method for enlarging the aortic valvular orifice. Usually, in a severely hypertrophied left ventricle there is a limitation in the duration of aortic clamping and also a great possibility of stone heart due to insufficient myocardial protection. Except for one case (Case 4) with a severe narrow annulus, no patient died following open commissurotomy. Thus open commissurotomy can be considered a safe palliative method. Calcium deposits in the aortic valve, which frequently need AVR, are rare in childhood; but increase in frequency in adults. In our cases, 4 of 16 patients required AVR without annular enlargement. Since AVR needed a longer duration of aortic clamping (over 120 min), than open commissurotomy, its mortality (2/4) was higher than that of commissurotomy (2/12). Of the two AVR patients who died, both died of 'stone heart'⁸⁾ on the operation table. In Case 16, the LV cavity was very small with a wide LV wall of 20 mm. In Case 18, the aortic valve was bicuspid and calcified. When a narrow annulus is present, a method which enlarges the annulus is necessary in order to achieve good results.

Recently, in congenital AS with a narrow annulus, the following methods are usually performed:

- 1) NICKS²²⁾ and BLANK'S⁴⁾ method, in which the non-coronary cusp is incised extending to the mitral annulus.
- 2) KONNO¹⁸⁾, SOHMA²⁴⁾ and RASTAN'S²³⁾ method (aortoventriculoplasty)
- 3) MANOUGUIAN'S¹⁹⁾ method in which the annulus is inserted at the site between the non- and left coronary cusp, extending to the anterior mitral cusp.

RASTAN²³⁾ operated upon patients with the following lesions: 1) isolated diffuse fibromuscular subaortic stenosis, 2) diffuse subaortic stenosis plus other cardiovascular anomalies, 3) hypoplastic aortic annulus, 4) IHSS, and 5) previously implanted small aortic valvular prosthesis.

These methods achieve sufficient enlargement of the annulus. However, prosthesis and long duration of aortic clamping are necessary. Improvement of prosthesis and cardioplegic techniques has made this complex surgery easy and safe. However, the surgical damage is extensive enough to require some strong cardioplegic techniques. During the operation we commonly used cold coronary perfusion or topical cooling (ice slush) with cold cardioplegic solution (MIK solution²¹⁾). In addition, IABP was used during the operation and postoperatively.

In AS, a severely hypertrophied LV wall, high LV pressure, low cardiac output, increased oxygen consumption and cardiac work may bring about myocardial damage and a relative ischemic state of endocardium due to decreased coronary blood flow⁹⁾. Especially in cases associated with a single coronary artery, it may be difficult to completely perform cardioplegic techniques. Cardioplegic solution cannot be infused because, as the solution escapes from the incision of the right ventricle and interventricular septum, the infusion pressure drops resulting in a decrease of infusion flow, especially in the endocardial layer.

KIMOTO¹⁶⁾ reported the experimental results of various surgical procedures which enlarge the aortic annulus using live mongrel dogs and extirpated porcine hearts in order to study the clinical usefulness. According to his findings, MANOUGUIAN'S¹⁹⁾ method could enlarge the aortic annulus with a rate of enlargement of $17.1 \pm 4.3\%$ without mitral regurgitation. On the other hand, aortoventriculoplasty could enlarge the aortic annulus with a rate of enlargement of $23.6 \pm 2.5\%$ with safety.

The youngest patient whom RASTEN²³⁾ performed successful operation was 8 years old. Thus, from experimental and clinical studies, the optimal age, in which an adult size prosthesis can be inserted with safety using aortoventriculoplasty, appears to be over 8 years. However, with a single coronary artery, there is a limitation in the selection of surgical procedures for enlarging the aortic annulus.

WADA²⁷⁾ stated that, when the aortic root is hypoplastic and severe calcium deposits are present in the aortic valve, apico-aortic bypass^{3,25)} is advisable. Furthermore, he pointed out the following indications for apico-aortic bypass: 1) insufficient alleviation of aortic stenosis, 2) insufficient myotomy in subvalvular AS, 3) reoperation following AVR and/or MVR, and 4) inapplicability of surgical procedure to aortic valve due to subacute bacterial endocarditis. This method may be advisable for reoperation following AVR in infancy or childhood, as in Case 23 of aortic tumor.

Recently, with improvement of cardioplegic techniques and prosthesis, AVR combined with enlargement of annulus is performed instead of open commissurotomy. However, patients less than 8 years old should be treated by commissurotomy as a first choice of surgical procedure.

3) Subvalvular (subaortic) AS

There are two types of subvalvular AS: 1) discrete subvalvular stenosis or subvalvular fibrous ring stenosis, 2) idiopathic hypertrophic subaortic stenosis (IHSS).

In discrete subvalvular stenosis, transaortic resection of the obstructive portion is advisable. In our three cases, transaortic myotomy was performed and good results were achieved. However, there is a combined type of discrete subvalvular stenosis and hypertrophied muscular stenosis.

In IHSS, indications for surgical treatment are of outmost importance. FRANK and BRAUNWALD¹²⁾ reported that the natural course of IHSS was variable. Therefore, accurate criteria for operative indication can not be established. However many authors^{15),26)} agree with the following criteria: 1) severe symptoms, 2) no improvement by administration of propranolol, 3) severe stenosis at rest and increased stenosis upon exertion, and 4) remarkable increase of stenosis by administration of isoproterenol.

Resection of obstructive muscle has been performed by various approaches: 1) transaortic, 2) through LV-apex, 3) through RV, and 4) through LA. We experienced two IHSS cases associated with other heart diseases. One had T/F which was treated by total repair 9 years previously. The other had ASD(II), which was treated 6 months previously, and MR. Both cases were treated by resection of the obstructive muscle through right ventriculotomy. However surgical damage was so extensive that the patients did not survive the operation. Our case of T/F was a combined type of discrete subvalvular stenosis and IHSS. Rastan operated upon two cases of IHSS by aortoventriculoplasty, and good results were achieved in one case, but the other died of severe acidosis during perfusion.

Summary

In supravalvular AS, except for the hypoplastic type, the use of a Dacron patch poses no problem in surgical treatment. The hypoplastic type should be treated by apico-aortic bypass.

In valvular AS, with improvement of prosthesis and cardioplegic techniques, AVR which enlarges the aortic annulus has been performed with safety. However surgical damage is so extensive that strong myocardial protection is necessary to achieve good results. These methods have a limitation in the rate of enlargement of the aortic annulus, thus limiting the patients' age to over 8 years old. The patient less than 8 years old should be treated by commissurotomy, a safe palliative operation, as a first choice of surgical procedure until the time when radical operation can be performed.

In subvalvular AS, the membranous discrete type was treated by transaortic resection of the obstructive muscle with good results. However, other types of subvalvular AS, including IHSS, should be treated by aortoventriculoplasty. In IHSS, clear surgical indications are necessary in order to achieve good results.

References

- 1) Abbott ME: Atlas of congenital cardiac diseases. American Heart Association, New York, 1936.
- 2) Bernhard WF, Keane JF, et al: Progress and problems in the surgical management of congenital aortic stenosis. *J Thorac Cardiovasc Surg* **66**: 404-419, 1973.
- 3) Bernhard WF, Poirier V, et al: Relief of congenital obstruction left ventricular outflow with a ventriculo-aortic prosthesis. *J Thorac Cardiovasc Surg* **69**: 223-229, 1975.
- 4) Blank RH, Pupello DF, et al: Method of managing the small aortic annulus during valve replacement. *Ann Surg* **22**: 356-361, 1976.
- 5) Buckberg GD, Fixler DE, et al: Experimental subendocardial ischemia in dogs with normal coronary arteries. *Circ Res* **30**: 67-81, 1972.
- 6) Campbell M and Kauntze R: Congenital aortic stenosis. *Brit Heart J* **15**: 179-194, 1953.

- 7) Cohen LS, Friedman WF, et al: Natural history of mild congenital aortic stenosis elucidated by serial hemodynamic studies. *Amer J Cardiol* **30**: 1-5, 1972.
- 8) Cooley DA, Ruel GJ, et al: Editorials—Ishcemic contracture of the “Stone heart” *Amer J Cardiol* **29**: 575-577, 1972.
- 9) Doty DB, Polansky DB, et al: Supravalvular aortic stenosis, repair by extended aortoplasty. *J Thorac Cardiovasc Surg* **74**: 362-371, 1977.
- 10) Edwards JE: Pathology of left ventricular outflow tract obstruction. *Circulation* **31**: 586-599, 1965.
- 11) El-Said G, Galio to FM Jr, et al: Natural hemodynamic history of congenital aortic stenosis in childhood. *Amer J Cardiol* **30**: 6-12, 1972.
- 12) Frank S and Braunwald E: Idiopathic hypertrophic subaortic stenosis. Clinical analysis of 126 patients with emphasis on the natural history. *Circulation* **37**: 759-788, 1968.
- 13) Goor DA and Lillehei CW: Congenital malformations of the heart—Embryology, anatomy and operative considerations. Grune & Stratton, New York, 1975. p. 257-258.
- 14) Hurwitz RA: Valvular aortic stenosis in childhood. Clinical and hemodynamic history. *J Pediat* **82**: 228-233, 1973.
- 15) Kazama S, Asari H, et al: Surgical treatment of idiopathic hypertrophic subaortic stenosis (IHSS). *Heart* **8**: 94-102, 1976.
- 16) Kimoto H: Experimental study of the aortic annulus enlargement. *J Jpn Asso Thorac Surg* **29**: 1200-1213, 1981.
- 17) Konishi Y, Tatsuta N, et al: The surgical treatment of congenital aortic stenosis. *Arch Jpn Chir* **47**: 94-104, 1978.
- 18) Konno S, Imai Y, et al: A new method for prosthetic valve replacement in congenital aortic stenosis associated with hypoplasia of the aortic valve ring. *J Thorac Cardiovasc Surg* **70**: 909-917, 1975.
- 19) Manouguian S: Erweiterungsplastik des hypoplastischen Aortenklappenringes; Beschreibung einer neuen Operationsmethode. Eine experimentelle Studie. *Thoraxchirurgie* **24**: 418-423, 1976.
- 20) McGoon DC, Mankin HT, et al: The surgical treatment of supravalvular aortic stenosis. *J Thorac Cardiovasc Surg* **41**: 125-133, 1961.
- 21) Murata K: Experimental and clinical studies on various methods of myocardial protection—with special reference to Manitol-Insulin-Potassium (MIK) solution. *Arch Jpn Chir* **50**: 1981.
- 22) Nicks R, Cartmill T, et al: Hypoplasia of the aortic root. The problem of aortic valve replacement. *Thorax* **25**: 339-346, 1970.
- 23) Rastan H, Abu-Aishah N, et al: Results of aortoventriculoplasty in 21 consecutive patients with left ventricular outflow tract obstruction. *J Thorac Cardiovasc Surg* **75**: 659-669, 1978.
- 24) Sohma Y, Imamura Y, et al: Right coronary cusp approach—Patch-enlargement of narrow aortic annulus and aortic valve replacement. *Jpn J Thorac Surg* **28**: 41-47, 1975.
- 25) Sarnoff SJ, Donovan TJ, et al: The surgical relief of aortic stenosis by means of apical-aortic valvular anastomosis. *Circulation* **11**: 564-575, 1955.
- 26) Tajik A, Giuliani ER, et al: Idiopathic hypertrophic subaortic stenosis. Long-term surgical follow-up. *Amer J Cardiol* **34**: 815-822, 1974.
- 27) Wada J, Ohteki H, et al: Left ventricular apical-aortic bypass for congenital aortic stenosis. *Jpn J Thorac Surg* **33**: 275-281, 1980.
- 28) Williams JCP, Baratt-Boyes BG, et al: Supravalvular aortic stenosis. *Circulation* **24**: 1311-1318, 1961.

和文抄録

先天性大動脈狭窄症の外科治療

京都大学医学部外科学教室第2講座（主任：日笠頼則教授）

南 一明，龍田 憲和，小西 裕，松田 捷彦，山里 有男
千葉 幸夫，石原 浩，白石 義定，村口 和彦
西脇 登，日笠 頼則

京都大学医学部小児科学教室

上 田 忠

天理よろづ相談所病院小児循環器科

田 村 時 緒

大動脈弁上狭窄症では，低形成型を除いてパッチ拡大術で良好な成績を得た。

大動脈弁狭窄症では，弁置換術が主流となりつつあるが，交連切開術の高い安全性は再考の余地がある。成人用サイズの人工弁置換の困難な8才未満では，第

一選択として交連切開術か，8才以上では今野の手術をはじめ人工弁置換術がより良策と考えられる。

大動脈弁下狭窄症では，discrete型では，経大動脈切除で良好な結果が得られたが，IHSSでは，結果は不良で，手術適応の確立がまず必要である。