

| | |
|-------------|-----------------------------------------------------------------------------------|
| Title | Aneurysm at the Fenestration of Basilar Artery : Case Report |
| Author(s) | NAKASU, YOKO; NAKASU, SATOSHI; KIDOOKA, MINORU; HANDA, JYOJI |
| Citation | 日本外科宝函 (1982), 51(2): 344-348 |
| Issue Date | 1982-03-01 |
| URL | http://hdl.handle.net/2433/208928 |
| Right | |
| Type | Departmental Bulletin Paper |
| Textversion | publisher |

症 例

Aneurysm at the Fenestration of Basilar Artery
—Case Report—

YOKO NAKASU, SATOSHI NAKASU, MINORU KIDOOKA, JYOJI HANDA

Department of Neurosurgery, Shiga University of Medical Science

(Director: Prof. Dr. JYOJI HANDA)

Received for Publication, Jun. 11, 1982.

An aneurysm arising at the fenestration of the cerebral artery is rare. Recently we encountered a patient with an aneurysm at the fenestration of the basilar artery.

Report of a case

One morning, this 49-year-old man noted a weakness in his right leg, which progressed to a right hemiparesis including the face. Computed tomographic (CT) scan on admission to a local hospital was reportedly normal. His hemiparesis improved gradually in 3 months. However, a repeated CT scan with a contrast administration disclosed a large, enhancing lesion in the posterior cranial fossa (Fig. 1). The patient was referred to us for further examinations.

Neurologic examinations on admission were normal except for a mild residual weakness involving the right upper extremity. Laboratory examinations showed high serum triglyceride levels and low serum HDL-cholesterol levels. A vertebral angiography by a femoral route showed a large aneurysm of the left vertebral artery (Fig. 2). In addition, there was found a fenestration of the middle third of the basilar artery, and a small aneurysm at the proximal end of the fenestration. Bilateral carotid angiographies were noncontributory. No parenchymatous lesions were found by a repeated CT scanning. He was discharged without an operation. At a follow-up visit 8 months later, he is neurologically normal except for a minimal weakness of his right arm.

Discussion

According to PADGET¹³⁾, the basilar artery is formed by a fusion of the paired primitive longitudinal neural arteries during the second to fourth stage of embryonic development. An incomplete fusion for unknown reasons results in a fenestration, or a partial duplication, of the basilar artery. Although the fenestration of the basilar artery has been described both in anatom-

Key words: Basilar artery, Cerebral aneurysm, Cerebral arteries, Fenestration.

索引語: 脳底動脈, 脳動脈瘤, 脳動脈, 窓形成.

Present address: Jyoji Handa, M.D., Department of Neurosurgery, Shiga University of Medical Science, Seta, Ohtsu, Shiga, 520-21, Japan.

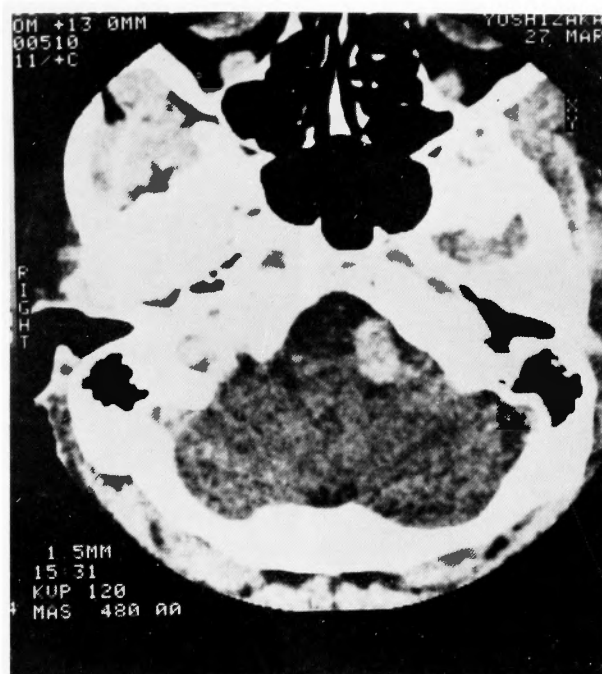

Fig. 1. CT scan showing enhanced mass in the left cerebellopontine angle (vertebral artery aneurysm).

ical specimens and in angiographic literature^{1,4,14,16,17,18}, it is generally thought to be an infrequent vascular anomaly. TAKAHASHI et al.¹⁴ estimated its angiographic incidence to be approximately 0.6 per cent. However, an angiographic identification of this anomaly tends to be hampered by superimposition of the mastoid cells or of dense bones of the skull base, and the low incidence in the previous reports may well be related to oversight.

The fenestration of the cerebral artery usually belongs to an incidental finding. But a simultaneous occurrence of other cerebrovascular anomalies has also been reported, particularly in the cases with the fenestration of the anterior cerebral, middle cerebral or vertebral arteries^{2,5,9,11,12}. In such cases reported previously, however, the aneurysm or arteriovenous malformation arose at a different site from the fenestration, and an association of a congenital aneurysm at the site of the fenestration of the basilar artery is very rare.

To our knowledge, TAVERAS and WOOD¹⁵ were the first to have shown a case with an aneurysm at the proximal end of the fenestration of the basilar artery. Since that time, only few more cases have been reported^{3,6,7,10}. Pertinent data of a total of 7 cases including the present one are summarized in the Table. In six of these 7 cases, the fenestration was found in the proximal portion of the basilar artery, except for our patient in whom the middle third of the basilar trunk was involved.

Furthermore, it should be noted here that in all 7 patients the aneurysm arose at the proximal end of the fenestration. The proximal portion of an arterial fenestration is Y-shaped as in the usual arterial branching. It has been well established that most congenital aneurysms arise at

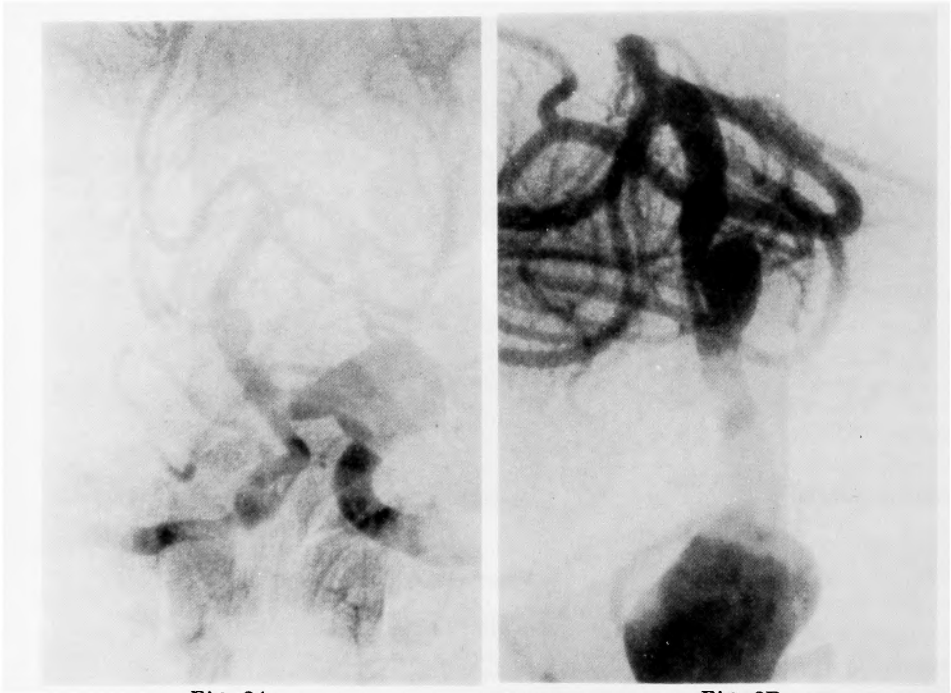


Fig. 2. Vertebral angiogram showing two aneurysms and the fenestration of the middle third of the basilar artery. Smaller aneurysm arose at the proximal end of the fenestration. (A) posterior-anterior view. (B) oblique view.

Table Saccular aneurysm at the basilar artery fenestration

| Authors | Year | Age*/Sex | Location of fenestration | Site of aneurysm | Clinical presentation | Operation | Other associated vascular abnormalities |
|------------------------|------|----------|--------------------------|------------------|-----------------------|---------------|-----------------------------------------|
| Taveras & Wood | 1976 | ?/? | proximal third | proximal end | ? | ? | ? |
| Hemmati & Kim | 1979 | 35/M | proximal third | proximal end | SAH | none | none |
| Hoffman & Wilson | 1979 | 55/F | proximal third | proximal end | SAH | neck clipping | none |
| Becker & Hamilton | 1979 | 34/M | proximal third | proximal end | SAH | neck clipping | none |
| Matricali & van Dulken | 1980 | 47/M | proximal third | proximal end | SAH | neck clipping | none |
| | | 38/M | proximal third | proximal end | SAH | neck clipping | none |
| Nakasu et al. | 1982 | 49/M | middle third | proximal end | PRIND | none | aneurysm of vertebral artery |

*: Age in years, SAH: subarachnoid hemorrhage, PRIND: prolonged reversible ischemic neurological deficit.

the site of arterial branching where a medial defect is present. CROMPTON⁴⁾ has described that a similar defect in the media is present in the proximal end of the fenestration of the basilar (as well as the anterior cerebral) arteries. It is interesting to note, therefore, that there are remarkable

morphological and hemodynamic similarities between two sites of aneurysmal formation, proximal end of the fenestration and the apex of the arterial branching.

References

- 1) Adachi B: *Das Arteriensystem der Japaner*. Kyoto/Tokyo: Maruzen, 1928, Vol. 1, pp. 119.
- 2) 馬場元毅, 清水 隆, 他: 多発脳血管奇形の1例—中大脳動脈窓形成, 前交通動脈瘤, および脳動静脈奇形を合併した1症例について. *脳神経外科* 5: 59-64, 1977.
- 3) Becker DH, Hamilton RD: Saccular aneurysm associated with fenestrated basilar artery: Case report. *Neurosurgery* 5: 695-697, 1979.
- 4) Crompton MR: The pathology of ruptured middle-cerebral aneurysms with special reference to the differences between the sexes. *Lancet* 2: 421-425, 1962.
- 5) Handa J, Teraura T, et al: Agenesis of the corpus callosum associated with multiple developmental anomalies of the cerebral arteries. *Radiology* 92: 1301-1304, 1969.
- 6) Hemmati M, Kim KS: A ruptured aneurysm at the basilar artery fenestration. *Radiology* 130: 174, 1979.
- 7) Hoffman WF, Wilson CB: Fenestrated basilar artery with an associated saccular aneurysm. Case report. *J Neurosurg* 50: 262-264, 1971.
- 8) Krayenbühl H, Yasargil MG: *Die vaskulären Erkrankungen im Gebiet der Arteria Vertebralis und Arteria Basialis*. Stuttgart: Thieme, 1957, pp. 38-42.
- 9) 郭 隆燦, 桑原健次, 他: 中大脳動脈奇形を伴った脳動脈瘤—重複中大脳動脈および中大脳動脈窓形成. *脳神経外科* 7: 691-696, 1979.
- 10) Matricali B, van Dulken H: Aneurysm of fenestrated basilar artery. *Surg Neurol* 15: 189-191, 1981.
- 11) Miyazaki S, Kamata K, et al: Multiple aneurysms of the vertebrobasilar system associated with fenestration of the vertebral artery. *Surg Neurol* 15: 192-195, 1981.
- 12) 水上公宏, 峯 徹, 他: 椎骨動脈窓形成 (vertebral diastematoarteria)—脳動脈瘤, 脳動静脈奇形との合併. *脳と神経* 20: 81-86, 1968.
- 13) Padget DH: The development of the cranial arteries in the human embryo. *Contrib Embryol* 32: 205-261, 1948.
- 14) Takahashi M, Tamakawa Y, et al: Fenestration of the basilar artery. *Radiology* 109: 79-82, 1973.
- 15) Taveras JM, Wood EH: *Diagnostic Neuroradiology*. Ed 2. Baltimore: Williams & Wilkins, 1976, Vol. 2, pp. 795.
- 16) Teal JS, Rumbaugh CL, et al: Angiographic demonstration of the intradural intracranial arteries. *Radiology* 106: 123-126, 1973.
- 17) von Mitterwallner F: Variationsstatistische Untersuchungen an den basalen Hirngefäßen. *Acta Anat* 24: 51-87, 1955.
- 18) Wollschlaeger G, Wollschlaeger PB, et al: Experience and result with postmortem cerebral angiography performed as routine procedure of the autopsy. *Am J Roentgenol Radium Ther Nucl Med* 101: 68-87, 1967.

和文抄録

脳底動脈窓形成部に動脈瘤を合併した1症例

滋賀医科大学脳神経外科学教室 (主任: 半田譲二教授)

中洲 庸子, 中洲 敏, 木戸岡 実, 半田 譲二

脳動脈の窓形成部に動脈瘤をみとめることは稀であるが、神経放射線学の進歩によって、最近報告が散見されるようになった。

著者らは脳底動脈の窓形成部に嚢状動脈瘤がみとめられた1症例を経験したので報告し、さらに現在まで

に報告された6例について合わせて検討を加えた。いづれの場合も動脈瘤は窓形成の近位側分岐部に発生しており、この部に中膜の欠損がみとめられると報告されていることから、動脈瘤の成因を考える上で非常に興味深い症例である。