

Title	Cardiac Arrhythmias Following An Open Heart Surgery of Atrial Septal Defect, Treated Successfully with Temporal Emergency Pacing
Author(s)	NAKGAWA, AKITO; SAKAMOTO, KIYOSHI; MIKAJIMA, TAKATOSHI; ARAKI, MASANORI; AKAGI, MASANOBU
Citation	日本外科宝函 (1983), 52(5): 703-709
Issue Date	1983-09-01
URL	http://hdl.handle.net/2433/208881
Right	
Type	Departmental Bulletin Paper
Textversion	publisher

症 例

Cardiac Arrhythmias Following An Open Heart Surgery
of Atrial Septal Defect, Treated Successfully
with Temporal Emergency Pacing

AKITO NAKAGAWA, KIYOSHI SAKAMOTO, TAKATOSHI MIKAJIMA,
MASANORI ARAKI and MASANOBU AKAGI

The Second Department of Surgery, Kumamoto University Medical School
(Director: Prof. MASANOBU AKAGI)
Received for Publication, June. 20, 1983.

Case report

We report a case presenting the atrial septal defect, and mitral and tricuspid insufficiency complicated with the pulmonary hypertension. The patient was able to survive 9 episodes of postoperatively ventricular fibrillation through the application of counter shock and emergency pacing.

(Patient) Matsu○ Hi○ko, 50-year-old female

(Diagnosis) Atrial septal defect + mitral and tricuspid insufficiency + pulmonary hypertension

(Anamnesis) Gastric ulcer at the age of 48

(Medical record) The patient had been in good health except for a common cold in February, 1972 at which time a diagnosis of the atrial septal defect was made.

Since around September, 1981, she began to experience general fatigue, palpitation and shortness of breath and was admitted to our hospital in January, 1982.

(Status at the time of hospitalization)

The patient (height 150 cm, weight 36.3 kg) showed symptoms resembling cardiac cachexia with the jugular dilatation and the labial cyanosis. A grade 2/6 ejective systolic murmur was auscultated at the left second intercostal sternal margin, and a 3/6 general systolic murmur, at the cardiac apex. The fixed splitting of II-sound and the upright of IIp were audible. Slight Ra-sound was auscultated in the lung region of the upper right back. The liver was palpable 5 finger breaths on the mamillary line. Laboratory reports at the time of hospitalization

(Functions of blood, liver, and kidney) No particular anomalies were observed.

(Lung function) VC 1310cc, % VC 52%, FEV 1.0% 72%, The lung function was slightly

Key words: Atrial septal defect, Serious arrhythmia, Ventricular fibrillation, Counter shock, Emergency myocardial pacing.

索引語: 心房中隔欠損症, 重症不整形, 心室細動, カウンターショック, 緊急心筋電極ペースング.

Present address: The Second Department of Surgery, Kumamoto University, 1-1-1 Honjo, Kumamoto 860, Japan.

weakened.

(Electrocardiogram) Atrial fibrillation, right axis deviation, right bundle branch block, right ventricular hypertrophy, and the changes in ST-T were noted (Figure-1).

(Echocardiogram) Right ventricular hypertrophy and paradoxical movement of the septum were seen and contrast echo revealed the tricuspid insufficiency.

(Cardiac catheter) The cardiac catheterization showed a left-to-right shunt ratio of 62% at the

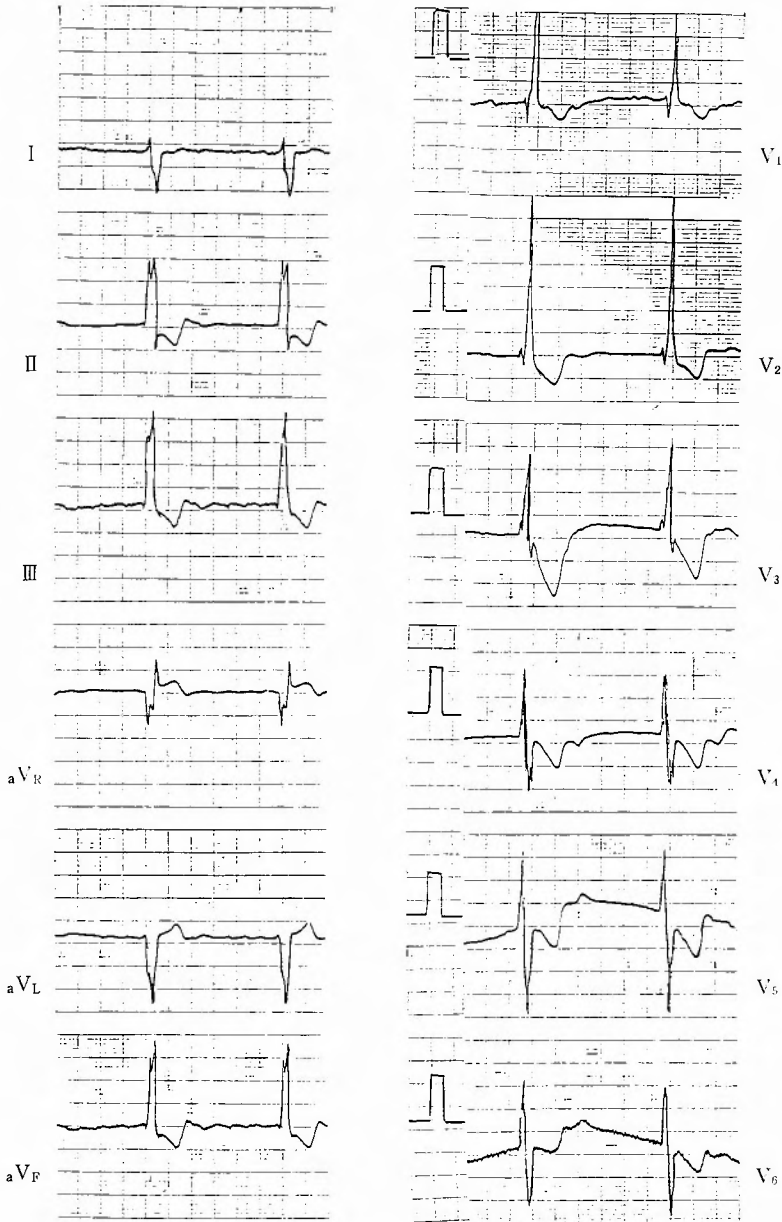


Fig. 1. Electrocardiogram before the operation

atrial level, main pulmonary arterial pressure of 70/30 mmHg, Pp, P's of 68%, Qp/Qs of 2.2 (Chest plain radiography) The cardio-thoracic ratio was 72%.

(Radiography of left ventricle) Sellers 2° of mitral insufficiency was observed.

(Operation and postoperative course) On August 9th, 1982, atrial septal defect patch suture and mitral and tricuspid annuloplasty were performed, after the patient's recutum and myocardial temperatures were cooled to 25°C, and to 15°C, respectively, under the extracorporeal circulation. After discontinuing extracorporeal circulation, the patient was admitted to the ICU. In the ICU, the patient initially presented relatively stable conditions, showing no arrhythmia, blood pressure of 130/70 mmHg, and pulse of 70/m (Figure 2-a). The following day at around 01.00, atrial and ventricular premature contractions and the bigeminal pulse were noted and Lidocaine hydrochloride, Phenytonin natrium and Disopyramide were administered (Figure 2-b). At around 07:50, with the observation of increasing arrhythmia, decreasing blood pressure to 70/40 mmHg, and brady cardia of 54/m., the application of a pace-maker was considered. Suddenly,

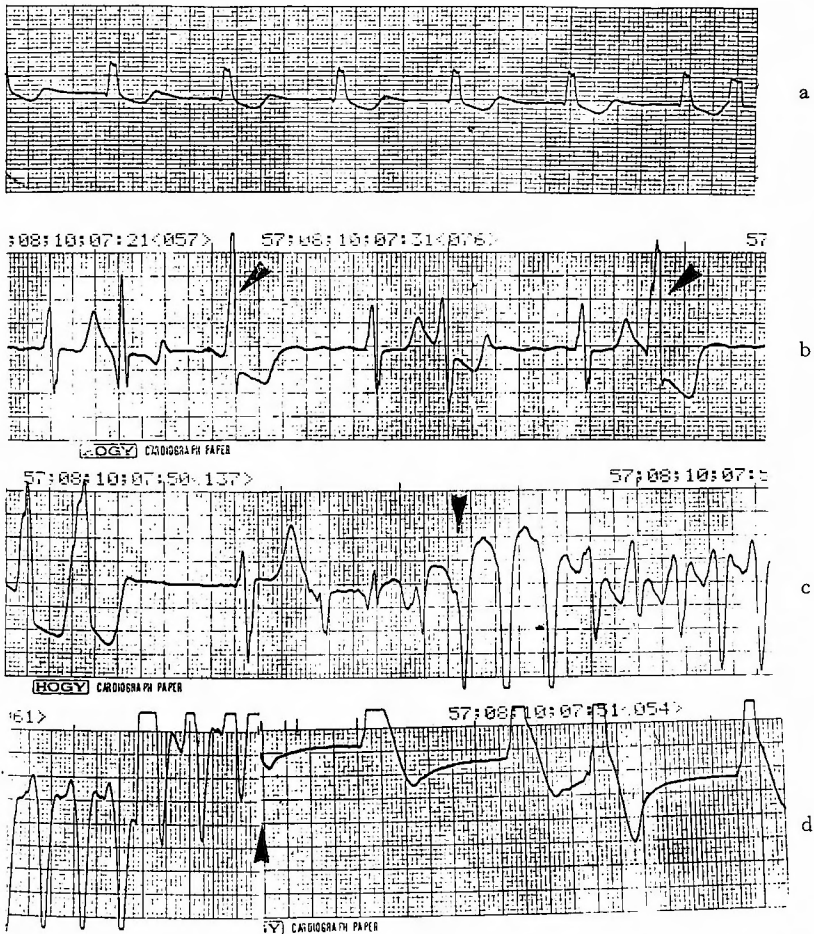


Fig. 2. a. Electrocardiogram in the ICU the day following the operation, b. Ventricular extrasystole (arrows), c. Initiation of ventricular fibrillation (arrow), d. Application of counter shock (arrow)

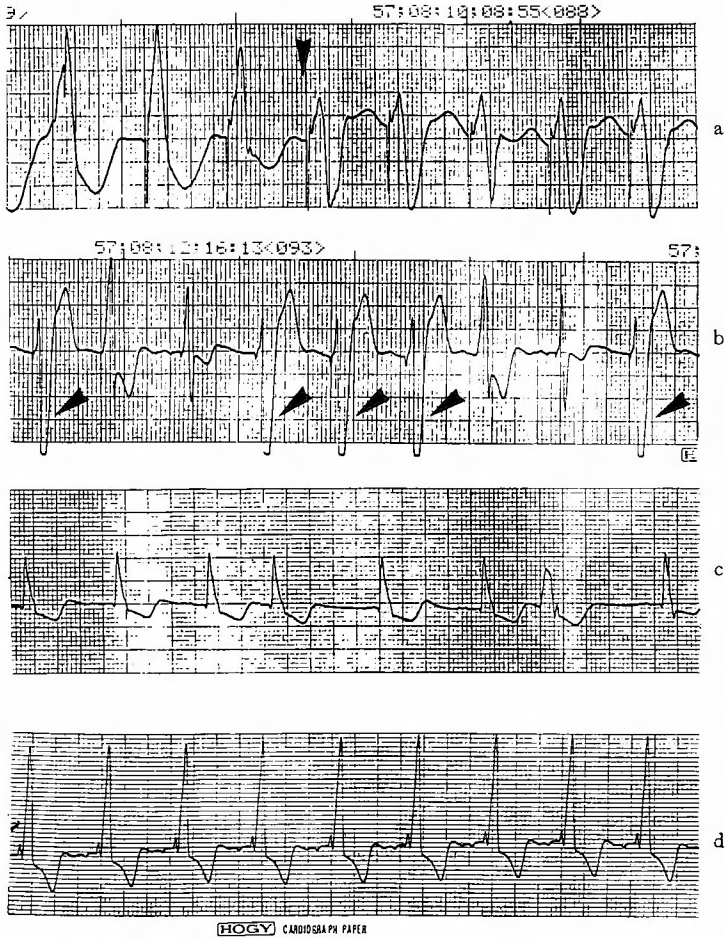


Fig. 3. a. Initiation of pacing (arrow), b. Pacing pulses (arrows), c. Self-pulse only, d. Pacing off, sinus rhythm

high frequency of ventricular extrasystole from ventricular tachycardia to ventricular fibrillation occurred, and this was stopped by immediate defibrillation (Figure 2-c, d). Subsequent episodes of ventricular fibrillation, occurring at 07:52, 08:10, 08:33, 08:34, and 08:36, were also defibrillated. Pacing 90/m was immediately started with a myocardial electrode wire, which was attached to the right ventricular apex through the lower end of the reopened median sternotomy wound (Figure 3-a). Because the frequency of the arrhythmias increased from ventricular tachycardia to ventricular fibrillation due to cough and physical movement of the patient, defibrillation was performed at 13:42 and 14:20, followed by increasing the pacing rate to 100/min. From the 3rd postoperative day the pacing rate was reduced (Figure 3-b). On the 8th postoperative day, with the rate of 60/m., only the self-pulse was observed (Figure 3-c). A sinus arrhythmias of 90/m was observed 4 days later upon cessation of the pacing (Figure 3-d); No other particular anomalies were noted. The patient was transferred to the ward on the 19th postoperative day. The patients made a steady recovery with pulse rate of 70/m, showing only

atrial fibrillation. The improvement was also observed in the venous dilatation, palpitation, shortness of breath, and night-sweat. The patient was discharged on the 54th postoperative day.

Discussion

Arrhythmia, a postoperative complication, is caused by any factor such as the seriousness of the case, operation, therapy, respiratory circulation, anesthesia, drugs, infection, and nutrition. In an elder patient like this case, who had been given long-term digitalis treatment and presented with the atrial fibrillation and acquired valvular disease complicated with the pulmonary hypertension, the arrhythmia is often observed. Though drugs are usually administered to control arrhythmia before, during and after the operation in the cases with the arrhythmia, the drug therapy is not only ineffective but may also exacerbate the condition. Therefore, it may be necessary to perform emergency pacing during the operation as in this case. SAKURAI et al²⁾ indicated that the pacing therapy and the consecutive administration of digitalis were effective in a patient with ventricular extrasystole in both post-and pre-operation period, and that the performance of pacing performed in 52% of the postoperative arrhythmias showed favorable results. There are various kinds of arrhythmias, which can be treated with pacing therapy, including sinus bradycardia, bradycardia-tachycardia syndrome, auriculoventricular block, atrial flutter, atrial tachycardia, and ventricular tachycardia. The pacing methods consists of three types; atrial, ventricular, and atrioventricular pacings, among which the ventricular pacing is the most widely applied. WALDO et al⁵⁾ reported that they always conducted atrial wall dipole pacing in the postoperative treatment because of the effectiveness shown not only in postoperative therapy but also in the diagnosis of arrhythmia. It is now commonly accepted that in the case of potential postoperative arrhythmia, the pace-maker wire should be attached to the atrial or ventricular wall during the operation, and this enables immediate pacing therapy during an emergency. There are several ways to attach pace-maker electrode in such cases. According to ROSENBERG⁴⁾, ESCHER¹⁾, and others, a SWAN-GANZ catheter is applied to insert an electrode percutaneously through antebrachial, subclavia, or femoral veins to the right ventricle endocardium where the pacing is performed. YOKOYAMA, ROE and others^{3,6)} showed different methods in which the pacing is performed by the specially designed electrode inserted into the right ventricle endocardium percutaneously through the myocardium. It can not be denied, however, that the both methods have technical difficulties and are not always reliable. In our case the pacing operation was performed after the median sternotomy; Sutureless myocardial electrode was attached to the right ventricle cardiac apex through the 10 cm-long reopened lower end of the operative wound. This procedure taken within only a few minutes was reliable and easy to apply. Though our patient survived because of emergency pacing, there are many points to be considered, including the possibility of earlier performance of pacing. Fortunately, several other factors contributed to the success of our procedure, such as that the airway was secured by an artificial respirator, the myocardial electrode wire was easily attached, and the heart murmur disappeared completely.

Summary

Under extracorporeal circulation we performed mitral valve commissure suturing, tricuspid annuloplasty, and atrial septal defect closure on a patient with mitral and tricuspid insufficiency, and atrial septal defect complicated with pulmonary hypertension. On the following day, however, the atrial and ventricular premature contractions, serious arrhythmias, and the consecutive ventricular fibrillations were observed. We applied counter shock and emergency pacing against each of the ventricular fibrillation attacks. For the pacing a sutureless myocardial electrode was attached into the right ventricular apex through a 10 cm-long reopened end of the operative wound. The pacing rate was reduced gradually until the 12 postoperative day, when the patient was stable. Our report shows that postoperative emergency pacing by attaching a myocardial electrode through the lower end of reopened medial sternotomy wound is a reliable and simple method, that causes no deleterious effects.

Conclusion

In this report, we demonstrated the successful application of emergency myocardial pacing against the drug-antagonistic arrhythmia and frequent ventricular fibrillations which occurred after the operation of serious atrial septal defect. In our case, the lower end of median sternotomy way reopened and then a sutureless electrode was attached. Among several methods of emergency pacing, this method seems to be preferable because of its reliability and ease of application.

Reference

- 1) Escher DJW and Furman S: Emergency treatment of cardiac arrhythmias emphasis on use of electrical pacing. *JAMA* **214**: 2028-2034, 1974.
- 2) Sakurai J, Misaki J, et al: Cardiac pacing after open heart surgery. *Jpn J Thorac Surg* **33**: 44-49, 1980.
- 3) Roe BB: Intractable Stokes-Adams disease, A method of emergency management. *Am Heart J* **69**: 470-472, 1965.
- 4) Rosenberg AS, Grossman JI, et al: Bedside transvenous cardiac Pacing. *Am Heart J* **77**: 697-703, 1969.
- 5) Waldo AL, MacLean AH, et al: Use of temporarily placed epicardial atrial wire electrode for the diagnosis and treatment of cardiac arrhythmias following open heart surgery. *J Thorac Cardiovasc Surg* **76**: 500-505, 1978.
- 6) Yokoyama M, Wada J, Yanagizawa M, et al: Transthoracic Emergency pacing. *Jpn J Thorac Surg* **33**: 197-200, 1980.

和文抄録

直視下開心術後に出現した難治性不整脈に対する
緊急ペーシングによる治験例

熊本大学医学部第二外科（主任：赤木正信教授）

中川 昭十，酒本喜与志，三ヶ島尊利，荒木 昌典，赤木 正信

我々は高度の肺高血圧症をともなった（心房中隔欠損症+僧帽弁及び三尖弁閉鎖不全症）に対して，体外循環下に僧帽弁両交連部縫縮術，三尖弁輪縫縮術，心房中隔欠損閉鎖術を行ったが，まもなく，上室性及び心室性期外収縮，short-run などの薬物的療法に難治性を示した重症不整脈と，続いて連発した心室細動に遭遇した。心室細動に対して，その都度，カウンターショックを行い，直ちに緊急ペーシングの適応と考え，

手術創の下端を約 10 cm 位再切開し，右室心尖部に sutureless 心筋電極を縫着し，ペーシングを行った。その結果，漸次，ペーシング数を減少させ，11日目にペーシング停止にして無事に救命し得ることができた。このように開心術後には，正中切開創の下端を再切開し心筋電極を装着すれば，ペーシングは数分内に可能であり，確実に侵襲もなく，簡単であり，よい方法であるので報告した。