

Title	Histological Study of the Femoral Heads Treated by Bone Grafting for Idiopathic Necrosis
Author(s)	HATTORI, AKIRA; SUZUKI, KENJI; ONOSE, YOSHINAGA
Citation	日本外科宝函 (1984), 53(2): 287-297
Issue Date	1984-03-01
URL	<a href="http://hdl.handle.net/2433/208776">http://hdl.handle.net/2433/208776</a>
Right	
Type	Departmental Bulletin Paper
Textversion	publisher

## Histological Study of the Femoral Heads Treated by Bone Grafting for Idiopathic Necrosis

AKIRA HATTORI, KENJI SUZUKI and YOSHINAGA ONOSE

Department of Orthopedic Surgery, Akita University School of Medicine

(Director: Prof. Dr. MICHIO ARAI)

Received for Publication, Dec. 6, 1983.

### Abstract

The results of bone grafting in three femoral heads were studied histologically. In the head (Grade III), obtained two years after the operation, collapsed deformity had advanced. Marrow spaces of the head were filled with necrotic debris. The other two heads (Grade II, III) were obtained one and a half months and three months after the procedures. Contours of the heads were not changed. The cell spaces in the grafts were empty except in areas around the graft, however limited, where creeping apposition was evident.

Many reports on the treatment by bone grafting for idiopathic necrosis of the femoral head have been presented, but the results of these procedures are obscure. The purpose of the present study is to examine the femoral heads treated by grafting from patients with idiopathic necrosis.

### Materials and Methods

Case 1. C.I., a male, aged fifty-six, complained of dull pain in his bilateral hips during weight-bearing which had been present for twelve months. There was no serious illness until this illness. Alcoholism, steroid usage, hyperuricemia, pancreatitis and liver disease were not recognized. The radiograph reveals a slight dense femoral head with minimal flattening and congruity of the weight-bearing articular surface in the right hip. In the left hip, on the other hand, the collapsed head without narrowing of the joint space and a radiolucent focus in the superior lateral part of the head were seen (Fig. 1-A). The lesions were classified into Grade II (SUGIOKA's classification, Table 1) in the right hip and Grade III in the left hip. A bone grafting in the left femoral head was performed on November 12, 1974. The technique used was as follows. By means of a two plane roentgenographic control, one K wire was started one centimeter below the tubercle of the greater trochanter, the other 1.5 cm distally. The wires were driven deeper into the head. Then with the aid of the wires a SMITH-PETERSEN nail was struck by a hammer. Two holes were made. Two cortical bone grafts (0.9 cm × 7.0 cm and 0.9 cm × 9.0 cm) were inserted. On January 21, 1975, the same procedure was performed on the

Key words: Idiopathic necrosis, Femoral head, Bone grafting, Histological study.

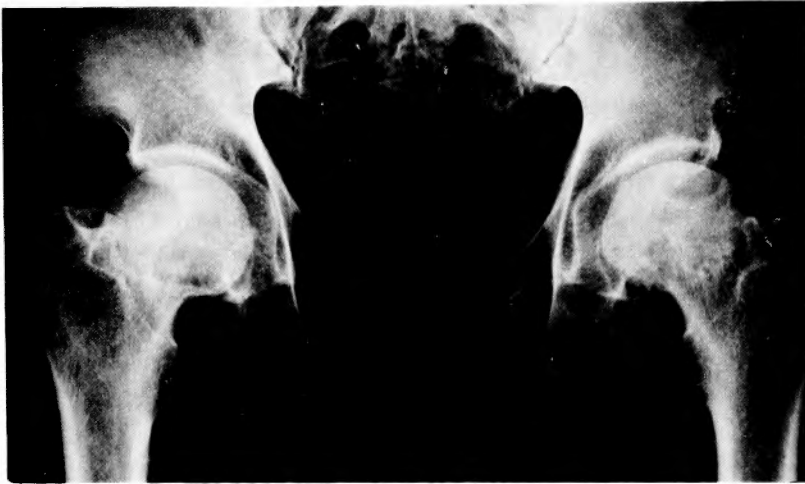索引語: 特発性壊死, 大腿骨頭, 骨移植, 組織学的検討.

Present address: Department of Orthopedic Surgery, Akita University School of Medicine, 1-1-1, Hondo, Akita 010, Japan.

**Table 1.** Classification of cases on the basis of roentgenograms (SUGIOKA)<sup>10)</sup>

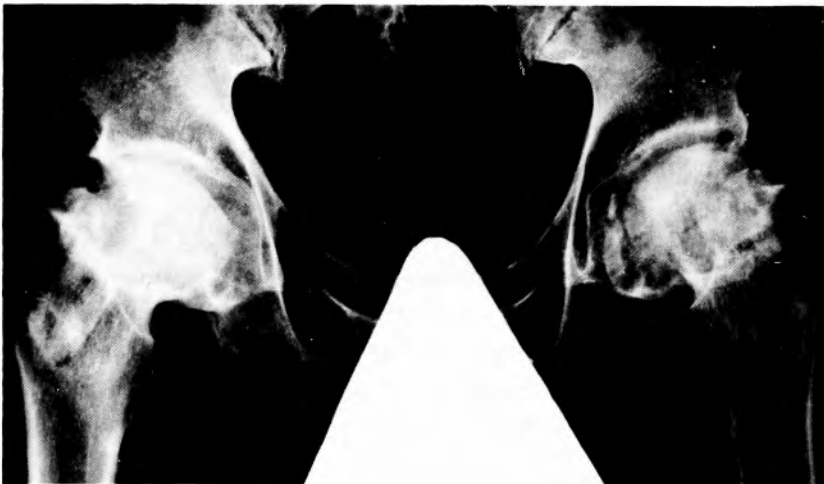Grade I	Necrosis just visible, femoral head still round
Grade II	Flattening of the head
Grade III	Markedly collapsed head without narrowing of the joint space
Grade IV	Advanced changes of the head with narrowing of the joint space

right femoral head. Figs 1-C, D show that the tips of the grafts had not penetrated the head and the tips are situated in far from the subchondral bone. On February 25, 1976, the patient was

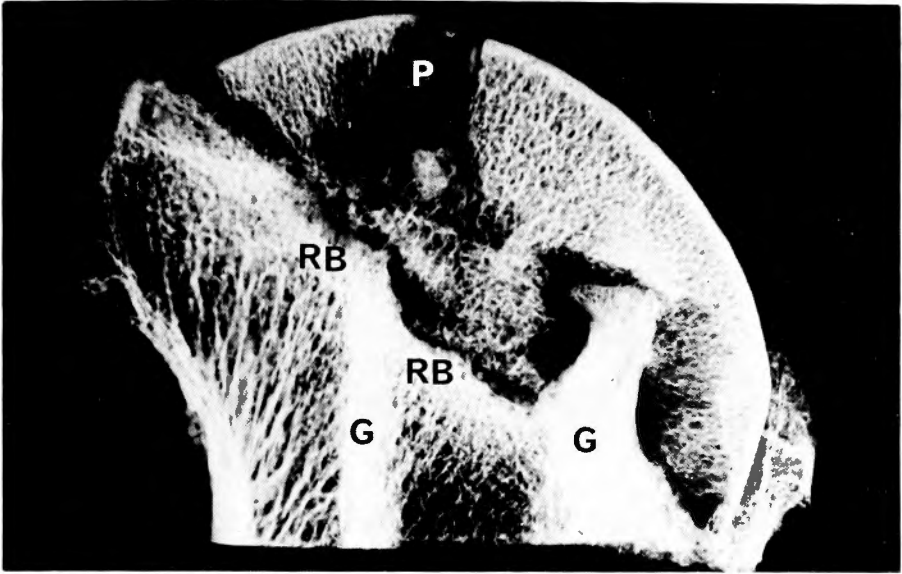


**Figs. 1-A through 1-E.** Case 1. C.I., a man, fifty-six years old, with idiopathic necrosis of the bilateral femoral heads, was treated by bone grafting.

**Fig. 1-A.** Preoperative roentgenograph of the bilateral hips shows a collapsed left femoral head (Grade III) and minimal flattening of the right femoral head (Grade II).

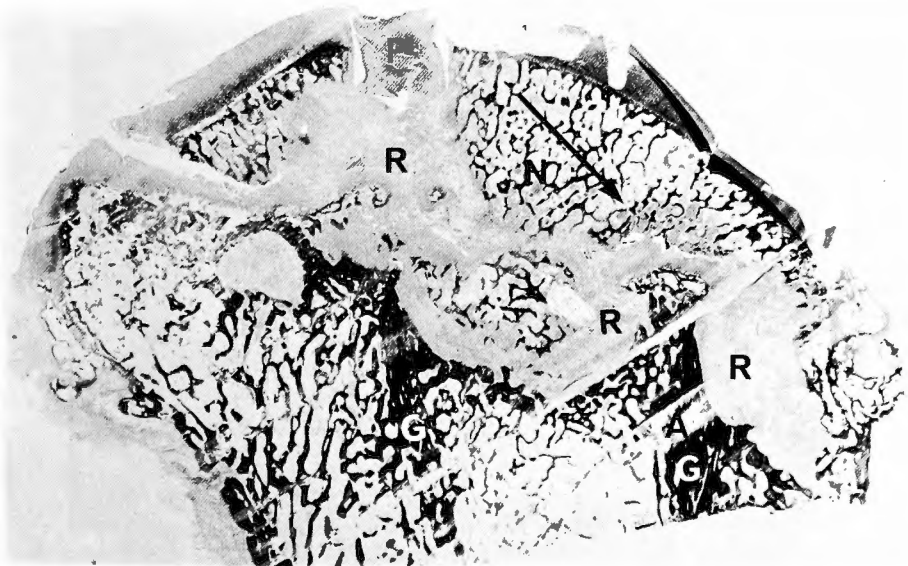


**Fig. 1-B.** Postoperative roentgenograph made twenty months after the operation of the left hip and eighteen months after the operation of the right hip. The markedly collapsed head is recognized in the left. Flattening of the right head is seen.

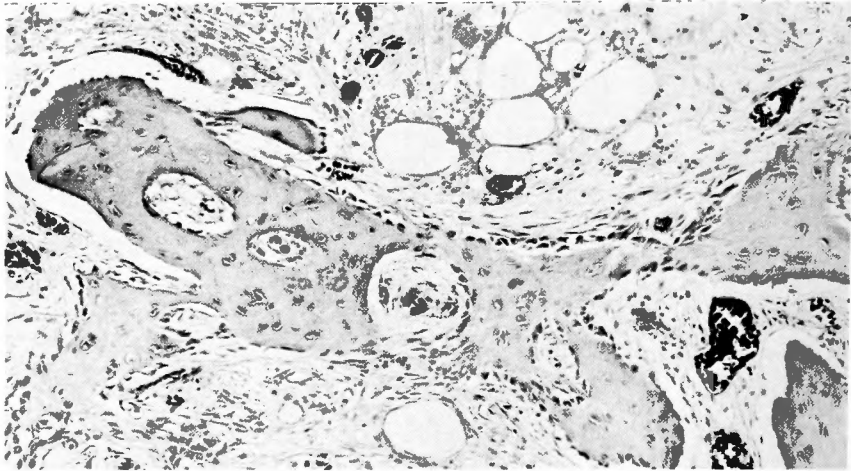


**Fig. 1-C.** Specimen radiograph ( $\times 2.5$ ) of the coronally sectioned left femoral head was obtained two years after the operation. Two tibial grafts (G) are seen. The tip of the distal graft in the area "P" has disappeared. Around the tip of the proximal graft the radiolucent area is seen. Reactive bone (RB) can be seen outlining the infarct.

allowed to walk with two crutches. However, the pains of the hips increased gradually on both sides. Fig. 1-B shows the roentgenograph of the hips on July 9, 1976. In the left hip, the markedly collapsed head was recognized and the fragment was seen at the medial region of the



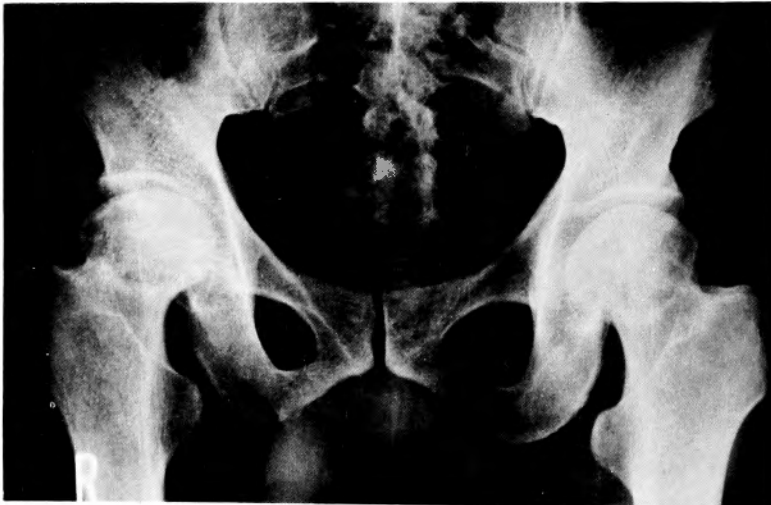**Fig. 1-D.** Macroscopic section (hematoxylin and eosin stain) of the gross section (Fig. 1-C) shows the extensive cancellous bone loss within the reactive fibrous interface (R). In the peripheral area of "P", articular cartilaginous tissues are recognized. Graft (G). Artifact (A). Osteonecrotic zone (N).



**Fig. 1-E.** Photomicrograph of the area shown by the arrow in Fig. 1-D. Note the woven bone formation rimmed with osteoblasts. Capillaries are seen in and around the bone formation (hematoxylin and eosin stain,  $\times 80$ ).

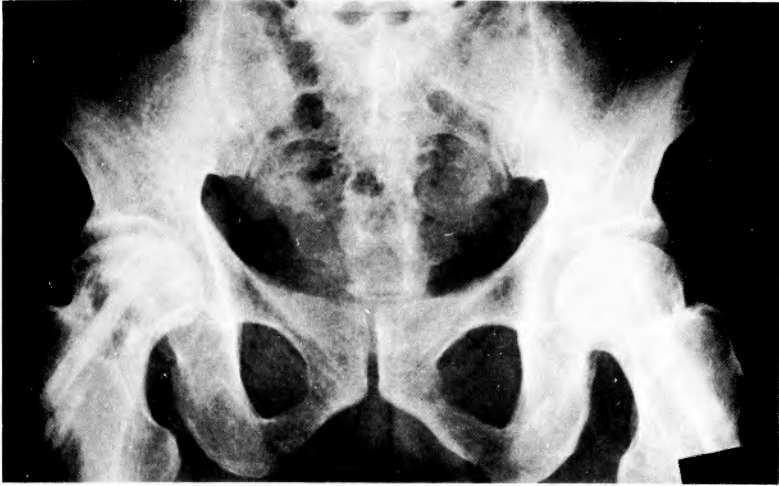head, but narrowing of the joint space was not observed. In the right hip, flattening of the head was seen and marked radiodensities were observed in the whole head. Because of considerable pains in the left hip, total hip replacement was performed on November 16, 1976. Two years had passed after the operation of bone grafting of the left hip. A 5 mm thickness bone slab of the divided head was made, and the Softex radiograph of the slab was obtained (Fig. 1-C). The section of the slab was stained with HE and AZAN and examined histologically (Fig. 1-D, E).

Case 2. K.H., a male, aged fifty-five, complained of the gradually increasing pains in his



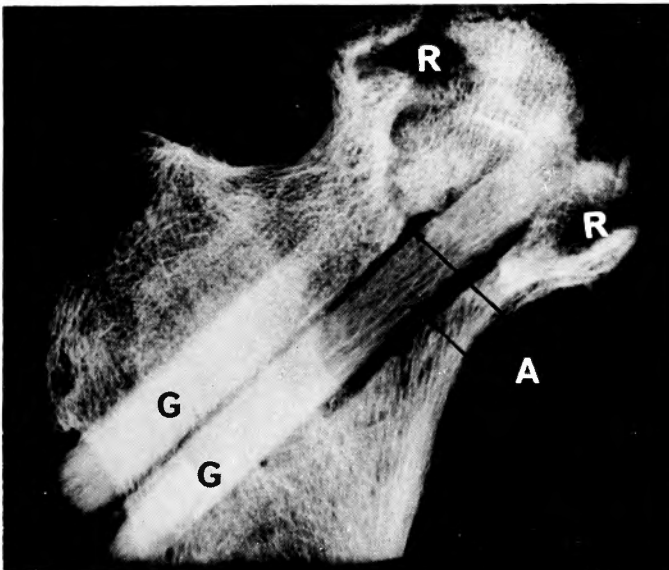
**Figs 2-A through 2-H.** Case 2. K.H., a man, fifty-five years old, with idiopathic necrosis of the bilateral femoral heads, was treated by bone grafting.

**Fig. 2-A.** Preoperative roentgenograph of the bilateral hips shows flattening of the left femoral head (Grade II), and the collapsed right head without narrowing of the joint space (Grade III).



**Fig. 2-B.** Postoperative roentgenograph made approximately three months after the right and one month after the left hip procedure. Contours of the bilateral femoral heads remain unchanged.

bilateral hips during weight-bearing which had been present for eleven months. He had the habit of drinking 1.8 liters of sake (concentration of alcohol; about 15%) every day for twenty years. He suffered from liver disease five years ago. Steroid usage, hyperuricemia, pancreatitis and dysbaric disorders were not recognized. The radiograph revealed slight radiodensities and slight flattening of the bilateral femoral heads, however, collapse had occurred in the right femoral head (Fig. 2-A). A diagnosis was made of necrosis of the both femoral heads. The lesions were

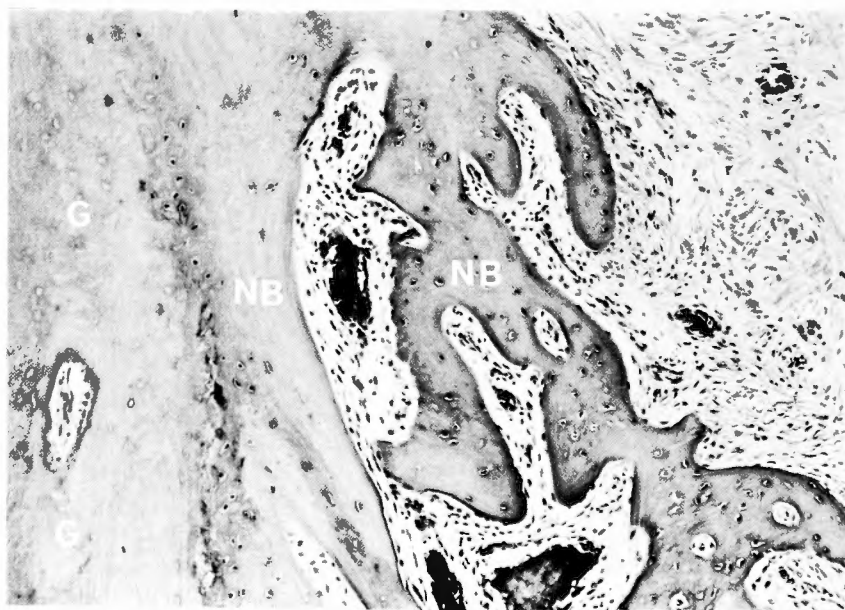


**Fig. 2-C.** Specimen radiograph of the coronally sectioned right femoral head was obtained three months after the operation. Note the extensive bone loss in both the medial and lateral reactive margins (R). Tibial grafts (G). Around the graft the radiolucent area is seen (arrow A).

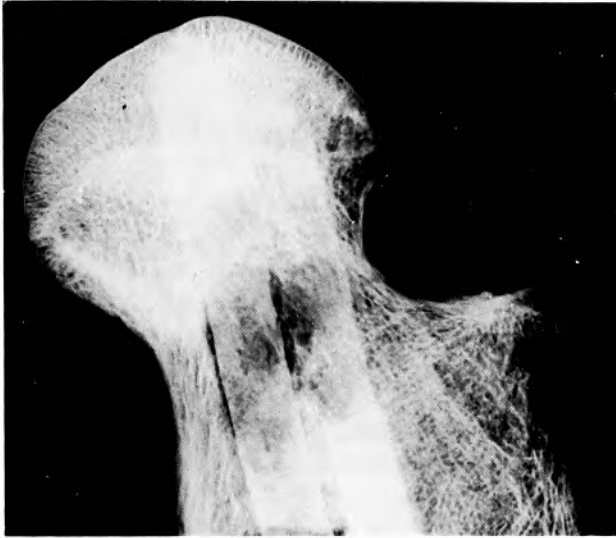

**Fig. 2-D.** Macroscopic section (hematoxylin and eosin stain,  $\times 2$ ) of the gross section (Fig. 2-C) at the different level shows only one tibial graft. Reactive fibrous interface (R). Tibial graft (G). Osteonecrotic zone (N). In "B", there are many dead trabeculae.

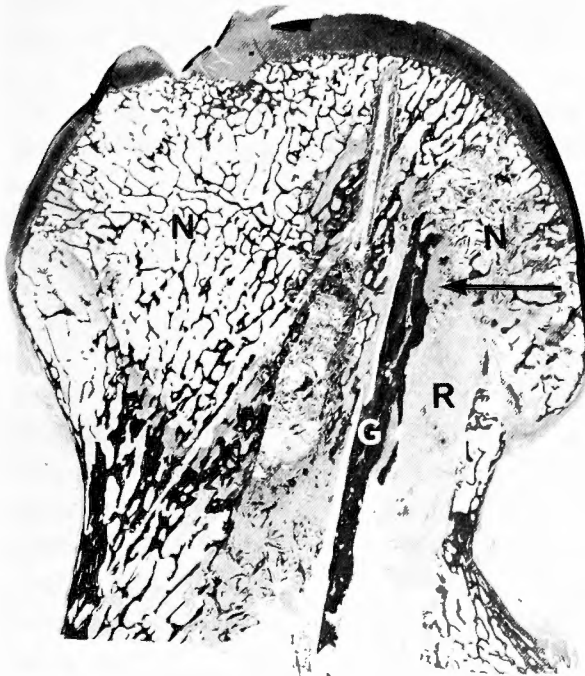classified into Grade II in the left side and Grade III in the right side (SUGIOKA's classification Table 1). Bone grafting procedures for necrosis of the bilateral femoral heads of the case 2 were



**Fig. 2-E.** Photomicrograph of the area shown by the arrow in Fig. 2-D. Necrotic tibial graft (G) is annealed by new bone (NB). This sequence of the change has been referred to as creeping apposition.

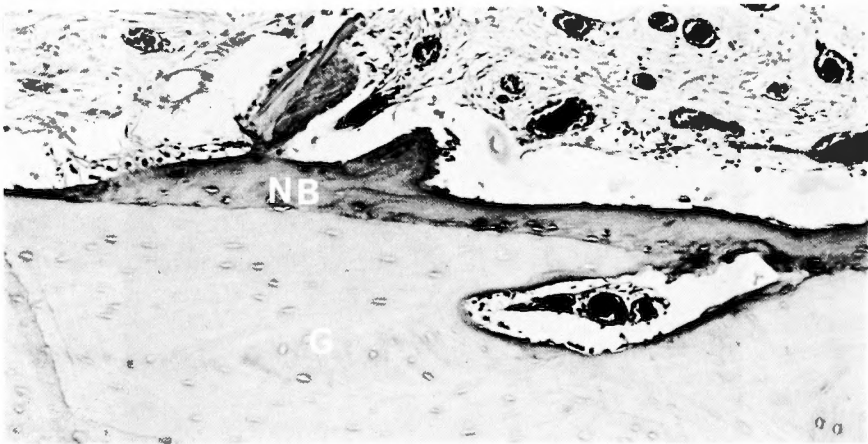


**Fig. 2-F.** Specimen radiograph of the coronally sectioned left femoral head was obtained one and a half months after the operation. Tibial grafts remain almost unchanged. The collapsed head is not recognizable. The tip of the distal graft is situated in the subchondral bone.



**Fig. 2-G.** Macroscopic section (hematoxylin and eosin stain,  $\times 2$ ) of the gross section (Fig. 2-F) at different levels show the essentially normal articular surface and subchondral plate. Tibial graft (G). Osteonecrotic zone (N). Reactive fibrous interface (R).





**Fig. 2-H.** Photomicrograph of the area shown by the arrow in Fig. 2-G. Necrotic tibial graft (G) is annealed by new bone (NB). Bone resorption is recognizable in the graft. Capillaries are seen above the new bone.

performed on February 5, 1981 in the left hip and on March 26, 1981 in the right hip. The techniques used were different from case 1. The holes were drilled with a 9.5 mm-diameter drill. The grafts (9.0 mm in width) did not penetrate the heads. As far as the positions of the tips of the grafts were concerned, only the distal graft on the left hip was situated in the subchondral bone, and the others were separated from it (Fig. 2-C, F). On April 24, 1981, walking exercise began in a warm water pool. Fig. 2-B shows the roentgenograph of the hips on April 25, 1981. Flat deformities of the bilateral femoral heads are not progressing. He suddenly died of idiopathic hypertrophic cardiomyopathy on May 10, 1981. Three months in the right hip and one and a half months in the left hip had passed after the operations. The 5 mm thickness bone slabs of the bilateral femoral heads were made and the Softex radiographs of the slabs were obtained (Fig. 2-C, F). The sections of the slabs were stained with HE and AZAN and examined histologically (Fig. 2-D, E, G, H).

## Results

Figs 1-C through 1-E show the Softex radiograph of the slab and the stained sections of the slabs of the femoral head from case 1. The specimens were obtained two years after the operation. In Fig. 1-D, the head is collapsed and segmented, two tibial grafts are connected to the adjoining bones in the distal area of the reactive fibrous interface. The medial graft, however, is absorbed in the reactive fibrous interface. In the area "P" there are two clefts of articular cartilage. However, in the peripheral area of "P" articular cartilaginous tissues still are recognizable. So it is clear that the graft did not penetrate the head, and the graft did not extend into the joint space. In the area "N", creeping apposition of the preexisting dead trabeculae is not recognizable. However, the woven bone formation, rimmed with osteoblasts and many capillaries, is seen (Fig. 1-E). However, between the tip of the graft and the area where the new bone formation takes place, the reactive fibrous interface is observable. There is no continuity

in those tissues.

Figs 2-C through 2-H show the Softex radiograph of the slabs and the stained sections of the slabs of the femoral head from the case 2. The specimens (Figs 2-C through 2-E) were obtained from the right hip three months after the operation, and the specimens (Figs 2-F through 2-H) were obtained from the left hip one and a half months after the operation. In Fig. 2-C, the head is flattened and segmented. Only one tibial graft is seen in Fig. 2-D. The tip of the graft is separated from the subchondral bone. The articular cartilage is maintained there. So it is clear that the graft did not penetrate the femoral head. In the area "N", creeping apposition of the preexisting dead trabeculae is not recognized. In the area "B" in Fig. 2-D there are many trabeculae, but these trabeculae show empty lacunae and among them are there necrotic fatty tissues and no creeping apposition. Around the necrotic graft, in the limited area of the "arrow", new bone formation is recognized. The area is surrounded with the reactive fibrous interface and separated from the osteonecrotic zone (Fig. 2-D).

In Figs 2-F, G, the head is almost round. The tip of the distal graft is situated in the subchondral bone, but separated from the tip of the proximal graft. The whole articular cartilage is intact, so it is clear that the graft did not penetrate the head. Creeping apposition of the preexisting dead cancellous trabeculae is not seen in the area of "N" in Fig. 2-G. Around the dead graft, in the very limited area of the "arrow" new bone formation is recognizable. Bone resorption is observed in the necrotic graft. Capillaries are seen around the new bone (Fig. 2-H). The area of the new bone formation is surrounded with the reactive fibrous interface separated from the osteonecrotic zone.

### Discussion

PHEMISTER<sup>6)</sup> (1949) stated that cortical bone grafting had been used to stimulate healing of the ununited femoral neck fracture. He reported cases which presented evidence that drilling and bone-pegging of the upper portion of the necrotic head of the femur may increase the rate of transformation of the structure into living bone. He also noted that the drilling not only removed much of the dead bone, but also permitted rapid invasion and transformation of the head. Secondly, he noted that the bone pegs served to prevent fracture and collapse of the head. BONFIGLIO et al.<sup>2)</sup> (1968), BOETTCHER et al.<sup>1)</sup> (1970), MARCUS et al.<sup>5)</sup> (1973), SPRINGFIELD, et al.<sup>8,9)</sup> (1978) and SMITH et al.<sup>7)</sup> (1980) reported good results with cortical bone grafting on idiopathic necrosis of the femoral heads. The techniques they used were essentially that of PHEMISTER<sup>6)</sup>. They noted that the procedure should be done in the early stage. They also emphasized the importance of proper placement of the graft extending to the subchondral bone. On the other hand HUNGERFORD<sup>3,4)</sup> (1979, 1981) reported on decompression, consisting of removal of a 1 cm core of bone from the femoral head and neck through a lateral trochanteric window, to provide rapid relief of symptoms and arrest the disease. He also noted that the procedure should be done in the early stages.

In case 1, the holes were made with nails of SMITH-PETERSEN type instead of drills. And the holes did not penetrate into the joint cavities. Two tips of the grafts are situated far from the

subchondral bones. With these points in view, the procedure was essentially different from PHEMISTER's technique. Firstly decompression of the femoral head seemed not to be enough. Secondly, the improperly positioned grafts did not serve to prevent fracture and collapse of the heads. Fig. 1-A shows a collapsed femoral head of the left hip before the operation, and Fig. 1-B shows the markedly collapsed head (Grade III) twenty months after the operation. The medial graft is absorbed into the reactive fibrous interface (Fig. 1-D). The new bone formation is seen in the limited area of the necrotic zone (Fig. 1-D). It is difficult to judge the effect of the bone grafting because the area of the new bone formation is far from the graft, and the area of the new bone formation is in close contact with the reactive fibrous interface. Generally, clinically and roentgenologically good results of the bone grafting is not recognizable in the left femoral head of case 1.

In case 2, the holes of the bilateral femoral heads were made with drills, and so decompression of the heads seems to be rather better than case 1, however, all four grafts did not penetrate the femoral heads. In this sense decompression of the femoral heads must not have been enough. As far as the positions of the tips of the grafts are concerned, only the distal graft of the left femoral head is situated in the proper position. Fig. 2-A shows a flattening of the left femoral head (Grade II) and a collapsed right femoral head (Grade III) before the operation. Fig. 2-B shows that contours of the bilateral femoral heads remain unchanged after the operations. In the right femoral head, the collapsed head is seen (Fig. 2-C). In the area "B" of Fig. 2-D, many dead trabeculae are observed. There is no necrotic creeping apposition, so it is difficult to decide from which tissues the dead trabeculae are derived, the original cancellous bone of the femoral head or the reactive bone, stimulated by the bone grafts. In any case, the living new bone is recognized in the very limited area of the arrow of Fig. 2-D (Fig. 2-E). And the new bone formation is surrounded with the reactive fibrous interface and not in the osteonecrotic zone, so it is difficult to determine the effect of the bone graft. This small amount the new bone material seems not to be helpful in preventing the affected femoral head from progressing in the collapsed deformity. In the left femoral head of case 2, the contour of the head still is almost round after the operation (Fig. 2-F). In the very limited area (arrow in Fig. 2-D, and 2-E), the new bone formation is seen. Around the graft, there is no annealed new bone in the osteonecrotic zone. In the head, the specimens were obtained within a period of one and a half months after the operations. Therefore, it is difficult to evaluate the results of the bone graft.

In our experiences, the techniques used were essentially different from PHEMISTER's method. The new bone formation, which seemed to have resulted from the bone grafting, was not meant to prevent the progressive collapse of the femoral head of idiopathic necrosis.

#### Acknowledgement

The authors wish to thank Professor MICHIO ARAI for his constant interest and advice in this investigation. The authors also thank Dr. EIKICHI OKADA, the Second Department of Pathology, Akita University, for his kind technical assistance.

## References

- 1) Boettcher WG, Bonfiglio M, et al: Non-traumatic necrosis of the femoral head. Part 2. Experiences in treatment. *J Bone Joint Surg* **52-A**: 322-329, 1970.
- 2) Bonfiglio M, Voke EM: Aseptic necrosis of the femoral head and non-union of the femoral neck. *J Bone Joint Surg* **50-A**: 48-66, 1968.
- 3) Hungerford DS: Bone marrow pressure, venography, and core decompression in ischemic necrosis of the femoral head. *The Hip*, St. Louis, C. V. Mosby 1979, p. 218.
- 4) Hungerford DS: Pathogenetic consideration in ischemic necrosis of bone. *Canad J Surg* **24**: 583-588, 1981.
- 5) Marcus ND, Enneking WF, et al: The silent hip in idiopathic aseptic necrosis treated by bone-grafting. *J Bone Joint Surg* **55-A**: 1351-1366, 1973.
- 6) Phemister DB: Treatment of the necrotic head of the femur in adults. *J Bone Joint Surg* **31-A**: 55-66, 1949.
- 7) Smith KR, Bonfiglio M, et al: Non-traumatic necrosis of the femoral head treated with tibial bone-grafting. *J Bone Joint Surg* **62-A**: 845-847, 1980.
- 8) Springfield DS, Enneking WF: Role of bone grafting in idiopathic aseptic necrosis of the femoral head. *The Hip*; St. Louis, C.V. Mosby. 1975, p. 3.
- 9) Springfield DS, Enneking WF: Surgery for aseptic necrosis of the femoral head. *Clin Orthop* **130**: 175-185, 1978.
- 10) Sugioka Y: Trochanteric rotational osteotomy of the femoral head. *The Hip*, St. Louis, C. V. Mosby. 1980, p. 3.

## 和文抄録

## 特発性大腿骨頭壊死に対する骨釘移植術後の組織学的検索

秋田大学医学部整形外科学教室（指導：荒井三千雄教授）

服部 彰，鈴木 堅二，小野瀬好良

特発性大腿骨頭壊死に対する，骨釘移植術の結果を組織学的に検討した。骨移植時3度，術後2年で症状悪化し，股関節全置換術の際に得られた骨頭（第1例）と，骨移植時両側それぞれ2，3度で，術後それぞれ1カ月半，3カ月に心疾患により死亡し，剖検により得られた2骨頭（第2例）を対象とした。第1例の骨

頭は陥没変形が進行し，広範囲の壊死組織を認めた。骨釘は壊死域内にも存続し，骨釘周辺には血管に富む骨組織がみられた。第2例の2骨頭の骨釘骨梁はともに empty lacunae で周辺の一部に添加骨形成が認められた。一方骨釘より離れた壊死組織の部位では，これら反応性の骨新生の像は全くみられなかった。