

Title	A New Technique for Correction of Total Anomalous Pulmonary Venous Connection to the Right Atrium Using a Flap of the Right Atrial Wall
Author(s)	MURAOKA, RYUSUKE; YOKOTA, MICHIO; AOSHIMA, MINORU; KYOKU, INSHIN; NOMOTO, SHINICHI; KOBAYASHI, AKIRA; NAKANO, HIROYUKI; UEDA, KEN; SAITO, AKIHIRO
Citation	日本外科宝函 (1981), 50(6): 860-866
Issue Date	1981-11-01
URL	<a href="http://hdl.handle.net/2433/208565">http://hdl.handle.net/2433/208565</a>
Right	
Type	Departmental Bulletin Paper
Textversion	publisher

---

臨 床

---

## A New Technique for Correction of Total Anomalous Pulmonary Venous Connection to the Right Atrium Using a Flap of the Right Atrial Wall

RYUSUKE MURAOKA, MICHIO YOKOTA, MINORU AOSHIMA, INSHIN KYOKU,  
SHINICHI NOMOTO, AKIRA KOBAYASHI, HIROYUKI NAKANO,  
KEN UEDA and AKIHIRO SAITO

The Departments of Cardiovascular Surgery and Cardiology,  
Shizuoka Children's Hospital

Received for Publication, Aug. 19, 1981.

Late pulmonary venous obstruction in children who underwent early correction has become one of the most important problems in surgical treatment of total anomalous pulmonary venous connection (TAPVC)<sup>1-4,8,16)</sup>. In the repair of cardiac type of TAPVC, a patch of pericardium or prosthetic material has been used to redirect the pulmonary venous flow to the left atrium. Recently, WHIGHT, BARRATT-BOYES and their associates<sup>16)</sup> reported a case of late pulmonary venous obstruction due to the patch material. We developed a new procedure in which a flap of the right atrial wall was used as a patch to prevent late pulmonary venous obstruction.

### Operative procedure

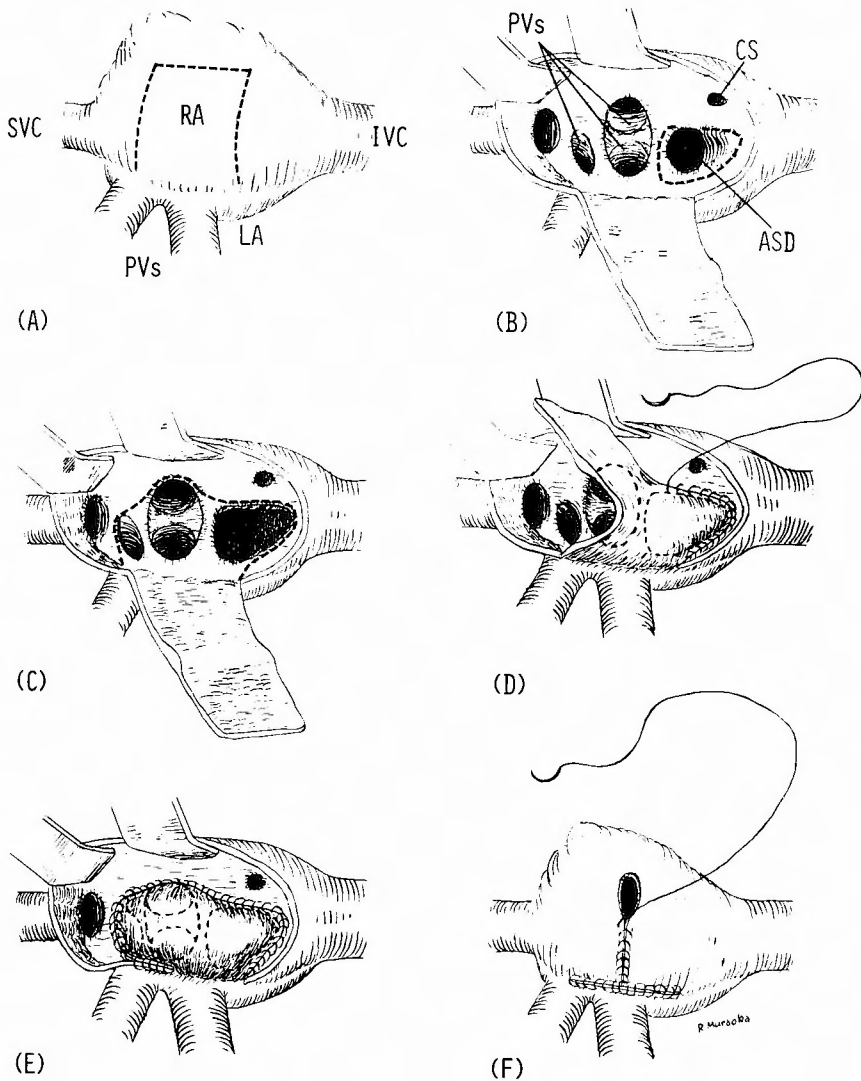
The heart is exposed by means of a median sternotomy. After establishment of cardiopulmonary bypass or deep hypothermic circulatory arrest, the right atrium which usually dilates markedly is opened approximately 1 cm posterior and parallel to the atrioventricular groove. After identification of intracardiac anatomy, the atrial incision is extended posteriorly toward the interatrial groove on both sides as to form a rectangular flap (Fig. 1. A). Base of this flap occupies the middle one-half of the distance between each vena cava. The patent foramen ovale or atrial septal defect is enlarged by excising the atrial septum superiorly, inferiorly and laterally but not medially to preserve the middle and anterior internodal pathways (Fig. 1. B). The rectangular atrial wall flap is then sutured over the resulting defect and the pulmonary vein orifices to direct pulmonary venous blood into the left atrium (Fig. 1. C, D, E). The atrial incision then is closed in the shape of inverted T utilizing the atrial wall itself (Fig. 1. F).

---

Key words: Total anomalous pulmonary venous connection, Atrial flap, Anastomotic stricture.

索引語: 総肺静脈還流異常症, 有茎心房片, 吻合部狭窄.

Present address: The Department of Cardiovascular Surgery, Shizuoka Children's Hospital, Urushiyama 860, Shizuoka, 420, Japan.



**Fig. 1.** Operative procedure used for repair of total anomalous pulmonary venous connection to the right atrium in the present case. A, The right atrium was opened as indicated by the dotted line. B, The atrial septal defect was enlarged by excising the atrial septum superiorly, inferiorly and laterally. C, The dotted line indicates the suture line of the atrial wall flap to the atrial septum. D and E, The atrial wall flap was sutured over the atrial septal defect and the pulmonary vein orifices to direct pulmonary venous blood into the left atrium. F, The atrial incision was closed in the shape of inverted T utilizing the atrial wall.  
 Legend: SVC, Superior vena cava. IVC, Inferior vena cava. RA, Right atrium. PVs, Pulmonary veins. LA, Left atrium. CS, Coronary sinus. ASD, Atrial septal defect.

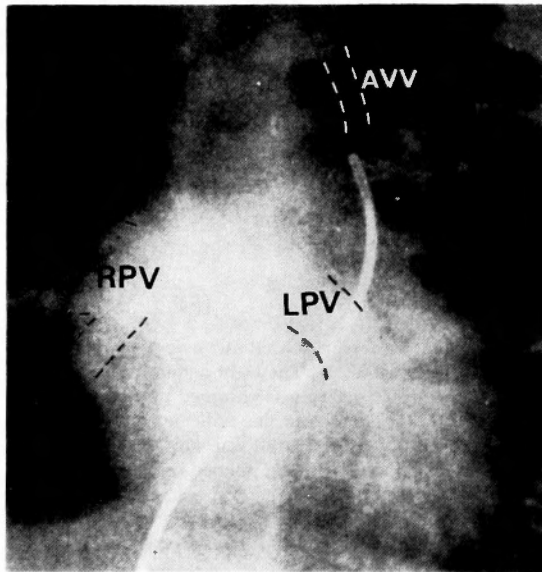
### Case report

The patient was a 15-month-old boy who had been born of a term, normal delivery with a birth weight of 3,100 gm. A cardiac murmur was first heard at 1 month of age. His feeding and

weight gain were poor and he suffered from frequent respiratory infections but no cyanosis was noticed. At 10 months of age, the first examination at our hospital revealed an acyanotic child with a loud and narrowly split second heart sound, no thrill, and a Grade 3/6 systolic ejection murmur and a Grade 2/6 diastolic murmur maximal along the left sternal border. The electrocardiograms indicated right ventricular hypertrophy and right atrial enlargement with a QRS axis of  $-170^\circ$  in the frontal plane. Chest roentgenograms showed increase in heart size and pulmonary vasculature. Echocardiograms revealed the dilated right ventricle with paradoxical movement of the ventricular septum and the small-sized left ventricle.

When he was 11 months of age, cardiac catheterization and angiocardiology were performed. A marked oxygen step-up was found at the right atrial level. Cineangiography demonstrated that the right and left pulmonary veins connected directly with the upper half of the right atrium, and a small anomalous vertical vein connected with the innominate vein (Fig. 2). Diagnosis of mixed type TAPVC was established but the communication between the right atrium and the anomalous vertical vein could not be confirmed.

The child was operated upon at the age of 15 months with the body weight of 6,940 gm. on August 8, 1979. Deep hypothermia with surface cooling combined with limited cardiopulmonary bypass<sup>6,10)</sup> was used. A median sternotomy incision was made at the nasopharyngeal temperature of  $27.5^\circ\text{C}$ . The right atrium was markedly enlarged and its longitudinal size was 47 mm. Two right pulmonary veins of 9 and 10 mm in diameter drained into the right atrium (Fig. 1. A). Cardiopulmonary bypass was established with venous drainage from a single cannula in the



**Fig. 2.** Preoperative cineangiogram of anteroposterior view. The right and left pulmonary veins connected directly with the upper half of the right atrium, and a small anomalous vertical vein connected with the left innominate vein.

Legend: RPV, Right pulmonary vein. LPV, Left pulmonary vein.  
AVV, Anomalous vertical vein.

right atrium from the right atrial appendage and arterial infusion through a cannula inserted into the ascending aorta. On 10 minutes bypass, the child was cooled from 23.7°C to 15.4°C of nasopharyngeal temperature and the aorta was cross-clamped. The right atrium was opened in the manner as described above (Fig. 1. A) and anatomy was identified. The right superior pulmonary vein drained separately into the right atrium closely beneath the orifice of the superior vena cava. Its orifice was 8×5 mm. The right inferior pulmonary vein and the left pulmonary vein drained into a common recess just beneath the orifice of the right superior pulmonary vein. Elliptical orifice of the recess was 16×14 mm and diameter of each pulmonary vein was 10 mm. An atrial septal defect of 10 mm in diameter was present 3 mm caudad to the recess (Fig. 1. B). Anomalous vertical vein then was dissected and it was confirmed that it connected to the left upper lobe of the lung independently. The atrial septal defect was enlarged as described above and a rectangular flap of the right atrial wall of 22 mm wide and 45 mm long was sutured over the defect and the pulmonary vein orifices to direct pulmonary venous blood into the left atrium (Fig. 1. C, D, E). The atrial incision then was closed in the shape of inverted T utilizing the atrial wall itself (Fig. 1. F). Lastly, the anomalous vertical vein was ligated and cut near the innominate vein and a proximal edge was sutured to the posterior left atrial wall. Total procedure necessitated 60 minutes and the time necessary for the right atrial manipulation was 21 minutes.

The postoperative course was uneventful except for transient arrhythmia of supraventricular type. The patient was discharged on October 18, 1979 in an excellent condition without any medication. Postoperative cardiac catheterization and angiocardiography performed 2 months

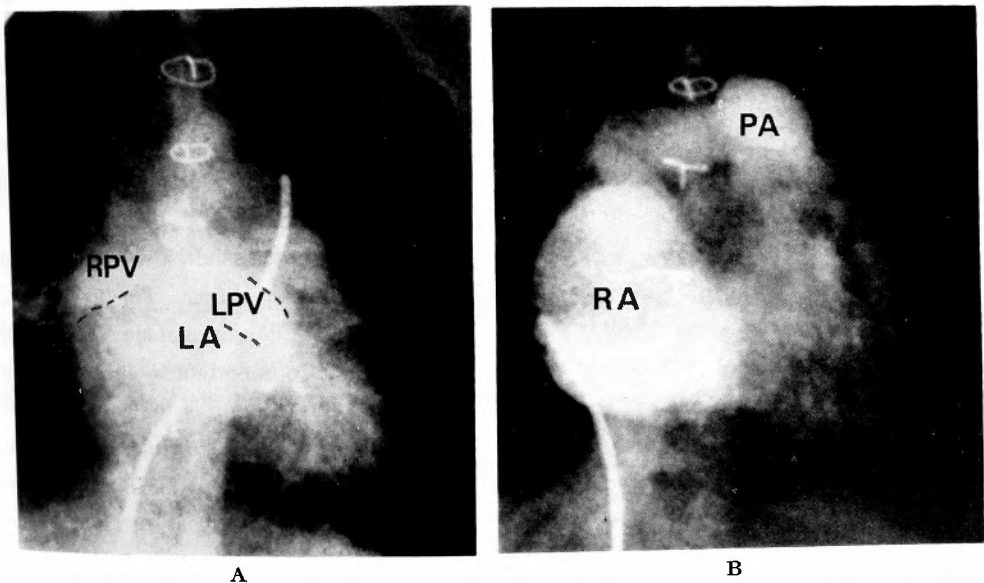


Fig. 3. Postoperative cineangiograms of anteroposterior view. A, The right and left pulmonary veins drained into the left atrium and the size and the shape of the left atrium were normal. B, The right atrium was large in size and normal in shape.  
Legend: RPV, Right pulmonary vein. LPV, Left pulmonary vein. LA, Left atrium. RA, Right atrium. PA, Pulmonary artery.

after surgery revealed normal-sized and normal-shaped left atrium and rather large-sized but normal-shaped right atrium with normal hemodynamics (Fig. 3. A, B). Twenty-four months postoperatively, the child is alert, active and has normal exercise tolerance.

### Discussion

Many of patients with TAPVC have severe symptoms in early infancy and necessitate surgical intervention in this period. As surgical techniques advance and as more of these patients survive the initial operation, late pulmonary venous obstruction can be expected. In fact, anastomotic stricture between the common pulmonary vein and the left atrium in supra- and infracardiac type, obstruction due to the patch material in the cardiac type, and non-surgical obstruction of the pulmonary veins have been reported in the literature.

The procedure described in this paper may prevent late obstruction in the cardiac type of TAPVC because an atrial flap which was used for redirect the pulmonary venous flow to the left atrium is assumed to have a potential for growth as the child grows. The right atrium is usually large enough to allow making a sufficient size of an atrial flap in cardiac type of TAPVC. In addition, an atriotomy may be able to close utilizing inherent atrial wall itself as shown in our patient. In his postoperative angiocardiography, the size of the right atrium was still larger than normal. Although this procedure was developed for correction of the drainage to the body of the right atrium, it may also be applicable to the drainage to the coronary sinus. However, in the repair of the drainage to the coronary sinus we prefer the procedure proposed by VAN PRAAGH and his associates<sup>15)</sup> at present because their procedure is simpler and more protective to the conduction pathways. The technique of utilizing inherent atrial tissue to redirect the pulmonary venous flow to the left atrium in the correction of partial anomalous pulmonary venous connection has been reported by NEPTUNE<sup>11)</sup>, KIRKLIN<sup>9)</sup>, PUIG-MASSANA<sup>12)</sup> and their associates since 1953. The similar procedure was also used for venous inversion in the correction of complete transposition of the great arteries by SENNING<sup>13)</sup>, SHUMACKER<sup>14)</sup> and their associates. Our method described here essentially fall into the same category of the treatment.

Since this procedure requires interruption of the posterior internodal pathway, remaining middle and anterior pathways must be preserved carefully during operation. For this purpose, enlargement of the atrial septal defect is restricted to the superior, inferior, and lateral portion of the septum and the medial portion must be left intact. It is also important to anchor the flap near the edge of the atrial septal defect on the medial side. Interruption of the posterior internodal pathway alone appears to have less significance from the results of modified SHUMACKER-KING procedure for TAPVC<sup>5,16)</sup> and BLALOCK-HANLON procedure for complete transposition of the great arteries<sup>7)</sup>. In both methods the posterior internodal pathway is interrupted completely, but the remaining two pathways are usually not disturbed.

Although more experience and a long-term follow-up study are necessary to evaluate this new procedure, we believe that prevention of late lethal pulmonary venous obstruction is worthwhile in the surgical treatment of this type of defect even at the expense of interruption of one of the three internodal pathways.

### Summary

A new operative procedure for repair of TAPVC to the right atrium was developed. A flap of the right atrial wall was used for redirect the pulmonary venous flow to the left atrium to prevent late pulmonary venous obstruction. A 15-month-old boy with TAPVC to the body of the right atrium was successfully operated on using this procedure and an atriotomy was also closed with atrial wall itself. Postoperative angiocardiography revealed satisfactory morphologic and hemodynamic results. The atrial flap can be expected to grow without developing pulmonary venous obstruction.

### References

- 1) Behrendt DM, Aberdeen E, et al: Total anomalous pulmonary venous drainage in infants. 1. Clinical and hemodynamic findings, method, and results of operation in 37 cases. *Circulation* **46**: 347-356, 1972.
- 2) Breckenridge IM, deLeval M, et al: Correction of total anomalous pulmonary venous drainage in infancy. *J Thorac Cardiovasc Surg* **66**: 447-453, 1973.
- 3) Cooley DA, Hallman GL, et al: Total anomalous pulmonary venous drainage. Correction with the use of cardiopulmonary bypass in 62 cases. *J Thorac Cardiovasc Surg* **51**: 88-102, 1966.
- 4) Fleming WH, Clark EB, et al: Late complications following surgical repair of total anomalous pulmonary venous return below the diaphragm. *Ann Thorac Surg* **27**: 435-439, 1979.
- 5) Gersony WM, Bowman FO, et al: Management of total anomalous pulmonary venous drainage in early infancy. *Circulation* **43**, **44** (Suppl. I): 19-24, 1971.
- 6) Hikasa Y, Shirotani H, et al: Open heart surgery in infants with an aid of hypothermic anesthesia. *Arch Jpn Chir* **36**: 495-508, 1967.
- 7) Issacson R, Titus JL, et al: Apparent interruption of atrial conduction pathways after surgical repair of transposition of great arteries. *Am J Cardiol* **30**: 533-535, 1972.
- 8) Katz NM, Kirklin JW, et al: Concepts and practices in surgery for total anomalous pulmonary venous connection. *Ann Thorac Surg* **25**: 479-487, 1978.
- 9) Kirklin JW, Ellis FH, et al: Treatment of anomalous pulmonary venous connection in association with interatrial communications. *Surgery* **39**: 389-398, 1956.
- 10) Muraoka R, Yokota M, et al: Simplified method for total correction of interrupted aortic arch with ventricular septal defect in infancy. *J Thorac Cardiovasc Surg* **78**: 744-749, 1979.
- 11) Neptune WB, Bailey CP, et al: The surgical correction of atrial septal defects associated with transposition of the pulmonary veins. *J Thorac Surg* **25**: 623-634, 1953.
- 12) Puig-Massana M, Murtra M, et al: A new technique in the correction of partial anomalous pulmonary venous drainage. *J Thorac Cardiovasc Surg* **64**: 108-113, 1972.
- 13) Senning A: Surgical correction of transposition of the great vessels. *Surgery* **45**: 966-980, 1959.
- 14) Shumacker HB, Girod DA: Transposition of the great vessels. Long-term follow-up of corrected cases. *J Thorac Cardiovasc Surg* **57**: 747-752, 1969.
- 15) Van Praagh R, Haken AH, et al: Total anomalous pulmonary venous drainage to the coronary sinus. A revised procedure for its correction. *J Thorac Cardiovasc Surg* **64**: 132-135, 1972.
- 16) Whight CM, Barratt-Boyes BG, et al: Total anomalous pulmonary venous connection. Long-term results following repair in infancy. *J Thorac Cardiovasc Surg* **75**: 52-63, 1978.

## 和文抄録

## 右房還流型総肺静脈還流異常症に対する有茎右房壁を利用した新しい手術法

静岡県立こども病院心臓血管外科, 循環器科

村岡 隆介, 横田 通夫, 青嶋 実, 曲 人伸, 野本 慎一  
小林 彰, 中野 博行, 上田 憲, 齊藤 彰博

右房自身に還流する総肺静脈還流異常症に対しては心房中隔欠損孔を拡大してこれと肺静脈開口部を共通に心膜あるいはタクロンなどの合成布で被うことによって肺静脈血を左房へ流入させる方法が標準的術式として使用されている。しかしながら総肺静脈還流異常症は新生児期あるいは乳児期に手術が必要となるものが多く、従来の方法では術後の身体的発育に伴って肺

静脈開口部の狭窄や閉塞が起る可能性があり、実際に閉塞で死亡した例も報告されている。われわれは心膜あるいは合成布の代りに発育とともに成長する有茎右房壁を使用する方法を考案し15カ月の本症男児に応用した。術後2カ月で実施した心血管造影では満足すべき所見が得られ、術後24カ月の現在まで無症状、無所見に経過している。