

Title	Heterotopic Bone Formation in the Scar of Abdominal Surgery
Author(s)	KASAHARA, YOH; YAMADA, YUKIKAZU; TANAKA, SHIGERU; SONOBE, NARUMI; UMEMURA HIROYA; KUYAMA, TAKESHI; IMANISHI, YOSHIO
Citation	日本外科宝函 (1981), 50(6): 876-884
Issue Date	1981-11-01
URL	<a href="http://hdl.handle.net/2433/208563">http://hdl.handle.net/2433/208563</a>
Right	
Type	Departmental Bulletin Paper
Textversion	publisher

---

症 例

---

## Heterotopic Bone Formation in the Scar of Abdominal Surgery

YOH KASAHARA, YUKIKAZU YAMADA, SHIGERU TANAKA, NARUMI SONOBE,  
HIROYA UMEMURA and TAKESHI KUYAMA

The Second Department of Surgery, Kinki University School of Medicine  
(Director: Prof. Dr. TAKESHI KUYAMA)

YOSHIO IMANISHI

The Second Department of Anatomy, Tokai University School of Medicine  
(Director: Prof. Dr. KANJI KIYOKI)

Received for Publication, Sept. 9, 1981.

Since the first report of ASKANAZY<sup>3)</sup> in 1901, the published cases of so-called heterotopic bone formation in the scar of abdominal surgery have been rare. Recently we have reported two cases<sup>10)</sup>, and this is a report of a new additional case with review of the literature.

### Report of a case

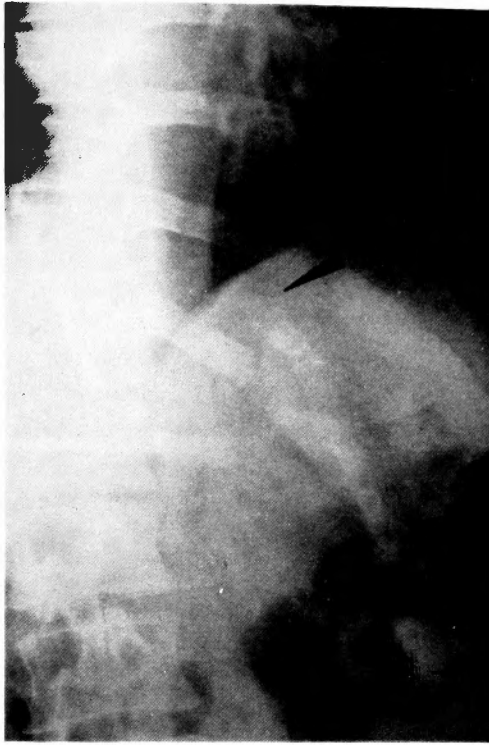
On November 3, 1980, a 28-year-old male mishandled his automobile and collided against the guard-rail of road. Several hours later, he underwent emergency laparotomy because of rupture of the liver and mesentery and perforation of the jejunum. He was re-explored due to small bowel obstruction 12 and 15 days after the initial surgery, respectively. These laparotomies were performed through vertical mid-line incision from the xiphoid process to the point of 5 cm below the navel. Although postoperative wound sepsis and partial dehiscence had occurred, he was discharged with good condition on January 18, 1981.

Complaining on lumbago, he revisited our out-patient department 203 days after the last laparotomy (June 9, 1981). Films of the lumbar vertebra incidentally revealed a calcified mass along the surgical scar (Fig. 1). The films of abdominal CT confirmed the calcification in the median anterior wall (Fig. 2). He was readmitted on June 29, 1981. He looked healthy with body weight of 68 kg. Along the upper portion of the abdominal scar, 10 cm of induration was noted. No lump was present. He complained of neither tenderness on the scar nor restriction of forward bending. The laboratory studies showed no abnormal value.

Key words: Heterotopic bone formation, Scar of the abdominal surgery, Plain film of the abdomen, Computed tomography (CT), Frequent laparotomy.

索引語: 異所性骨形成, 腹部手術後癒痕, 腹部単純写真, コンピューター断層撮影, 頻回開腹。

Present address: The Second Department of Surgery, Kinki University, Sayama-cho, Osaka, 589, Japan.



**Fig. 1.** X-ray film of the lumbar vertebra in oblique position showing heterotopic bone formation; arrows indicate the length

With a diagnosis of heterotopic bone formation in the abdominal scar, he was operated on June 30, 1981. An irregular-shaped bone with a size of  $12 \times 1.5 \times 1$  cm was resected from the upper half of scar (Fig. 3). The bone neither connected to the xiphoid process, nor adhered into the abdominal viscera. Histologically the specimen had structures of usual bone. His post-operative course was uneventful.

### Discussion

Extrasketal new bone formation has been found in the eye, lung, heart muscle, blood vessels, urinary bladder, kidney, nerve tissue, fascia, tendon, skeletal muscle, meninges, arachnoid, tonsil, thyroid, ovary, uterus, fallopian tube, penis, intestinal wall, appendix and in the dental pulp<sup>22</sup>. However, in these structures the development of the bone is not usually preceded by surgical treatment<sup>12</sup>.

Since the first report of HAYASHI<sup>8</sup>) in 1938, a total of 71 cases of heterotopic bone formation in the laparotomy scars have been reported in the Japanese literature including three of our own. Although the precise frequency of this phenomenon is not able to determine, the incidence must be much higher than the published cases because of remaining asymptomatic cases<sup>26,28</sup>). For instance, MEBIUS<sup>18</sup>) found three examples for this ossification in a series of 31 autopsies.

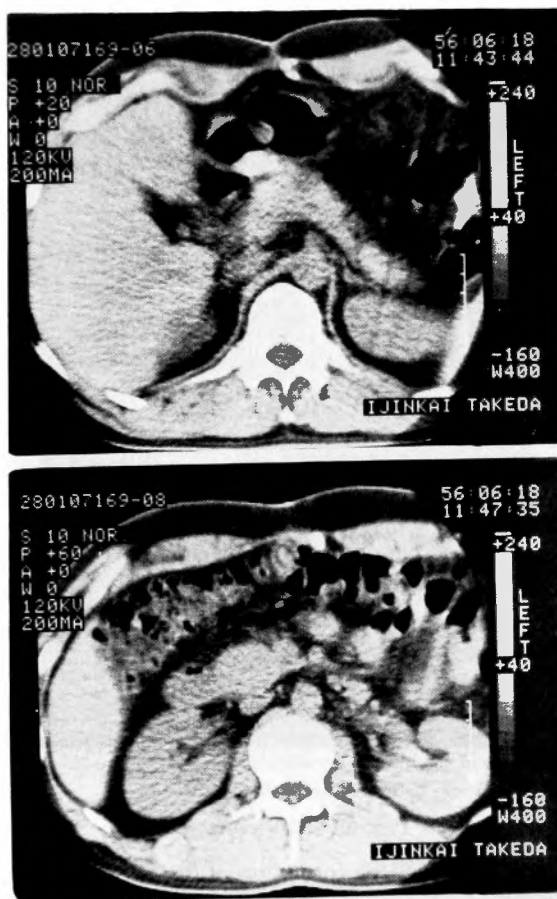


Fig. 2. Abdominal CT showing calcified mass in the median anterior abdominal wall



Fig. 3. Gross specimen of the resected bone

**Table 1.** Age and sex distributions in 71 Japanese cases

No. of pts.	Male	Female	Total
Age (yrs)			
20 - 29	4	1	5
30 - 39	3	0	3
40 - 49	11	3	14
50 - 59	17	1	18
60 - 69	18	0	18
70 - 79	7	1	8
80	1	0	1
Unknown	0	0	4
Total	61	6	71

SANDERS<sup>21)</sup> discovered six cases over a period of seven years, MARTEINSSON and MUSGROVE<sup>19)</sup> reported a total of 23 cases during 15 years period, and in Japan, seven cases in an institution were also reported<sup>26)</sup>. All these incisions were vertical, especially in mid-line, in the upper abdomen. The ossification generally showed the tendency to place more caudally in the scar of upper abdomen. In Japan, males in the fifth to seventh decades were most prevalent, and the male-to-female ratio was 10 : 1 (Table 1). The striking difference in sex incidence was reported in the ratio as 17 : 1<sup>15)</sup> or 4 : 1<sup>17)</sup>.

The diseases followed by surgery and performed operations were summarized in Table 2. Operations through the upper mid-line incision were made in 60 cases (85%), and eight cases

**Table 2.** Diseases followed by surgery and performed operations

Diseases and operations	No. of pts.
Gastric neoplasm; gastrectomy	24
exploratory laparotomy	3
Peptic ulcer; gastrectomy	13
ulcer operation	5
gastro-jejunostomy	2
Bile duct disorders; cholecystectomy	6
choledocho-lithotomy	1
Suspicious intra-abdominal disease; exploratory laparotomy	3
Esophageal carcinoma; radical resection	1
gastrostomy	1
Esophageal achalasia; Heller's operation	1
Gastric polyp; gastrotomy	1
Pancreatic lithiasis; pancreato-jejunostomy	1
Appendicitis; appendectomy	1
Transverse colon carcinoma; resection	1
Urinary bladder papilloma; resection	1
Ileus; lysis	4
Unrecorded	2

underwent operations through the upper abdominal incision, of which details were unknown. In the remainder, a 67-year-old male underwent extirpation of papilloma of the urinary bladder through the lower mid-line incision<sup>23)</sup>, a 25-year-old female received appendectomy, whose incision was not recorded<sup>14)</sup>, and another was not described the procedure.

BORRAS<sup>1)</sup> has estimated that 70 per cent of patients with heterotopic bone formation in the abdominal scar have had incisions in the upper part of abdomen. In Japan, this frequency is much higher—68 out of 71 cases (96%). Although LEHRMAN, et al<sup>15)</sup> suggested that the prevalence of peptic ulcer surgery and age factor for the characteristics of this ossification in the upper abdominal scar, the reasonable explanation has not been made for this extremely higher incidence of bone formation in the upper abdominal, especially mid-line positioned, scar in the Japanese cases, as well as for the sexual difference.

Various theories concerning this ossification have been published, among which periosteal theory and metaplastic theory seem to be preferable. The former theory is that the probable cause of this bone formation is injury to the xiphoid process above or pubis below with liberation of bone-forming cells into the wound. The latter theory means that fibrous tissue, cartilage and bone are the end products of a common mesoblastic stem, and under exceptional circumstances any connective tissue cell may revert to an embryonal state and assume new functions and properties, i.e., fibroblasts from the connective tissue may become osteoblasts and form true bone. LERICHE and POLICARD<sup>16)</sup> pointed out that bone will form in any region where there are fibroblasts, an excess of calcium salts and an adequate blood supply. The periosteal theory seems to be untenable, although some authors<sup>17, 27)</sup> prefers this theory to others. In the 39 Japanese cases recording the continuity of this ossification to the xiphoid process, only 15 cases (38%) had continuity.

KIMURA, et al<sup>13)</sup> proposed that the periosteal theory explained a portion of the metaplastic theory; if the fragment of bone was implanted into the tissue, only the periosteum survived and fibroblasts around the necrotic fragment began to make metaplasia to the bone. URATA<sup>27)</sup> also reported that osteogenesis had occurred after the implantation of various bone tissues. Whereas the metaplastic theory seems to be appropriate, none of generally accepted inducing factors has been reported. According to ABESHOUSE<sup>1)</sup>, inflammation, infection, hemorrhage, irritation of acid urine, degenerative circumscribed myositis, ossifying diathesis or tissue predisposition, impregnation of calcium salts in inflamed tissues, foreign body reaction to sutures, abnormalities in tissue chemistry, instrumental trauma to connective tissue and muscle, or periosteal injury and proliferation had been considered to be the initiating or predisposing factor responsible for the heterotopic bone formation. None of them were prevalent in the literature, for example, frequent laparotomy as is in our case showed only 7 out of 71 cases (10%) in Japan.

Some have found the ossification in the scar as early as 7 days<sup>14)</sup> and 13 days<sup>23)</sup> following surgery, while in other instances as much as 11 years<sup>26)</sup> and 17 years<sup>11)</sup> have elapsed before detection (average 18.4 months). Thirty-six out of 71 cases (51%) were discovered the ossification as early as 6 months following the surgery. There were several cases<sup>9, 11, 19)</sup> showing osteoid or premature bones in the specimens, whose extirpations were made over the period of six months

following surgery. This may indicate the midway of metaplasia.

The progress of this ossification is interesting. Most of the bone remains permanently, while in the rare cases the bone has completely absorbed and diminished<sup>17, 27)</sup>. Whereas, SUZUKI, et al<sup>24)</sup> reported two cases whose length of the bone had increased 4 times over the period of 3 and 4 years, respectively. Generally the ossification never developed beyond the length of scar, and RICH's report of impingement into the abdominal viscera<sup>20)</sup> has not been noted in the Japanese literature in spite of the association with BRAUN'S or SCHLOFFER's tumor. Neither multiple bone formation in the scars of frequent laparotomies on the different sites, nor the association of myositis ossificans in other portion of body has been reported. Hereditary predisposition is not contributory except two cases in brothers of TAMA<sup>25)</sup>. Laboratory studies usually show normal value without evidence of calcium metabolism disorder.

Heterotopic bone formation in surgical abdominal scars is usually asymptomatic, however, 19 out of 63 cases (30%) had complaints; local pain in 7 patients (11%), tenderness in 15 (24%), restriction of forward bending in 8 (53%), sense of oppression in 3 patients (5%). Mass or induration was palpated in 49 out of 63 cases (78%). Two patients complained of tenderness on the scar without palpable mass. Fourteen patients were incidentally recognized the bone during re-laparotomy against another disorder. If the bone develops long enough to make fracture, this may resolve the problem of restriction of bending<sup>6)</sup>.

The diagnosis of heterotopic bone formation in the abdominal scar in the Japanese cases were listed in Table 3. Roentgenographic verification of the ossification, first reported by BOUTON<sup>9)</sup> in 1926 and first published by SILVER<sup>22)</sup> in 1931, has been a useful diagnostic aid. The roentgenograms in the extremely oblique or tangential position were recommended for the purpose of avoiding the super-imposition on the vertebral bodies<sup>12)</sup>. Almost all of the cases were first suspected the heterotopic ossification during screening the plain films of the abdomen. Bone scintigram is also utilized to confirm the diagnosis<sup>2)</sup>. Some cases show negative shadow in the roentgenogram, and some show far longer ossification at removal than the range of super-

**Table 3.** Various preoperative diagnosis

Diagnoses	No. of pts.
Correct diagnosis	
Confirmed by operation	27
Confirmed by roentgenogram	6
Incidentally found during relaparotomy	12
Carcinoma metastasis into the abdominal wall	11
Mass or induration in the scar	8
Schloffer's tumor	2
Braun's tumor	1
Desmoid	1
Abscess in the abdominal wall	1
Found at the autopsy	1
Unrecorded	1

ficial induration.

When the abdominal CT was utilized, the calcified mass in the anterior abdominal wall was clearly demonstrated. The abdominal CT was very useful to diagnose the ossification in the asymptomatic cases who were detected other diseases with this maneuver, as well as to determine the range of ossification. The frequency of incidental discovery of the ossification may increase by use of abdominal CT.

The differential diagnosis from other calcified structures in the abdomen is relatively simple<sup>12)</sup>. If the surgery had made for malignancy, metastasis to the abdominal wall should be suspected and be eliminated. Although some exceptional cases were associated with the recurrence of carcinoma, unnecessary laparotomy may be avoided when the diagnosis of heterotopic bone formation was established preoperatively by means of roentgenogram, bone scintigram and/or abdominal CT.

Resection of the bony mass is the only known form of treatment. Irradiation for symptomatic patients reported by EIDERMAN and WARON<sup>7)</sup> is nowadays doubtful. In Japan 55 out of 71 cases (77%) underwent resection of the bone. The resected bone showed considerable variety in the shape and contours of the formation, which may be plaque-like, round, elongated, fenestrated, scissors-like, antler-like, ring-form, regular or irregular, with or without so-called pseudoarthrosis. The length of bone ranged from 1.5 to 17 cm (average 7.8 cm) in 62 Japanese cases. Histologic studies of the specimens invariably revealed true bone, usually of the cancellous type<sup>15, 22)</sup> without any report of malignant change. Only a few exceptional cases show premature bone as is mentioned before. Recurrence have never been reported after the complete removal.

Although there appears to be no contraindication to allowing the bone to remain in place, careful follow-up of the degree of ossification and symptoms of patients should be necessary.

### References

- 1) Abeshouse BS: Heterotopic bone formation following suprapubic prostatectomy. *J Urol* **59**: 50-66, 1948.
- 2) Asahi H, Iseki H, et al: Heterotopic bone formation in abdominal operation scars. *Nihon Rinsho Geka Igakukaishi* **40**: 1173-1178, 1979.
- 3) Askanazy: *Verhandl. d. deutsch. pathol. Ges.*, 1900, p. 106-cited by 1).
- 4) Borrás JA: Dos casos raros de osificación heterotópica. *Med espan* **30**: 49-55, 1953:cited by 12).
- 5) Bouton M: Contribution à l'étude de l'ossification hétérotypique dans les cicatrices opératoires. Thèse de Paris, No. 543, 1926-cited by 12).
- 6) Classen KL, Wiederanders RF, et al: Clinical and experimental observations on heterotopic osseous formation in abdominal wall scars. *Surg* **50**: 824-832, 1961.
- 7) Eidelman A, Waron M: Heterotopic ossification in abdominal operation scars. *Arch Surg* **107**: 87-88, 1973.
- 8) Hayashi M: A case of ossification in the abdominal scar of gastric carcinoma surgery. *Chiba Igakukaishi* **16**: 132, 1938.
- 9) Ishikawa K, Hachisuka K, et al: Four cases of heterotopic bone formation in laparotomy scars. *Geka* **35**: 313-316, 1973.
- 10) Kasahara Y, Yamada Y, et al: Two cases of heterotopic bone formation in the scar of abdominal surgery. *Geka Shinryo* **23**: 1289-1291, 1981.
- 11) Katayama Y, Okuda M, et al: Localized myositis ossificans due to abdominal surgery. *Nihon Shokaki Geka Gakkaishi* **11**: 124, 1978.
- 12) Katz I, LeVine M: Bone formation in laparotomy scars. *Am J Roentgenol Rad Ther Nucl Med* **84**: 248-261, 1960.



- 13) Kimura N, Komi N, et al: A case of heterotopic bone formation after laparotomy associated with Braun's tumor. *Geka* **25**: 1012-1016, 1963.
- 14) Kimura T: A case of metaplastic ossification in the abdominal wall. *Nihon Geka Gakkaishi* **57**: 1617, 1956.
- 15) Lehrman A, Pratt JH, et al: Heterotopic bone in laparotomy scars. *Am J Surg* **104**: 591-596, 1962.
- 16) Leriche R, Policard A: Some fundamental principles in pathology of bone. *Surg Gynec Obstet* **43**: 308-309, 1926.
- 17) Marteinsson BTH, Musgrove JE: Heterotopic bone formation in abdominal incisions. *Am J Surg* **130**: 23-25, 1975.
- 18) Mebius J: Die formale Genese der Knochenbildung in Bauchnarben. *Virchow Arch path Anat* **248**: 252-284, 1924-cited by 12).
- 19) Ohtsuka H, Kameya S: Two cases of heterotopic bone formation in the laparotomy scars. *Geka* **34**: 639-642, 1972.
- 20) Rich, J Hamit HF: Postoperative exostoses of the xiphoid process. Report of a case with impingement of the common bile duct. *Am J Surg* **115**: 712-715, 1968.
- 21) Sanders RL: Bone formation in upper abdominal scars. *Ann Surg* **141**: 621-626, 1955.
- 22) Silver PG: Ossification in a laparotomy wound. *Canad Med Ass J* **24**: 414-416, 1931-cited by 12).
- 23) Sugimoto S, Miyazi M, et al: Heterotopic bone formation in the operation scars. *Nihon Rinsho Geka Igakukaishi* **37**: 498-5023, 1976.
- 24) Suzuki T, Horikoshi K, et al: Four cases of heterotopic bone formation in the scar of abdominal surgery. *Nihondaigaku Igakuzasshi* **33**: 137-139, 1974.
- 25) Tama L: Heterotopic bone formation in abdominal surgical scars. A report of two cases in brothers. *JAMA* **197**: 219-221, 1966.
- 26) Udaka H, Saito T, et al: Seven cases of heterotopic bone formation in laparotomy scars. *Nihon Shokaki Geka Gakkaishi* **10**: 191-195, 1977.
- 27) Urata K: Histochemical studies on ectopic bone formation. *Nippon Geka Hokan* **29**: 1258-1271, 1960.
- 28) Watkins GL: Bone formation in abdominal scars after xiphoidectomy. *Arch Surg* **89**: 731-734, 1964.
- 29) Wong J, Lowenthal J: Heterotopic bone formation in abdominal scars. *Surg Gynec Obstet* **140**: 893-895, 1975.

## 和文抄録

## 腹壁手術創癒痕内異所性骨形成

近畿大学医学部第二外科学教室 (主任: 久山 健教授)

笠原 洋, 山田 幸和, 田中 茂, 園部 鳴海, 久山 健

東海大学医学部第二解剖学教室 (主任: 清木勘治教授)

今 西 嘉 男

身体の各部位の内臓, 器官などに異所的に化骨現象が生ずること自体はそう稀なものとはいえない。しかしこれらの臓器の化骨は手術侵襲後にみられる訳ではない。いわゆる腹壁手術創の癒痕内に異所的に化骨を生ずる例の文献的報告は非常に少なく, 本邦では自験3例を含めて71例のみであった。無論無症状で発見されていない例も多いと思われる。その成因として化成

説が妥当と思われたが, 間葉系細胞の骨細胞への化成をもたらす原因として諸説がみられるが, 未だ定説はみられない。

28歳男子の1例を報告し, 本邦71例の集計で男女比10:1, 40~60歳代の男性に多く発見されること, 上腹部手術後の癒痕内に発生するものが圧倒的に多いこと, その他について述べた。