

Title	An Isolated Traumatic Hernia of Right Diaphragm Presenting a Mashroom-shaped Lesion
Author(s)	IDA, TAKESHI; YAMADA, KINYA; NAKAGWA, MASAHISA; MORIMOTO, TAISUKE; OKAMOTO, YOSHIFUMI; NAKASE, AKIRA
Citation	日本外科宝函 (1981), 50(6): 885-890
Issue Date	1981-11-01
URL	<a href="http://hdl.handle.net/2433/208562">http://hdl.handle.net/2433/208562</a>
Right	
Type	Departmental Bulletin Paper
Textversion	publisher

## An Isolated Traumatic Hernia of Right Diaphragm Presenting a Mashroom-shaped Lesion

TAKESHI IDA, KINYA YAMADA, MASAHISA NAKAGAWA, TAISUKE MORIMOTO,  
YOSHIFUMI OKAMOTO, and AKIRA NAKASE

The 1st Department of Surgery, Shimane Medical University

Received for Publication, Aug. 10, 1981.

### Introduction

Diaphragmatic hernia secondary to a blunt trauma or a penetrating trauma is often life-threatening and rarely occult. The right-sided diaphragmatic hernia has been estimated to be rare due to the protection by the dome of the liver and to occur only one twentieth or less of the case of the left side<sup>2,5,6)</sup>. Most series are usually ascertained with severe injuries of the pelvis, extremities or head as well as of intra-abdominal organs. But, because of the reason that the right diaphragmatic hernia is often accompanied with severe other lesions or some patients are asymptomatic in the latent phase, it is often missed during the initial hospitalization.

We will report a case of a traumatic right diaphragmatic hernia with a strange mashroom-shaped lesion on the right diaphragmatic leaf having been asymptomatic for eight years following the traffic accident.

### A Case Report

#### *Clinical history*

A 62-year-old man sustained a blunt trauma in the right lateral chest and the right upper quadrant of an abdomen by the traffic accident in 1971. He was admitted to an emergency unit three hours following this accident, where he was found to have a slight subcutaneous emphysema of the right chest and a microscopic hematuria. A chest roentgenogram disclosed only a mild effusion of the right lower pleural cavity, but with neither an elevated diaphragm nor a rib fracture. Even though accompanied with these findings, his vital signs were stable and these findings subsided gradually. Therefore, any surgical procedure was not performed. He was asymptomatic for eight years following this accident. But he had a sudden episode of severe epigastric pain during drinking Sake on Nov. 20, 1979. Two days after this episode, he was admitted to another hospital for further examinations, where gallbladder stones and an abnormal shadow on the right diaphragmatic leaf were pointed out. He consulted with us for further examination concerning this abnormal shadow and for a surgical treatment of the gallbladder.

---

Key word: Traumatic diaphragmatic hernia.

索引語: 外傷性横膈膜ヘルニア.

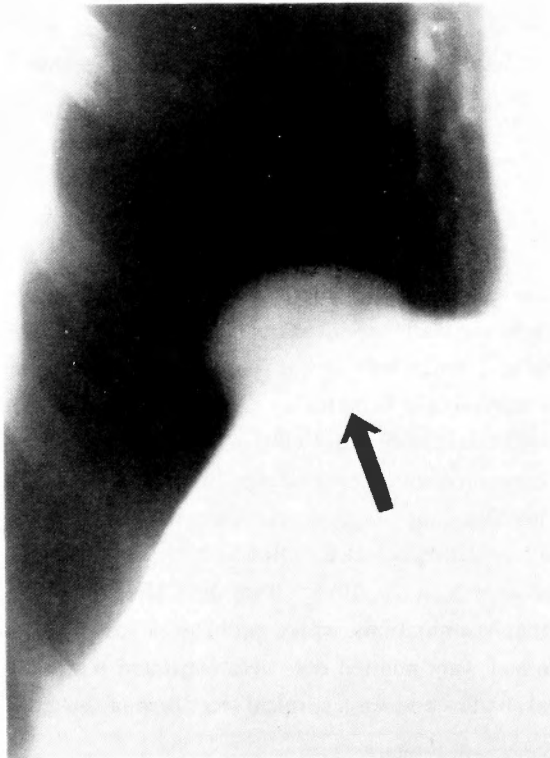
Present address: The 1st Department of Surgery, Shimane Medical University, Izumo Shimane, 693, Japan.

*Clinical examinations*

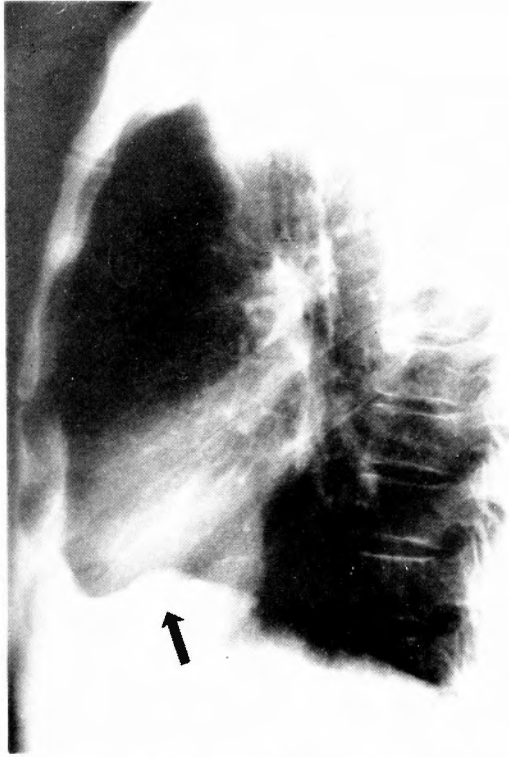
Routine laboratory data were within normal values and  $\alpha$ -Fetoprotein was also negative. Drip infusion cholangiogram showed two stones in the gallbladder and a decreased opacification of the gallbladder. Tomogram and plain roentgenogram of the abnormal shadow of the right chest are shown in Figs 1 and 2. A well-defined mushroom-shaped tumor, locating on the right diaphragm as shown in these films, made us suspect an accessory lobe of the liver. According to the celiac angiography (not presented), the angiogram of arterial and capillary phases of the right hepatic lobe continued smoothly to the area of this tumor and there was no neoplasma in this region. A liver scintigram shown in Fig. 3 led to a preoperative diagnosis of an accessory lobe of the liver.

*Findings of surgical procedures*

The abdominal cavity was entered through an upper midline abdominal incision on Jan. 29, 1980. As the moderately enlarged gallbladder and some gallbladder stones were ascertained, a routine normograde cholecystectomy was performed. After the cholecystectomy, the dome of a right hepatic lobe was carefully examined. A round and smooth-surfaced protrusion on the right lobe, about 4 cm in diameter, located at between 3 and 7 cm laterally from the falciform ligament and between 7 cm and 11 cm posteriorly from the hepatic margin, could be easily



**Fig. 1.** An antero-posterior view of the tomogram of the mushroom-shaped shadow on the right diaphragm.

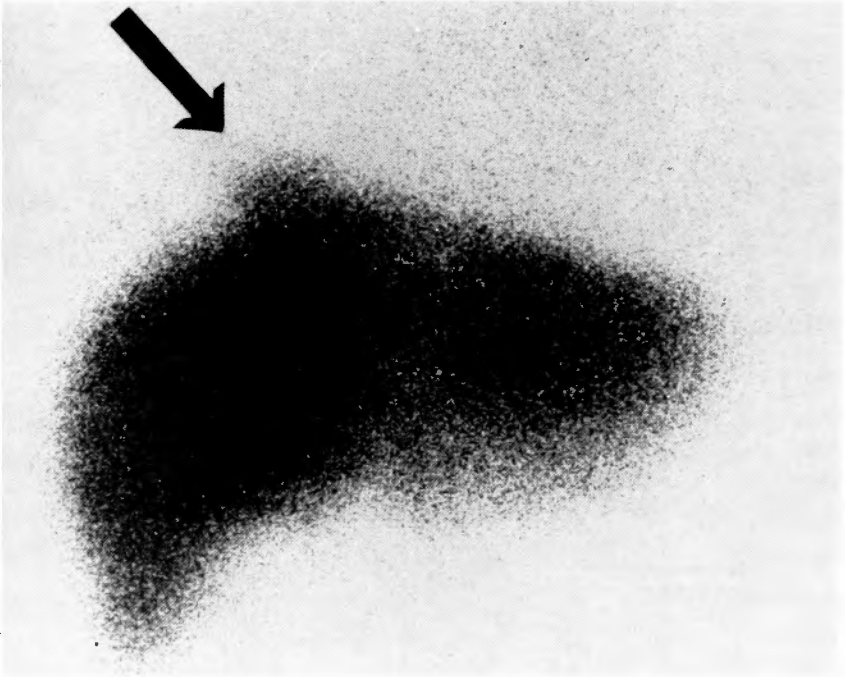


**Fig. 2.** A lateral view of the chest with the protruding shadow on the diaphragm.

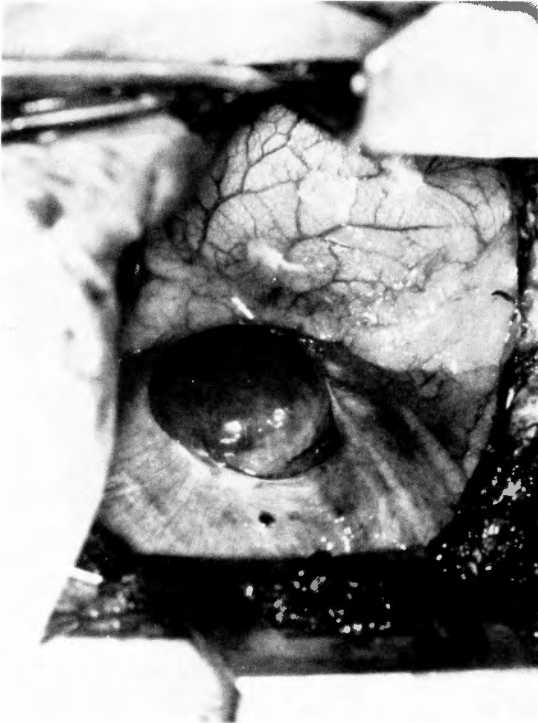
visualized by the upward traction of the right costal margin. The color of the surface of this tumor was similar to that of the normal liver, therefore biopsy was not performed. Because an anterior half of this tumor penetrated the right diaphragm sharply, the abdominal cavity continued directly to the pleural cavity through this opening. The edge of the diaphragmatic opening was round and well-defined as punched-out, and also contained only a slight fibrinous adhesion to the ring of compression where this liver tumor was firmly wedged through this opening. The anterior half of this protrusion could be easily seen, but the entire anatomical relationship of the posterior half of the tumor to the diaphragm was not clear by this approach. Therefore, a right anterolateral thoracotomy was additionally performed. This procedure made us easy to see the opening of the right diaphragm and the entire margin of this opening (Fig. 4). The entire shape of the opening was oval, and could be safely repaired with interrupted, non-absorbable mattress sutures. A preoperatively-shown abnormal shadow on the routine chest film became unclear on the 8th postoperative day. A postoperative course was uneventful and he was discharged on the 20th postoperative day.

### Comment

Traumatic diaphragmatic hernias usually occur with severe concomitant multiple injuries of various organs and soft or bony tissues as well as an abdomen, and their frequency is reported



**Fig. 3.** A liver scintigram is a postero-anterior view. A protrusion on the right lobe of the liver is clearly demonstrated.



**Fig. 4.** The view of the right diaphragmatic defect and the eventrated liver lobe seen through the thoracotomy incision of the VIIth intercostal space.

as 4.5% in such cases as nonpenetrating abdominal injuries<sup>7)</sup>. Generally, left-sided hernias are more common than those of the right side and are said to be approximately between twenty and fifty times of the right side. Because traumatic diaphragmatic hernias are also rarely asymptomatic, a correct diagnosis is often difficult and delayed unless elevated diaphragm or a mass lesion of the right pulmonary area can be initially disclosed by a chest roentgenogram. Recently, a rare isolated right diaphragmatic hernia without multiple injuries was reported<sup>8)</sup>. Thus, only suspicion of a traumatic right diaphragmatic hernia can allow us to diagnose this correctly in such cases.

According to Epstein et al., the average time between an initial injury and repair of the right side hernias was about nine years in the cases with late recognition, and early diagnosis of traumatic right diaphragmatic hernia was made in only 6 cases among 36 cases reported in the literature<sup>4)</sup>. Early diagnosis is necessary even in asymptomatic cases, because various symptoms which depend on herniated organs, occur suddenly, or because repair is more difficult due to adhesions to liver, lung and other organs. A correct diagnosis of our case was overlooked during an initial hospitalization, though the subcutaneous emphysema and the mild effusion were shown. A possible reason for a missed diagnosis may be that these clinical findings subsided gradually without severe complications, and that a further examination was not consequently performed. A preoperative definite diagnosis was not made even with the assist of various clinical examinations as described. These examinations showed only the presence of the protruding liver tumor with a non-neoplastic character, and a correct diagnosis could possibly have been made by asking carefully to the patient about the trauma accident.

Although an abnormal shadow on the right diaphragm as in this case is roentgenologically very strange, a similar case of isolated right diaphragmatic hernia has already been reported<sup>3)</sup>. In our case, a chest X-ray film taken just before the discharge of the initial hospitalization did not show such a protruding shadow. Therefore, the accessory lobe of the right hepatic lobe may have protruded very slowly during eight years possibly due to the negative pressure on the liver surface through the slightly lacerated diaphragm.

On the other hand, a transthoracic approach is generally preferred in the cases of delayed diagnosis because of various adhesions<sup>1,9)</sup>. In our case, after an appearance of the right diaphragmatic hernia was ascertained through an upper midline incision for cholecystectomy, safe and successful repair of the ruptured diaphragm was facilitated through an additional transthoracic approach.

### Summary

A case of a traumatic right diaphragmatic hernia of which chest X-ray showed a strange shadow, was presented. A mushroom-shaped shadow in the midregion of the right diaphragm was pointed out by chance after an episode of gallbladder stones, and various examinations made us diagnose preoperatively as an accessory lobe of the right hepatic lobe. But the definite diagnosis was a rare traumatic right diaphragmatic hernia which had been asymptomatic for about eight years.

### Acknowledgments

We thank Miss M. KAMEDA, T. ITAGAKI and some members of the photo-service center of our university for their friendly assistance in publishing this article.

### References

- 1) Andrus CH, Morton JH: Rupture of diaphragm after blunt trauma. *Am J Surg* **119**: 686-693, 1970.
- 2) Bernatz PE, Burnside AF Jr, Clagett OT: Problem of the ruptured diaphragm. *JAMA* **168**: 877-881, 1958.
- 3) Davis SF: Right-sided posttraumatic diaphragmatic hernia presenting as a coin lesion. *South Med J* **72**: 1211-1212, 1979.
- 4) Epstein LI, Lempke RE: Rupture of the right hemidiaphragm due to blunt trauma. *J Trauma* **8**: 19-28, 1968.
- 5) Harrington SW: Traumatic diaphragmatic hernia. *Surg Clin North Am* **30**: 961-970, 1950.
- 6) Meads GE, Carroll SE, et al: Traumatic rupture of the right hemidiaphragm. *J Trauma* **17**: 797-801, 1977.
- 7) Rodkey GV: The management of abdominal injuries. *Surg Clin North Am* **46**: 627-644, 1966.
- 8) Salomon NW, Fukoshi CF: Isolated rupture of the right diaphragm with eventration of the liver. *JAMA* **241**: 1929-1930, 1979.
- 9) Schwindt WD, Gale JW: Late recognition and treatment of traumatic diaphragmatic hernias. *Arch Surg* **94**: 330-334, 1967.

### 和文抄録

## 胸部レ線上特異な陰影を呈した肝副葉の1症例

島根医科大学第一外科 (主任: 中瀬 明教授)

井田 健, 山田 公弥, 中川 正久, 森本 泰介  
岡本 好史, 中瀬 明

右下肺野横隔膜上にキノコ状陰影があるのを偶然発見された62才男性の一症例。術前診断は肝副葉であったが術中診断は外傷性右横隔膜ヘルニアであった。こ

の症例は受傷后八年間無症状に経過し、その間徐々に肝副葉が形成されたものと推定される。