

Title	Application of a Microwave Tissue Coagulator to Hepatic Surgery : The Hemostatic Effects on Spontaneous Rapture of Hepatoma and Tumor Necrosis
Author(s)	TABUSE, KATSUYOSHI; KATSUMI, MASA HARU
Citation	日本外科宝函 (1981), 50(4): 571-579
Issue Date	1981-07-01
URL	http://hdl.handle.net/2433/208547
Right	
Type	Departmental Bulletin Paper
Textversion	publisher

Application of a Microwave Tissue Coagulator to Hepatic Surgery —The Hemostatic Effects on Spontaneous Rupture of Hepatoma and Tumor Necrosis—

KATSUYOSHI TABUSE and MASAHARU KATSUMI

Department of Gastrointestinal Surgery, Wakayama Medical College, Wakayama

(Director: Prof. Dr. MASAHARU KATSUMI)

Received for Publication, April 10, 1981.

Introduction

The authors have developed a microwave tissue coagulator which is applicable to hepatic surgery. On June 10, 1980, the coagulator was applied in order to stop the intraperitoneal massive hemorrhage, which had been induced by spontaneous rupture of a hepatoma in a 60-year-old male patient with liver cirrhosis. The success in coagulation and hemostasis was obtained, and the survival effects were brought forth. Further, its application to the other three cases led to the confirmation of efficacy, safety, and convenience of the coagulator.

The experimental study of the surgical procedure utilizing^{1,2)} this apparatus in hepatic surgery has already been described. In the experiments with rabbits, it was ascertained that the maximum of hemostatic vascular diameter was 3 mm, and that the thickness of the coagulated necrosis was 10 mm. Furthermore, the safety of this method was confirmed on the basis of the results from the histological examination of the necrotic tissue and biochemical examination of serum in the time course.

In the present paper, the authors describe the method of treating ruptured hepatoma with liver cirrhosis, which is difficult to resect, but can be salvaged from bleeding and lead to tumor necrosis.

Apparatus

The microwave generator used is microtron MT-7P(Heiwa Electronics Co., Ltd.) of frequency of 2,450 MHz and the maximum output of 150 W. A monopole antenna is connected with the end of coaxial cable which is equipped with an electromagnetic timer and a foot switch.

Surgical Procedure

The monopole antenna is inserted directly into the tissue. The conditions of irradiation are variably adjusted in a range of 40 to 60 watts and during the period of 30 to 60 second so as to be

Key words: Microwave surgery, Microwave tissue coagulator, Spontaneous rupture of hepatoma, Hepatectomy.

索引語: マイクロ波外科, マイクロ波凝固装置, 肝癌自然破裂, 肝切除術.

Present address: Department Gastrointestinal Surgery, Wakayama Medical College, 7-Bancho Wakayama Wakayama, 640, Japan.

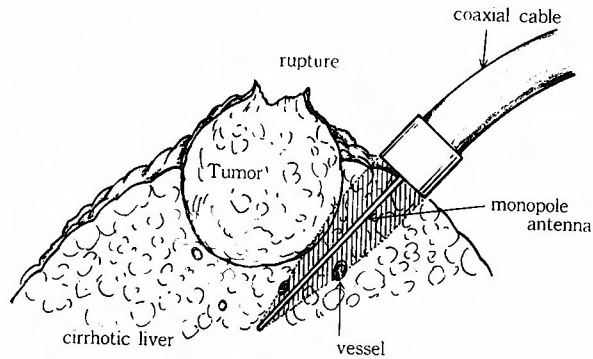


Fig. 1. Schema of the peroperative procedure for hepatoma rupture.

suitable to coagulate the hepatic parenchyma, the insertion is begun at the surroundings of a tumor and the coagulation is caused so as to surround the tumor in turn. The depth of the insertion depends upon the site, size, and form of the tumor, ranging in length from 3 cm to 5 cm. The antenna is the same in diameter as a 21 gauge injection syringe, and teflon-processed so as to prevent the tissue adhesion when inserted at the liver surface quietly. Some antenna are sustained a slight resistance on the way. At that time, the antenna tip should be a little shifted, other wise the insertion site should be changed so that the antenna base might be inserted. The antenna can be inserted into the tumor itself, but such insertion should be avoided when the tumor tissue is very fragile. It is possible to prevent the blood-stream metastasis of tumors, when the insertion is carried out following the sufficient coagulation around the tumor. In such a case as the antenna insertion into the portal or hepatic veins of diameter of 3 or more mm fails in coagulative hemostasis, the antenna extraction naturally leads to hemorrhage at the extraction pinhole. However, the press around the pinhole and the shift of insertion give rise to coagulation, resulting in hemostasis (Fig. 1).

Report of Cases

Case 1: A 60-year-old man was diagnosed as having had liver cirrhosis and diabetes mellitus and often received the treatment. He complained of acute right hypochondalgia and shoulder pain, and was admitted to the department of internal medicine of the hospital to which the authors belonged on June 3, 1980. After the admission, he has been shocked, with decreased hematocrit, and developed abdominal fullness. The peritoneal puncture disclosed bloody ascites. The hemorrhagic tendency and splenomegaly were noted. On June 10, laparotomy disclosed 5,000 ml of fresh blood, remarkable liver cirrhosis, and a tumor mass of about 8 cm in diameter. The hemorrhage from the tumor at the posterior segment of right lobe prevented hepatectomy and failed to give hemostatic effects, but the use of the coagulator led to the success in coagulation around the tumor and in hemostasis (Fig. 2). The coagulation was carried out around the tumor in the left lateral segment though it was incomplete. Although the postoperative course was favorable, the patient died of hepatic failure on November 19, 1980.

Autopsy: The coagulated necrosis assumed a white-yellow color; the border was replaced by the connective tissue; and the tumor in the right lobe reduced in size to $3 \times 3.5 \times 3.5$ cm. The tumor in the left lobe was of size of $10 \times 9 \times 6$ cm, showing no change from the size at laparotomy (Fig. 3). However, the central area fell into a necrotic state while the presence of tumor was noted only around the capsule. The histological diagnosis were hepatocellular carcinoma of Edmondson II or III type and postnecrotic liver cirrhosis.

Case 2: A 48-year-old man developed sudden right shoulder pain and right hypochondralgia on August 9, 1980. The physical examination disclosed tachycardia, reduction in blood pressure, anemia, muscle defence, and Blumberg's sign. Then, the patient was admitted to the hospital to which the authors belonged. On August 10, laparotomy was performed on the suspicion of acute pancreatic necrosis. The laparotomy disclosed fresh blood of approximately 5,000 ml retained in the abdominal cavity; remarkable liver cirrhosis; a mass of egg-size in the medial segment of left lobe; and the infiltration and adhesion of the tumor to the lower surface of the diaphragm. And the hemorrhage induced by tumor rupture was noted (Fig. 4). Then coagulation around the tumor led to hemostasis, resulting in the tumor coagulation (Fig. 5). The pathological diagnosis proved hepatocellular carcinoma of Edmondson II type, and portal liver cirrhosis.

Second look Operation: Four months after operation, a high value of α -fetotrotein and an accelerated function of the spleen were noted. The second laparotomy revealed the mass in the first operation reduced in size and showed a white-yellow color. Thus, the coagulation was performed again around the discolored area and then enucleation of the tumor was carried out (Fig. 6). As a result, the pathological diagnosis proved the coagulation necrosis and degeneration of the tumor cells (Fig. 7). Splenectomy improved pancytopenia. The patient was discharged from the hospital, three weeks after operation (Fig. 8).

Case 3: A 48-year-old man had been diagnosed as having liver disturbance and often had received the treatment. He had complained of lower abdominal pain for several years before June 27 when he complained of epigastralgia and right hypochondralgia and was admitted to a hospital on diagnosis. Pallor of the face and abdominal fullness were as remarkable as indicated bloody ascites. On the basis of diagnosis of hepatoma rupture, and emergency operation was performed at the hospital by the authors who carried the coagulator with them. Fresh blood ascites of 5,000 ml was retained in the abdominal cavity, and liver cirrhosis was remarkable. A mass of egg-size was noted in the medial segment of left lobe, and the hemorrhage induced by the tumor ruptured was noted. The coagulation was performed in the area around the tumor and in the tumor itself and the laparotomy was concluded that hemostasis was succeeded in. The following hemorrhage was not seen postoperatively. Although the patient could take food orally and appeared healthy, he suffered acute hepatic failure and suddenly died. The histological diagnosis was hepato-cellular carcinoma of Edmondson I type.

Case 4: A 40-year-old man had been under treatment on the basis of diagnosis of chronic hepatitis for two years. However, the symptom was not improved and what is worse, the abdominal fullness was aggravated. The patient complained of right shoulder pain 10 days before

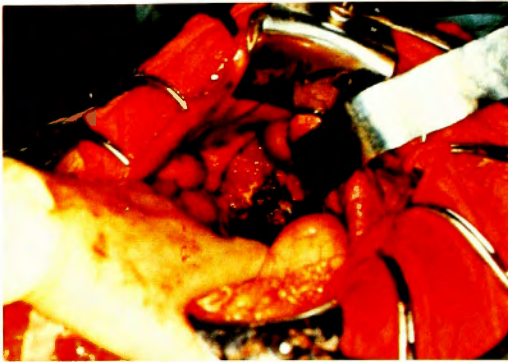

Fig. 2. Peroperative photo in case 1 showing a ruptured hepatoma at the posterior segment of the right lobe after coagulation hemostasis.

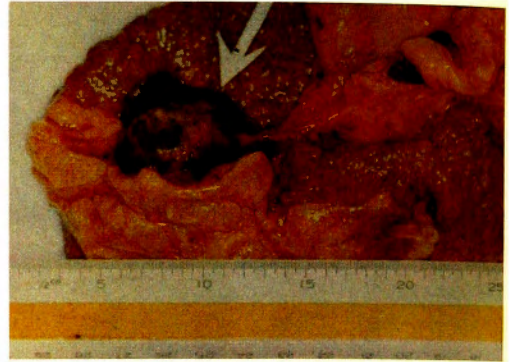

Fig. 3. Photo taken at autopsy in case 1. The arrow shows a hepatoma which underwent coagulation necrosis and reduced in size.

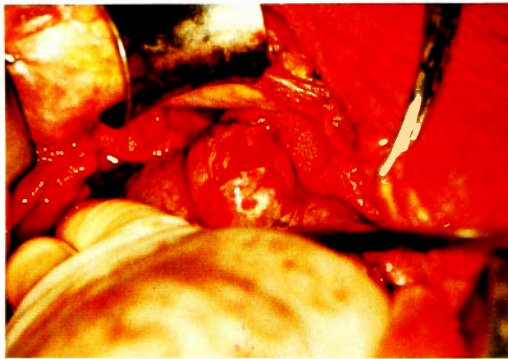


Fig. 4. Peroperative photo in case 2 showing the site of rupture of a hen egg sized hepatoma.

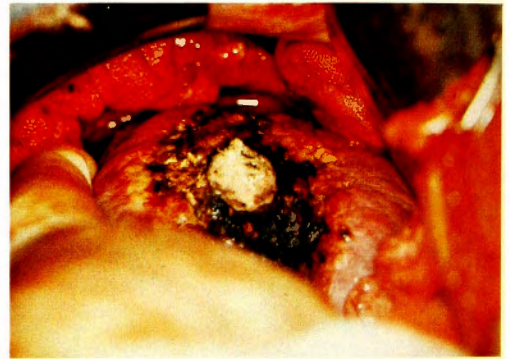


Fig. 5. Peroperative photo in case 2. The lesion and its surroundings were coagulated with this device. The regions necrotized by coagulation were degenerated to present a yellowing white color.

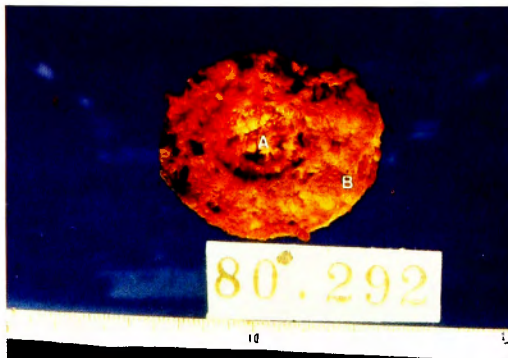


Fig. 6. Photo of the tissue block excised by second look operation in case 2. The tumor A was reduced in size due to the coagulation necrosis of its central part. The cirrhotic liver tissues B surrounding the tumor also underwent coagulation necrosis.

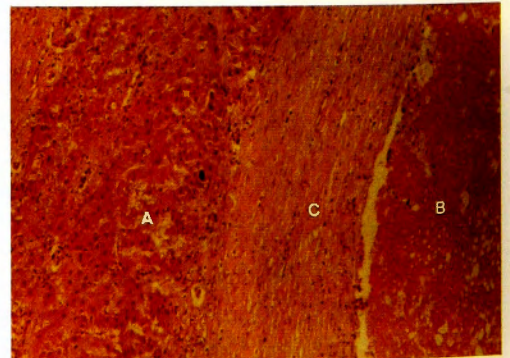


Fig. 7. Microscopical photo of the tumor excised in case 2 (hematoxylin eosin stain). A: Hepatocytes necrotized by coagulation. B: Tumor cells necrotized by coagulation. C: Tissues surrounding the tumor.

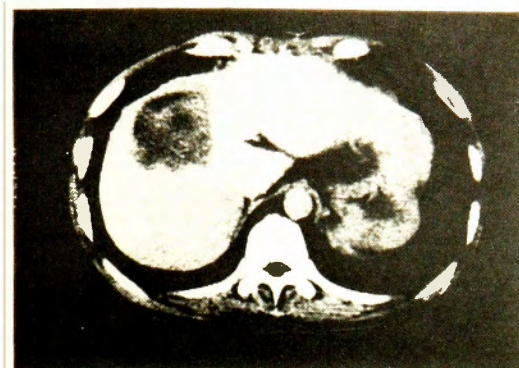


Fig. 8. Computed tomogram obtained 1 month after operation in case 2. The low density area corresponds to the site where the tumor existed until excised.

operation, but had no abdominal pain. When jaundice developed, he was admitted to the department of internal medicine of the hospital to which the authors belonged. Then, he was introduced to the authors on the suspicion of hepatoma rupture as well as on the basis of established diagnosis of bloody ascites, and then an emergency operation was performed. Bloody ascites of 12,000 ml was noted in the abdominal cavity and a tumor of fist-size was noted in the medial segment of left lobe. Remarkable liver cirrhosis was found. The coagulation around the tumor led to the success in hemostasis. Although the general conditions were good postoperatively, jaundice was aggravated. Furthermore, total bilirubin rised to 20 mg/dl. On the 17th postoperative day, the patient died of hepatic failure.

Autopsy: No hemorrhage was seen in the abdominal cavity. The tendency toward the reduction in tumor was noted. However, the infiltration extended from the intrahepatic duct to the common hepatic duct. In addition, embolism was noted in the portal vein as well as in the hepatic vein (Fig. 9). The border between the coagulated necrosis and the residual hepatic tissue sharply demarcated (Fig. 10). The scope of thermal effect was 10 mm in width. It was

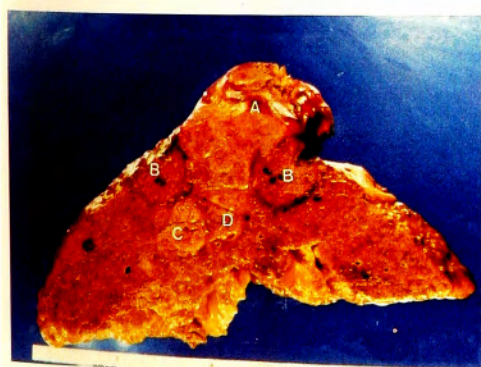

Fig. 9. Photo of the cross section of the liver obtained autoptically in case 4.
A: Tumor. B: Coagulated region. C: Tumor invasion into the hepatic duct.
D: Intravascular tumor embolism.

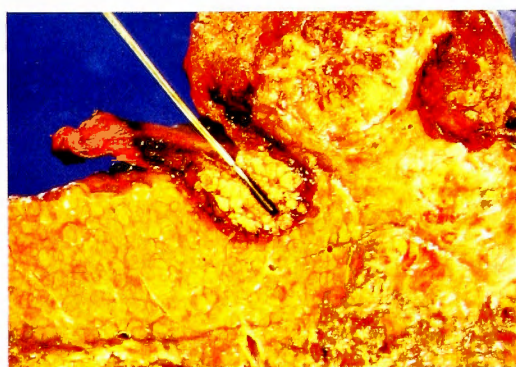


Fig. 10. Magnification of Figure 9, B. The coagulated region in the neighborhood of an antenna was well demarcated from liver tissues.

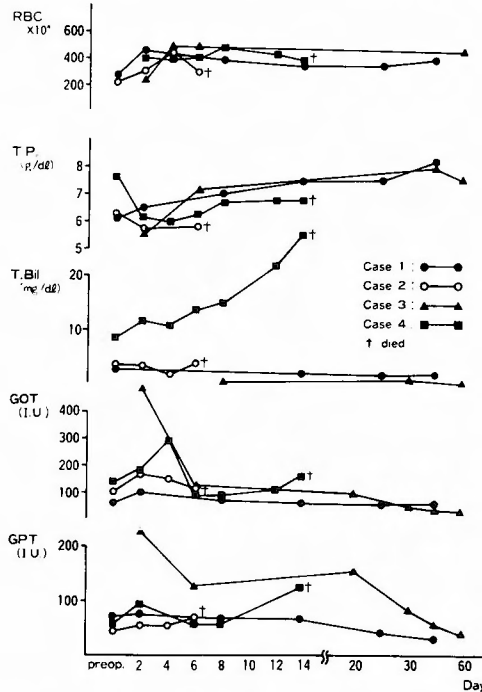


Fig. 11. Postoperative courses in the individual cases.

found that the coagulation around the tumor is effective. The hepato-cellular carcinoma of Edmondson III type and postnecrotic liver cirrhosis.

Postoperative Course

The transitional increase in serum GOT and GPT levels was seen, but the levels returned to the normal levels one week later. In no cases, the coagulator-specific postoperative course and complications were noted. The favorable courses were seen without any postoperative hemorrhage. The patient of case 3 was in the final stage of severe obstructive jaundice which was induced by tumoral growth in the hepatic duct. The patient of case 2 is alive now. The postoperative management consisted of glucose insulin therapy, fresh plasma therapy, lactulose administration and other preventive procedures of hepatic failure (Fig. 11).

Discussion

Spontaneous rupture of primary hepatoma is never a rare complication. Various other authors' reports on the spontaneous rupture are as follows: *Berman*²⁾ reported 8%; *Ong et al.*⁹⁾ reported 14.5%; *Lin et al.*⁶⁾ reported 8%; *Kuo et al.*⁵⁾ reported 13%; *Nakajima et al.*⁸⁾ reported 3%; and *Shimoyama et al.*¹¹⁾ reported 14.0%. Its incidence in Asia and Africa is comparatively high.

The clinico-pathological symptoms vary with the progress of tumor and degree of hepatic disturbance. In the cases of hepatoma rupture, the hemorrhage in the abdominal cavity develops

suddenly, showing a state of abdomen. Thus, laparotomy is often performed without any pre-operative established diagnosis. Since former times, the following surgical procedures have been employed as the treatment of hepatoma rupture; (1) primary hepatectomy, (2) only hemostasis in consideration of the general condition and (3) hepatic artery ligation. In the cases in which hepatectomy could be performed, some cases were expected to survive. Thus, some authors encourage primary hepatectomy.

However, most of the cases in the present study were of advanced cancer associated with remarkable liver cirrhosis which had a strong hemorrhagic tendency. Furthermore, in many cases, hepatectomy could not be performed on account of the site of tumor mass, or the bad general condition. The hemorrhage induced by necrotic rupture in the tumor itself was seen in the bleeding sites in the present study.

Hepatoma is supplied by the blood through the two pathways of the hepatic arteries and the portal veins. However, the predominancy of the artery increases with the growth of hepatoma. It is reported that the ligation of hepatic artery connected with the tumoral region give rise to the reduction of the tumor and to the survival effect. However, no report has been made on the evaluation of the results cases with hepatoma rupture. Although arterial blood is predominant in hepatoma focus, intra-hepatic circulation sometimes gives rise to the formation of a shunt between arterial and portal circulation. It is not assumable that the control of hemorrhage could not be complete.

*Shirabe et al.*¹⁰⁾ have maintained that though the ligation of hepatic artery branch is not problematic, the ligation of hepatic proprial artery is very dangerous during the period of formation of colateral circulation or in the cases with portal obstruction.

Portal blood supplies the circulation in the peripheries of hepatic tumor. Therefore, it is natural that the hemorrhage of the portal blood occurs at the time of hepatic tumor rupture. *Honjo et al.*³⁾ have maintained that the ligation of portal vein is effective in the cases which hepatectomy cannot be performed.

In the present study, the coagulator was applied to the cases with difficulty in grasping the preoperative state. For example, jaundic and ascites were remarkable, while the emdolism in the portal branch was vague, in the cases with liver cirrhosis as seen in case 3 and 4. The portal pressure was accelerated as seen in case 1 and 2. Hemostasis was completely performed when rupture hemorrhage occurred in the site which could be manipulated. As demonstrated in case 1 and 2, tumor-reducing effect and necrotic effect were obtained. Sometimes, enucleation could be performed as demonstrated in case 2. Further, as demonstrated in case 4, the border of the coagulated necrosis was clear when the coagulator was employed. The coagulator could be used safety even when the portal veins were in a safety of embolism. Accordingly it is assumed that the coagulator in the present study is no less effective when the ligation of the artery or the portal vein.

As shown in case 2 in the present study, even isolated, relatively small hepatoma ruptures. Accordingly, it is also assumed that the biological properties of tumor are related to the rupture rather than the size of tumor. And then, in this case the possibility of the second look operation

was demonstrated and the surgical detriment. When ever the physical strength strong enough to bear probe laparotomy is prepared, the risk resulting from the use of the coagulator can be neglected. Since not only inoperable cases but also curable cases are included in such case, it is desirable to perform laparotomy positively even if the diagnosis and the tumor site and size are vague preoperatively. Besides the application to hemostasis, the hepatectomical application will lead not only to a minimum hemorrhage but also to the avoidance of complication of biliary leakage. Further more, it is regarded as a new operative procedure, which is applicable to the operations of such parenchymal organs as the spleen, kidney, and pancreas in addition to the liver.

Conclusion

The microwave tissue coagulator developed by the authors was applied to the treatment of 4 cases with spontaneous rupture of hepatoma. The excellency of hemostatic and tumor-nectotic effects was confirmed on the basis of autopsy in two cases and second look operation in one case. It is concluded that the coagulator is useful for the clinical application to hepatic surgery, and that the surgical therapy of hepatic tumor can be extended in the indication of the coagulator.

References

- 1) Balasegaran M: Complete hepatic dearterialization for primary carcinoma of the liver. Report of twenty-four patients. *Am J Surg* **124**: 340-344, 1972.
- 2) Berman C: Primary carcinoma of the liver. A study in incidence, clinical manifestation, pathology and aetiology. London, HK Lewis and Co., Ltd. p. 27, 1951.
- 3) Honjo K: Surgery of the liver, Pancreas and biliary tract. Tokyo Nankodo. p303, 1980. (in Japanese)
- 4) Kasai Y: Indication of ligation of hepatic artery for Hepatoma. *J Jpn Soc Cancer Ther* **5**: 27, 1970. (in Japanese)
- 5) Kuo TP, Yang ZT, et al: Twelve cases of rupture of hepatoma. *J Formosan Med Assoc* **69**: 425-437, 1970.
- 6) Lin TY, Hsich CM: Study on primary carcinoma of the liver, clinical observations on 63 cases with 18 hepatectomies. *J Formasan Med Assoc* **71**: 323-344, 1962.
- 7) Murray-Lyon, LM Dawson, et al: Treatment of secondary hepatic tumors by ligation of hepatic artery and infusion of cytotoxic drugs. *Lancet*, **II**: 172-175, 1970.
- 8) Nakashima S and Terawaki A: Surgical therapy of Hepatoma. *Clin Surg* **24**: 161-172, 1969. (in Japanese)
- 9) Ong GB and Taw JL: Spontaneous rupture of hepatocellular carcinoma. *Brit M J* **4**: 146-149, 1972.
- 10) Shirabe J, Abe H and Shimoyama, et al: Ligation of hepatic artery. *Surgery* **37**: 360-366, 1975. (in Japanese)
- 11) Shimoyama T, Kitasato S: Spontaneous rupture of the primary liver cancer-proposal of the clinical pictures and its surgical significance. *J P S S* **39**: 780-786, 1970. (in Japanese)
- 12) Tabuse K: A new operative procedure of hepatic surgery using a microwave tissue coagulator. *Arch Jpn Chir* **48**: 160-172. 1979.

和文抄録

マイクロ波組織凝固装置の肝外科臨床への応用
—肝癌自然破裂に対する止血および腫瘍壊死効果—

和歌山県立医科大学消化器外科

田伏 克惇, 勝見 正治

著者らが開発したマイクロ波組織凝固装置を用い、外科的治療の困難な肺癌の自然破裂4例に応用し、その止血および腫瘍壊死効果の優れている点を2例の剖検、1例の second look operation にて確認した。腫瘍

の無血的摘除の可能であった症例は、現在も生存中であり、他の3例は1週間から5カ月間の延命効果を認めた。また本装置は肝腫瘍治療の外科的治療の適応拡大の期待しうることを論じた。