

Title	Monostotic Fibrous Dysplasia of the Rib
Author(s)	MINAMI, KAZUAKI; OKADA, YOSHIO; NAMIKAWA, SHOJI; NAKAJIMA, MASAKI; MORI, ATSUMI; HIGO, SHOGORO; SONO, JUN
Citation	日本外科宝函 (1981), 50(3): 516-525
Issue Date	1981-05-01
URL	<a href="http://hdl.handle.net/2433/208530">http://hdl.handle.net/2433/208530</a>
Right	
Type	Departmental Bulletin Paper
Textversion	publisher

## Monostotic Fibrous Dysplasia of the Rib

KAZUAKI MINAMI

The 2nd Department of Surgery, Faculty of Medicine, Kyoto University

YOSHIO OKADA, SHOJI NAMIKAWA, MASAKI NAKAJIMA, ATSUMI MORI,  
SHOGORO HIGO and JUN SONO

The 2nd Department of Surgery, Shiga University of Medical Science, School of Medicine

Received for Publication, March. 10, 1981.

Monostotic fibrous dysplasia of the rib is a rare type of lesion and it is difficult to differentiate it from bone tumor. In this paper two cases of monostotic fibrous dysplasia of the rib are reported. Also lesions involving the ribs in Japan are reviewed and the problems involving these lesions are discussed.

### Case 1: 30-year-old housewife

She had a cold with a little bloody sputa in August and October, 1978. And then she consulted a local doctor and was introduced to the Department of Otorhinolaryngology at Shiga University of Medical Science, School of Medicine.

She had no symptoms but the plane roentgenogram of the chest revealed a lesion on the right 6th rib. And she was referred to the 2nd Department of Surgery. She did not have any past history of tuberculosis, fracture or endocrine disturbance.

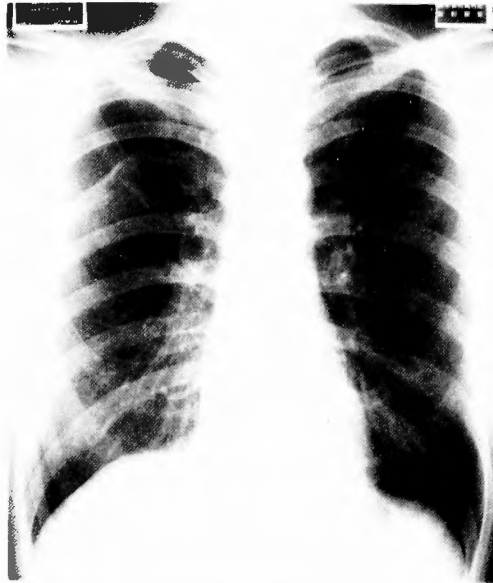
Upon admission, there was no abnormal pigmentation of the skin or mucous membrane and no swelling of the lymph nodes was found upon palpation. The chest was normal upon palpation and auscultation. All laboratory findings including serum alkaline phosphatase and calcium ion were within normal ranges. The plane roentgenogram of the chest taken upon admission revealed a spindle-formed lesion on the posterior portion of the right 6th rib (Fig. 1). In the roentgeno-tomogram the cortical bone became thin and redundant in thickness, and multicellular or cystic changes were found inside the lesion (Fig. 2). Similar changes were not found in any other bones. From these findings it was diagnosed that she had a tumor of the bone, such as fibrous dysplasia, fibroma, chondroma, aneurysmal bone cyst etc., but an accurate diagnosis could not be made and the tumor was removed on November 14, 1978.

The lesion of the right 6th rib including the periosteum, intercostal muscles and parietal pleura of the surrounding area was excised disjoining the costovertebral joint.

From the cross section of the excised tumor, normal bone marrow was absorbed and replaced

Key words: Monostotic fibrous dysplasia, Roentgenogram of the chest, Histological findings, Surgical treatment.  
索引語: 単発性線維性骨異形成, 肋骨, 胸部レ線像, 組織像, 外科治療.

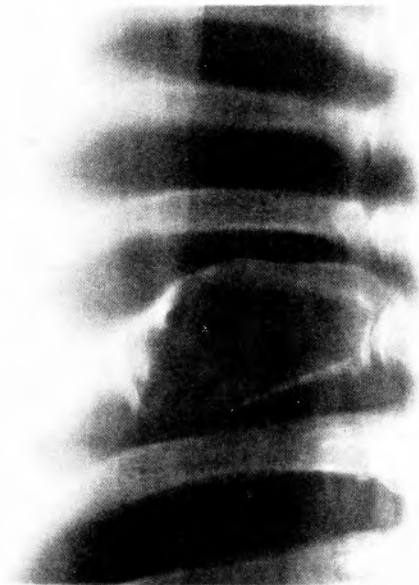Present address: The 2nd Department of Surgery, Faculty of Medicine, Kyoto University, Sakyo-ku, Kyoto 606, Japan.



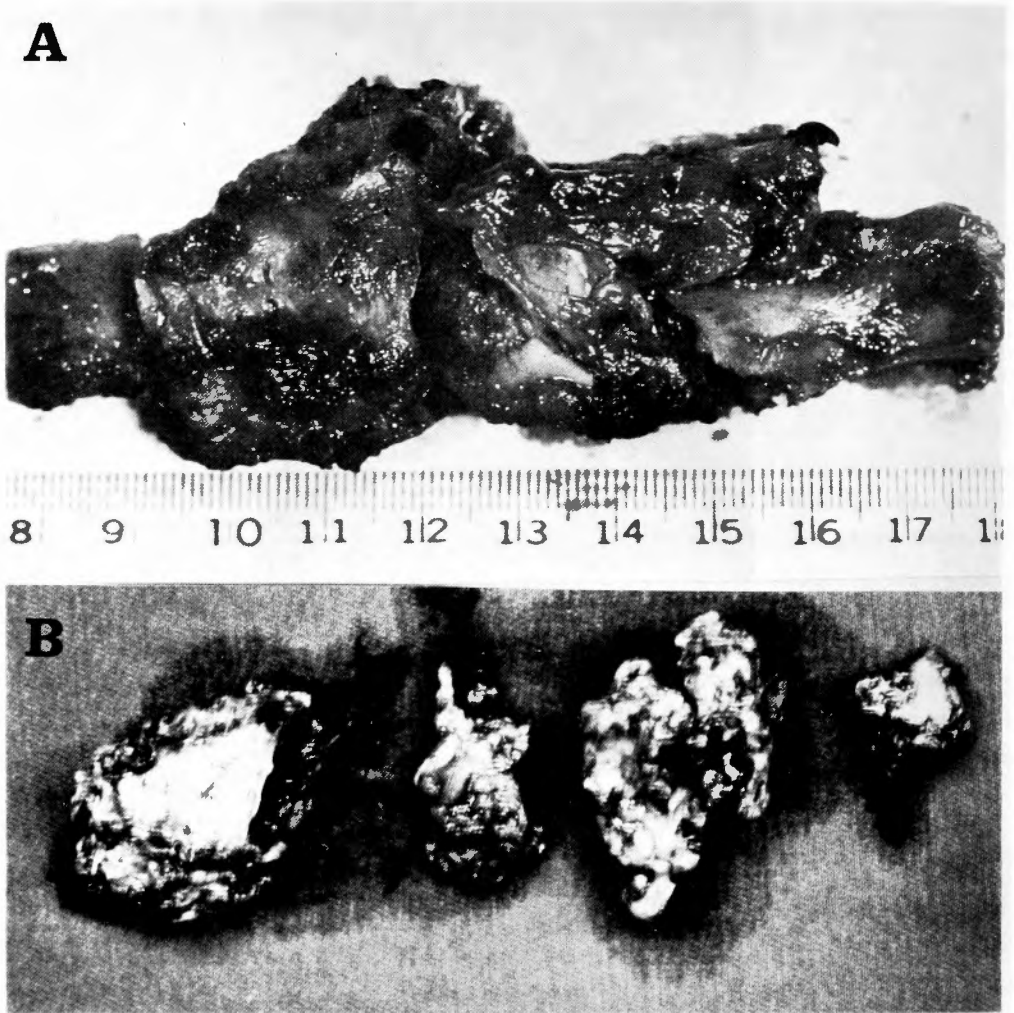
**Fig. 1.** Plane roentgenogram of the chest reveals a spindle-formed lesion on the posterior position of the right 6th rib. (Case 1)

mostly by light yellow connective tissue, partially looking like multiple hemorrhagic cyst (Fig. 3). There were no findings which indicated that the tumor destroyed the bone cortex or encroached upon the surrounding area.

Histologically, fibrous cells are arranged radially or in a coil and osteoclasts are in groups



**Fig. 2.** Roentgenotomogram reveals that the cortical bone becomes thin and redundant in thickness, and multi-cellular or cystic changes are found inside the lesion. (Case 1)



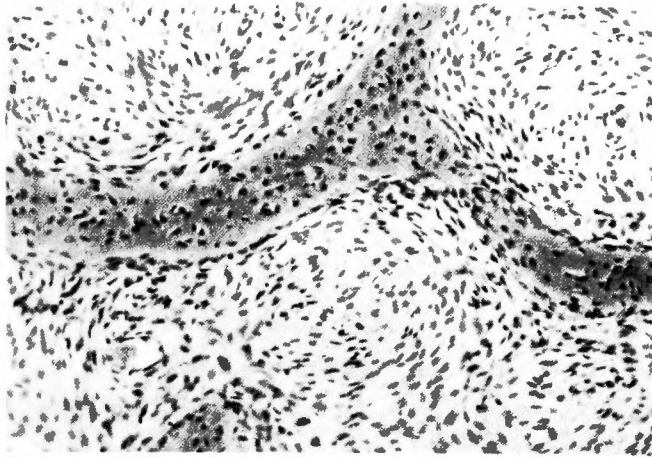
**Fig. 3-A.** Excised specimen shows the right 6th rib including the periosteum, intercostal muscles and parietal pleura of the surrounding area, excised disjoining the costovertebral joint. **B.** From the cross section of the excised tumor, normal bone marrow was absorbed and replaced mostly by light yellow connective tissue, partially looking like multiple hemorrhagic cyst. (case 1)

scattered randomly (Fig. 4).

From the histological study fibrous dysplasia was diagnosed. The postoperative course was uneventful. The past history of spitting bloody sputa was considered to be a symptom of acute bronchitis.

Case 2: 38-year-old housewife

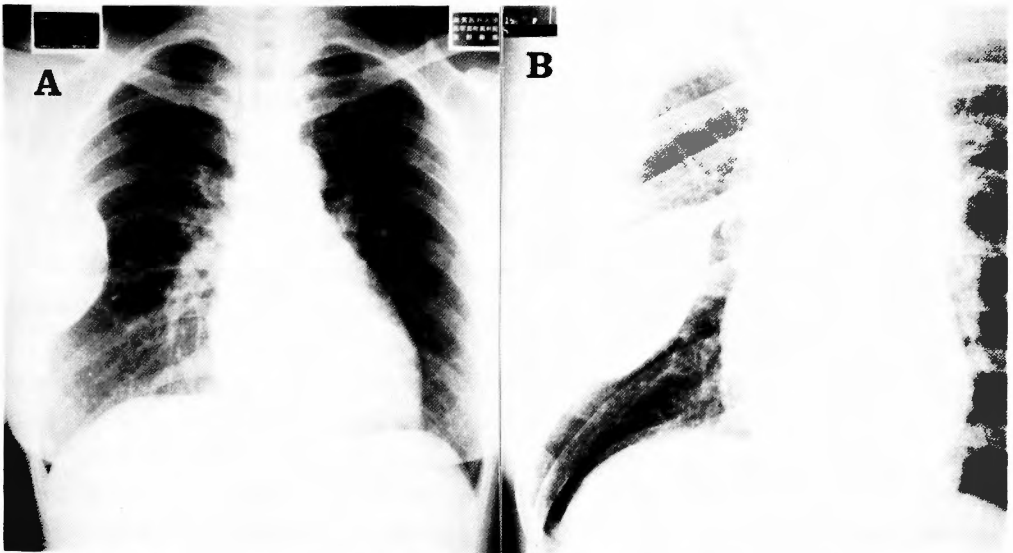A deformity of the right 6th rib from the plane roentgenogram of the chest was discovered when she underwent a medical examination. But until then she had no symptoms such as chest pain or bulging of the chest wall. And she had no past history of tuberculosis, fracture or endo-



**Fig. 4.** Photomicrograph shows that fibrous cells are arranged radially or in a coil and osteoclasts are in groups scattered randomly. (H-E stain,  $\times 200$ ) (Case 1)

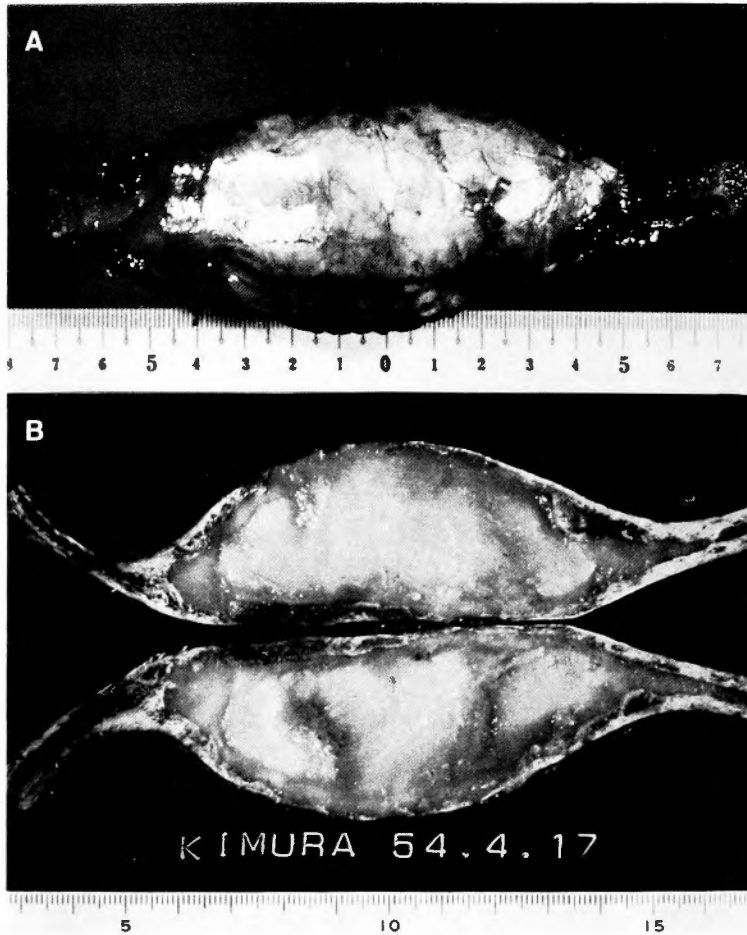
crine disturbance.

Upon admission, there was no abnormality of skin pigmentation or swelling of lymph node anywhere in the body. Physical findings on the chest were normal. Laboratory findings including serum alkaline phosphatase, calcium ion and phosphorus were within normal ranges. The plane roentgenogram of the chest upon admission revealed an oval swelling about 5 cm in diameter on the posterior portion of the right 6th rib. The lesion enlarged toward the inside more than the outside. The bone cortex of the lesion was a little thin and the inside of the swelled



**Fig. 5-A.** Plane roentgenogram in antero-posterior projection of the chest reveals an oval swelling on the lateral portion of the right 6th rib. The lesion enlarges toward the inside more than the outside.

**B.** Plane roentgenogram in left anterior oblique projection. (Case 2)



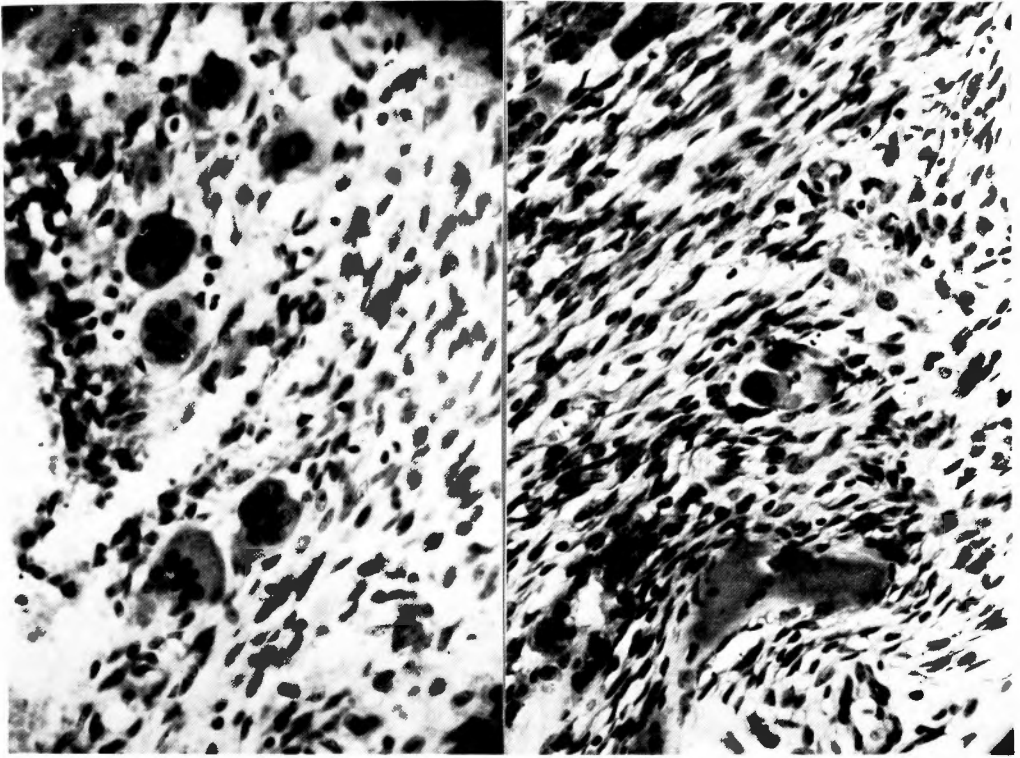
**Fig. 6-A.** Excised specimen of the swelled rib including periosteum, intercostal muscles and parietal pleura of the surrounding area.  
**B.** On looking at the cross section of the swelled portion, normal bone marrow is absorbed and is replaced by the light yellow connective tissue which becomes a little brown in the central portion as a result of central necrosis. (Case 2)

portion was relatively homogenous (Fig. 5). No other bones revealed a similar lesion.

We excised the swelled rib including periosteum, intercostal muscles and parietal pleura of the surrounding area (Fig. 6-A). The lesion did not adhere to the lung.

On looking at the cross section of the swelled portion, normal bone marrow was absorbed and was replaced by the light yellow connective tissue which became a little brown in the central portion as a result of central necrosis (Fig. 6-B). There were no findings that the swelled portion destroyed bone cortex or encroached upon the surrounding area. Also there was no indication of a malignant tumor.

Histologically, the bone marrow was replaced by fibrous tissue which was fine in the outside and became myxomatous in the central and outer portion (Fig. 7). These had incomplete lamellar formation or did not have any lamellar formation at all. Normal osteoblasts were not found



**Fig. 7.** Phonomicrograph shows that the bone marrow is replaced by fibrous tissue which is fine in the outside and becomes myxomatous in the central and outer portion. (Case 2)

around formation or did not have any lamellar formation at all. Normal osteoblasts were not found around the bone marrow at all. A few polynuclear cells were found in a portion of the fibrous tissue of the bone marrow. From the histological study fibrous dysplasia was diagnosed as in case No. 1.

### Discussion

The term fibrous dysplasia of bone was first used by LICHTENSTEIN<sup>11</sup> in 1938 to describe a condition to which attention had been drawn by HUNTER and TURNBULL<sup>7</sup>.

The etiology of fibrous dysplasia though unknown is now believed to be a developmental error in which primitive fibrous tissue proliferates within the bony medulla and encroaches upon the cortex from within, often producing expansion. The lesion may be localised to a small segment or may involve almost the entire shaft of the bone, and it may be monostotic or polyostotic. In the latter type some patients exhibit a remarkable combination of skin pigmentation and endocrine disturbance (ALBRIGHT'S syndrome<sup>11</sup>).

The single bone lesions unassociated with any these other disturbances are the most common form of fibrous dysplasia<sup>9</sup>.

In 1942 LICHTENSTEIN and JAFFE<sup>12</sup> reviewed 90 cases of this disease. In 1946

SCHLUMBERGER<sup>17)</sup> reviewed 67 cases of the monostotic type and 2 cases of the polyostotic type. In 1962 HARRIS<sup>5)</sup> reviewed 13 cases of the monostotic type and 37 cases of the polyostotic type. In 1963 REED<sup>14)</sup> reviewed 16 cases of the monostotic type and 9 of polyostotic type.

In Japan OHI<sup>13)</sup> was the first to report one case with ALBRIGHT'S syndrome. Since then though many case reports have been published, there have not been many studies involving a large number of cases. In 1969 FURUYA<sup>4)</sup> reviewed 86 cases and SHIMAZU<sup>16)</sup> 20 cases, but most of these case reports have been published in the departments of orthopedics, oral surgery, neurosurgery, otorhinolaryngology and ophthalmology; only a few in the department of thoracic surgery. YOKOYAMA,<sup>18)</sup> KOGA<sup>10)</sup> and ARAI<sup>2)</sup> reported their cases involving the ribs. In Japan the femur, tibia and jaw bone were those most often affected; the ribs being involved in only small number of cases (Table 1). It is common that monostotic fibrous dysplasia is clinically treated as a benign tumor.

The incidence of monostotic fibrous dysplasia of the rib is 8 to 37% of all benign tumors involving the chest wall. These lesions of the ribs are most commonly monostotic in number and are not uniformly at the site of occurrence (Table 2).

HENRY<sup>6)</sup> reported that the peak incidence of age distribution was between ten and fifteen years of age when all sites are taken together. Fibrous dysplasia is thus primarily a disease of growing bone. If, however, the age distribution is considered in relation to the site, it is found that lesions in the large bones mostly appear in childhood. The condition here is usually obvious, so that this time of onset is probably accurate.

Fibrous dysplasia in rib does not give rise to any urgent symptoms; in fact, it may be symptomless. This explains the late age of appearance of lesions at the site.

The patients were distributed almost equally between the sexes. This is in accordance with the findings of HARRIS<sup>5)</sup> and HENRY<sup>6)</sup>. Previous observers have found a great incidence in females. LICHTENSTEIN<sup>12)</sup> stated that the female per male ratio was at least 3 : 1. However, in our review which involved only Japanese cases a greater incidence in males was unexpectedly found and most cases were in adults from 18 to 53 years as shown in Table 2.

Most cases in which the rib is involved do not have symptoms. In a few cases localized

**Table 1.** Site and incidence of monostotic fibrous dysplasia in Japan (ARAI<sup>2)</sup>)

Bone	No. of case (%)
Mandibulla	30 (20.3)
Maxilla	28 (18.9)
Femur	26 (17.5)
Tibia	26 (17.5)
Rib	14 (9.5)
Humerus	9 (6.1)
Fibula	3 (2.0)
Radius	2 (1.4)
Others	10
Total	148



**Table 2.** Case of monostotic fibrous dysplasia involving the rib in Japan

Case	Age	Sex	Site of rib
1	48	m	L 3
2	18	m	L 6
3	29	m	L 2
4	27	m	L 3
5	48	m	R 3
6	23	m	R 2
7	53	m	L 9
8	45	m	R 8
9	25	m	L 5
10	22	m	R 7
11	18	m	4
12	39	m	2
13	29	m	8
14	28	m	8
15	25	f	L 7
16	32	m	L 4
17	25	m	L 5
18	30	f	R 6
19	38	f	R 6

bulging and tenderness on the chest wall can be found upon palpation in the more progressive stages when the lesion is larger. Therefore the abnormality is incidentally discovered by a roentgenogram of the chest taken for other reasons such as bronchitis in our case No. 1. Though usually the growth of the lesions is very slow, HENRY<sup>6)</sup> reported that in one rib case there was a doubling in size within 2 years. Fracture very rarely occurs at the portion of the lesion of the rib.

Because the lesion of the rib enlarges toward the inside rather than the outside, it is rarely found from the outside even if it is large. The appearance of monostotic fibrous dysplasia in the roentgenogram offers little that is characteristic. In long bones the lesions have a spindle form or round form and have a tendency to appear principally in the metaphyses and extend to the diaphyses, though occasionally they occupied the middle of the shaft. In the roentgenogram the area of fibrous dysplasia is polyostotic or radiolucence such as frosted glass, sometimes it is transversed by delicate trabeculae of bone, because of destruction of the cortex and marrow. It produces thinning and expansion of the cortex, particularly marked in the rib and fibula, at times there is a narrow margin of condensed bone at the periphery.

Clinical manifestations are not found in most cases of the monostotic type, but in about two-thirds of the polyostotic type, there is found a high value of serum alkaline phosphatase. In Albright's syndrome the dysfunction of hypophysis or thyroid gland is occasionally found.

The different types of lesions that can be diagnosed are, in order of frequency, as followed: solitary bone cyst, giant cell tumor, osteochondroma, chondroma, fibroma, ossifying fibroma, osteitis fibrosa cystica, sarcoma, myeloma, osteoma, chondromyxoma, non-osteogenic fibroma,

eosinophilic granuloma of bone, osteomyelitis and callus. It is often difficult to make a differential diagnosis between those diseases only from roentgenogram alone. Therefore a biopsy is needed to make an accurate diagnosis. By histological study a thin lamella of cortical bone can be found being encroached upon by osteoclasts at the edge of an area of fibrous dysplasia.

Many slender spindle-formed connective fibers densely occupied the bone marrow and metaplasia of the connective tissue and in additional new-made bone can be found.

The surgical procedures of the monostotic fibrous dysplasia are curettage and packing with cancellous block shaft, extraperiosteal excision and cancellous/cortical graft, but in the rib or fibula the involved segment of bone may be excised in a mass.

Therefore the prognosis of the patients with monostotic fibrous dysplasia of the rib is much better than that of the patients with monostotic fibrous dysplasia in other areas, and this may be related to the higher average age of the patients with the monostotic fibrous dysplasia of the rib.

The recurrence of the monostotic fibrous dysplasia of the rib has not been reported yet. DEPALMA<sup>3)</sup> stated that periosteum around the lesion might be one of the causes of recurrence. Therefore he emphasized periosteal excision of the lesions in a mass.

Among the reported cases monostotic fibrous dysplasia of the rib there are only a few reports of malignance changing to sarcoma<sup>8,15)</sup>. So it appears that when a lesion involving the rib is discovered, periosteal excision should be performed slightly wider than necessary.

The long-term follow-up studies may be needed to explain the recurrence in the postoperative period.

### Summary

We experienced two cases of the monostotic fibrous dysplasia both involving the right 6th rib.

It is difficult to make an accurate diagnosis of the monostotic fibrous dysplasia from only the plane and tomo-roentgenogram preoperatively. And because there is a small incidence of malignance changing to sarcoma of the fibrous dysplasia, we think that lesion involving the rib should be excised slightly wider than necessary so as to include the periosteum, the intercostal muscles and parietal pleura.

### References

- 1) Albright F, Butler AM, et al: Syndrome characterized by osteitis fibrosa disseminata, areas of pigmentation and endocrine dysfunction, with precocious puberty in females. *New England J Med* **216**: 727-746, 1937.
- 2) Arai M, Watanabe Y, et al: A case of monostotic fibrous dysplasia in the rib. *Jap Thorac Dis* **16**: 525-528, 1978.
- 3) DePalma AF, Smythe VI: Recurrent fibrous dysplasia in a cortical bone graft. *Clin Orthop* **26**: 136-144, 1963.
- 4) Furuya K: Fibrous dysplasia and its similar lesions. *J Jpn Orthop Ass* **43**: 151-174, 1969.
- 5) Harris WH, Dudley HR, et al: The natural history of fibrous dysplasia. *J Bone Jt Surg* **44-A**: 207-233, 1962.
- 6) Henry A: Monostotic fibrous dysplasia. *J Bone Jt Surg* **51-B**: 300-306, 1969.
- 7) Hunter D, Turnbull HM: Hyperparathyroidism; Generalised osteitis fibrosa. *Brit J Surg* **19**: 203-284,

- 1931.
- 8) Huvos AG, Higinbotham NL, et al: Bone sarcomas arising fibrous dysplasia. *J Bone Jt Surg* **54**: 1047-1056, 1972.
  - 9) Jaffe HL: *Tumors and tumorous conditions of the bones and joints*. London; Henry Kimpton, 1958.
  - 10) Koga A, Okuno T, et al: A case of monostotic fibrous dysplasia of the rib. *Jap J Chest Dis* **37**: 502-506, 1978.
  - 11) Lichtenstein L: Polyostotic fibrous dysplasia. *Arch Surg* **36**: 874-898, 1938.
  - 12) Lichtenstein L, Jaffe HL: Fibrous dysplasia of bone. *Arch Path* **33**: 777-816, 1942.
  - 13) Ohi M, Seki T: A case report of osteodysplasia fibrosa Lichtenstein with Albright's syndrome. *J Jpn Orthop Ass* **17**: 1240-1260, 1942.
  - 14) Reed RJ: Fibrous dysplasia of bone, a review of 25 cases. *Arch Path* **75**: 480-495, 1963.
  - 15) Sethi RS, Andrew RW, et al: Fibrous dysplasia of the rib with sarcomatous change. *J Bone J Surg* **44**: 183-188, 1962.
  - 16) Shimazu A, Ishida T, et al: Results of surgical treatment for fibrous dysplasia. *Orthop Surg* **20**: 694-701, 1969.
  - 17) Schlumberger MHG: Fibrous dysplasia of single bones (Monostotic fibrous dysplasia). *Mil Surg* **99**: 504-527, 1946.
  - 18) Yokoyama H, Takahashi S, et al: A case of monostotic fibrous dysplasia involving rib. *Hitachi J Med* **21**: 1-7, 1972.

## 和文抄録

# 肋骨に発生する Monostotic fibrous dysplasia

京都大学医学部外科学教室第2講座

南 一 明

滋賀医科大学第2外科学教室

岡田 慶夫, 並河 尚二, 中島 真樹, 森 渥視

肥後昌五郎, 藪 潤

右側第6肋骨に発生した monostotic fibrous dysplasia 2例を経験した。30才および38才の女性で、いずれも偶然に撮った単純胸部レ線より発見された。

本症は、単純胸部レ線や断層撮影から他の良性腫瘍との鑑別は困難であり、本症の悪性化の報告もあると

ころから摘出術を行ない、確実な組織診断を行なう必要がある。摘出に際し、再発の可能性があるところから、周囲の骨膜、肋間筋、胸膜も含めやや広範囲に行なうことが好ましい。