

Title	Treatment of Stress Ulcer with Neurotensin, An Experimental Study
Author(s)	YAMAGUCHI, TAKAYUKI; TOBE, TAKAYOSHI; HIKASA, YORINORI
Citation	日本外科宝函 (1980), 49(3): 269-274
Issue Date	1980-05-01
URL	<a href="http://hdl.handle.net/2433/208443">http://hdl.handle.net/2433/208443</a>
Right	
Type	Departmental Bulletin Paper
Textversion	publisher

## Treatment of Stress Ulcer with Neurotensin, An Experimental Study

TAKAYUKI YAMAGUCHI, TAKAYOSHI TOBE and YORINORI HIKASA

Department of Surgery, Faculty of Medicine, Kyoto University

(Director : Prof. Dr. YORINORI HIKASA)

Received for Publication, Feb. 6, 1980.

### Abstract

Neurotensin is a tridecapeptide possessing hypotensive action, which has been isolated from the bovine hypothalamus. In an investigation of synthetic neurotensin in the prevention and treatment of stress ulcers in rat, it was infused subcutaneously at the rate of 50 ng per kg per minute for about 15 hours into rats subjected to stress. The formation of stress ulcers was prevented in all test animals, and electron microscopy showed hypofunction of both endocrine and exocrine cells. It thus appears that neurotensin might be clinically effective in treating the acute stage of inoperably severe stress ulcers ; this possibility will be examined in the future.

### Introduction

It is well known that stress induces gastric ulcers in a high proportion of rats within a comparatively short time, and that ulcer formation can be prevented by vagotomy<sup>3)</sup>. Further, the findings of my colleagues and myself that medical vagotomy with atropine-hexamethonium bromide or the infusion of GIP (gastric inhibitory polypeptide) or somatostatin (growth hormone release inhibiting factor, both synthesized by Dr. YAJIMA of Kyoto University) can also prevent ulcer formation suggest that both the vagal nerve and gastric acid, a local aggravating factor, play an important role in the onset of stress ulcer<sup>14)</sup>. Neurotensin is also reported to inhibit pentagastrin-stimulated gastric acid secretion<sup>1)</sup>. This paper reports the clear inhibitory effect on ulcer formation of the continuous infusion of this hypothalamic peptide (synthesized by Dr. YAJIMA, Kyoto University)<sup>11)</sup> into rats subjected to stress, together with the electron microscopic findings of the gastric endocrine<sup>13)</sup> and exocrine<sup>10)</sup> cells.

### Method

After a fast of about 16 hours, rats weighing around 200 g were tied to a board by all

---

Key words : Stress ulcer, Neurotensin, Endocrine cells and exocrine cells of the rat stomach

索引語 : ストレス潰瘍, ノイロテンシン, ラット胃の内分泌細胞及び外分泌細胞.

Present address : TAKAYUKI YAMAGUCHI, Department of Surgery, Shimane Prefectural Central Hospital, Izumo, Shimane, 693, Japan.

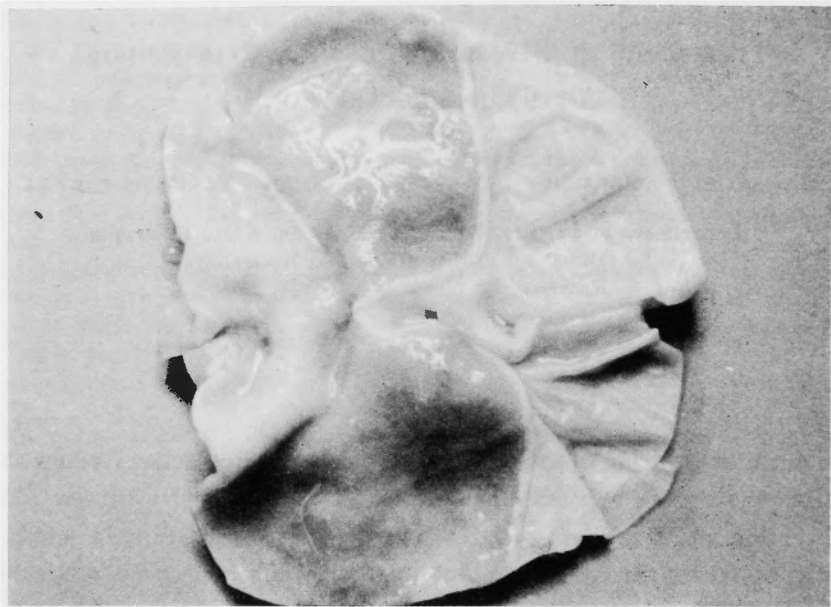
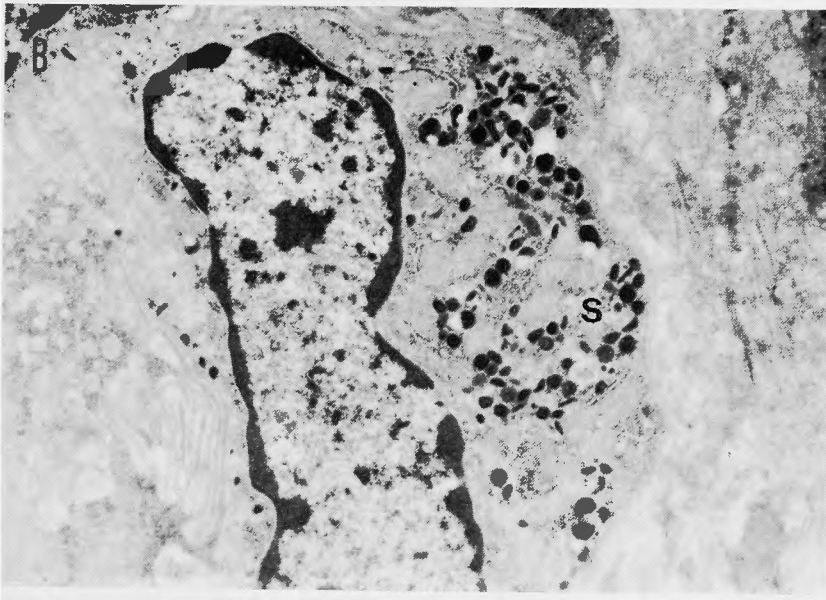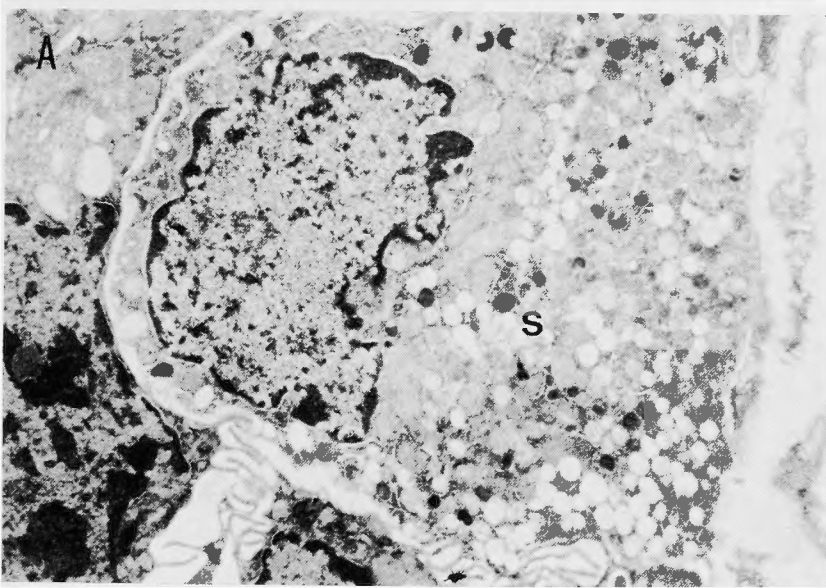


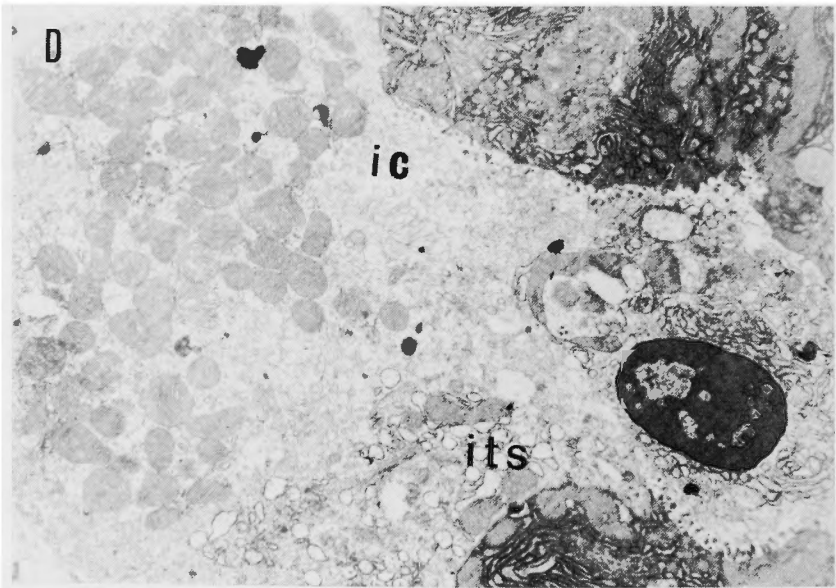
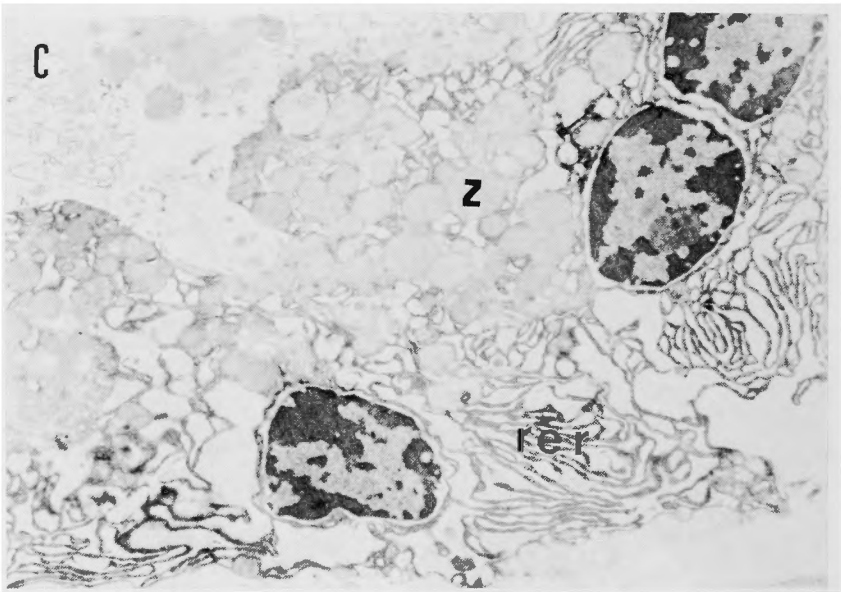
Fig. 1 Macroscopic sample of rat stomach after infusion of neurotensin during stress.

four limbs and immersed in water of approximately 20 °C ; at the same time neurotensin<sup>21</sup> was infused subcutaneously into the back at a rate of 50 ng per kg per minute with an infusion pump. After approximately 15 hours the animals were laparotomized and the stomachs were removed.

### Results

The continuous infusion of neurotensin prevented the formation of stress ulcers in all 20 test animals (Fig. 1), and the stomach pH was maintained between 6.0 and 7.0. Confirmation was made histologically by hematoxylin-eosin staining. The electron microscopic findings in endocrine and exocrine cells after the infusion of neurotensin during stress contrasted sharply with the hyperfunctional changes seen in these cells at the time of formation of stress ulcers<sup>14</sup>. Of the endocrine cells, both G-cells (gastrin cells, Fig. 2-A) and EC-cells (enterochromaffin cells, Fig. 2-B) showed intracellular retention of secretory granules(s) and atrophy of the Golgi apparatus to the point that it could hardly be seen, and the basement membrane showed no evident emiocytosis. Of the exocrine cells, the chief cells (Fig. 2-C) showed decreased rough endoplasmic reticulum (rer), with atrophied and flattened lumina forming scattered layers between which could be seen the intracisternal granules that appear when secretion is disturbed. Zymogen granules (z) were increased and retained and the Golgi apparatus was atrophied and difficult to discern. Parietal cells (Fig. 2-D) showed increased intracellular tubular system (its) and decreased intracellular canaliculi (ic). These changes in the endocrine and exocrine cells are indicative of hypo-function.





**Fig. 2** Electron microscopic findings after infusion of neurotensin during stress.

A : G-cell ( $\times 7,000$ ), B : EC-cell ( $\times 9,000$ ), C : chief cell ( $\times 9,500$ ),

D : parietal cell ( $\times 10,100$ ) (original magnification)

### Discussion

CARRAWAY and LEEMAN<sup>4)</sup> isolated a new peptide possessing hypotensive action from the bovine hypothalamus, which they named neurotensin. It is a tridecapeptide with the amino acid sequence pGlu-Leu-Try-Glu-Asn-Lys-Pro-Arg-Arg-Pro-Tyr-Ile-Leu-OH, and its presence has been demonstrated in the digestive tract<sup>4,5,7,8)</sup>. Its actions include the enhancement of blood vessel permeability and of cyanosis and a hyperglycemic action<sup>4,5,9,12)</sup>. Neurotensin also markedly inhibits pentagastrin-stimulated gastric acid secretion and gastric movement in dogs but does not inhibit histamine-stimulated acid secretion<sup>1,2)</sup>. Further, our experiment to date has suggested that the vagal nerve and gastric acid play a critical role in the onset of stress ulcer, leading to the inference that neurotensin might be useful in the prevention and treatment of stress ulcer.

Both the endocrine and exocrine cells of the stomachs of rats in which ulcers were induced by the application of stress showed changes indicative of hyperfunction<sup>14)</sup>. The formation of stress ulcers was prevented by the continuous infusion of neurotensin in all test animals, and electron microscopic examination revealed hypofunctional changes in both endocrine and exocrine cells. It thus appears that neurotensin might be applicable clinically in the treatment of inoperably severe acute stress ulcers. This possibility will be examined in the future.

### Acknowledgment

This paper was presented at the 78th Congress of the Japan Surgical Society, held in April 1978. I am deeply grateful to Dr. HARUAKI YAJIMA of the Faculty of Pharmacy, Kyoto University, who synthesized the neurotensin employed in this study, and to Miss MITSUE KANATO of the Electron Microscopy Department of Kansai Denryoku Hospital.

### References

- 1) Anderson S, Chang D, et al : Inhibition of gastric acid secretion in dogs by neurotensin. *Life Sciences* **19** : 367-370, 1976.
- 2) Anderson S, Rosell S, et al : Abstracts and participants in the First International Symposium on Gastro-intestinal Hormones at Asilomar and in the Symposium on Hormones and Peptic Ulcer at Los Angeles. 1976.
- 3) Brodie DA and Hanson HM : A study of the factors involved in the production of gastric ulcers by the restraint technique. *Gastroenterology* **38** : 353-360, 1960.
- 4) Carraway R and Leeman SE : The synthesis of a new hypothalamic peptide, neurotensin, from bovine hypothalamus. *J Biol Chem* **248** : 6854-6861, 1973.
- 5) Carraway R, Demers L, et al : Hyperglycemic effect of a hypothalamic peptide. *Fed Proc* **32** : 211, Abs. 1973.
- 6) Carraway R and Leeman SE : The amino acid sequence of a hypothalamic peptide, neurotensin. *J Biol Chem* **250** : 1907-1911, 1975.
- 7) Carraway R and Leeman SE : The synthesis of neurotensin. *J Biol Chem* **250** : 1912-1918, 1975.
- 8) Carraway R and Leeman SE : Characterization of radioimmunoassayable neurotensin in the rat. *J Biol Chem* **251** : 7045-7052, 1976.
- 9) Carraway R, Demers L, et al : Hyperglycemic effect of neurotensin, a hypothalamic peptide. *Endocrinology* **99** : 1452-1462, 1976.

- 10) Fujita H and Kataoka K : Exocrine cells of the stomach. *The Cell* 5 : 13-28, 1973.
- 11) Kitagawa K, Akita T, et al : Studies on peptides. LXV Conventional synthesis of a new hypothalamic peptide bovine neurotensin. *Chem Pharm Bull* 24 : 2692-2698, 1976.
- 12) Rosell S, Burcher E, et al : Cardiovascular and metabolic actions of neurotensin and (Gln<sup>4</sup>)-Neurotensin. *Acta Physiol Scand* 98 : 484-491, 1976.
- 13) Sasagawa T, Kobayashi S, et al : The endocrine cells in the human pyloric antrum. An electron microscopic study of biopsy materials. *Arch Histol Jap* 32 : 275-288, 1970.
- 14) Yamaguchi T : Acute stress ulcer : Experimental study on its etiology, pathophysiology and management. *Arch Jap Chir* 46 : 278-308, 1977.

## 和文抄録

# ノイロテンシンによるストレス潰瘍の 治療に関する実験的研究

京都大学医学部外科学教室第2講座

山口 孝之, 戸部 隆吉, 日笠 頼則

最近, Carraway と Leeman によりウシの視床下部から強力な血圧降下作用をもつ新しいペプチドとして単離された Neurotensin が, ペンタガストリン刺激による胃酸分泌抑制作用を有するところから, 京大薬学・矢島らの合成 Neurotensin を用いてラットで15時間拘束浸水ストレス潰瘍の防止実験を行いほぼ

100%の防止効果が得られた。又, 電顕所見でも胃の内分泌細胞, 外分泌細胞共にその分泌機能は低下していた。そこで, 手術も行えない程の重症のストレス潰瘍の急性期治療として臨床的にも応用できるのではないかと検討中である。