

Title	Surgical Treatment of Wolf-Parkinson-White Syndrome, a Report of Three cases
Author(s)	TATSUTA, NORIKAZU; MIKI, SHIGEHITO; KONISHI, YUTAKA; MATSUDA MITSUHIKO; TANIGUCHI, TEIICHI; ISHIWARA, HIROSHI; MURATA, SHINJI; KAO, CHIN-TZER; HIKASA, YORINORI; KONISHI, TOMOTSUGU; MATSUYAMA, EIICHI; SUEKANE, KEITA
Citation	日本外科宝函 (1979), 48(3): 382-392
Issue Date	1979-05-01
URL	<a href="http://hdl.handle.net/2433/208346">http://hdl.handle.net/2433/208346</a>
Right	
Type	Departmental Bulletin Paper
Textversion	publisher

## Surgical Treatment of Wolf-Parkinson-White Syndrome, a Report of Three cases.

NORIKAZU TATSUTA, SHIGEHITO MIKI, YUTAKA KONISHI,  
MITSUHIKO MATSUDA, TEIICHI TANIGUCHI, HIROSHI ISHIWARA,  
SHINJI MURATA, CHIN-TZER KAO, and YORINORI HIKASA  
The Second Department, of Surgery, Faculty of Medicine, Kyoto University.  
(Director : Prof. Dr. YORINORI HIKASA)

TOMOTSUGU KONISHI and EIICHI MATSUYAMA  
The Third Department of Internal Medicine, Faculty of Medicine, Kyoto University.  
(Director : Prof. Dr. CHUICHI KAWAI)

KEITA SUEKANE  
Department of Anesthesiology Faculty of Medicine, Kinki, University Osaka, Japan.  
Received for Publication March, 6, 1978

### Introduction

WOLF-PARKINSON-WHITE (WPW) syndrome is a well known cardiac disease characterized by unique electrocardiographic features and by frequent attacks of tachycardia. These paroxysmal atrial tachycardia attacks (PAT) not only disable patients but can also lead to ventricular tachyarrhythmia and sometimes sudden death. Atrial fibrillation and flutter in these patients are very dangerous as causes of intolerable ventricular tachyarrhythmias. Antiarrhythmic drugs and artificial pace maker overdriving<sup>10,14)</sup> are effective, but are not definitive treatment for refractory attacks.

Although pathological and electrophysiological evidence of abnormal conduction tissue between the atrium and the ventricle (bundle of KENT) had been proposed<sup>1, 16,22,23)</sup>, the final proof was presented by COBB<sup>5)</sup> and his co-workers who used a precordial mapping technique and definitively treated WPW syndrome by surgical division of the abnormal conduction tissue. Since that time, surgical treatment of WPW syndrome has been developed and is becoming increasingly successful in many cardiac centers<sup>6,9,14)</sup>, especially Duke University<sup>11,12,17,18,19,20)</sup>.

Electrophysiological mapping techniques are essential for this surgery<sup>7,8,12,15,19)</sup>. We have interested in this field and succeeded in surgical division of the bundle of KENT in three cases. This paper presents our experience in detail.

### Case report

#### Case 1 :

This seven year-old girl was born by normal delivery after a full term pregn-

Key words : Wolf-Parkinson-White syndrome, Kent bundle, Paroxysmal tachycardia attacks, Electrophysiological mapping, Ebstein's anomaly.

索引語 : WPW 症候群, ケント束, 発作性頻脈, 電気生理学的地図作製, エプスタイン奇形

Present address : The second Department of Surgery, Faculty of Medicine, Kyoto University, Sakyo-ku, Kyoto, 606, Japan.

ancy. The first attack of tachycardia occurred 22 days after birth. Since then, she was frequently admitted to a local hospital with PAT. A cardiac murmur and mild cyanosis were noted. At four years of age, a definite diagnosis of EBSTEIN'S anomaly with B-type WPW syndrome was made in the Pediatric Clinic of Kyoto University Hospital. Although her physical condition was not much impaired except during the tachycardia attacks, digitalization was begun and PAT was treated with antiarrhythmic drugs (Xylocaine, Ajmalin etc) and sometimes with cardioversion. At seven years of age, she was referred to us for surgical treatment of life-threatening PAT and EBSTEIN'S anomaly.

**"Preoperative evaluation"**

She had mild cyanosis. Hematologic examination, however, revealed no polycy-

**Table 1** Electrocardiographic Findings

	Preoperation				Postoperation			
	QRS Axis	PQ Time	V1	V5	QRS Axis	PQ Time	V1	V5
CASE 1	-130	0.11"			-90	0.18"		
CASE 2	-90	0.11"			-120	AV block		
CASE 3	+30	0.08"			+40	0.12"		

themia (RBC  $480 \times 10^4$ , Hb 13.4 g/dl). Her lungs were clear. A 3/6 systolic murmur was heard along the left lower sternal border, and  $S_3$  and  $S_4$  were prominent. The liver was not palpated and the jugular veins were not distended. Other laboratory tests including liver, lung and kidney function tests were normal. Electrocardiograms

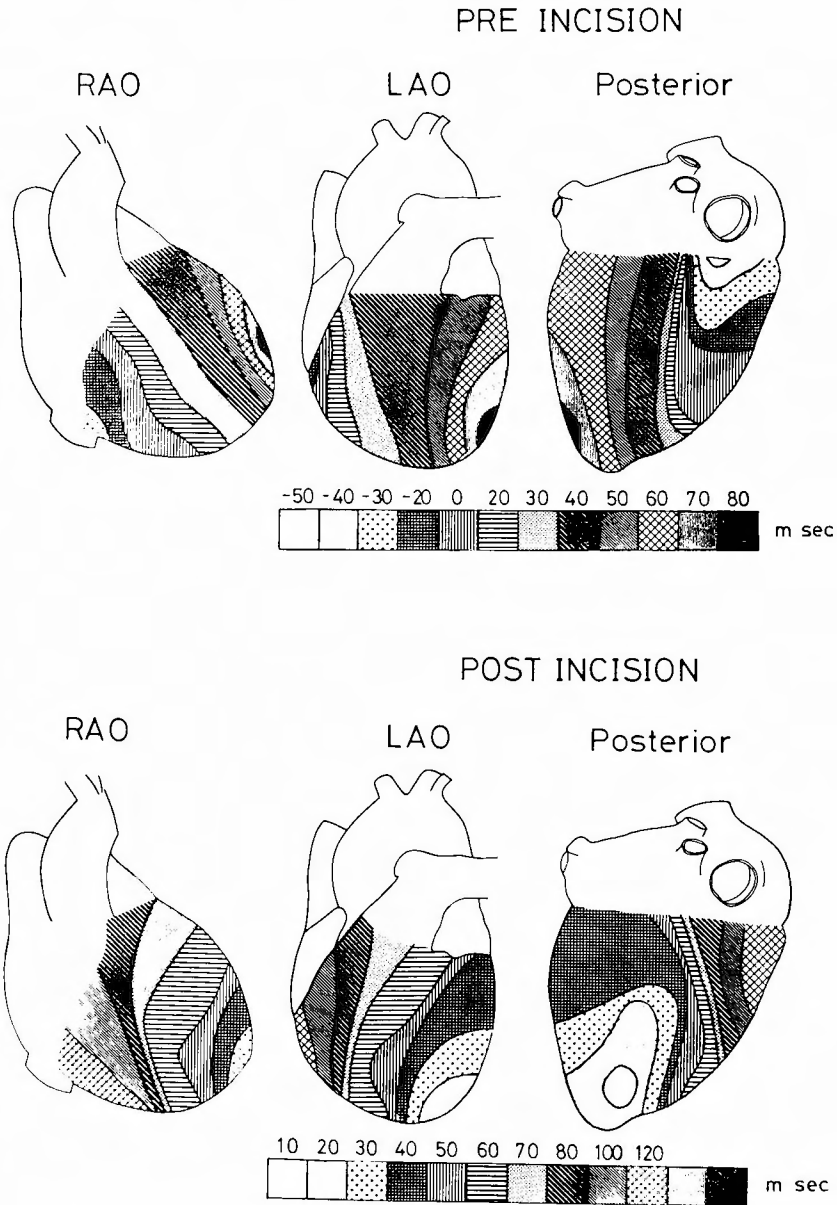


Fig 1. Antegrade epicardial mapping during operation (case 1) Preincision map shows the earliest point of abnormal excitation in the postero-inferior portion of the right ventricle along the atrio-ventricular groove. Postincision map is normalized.

showed classical B-type WPW syndrome (Table 1). A chest x-ray showed enlargement of the cardiac shadow (CTR=0.63) and decreased pulmonary vasculature. Right heart catheterization and selective right atrial angiography demonstrated an enlarged right atrium, atrialized right ventricle and right to left shunt at the atrial level. A His bundle study showed B-type WPW syndrome and shortening of the H-V interval.

#### “Operative method and findings”

She was operated on July 12, 1976 via median sternotomy. Antegrade epicardial mapping showed that the earliest area of excitation was at the postero-inferior portion of the right ventricle along the atrioventricular groove. This suggested the presence of abnormal antegrade conduction between the right atrium and the right ventricle (Fig 1). In retrograde mapping, abnormal retrograde conduction was found in the right atrium just opposite the right ventricular area mentioned above.

Under cardiopulmonary bypass, right atriotomy was done. The exact location of the bundle of KENT was confirmed again, by endocardial retrograde mapping. Endocardial incision by SEALY'S method<sup>17)</sup> was performed on atrial side, from the right trigone in a counterclockwise direction along the true tricuspid ring of EBSTEIN'S anomaly for about 4 cm (Fig 2). Delta waves in the electrocardiograms disappeared immediately. Then the endocardial incision was sutured, the atrial septal defect was closed and HARDY'S valvuloplastic operation<sup>13)</sup> was performed successfully. The postoperative antegrade electrical map was normalized (Fig 1).

#### Case 2 :

A seven-year-old girl was referred to our clinic for the surgical treatment of

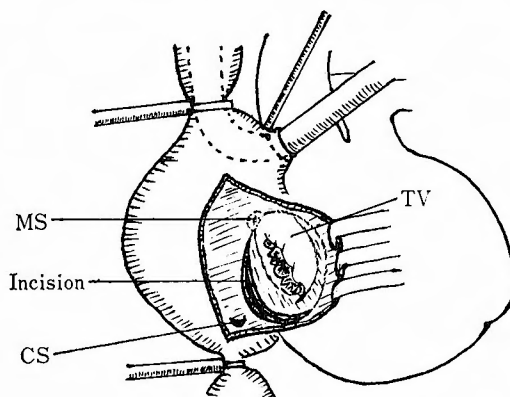


Fig 2. Operative method of the case 1.  
 TV : tricuspid valve, MS : membranous portion of the atrial septum, CS : coronary sinus  
 Endocardial incision was made just parallel with the true tricuspid valve ring for about four cm long in the right atrium

B-type WPW syndrome and EBSTEIN's anomaly in August 1978. Her delivery had been uneventful after a full-term pregnancy. Cyanosis on crying had appeared in infancy. At the age of one year, frequent abdominal pain and vomiting occurred, and these attacks became more frequent with growth. It eventually became clear that these attacks were usually accompanied by tachycardia. She was digitalized and treated with antiarrhythmic drugs and cardioversion. However, she was disabled by frequent PAT, and when her cyanosis became more severe she was referred to our clinic.

#### "Preoperative evaluation"

She had moderate cyanosis. Hematological examination revealed polycythemia ( $RBC \times 515 \times 10^4$ , Hb 16.0 g/dl). Other laboratory tests were within normal limits. Electrocardiograms showed evidence of B-type WPW syndrome. However, supraventricular tachycardia with bundle branch block was observed during the attacks (Fig 3). Chest x-ray (Fig 4) showed an increased cardio-thoracic ratio (0.71). Right heart catheterization and angiocardiography provided evidence of EBSTEIN's anomaly. A His bundle study showed B-type WPW syndrome with a right lateral KENT bundle.

#### "Operative method and findings"

Division of the bundle of KENT and HARDY's valvuloplasty were done on September 5, 1978. Electrophysiological mapping showed that the earliest point of excitation (AV interval was 103 msec with atrial pacing) was in the postero-inferior portion of the right ventricle near the AV groove. Under heart lung bypass, right

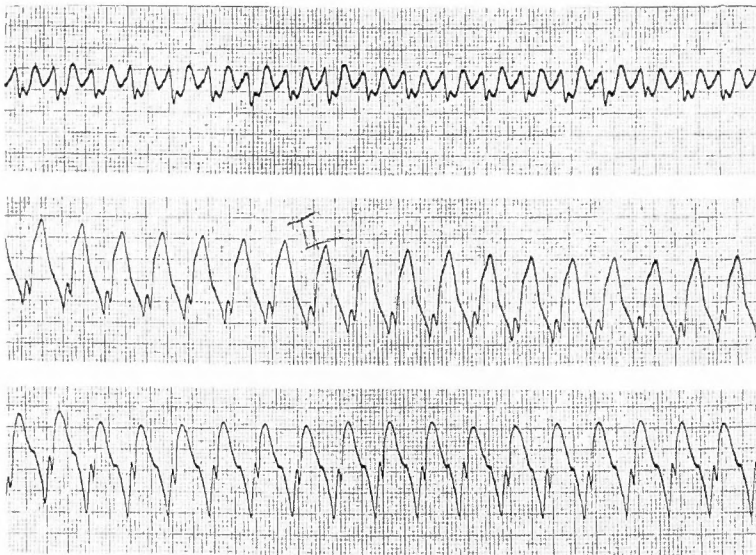


Fig 3. Electrocardiograms during tachycardial attack in the case 2. An atrial tachycardia with right bundle branch block is shown.

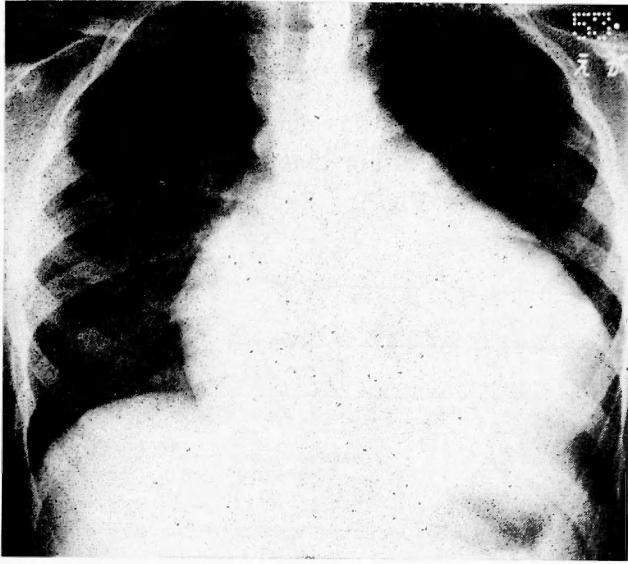


Fig 4. Chest x-ray film of the case 2.  
Cardiac enlargement due to EBSTEIN'S anomaly is shown.

atriotomy and endocardial retrograde mapping and division of the bundle of KENT were performed with the same technique as in case 1. Delta waves in the electrocardiograms disappeared. However, complete AV block occurred during valvuloplasty (HARDY'S method) for EBSTEIN'S anomaly, when the displaced false annulus of the tricuspid septal leaflet was transposed to the true annulus (Table 1). Four weeks after operation, her heart rate was fixed at 58 per minute. An artificial pacemaker (MICROLITH-P model 505, CPI Inc) was implanted and paced at a rate of 78 per minute.

### Case 3 :

A 35-year-old man was first referred to our surgical department in December, 1978. He had had frequent palpitations of short duration since childhood, but his physical and mental development had been normal. When he was 30-years-old, he developed precordial oppression and vomiting which continued for three days. Since then he had experienced frequent PATs of long duration requiring admission to a local hospital and sometimes cardioversion. He was treated antiarrhythmic drugs without benefit. He had further examinations in our department of cardiology, including a His bundle study and was referred for surgical treatment.

### "Preoperative evaluation"

He was an average-sized adult and appeared to be in good health. No cardiac murmurs and no abnormal heart sounds were heard. His laboratory tests were all normal except for his electrocardiograms, which showed B-type WPW syndrome with QRS axis of +30 degrees. The PQ interval was 0.08 sec (Table 1). The His bundle

examination showed WPW syndrome due to a right-sided KENT bundle.

### “Operative method and findings”

The abnormal point of excitation was detected in the anterior wall of the right ventricle near the AV groove indicating that the KENT bundle was in the anterior free wall of the right ventricle (Fig 5). Endocardial retrograde mapping revealed

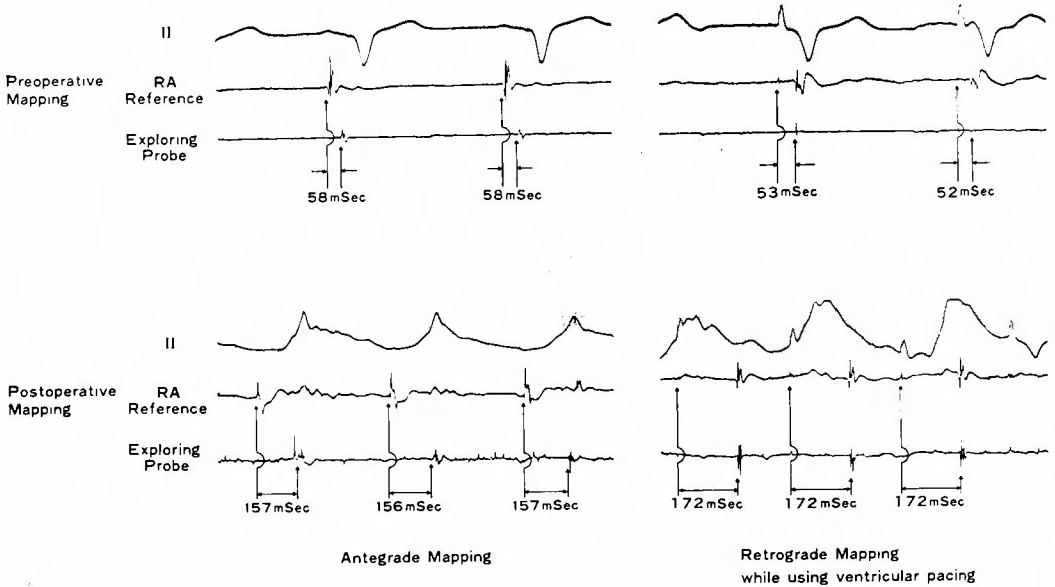


Fig 5. Epicardial electrograms from the point of pre-excitation during operation of the case 3.

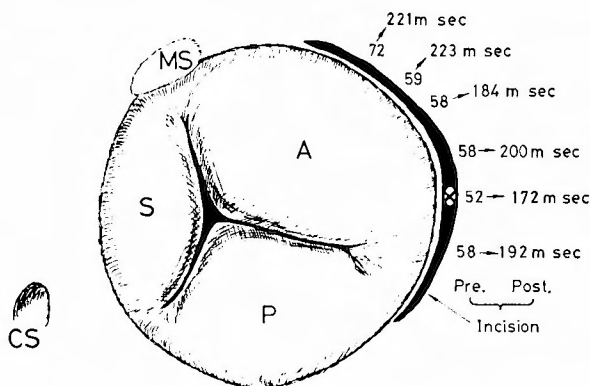
Preoperative mapping showed abnormal early AV conduction time (58 msec) with the exploring probe located on the free wall of the right ventricle near the AV groove. Preoperative retrograde mapping also showed abnormally shortened VA conduction (53 and 52 msec) with the exploring probe located on the corresponding area of the right atrium near the AV groove. Postoperative mapping on the same areas showed elongated conduction time both antegrade and retrograde direction. These are the definitive evidences of the division of the KENT bundle.

the earliest retrograde point of excitation corresponding to the middle portion of the anterior tricuspid valve. Incision and suture of the right atrial wall around that point for about 4 cm resulted in apparent elongation of both antegrade and retrograde excitation time (Fig 5, 6).

### Postoperative evaluation

Complete disappearance of the delta waves in the electrocardiograms was observed in all three cases (Table 1). Slight residual tricuspid regurgitation was proved in cases 1 and 2 after tricuspid valvuloplasty. Case 2 has an artificial pace-maker. Since operation these patients have been free of PAT for three years, seven months





**Fig 6.** Retrograde endocardial mapping during operation of the case 3.

Postoperative elongation of the VA conduction time at the site of the suspected KENT bundle (X figure). MS : membranous portion of the atrial septum, CS : coronary sinus, A : anterior tricuspid cusp, S : septal tricuspid cusp, P: posterior tricuspid cusp.

and two months respectively. However, a postoperative His electrogram study revealed the suspected presence of another retrograde conducting KENT bundle in case 3. He is now on an antiarrhythmic drug regimen (Verapamil).

**Discussion**

WPW syndrome is one of the pre-excitation syndromes<sup>10)</sup> (Table 2), and has a characteristic electrocardiogram with a short P-R, a long QRS and delta waves. The QRS complex in the WPW syndrome is thought to be a fusion complex from ventricular activation over the A-V nodal pathway and the accessory pathway (mainly KENT bundle). Many patients with WPW syndrome develop paroxysmal tachycardia attacks due to circus movements of the excitation between the atrium and the ventricle, or antegrade 1:1 conduction of atrial fibrillation.

**Table 2** The Three Forms of Pre-excitation<sup>10)</sup>

ECG Characteristics	Anatomic Tracts	Name
(1) Short P-R, long QRS with delta Wave	(a) KENT bundle or bundles (b) JAMES fibers plus MAHEIM fibers	WOLF-PARKINSON-WHITE (WPW) Syndrome
(2) Short P-R, normal QRS	JAMES fibers (posterior internodal tract)	LOWN-GANON-LEVINE (LGL) or JAMES type
(3) Normal P-R, long QRS with delta wave	MAHEIM fibers	MAHEIM type

WELLENS noted that 94 out of 107 patients with WPW syndrome had at least one electrocardiographically documented episode of tachycardia. Frequent tachycardia attacks disable patients and sometimes lead to sudden death due to ventricular tachyarrhythmias despite the prophylactic use of antiarrhythmic drugs.

Intraoperative epicardial mapping techniques were first described by DURRER and his colleagues in 1967<sup>8)</sup>, and BURCHELL and his colleagues<sup>2)</sup> succeeded in a temporary surgical block of the KENT bundle in 1967. However, definitive surgical division of the KENT bundle was first performed by COBB and his colleagues in 1968<sup>9)</sup>. We have also developed our own electrophysiological diagnostic equipment to be used during operation and have succeeded in dividing the KENT bundle in three cases, which are reported here. The first two patients also had EBSTEIN'S anomaly and a septal KENT bundle as described by GALLAGHER<sup>12)</sup>. The third patient had a KENT bundle in the anterior wall near the A-V groove of the right ventricle. We were able to divide the KENT bundle in all three cases. The second patient, however, developed complete A-V block after HARDY'S valvuloplasty for EBSTEIN'S anomaly and the third patient was suspected to have an additional retrograde conducting KENT bundle on the basis of his postoperative His bundle study.

Some authors have reported cases of multiple KENT bundles or other abnormal bypass pathways, such as a MAHEIM'S bundle, in addition to a KENT bundle<sup>3,4,19,21)</sup>. Tachycardia attacks may develop in the future in our third patient due to circus movements of excitation through a retrograde conducting KENT bundle. It is our opinion, however, that even if he develops atrial flutter or fibrillation, they cannot lead to intolerable lifethreatening ventricular tachyarrhythmias because the antegrade pre-excitation pathway (main KENT bundle) bypassing the atrioventricular ring has been definitely blocked.

Recently, SEALY and his colleagues<sup>18)</sup> reported their surgical experience with more than 100 patients. They showed improved results in many respects in the last 60 cases without any surgical deaths. They noted four locations of the KENT bundle right free wall, left free wall, posterior septal and left septal positions. Our experience includes two posterior septal and one right free wall case. We are convinced from our small experience that increased knowledge and skillful mapping techniques can widen the indications for surgical treatment of the WPW syndrome with a KENT bundle.

#### References

- 1) Becker AE, Anderson RH et al: The anatomical substrates of Wolf-Parkinson-White syndrome, a clinicopathologic correlation in seven patients. *Circulation* 57 : 870-879, 1978.
- 2) Burchell HB, Frye RL et al: Atrioventricular and ventriculoatrial excitation in Wolf-Parkinson-White syndrome (Type B), temporary ablation at surgery. *Circulation* 36 : 663-672, 1967.
- 3) Castellanos A, Agha AS et al: Double accessory pathways in Wolf-Parkinson-White syndrome. *Circulation* 51 : 1020-1025, 1975.
- 4) Coumel P, Waynberger M et al : Wolf-Parkinson-White syndrome. Problems in evaluation

- of multiple accessory pathways and surgical therapy. *Circulation* 44 : 1216-1230, 1972.
- 5) Cobb FR, Blumenschein SD et al : Successful surgical interruption of the bundle of Kent in a patient with Wolf-Parkinson-White syndrome. *Circulation* 38 : 1018-1029, 1968.
  - 6) Dreifus LS, Nichols H et al : Control of recurrent tachycardia of Wolf-Parkinson-White syndrome by surgical ligation of the A-V bundle. *Circulation* 38 : 1030-1036, 1968.
  - 7) Durrer D, Schuilenburg RM et al : Pre-excitation revisited. *Am J Cardiol* 25 : 690-697, 1970.
  - 8) Durrer, D and Roos JP : Epicardial excitation of the ventricle in a patient with Wolf-Parkinson-White syndrome. *Circulation* 35 : 15-21, 1967.
  - 9) Edmonds JH Jr, Ellison RG et al : Surgically induced atrioventricular block as treatment for recurrent atrial tachycardia in Wolf-Parkinson-White syndrome. *Circulation* 39 and 40 (Suppl 1) : 105-111, 1969.
  - 10) Ferrer MI : Pre-excitation, including the Wolf-Parkinson-White and other related syndromes. Futura Publishing Company Inc., New York, 1976.
  - 11) Gallagher JJ, Gilbert M et al : Wolf-Parkinson-White Syndrome. The problem, evaluation, and surgical correction. *Circulation* 51 : 767-785, 1975.
  - 12) Gallagher JJ, Kasell J et al : Epicardial mapping in the Wolf-Parkinson-White syndrome. *Circulation* 57 : 854-866, 1978.
  - 13) Hardy KL, May IA et al : Ebstein's anomaly : a functional concept and successful definitive repair. *J Thorac Cardio-vasc Surg* 48 : 927-940, 1964.
  - 14) Iwa T : Surgery of supraventricular tachycardia. I. Operative treatment of Wolf-Parkinson-White syndrome, II. Electrical treatment of supraventricular tachycardias with implanted radiofrequency atrial pacemaker. *Japanese Circulation Journal* 42 : 287-298, 1978.
  - 15) Neutze JM, Kerr AR et al : Epicardial mapping in a variant of type A Wolf-Parkinson-White syndrome. *Circulation* 48 : 662-666, 1973.
  - 16) Rosenbaum FF, Hecht HH et al : The potential variations of the thorax and the esophagus in anomalous atrioventricular excitation (Wolf-Parkinson-White syndrome). *Am Heart J* 29 : 281-326, 1945.
  - 17) Sealy WC and Wallace AG : Surgical treatment of Wolf-Parkinson-White syndrome. *J Thorac Cardiovasc Surg* 68 : 757-769, 1974.
  - 18) Sealy WC, Gallagher JJ et al : The surgical anatomy of Kent bundles based on electrophysiological mapping and surgical exploration. *J Thorac Cardiovasc Surg* 76 : 804-815, 1978.
  - 19) Tonkin AM, Dugan FA et al : Coexistence of functional Kent and Mahaim-type tracts in the pre-excitation syndrome. Demonstration by catheter techniques and epicardial mapping. *Circulation* 52 : 193-200, 1975.
  - 20) Wallace AG, Sealy WC et al : Surgical correction of anomalous left ventricular pre-excitation : Wolf-Parkinson-White (Type A). *Circulation* 49 : 206-213, 1974.
  - 21) Wellens HJJ : The electrophysiologic properties of the accessory pathway in the Wolf-Parkinson-White syndrome. In *The Conduction System of The Heart. Structure, Function and Clinical Implications* (edited by Wellens, Lie and Janse), H.E. Stenfert Kroese B.V., Leiden, 1976, p. 567-587.
  - 22) Wolferth CC and Wood FC : The mechanism of production of short P-R intervals and prolonged QRS complexes in patients with presumably undamaged hearts : Hypothesis of an accessory pathway of auriculo-ventricular conduction (bundle of Kent). *Am Heart J* 8 : 297-311, 1933.
  - 23) Wood FC, Wolferth CC et al : Histologic demonstration of accessory muscular connections between auricle and ventricle in a case of short P-R interval and prolonged QRS complex. *Am Heart J* 25 : 454-462, 1943.

## 和文抄録

## Wolf-Parkinson-White 症候群の外科治療

## — 3 症例の経験 —

京都大学医学部外科第2講座 (指導: 日笠頼則教授)

龍田 憲和, 三木 成仁, 小西 裕,  
松田 光彦, 谷口 亭一, 石原 浩,  
村田 眞司, 高 欽澤, 日笠 頼則

京都大学医学部内科第3講座 (指導: 河合忠一教授)

小西 與承, 松山 栄一

近畿大学医学部麻酔学教室

末 包 慶 太

Wolf-Parkinson-White (WPW) 症候群は特徴的な心電図所見と頻脈発作を伴う疾患である。頻脈発作は患者の活動力を低下させるばかりか、時には致死的な心室性頻脈に移行する。

抗不整脈剤、人工ペースメーカー装置による治療も有効であるが根治的治療とは云い難い。最近電気生理学的心表面地図作製法の進歩によってケント束の位置を診断して切断する外科的治療が開発され WPW 症

候群に対する根治的治療法として注目されている。

WPW 症候群の3例に対し、われわれの測定装置によって術中心表面地図を作製し、全例ケント束の切断に成功した。この中2例はエプスタイン奇形を同時に合併し、何れも後部中隔にケント束が証明され、残る1例は右室自由壁にケント束が存在した。最後の症例は術後ヒス束心電図検査によって弱い逆方向伝導性のケント束の遺残が疑われている。