

Title	Surgical Treatment of Thoracic Aortic Aneurysm
Author(s)	KOIE, HISAAKI; KUSUHARA, KENJI; HIKASA, YORINORI
Citation	日本外科宝函 (1979), 48(1): 60-72
Issue Date	1979-01-01
URL	<a href="http://hdl.handle.net/2433/208322">http://hdl.handle.net/2433/208322</a>
Right	
Type	Departmental Bulletin Paper
Textversion	publisher

---

臨 床

---

## Surgical Treatment of Thoracic Aortic Aneurysm

HISAAKI KOIE and KENJI KUSUHARA

From the Department of Cardiovascular Surgery, Tenri Hospital

YORINORI HIKASA

From the 2nd Department of Surgery, Faculty of Medicine, Kyoto University

Received for Publication Oct. 2, 1978

In the surgery of thoracic aortic aneurysm, temporary bypass, partial left heart bypass and total cardiopulmonary bypass have been often employed. Temporary bypass which is regarded as an intricate and time-consuming technique is not applicable if aneurysmal process involves the proximal portion of the ascending aorta. Clotting factors in the blood is not wasted by using this technique however. Heparin is usually not needed. In addition, possible respiratory complications which might occur if heart lung bypass is instituted can be eliminated.

Seven cases of thoracic aortic aneurysm were operated on during a period from 1972 through 1973 at the 2nd Surgical Department of Kyoto University Hospital and during a period from 1974 through April 1978 at Tenri Hospital employing a technique of temporary bypass combined with hypothermia of approximately 30°C. One patient with acute dissection of the aorta combined with extensive necrosis of right lower extremity expired. Six patients survived surgery without any significant complication and were discharged in good condition. These cases were analysed.

### Clinical Materials

Ages of these seven patients averaged 56 years, the youngest being 42 and the oldest being 64-year-old (Table 1). Woven graft with a diameter of either 14 mm (Cases 2,3) or 16 mm (Cases 1, 4, 5, 6, 7) was used for the temporary bypass. Proximal end of temporary graft was anastomosed directly to the aorta. This was done for the purpose of obtaining good bypass-flow and reserving a space for the placement of aortic clamp between left subclavian and left common carotid arteries in cases when aneurysmal change extends up to the origin of left subclavian artery. Average bypass time was 2 hours. Urine output during temporary bypass was 20 to 130 ml/hour.

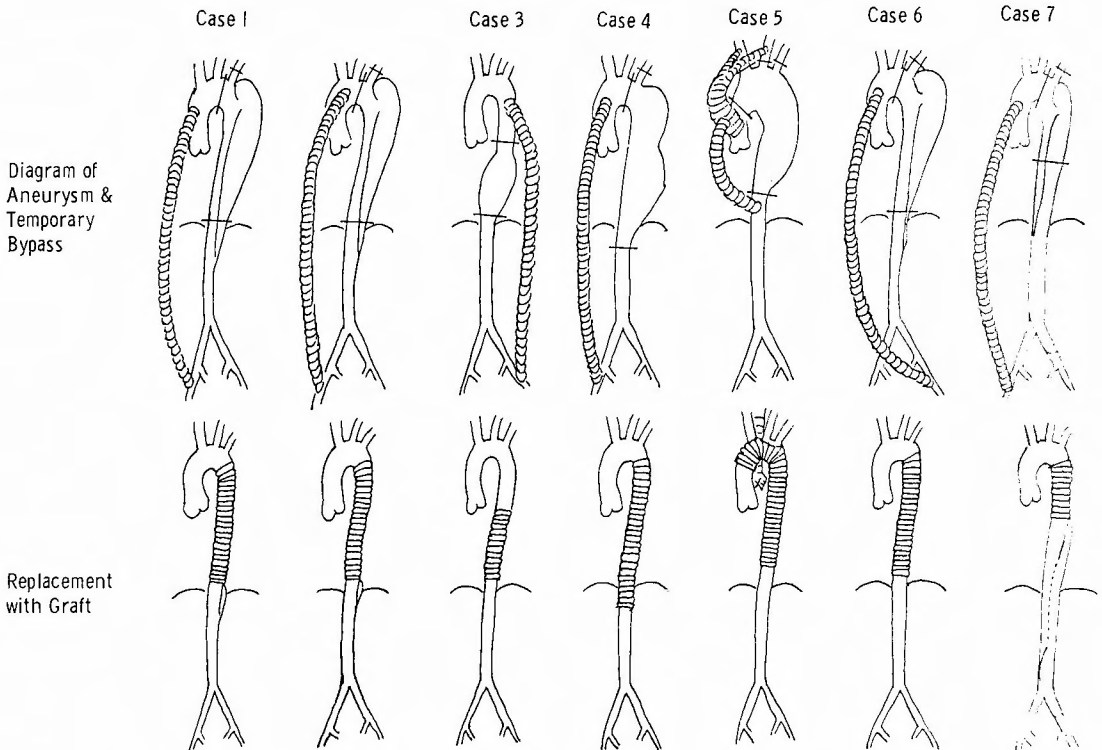
---

Key words : Aortic aneurysm, Thoracic aorta, Temporary bypass, Aortic surgery.

Present address : The Department of Cardiovascular Surgery, Tenri Hospital, Tenri, Nara, 632, Japan.

**Table 1.** Cases of surgery for thoracic aortic aneurysm by combined use of temporary bypass and hypothermia

	Age	Sex	Type of aneurysm	Operation	Result	
Case 1.	K. T.	60	male	Chronic dissection Type IIIb (DeBakey)	Replacement of descending thoracic aorta	Survived
Case 2.	K. T.	50	female	Chronic dissection Type IIIb (DeBakey)	Replacement of descending thoracic aorta	Survived
Case 3.	S. Y.	64	male	Arteriosclerosis Descending thoracic aorta	Replacement of descending thoracic aorta	Survived
Case 4.	S. S.	55	male	Arteriosclerosis Thoracoabdominal aorta	Replacement of thoracoabdominal aorta	Survived
Case 5.	Y. K.	59	female	Syphilis Aortic arch involved	Replacement of thoracic aorta & left pneumonectomy	Survived
Case 6.	T. N.	42	male	Chronic dissection Type IIIb (DeBakey)	Replacement of descending thoracic aorta	Survived
Case 7.	N. S.	60	male	Acute dissection with necrosis of right lower extremity	Replacement of descending aorta. Reentry creation at the aortic bifurcation	Died



**Fig. 1** Thoracic aortic aneurysm, temporary bypass as well as replaced prosthetic graft are shown in each case.

As described above, surgery was performed at the temperature of about 30°C cooled by surface cooling method.

Chest was opened through the left fourth or fifth intercostal space. From the same skin incision, another opening was made through the seventh or eighth intercostal space in order to manipulate smoothly the lower portion of descending thoracic aorta (Fig. 2). In

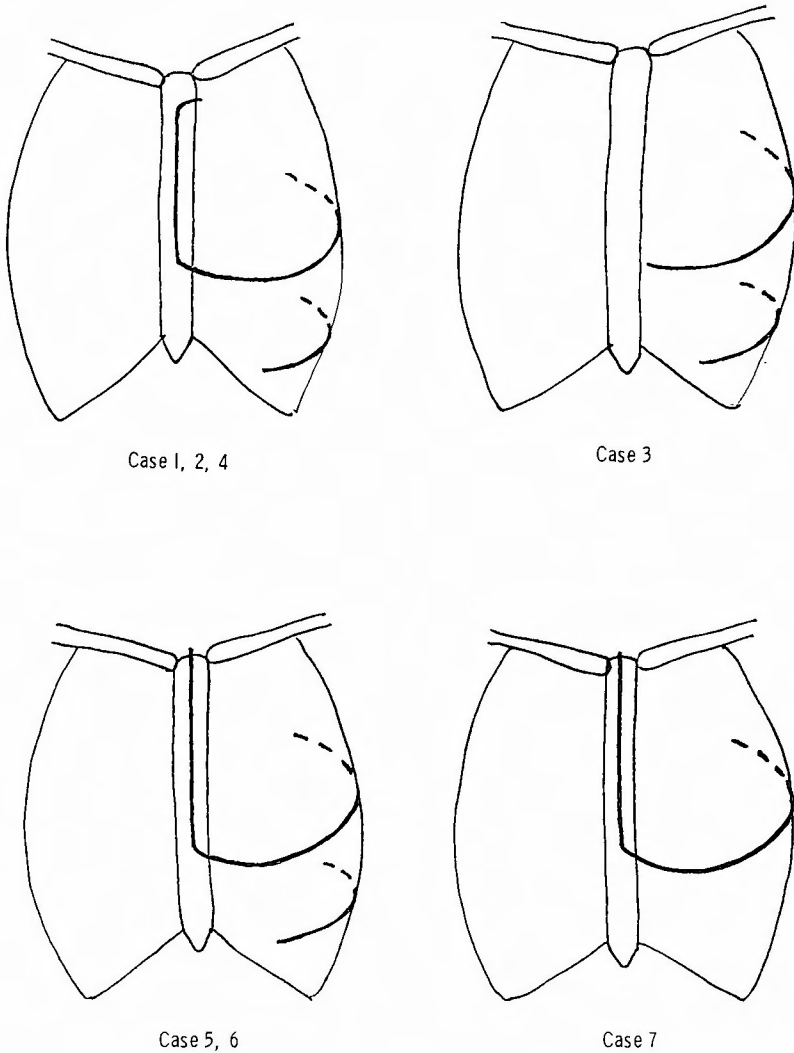


Fig. 2 Thoracotomy sites are indicated by thick lines.

six cases, thoracotomy through the upper intercostal space was extended to the middle of sternum and median splitting of upper portion of sternum was added. In the earlier cases (Cases 1, 2 and 4), longitudinal sternal incision ended at the left first intercostal space without reaching to the suprasternal notch, because it was expected to give less injury to the thorax. This exposure however, was not always sufficient and a better exposure could

certainly be obtained by extending the sternal incision up to the suprasternal notch. In the later cases incisions were extended to the suprasternal notch. Bilateral thoracotomy or transection of sternum was avoided in order to prevent postoperative respiratory impairment. For the purpose of preventing cerebral embolism, heparin was given to one patient whose innominate and left common carotid arteries were attached with temporary bypass for the resection of an aneurysm involving the transverse aortic arch. There was no apparent renal nor pulmonary impairment due to the surgery except in one patient of acute dissecting aneurysm who was mentioned earlier in this report. Average operation time was 8 hours. Respiratory impairment was present before surgery in Cases 1 and 5. These two cases and Case 7 (expired) will be presented further for details.

#### *Case reports*

Case 1 A 60-year-old male patient with dissecting aneurysm of descending aorta (Type IIIb by DEBAKEY's classification) had accident of falling down a flight of stairs one and a half years prior to admission. About that time he started to have pain in his anterior chest and back. He has had 30 years' history of bronchial asthma. He had been admitted to a hospital for lung tuberculosis at the age of 55. At the time of present admission, old tuberculous lesion was noticed at the right upper lung field by chest roentgenogram. Pulmonary function test revealed a vital capacity was 78%. Maximal breathing capacity was 43% of predicted value. On electrocardiogram slight depression of  $V_4$  and  $V_5$  was noticed. Aortogram revealed the dissecting aortic aneurysm, starting right below the origin of left subclavian artery (Fig. 1).

Surgery was performed on November 13, 1972. Patient was cooled to  $30^{\circ}\text{C}$  by surface cooling. Small tubes were introduced percutaneously to the right radial and left femoral arteries for pressure study. Chest was opened through the left fourth intercostal space.

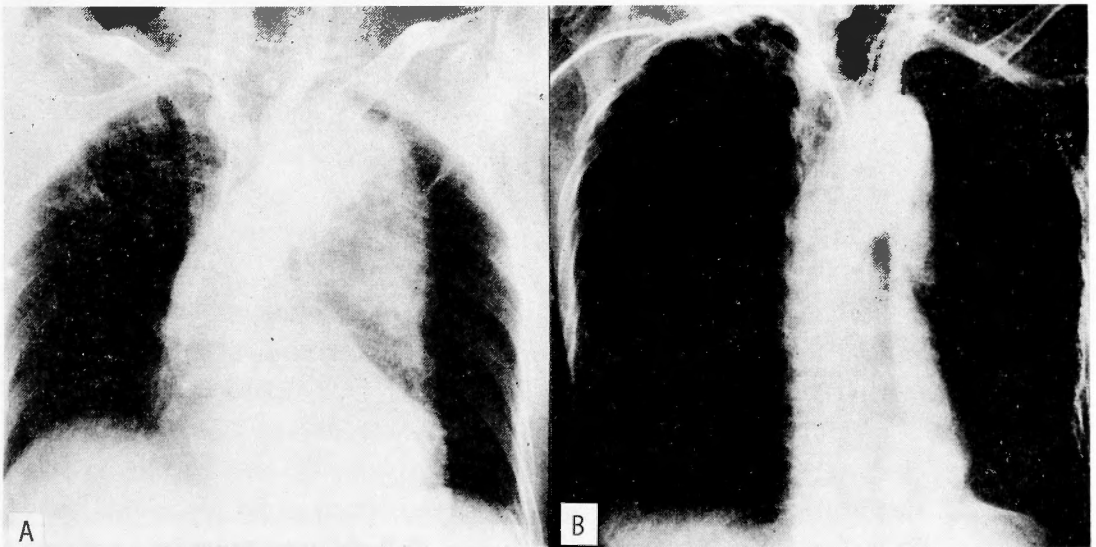


Fig. 3 Case 1 K.T. A) Preoperative aortogram B) Postoperative aortogram

This incision was extended to the middle of sternum, then upwards to the left first intercostal space splitting the sternum. Under the same skin incision, another opening through the seventh intercostal space was added for the purpose of easing the manipulation to the lower portion of descending thoracic aorta. By these incisions, ascending aorta and transverse aortic arch as well as the descending aorta were well exposed. Temporary bypass graft was attached between ascending aorta and right external iliac artery using a 50 cm long woven graft with a diameter of 16 mm. Clamps were placed to the aorta between the orifices of left subclavian and left common carotid arteries, and just above the diaphragm. There was no difference of mean pressures between radial and femoral arteries at that time. Therefore, it was concluded that the bypass was quite efficiently functioning.

Aneurysm was resected from the aortic portion right below the origin of the left subclavian artery for almost entire length of descending thoracic aorta. It was then replaced with a woven Teflon graft with a diameter of 25 mm. Temporary bypass time was 2 and a half hours. During that time urinary output was more than 50 ml/hour. Operation time was 8 hours and 40 minutes. Postoperative course was quite uneventful. There was no respiratory complication nor significant postoperative bleeding. Throughout postoperative periods urinary output was always more than 1000 ml per day. Highest value of blood urea nitrogen was 27 mg/dl indicating only slight elevation.

Case 5 (Y.K.)<sup>15)</sup> A 59-year-old female patient with a luetic aortic aneurysm. Eight months prior to the admission, she started to have pain in her back. She was seen by a cardiologist and the diagnosis of aneurysm of thoracic aorta was made. Recently, she developed dyspnea and palpitation at rest and also anterior chest pain. Owing to the severe back pain, it had become impossible for her to lie down and take a recumbent position. It was hardly possible to walk by herself. Roentgenogram revealed the atelectasis

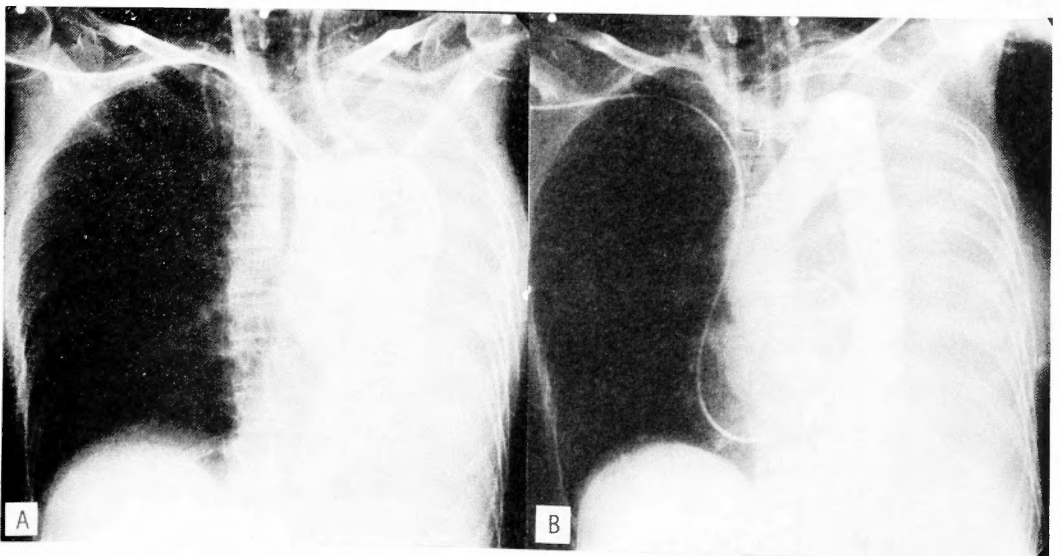


Fig. 4 Case 5 Y.K. A) Preoperative aortogram B) Postoperative aortogram

of entire left lung with the shift of mediastinum to the left. Aortogram revealed an extensive aneurysm spreading from the distal portion of the ascending aorta to the distal portion of the descending thoracic aorta (Fig. 4).  $PCO_2$  and  $PO_2$  of arterial blood taken while breathing room air were 28.4 mmHg and 61.1 mmHg respectively. Serological test for syphilis was strongly positive. Phenolsulfonphthalein excretion in 2 hours was 53%. Blood urea nitrogen level was 47.8 mg/dl. Serum creatinin level was 1.7 mg/dl. There was no abnormal ST. T segment of electrocardiogram. Blood pressure was 98/64 mmHg.

Surgery was performed on July 30, 1976. Patient was cooled by surface cooling method. Skin incision was started at 32°C. Lowest rectal temperature during surgery was 29°C. Chest was opened through the left fifth intercostal space. This incision was extended to the middle of sternum, then up to the suprasternal notch by splitting the upper two thirds of sternum. Upper portion of the left anterior chest wall was lifted up like a flap. Ascending aorta and transverse aortic arch as well as its three major branches were well exposed. Pericardium was opened. It was confirmed that the aneurysm was a fusiform one extending from the distal portion of the ascending aorta to the descending thoracic aorta ending at 7 to 8 cm above the diaphragm. In order to provide better exposure of distal part of descending aorta, incision of the left eighth intercostal space was added. It was noticed that the left lung was completely atelectatic. A 16 mm woven straight graft was attached to the side of a 25 mm woven bifurcated graft and was prepared for use of temporary bypass. As was shown in Fig. 1, to the side walls of innominate artery, left common carotid artery, descending aorta immediately above the diaphragm and intact proximal portion of the ascending aorta temporary bypass graft was attached by end to side anastomosis. Heparin was given at a dose of 1.5 mg per kilogram of body weight and was added later at a dose of 1 mg/kg. After starting temporary bypass, aorta and its three major branches were cross-clamped excluding the aneurysm. Aneurysm was opened longitudinally. It was noticed that the left main bronchus was compressed and was occluded by the aneurysm. Vertebral column was eroded remarkably. There was a large amount of blood clot inside of the aneurysm. Atelectatic lung was not inflated at all by relieving the compression to the bronchus. While evacuating the clot inside of the aneurysm, necrosis and perforation of the wall of left main bronchus was noticed. So left pneumonectomy was performed. One end of a 25 mm woven Dacron straight graft was anastomosed to the distal open end of ascending aorta. Innominate artery was attached by end to side anastomosis to the side of the graft. Left common carotid and left subclavian arteries together with a small cuff of the aortic wall were attached to the side of the graft. Opposite end of the graft was anastomosed to the distal open end of descending aorta.

There was no change of blood pressure by placing the aortic clamp and diverting blood flow to the bypass. Urine volume during temporary bypass time of approximately two hours and fifty minutes was 380 ml. Operation time was 9 hours and 5 minutes. Bleeding amount throughout the operation was 4,500 ml. Volume of drainage through thoracotomy tube after surgery amounted to 2,900 ml. This patient took uneventful course after surgery,

PCO<sub>2</sub> and PO<sub>2</sub> of arterial blood taken while breathing room air 17 hours after surgery were 40.9 mmHg and 73.6 mmHg respectively. Oxygen therapy was discontinued after this 17 hour period. Aortogram taken one month after surgery revealed satisfactory blood flow through the replaced grafts. She was discharged in good condition 39 days after surgery.

Case 7 (expired case) This 66-year-old patient had severe pain in his upper abdomen and in his back suggestive of acute dissection of the aorta, 13 days prior to the admission. He started to have ischemic change over the right lower extremity 3 days prior to the admission. At the time of admission, his blood pressure was 230/110 mmHg. Serum creatinin level was 5.7 mg/dl. Blood urea nitrogen was 53.7 mg/dl. Phenolsulfonphthalein excretion for 2 hours was 17%. Myoglobin was positive in the urine. Serum glutamic oxalacetic transaminase was 1,038 u. and serum creatine phosphokinase was more than 700 Sigma unit. Aortogram revealed the dissection of the aorta of Type IIIb by DEBAKEY's classification. Dissection extended to the left iliac artery disturbing the blood flow of the arteries which were taking off the abdominal aorta. Blood flow to the right iliac artery was almost completely interrupted. Left renal artery took off the aorta through its dissected cavity.

Thoracotomy was performed and temporary bypass was attached. 5 cm long portion of the descending thoracic aorta including the intimal tear located just below the origin of the left subclavian artery was resected. Then, prosthetic graft was replaced. However, the pulsation of the right femoral artery did not recover by this procedure. Therefore, the abdomen was opened, and dissected intima which occluded the orifice of the right iliac artery was widely resected at the bifurcation of the abdominal aorta, so that the blood flow could be restored to the right lower extremity. Postoperatively, this patient was connected to a respirator for 8 hours, then was transferred into an oxygen tent because of good respiratory state. However, renal insufficiency continued and he deteriorated gradually. He died 13 days later. Autopsy revealed massive necrosis of the muscle of right lower extremity and myoglobin cast of renal tubules. It was suggestive that these pathological findings might have contributed in the continuation of renal insufficiency.

### Discussion

Surgery for the thoracic aortic aneurysm has come to be widely performed at many hospitals in recent years. And its technique has become rather established. According to the reports by DEBAKEY and coworkers in 1966<sup>2)9)</sup>, more than 90% of patients survived following the surgery for descending thoracic aortic aneurysm. 60 to 80% of the patients who had surgery for the aneurysm of transverse aortic arch survived. INOUE and others<sup>12)</sup> reported that 23 patients (24.5%) of the 94 patients who had surgery for the aneurysm of thoracic aorta expired. They also reported that their operative result improved remarkably in recent years. Such advances of the result of the surgery for thoracic aortic aneurysm may certainly be due to the remarkable improvement on the operative technique, quality of prosthetic graft, supportive technique, postoperative care and the like. However, further



improvement in these aspects is still necessary.

As is well known, because it is often necessary to crossclamp the aorta involving the aneurysm, various supportive techniques have been devised and clinically practised in order to cope with left heart overload and ischemia of peripheral organs which may be caused by the crossclamping. These techniques are 1) hypothermic technique, 2) utilization of artificial heart lung machine (left heart bypass technique is included) 3) temporary bypass technique which does not need artificial heart and so on.

Hypothermia can be induced either by surface cooling or by blood stream cooling. This is often employed in combination with temporary bypass or extracorporeal circulation. Under hypothermic state, duration of ischemia of important organs such as brain, heart and so on are prolonged, and sudden and disastrous changes of hemodynamics can be well tolerated. Therefore, we have practised hypothermia by surface cooling of about 30°C in all cases with the recognition that such a condition is safe and relatively easy to have.

20°C of hypothermia by means of blood stream cooling and the interruption of blood flow to the brain for 36 minutes was practised by NICKS<sup>22)</sup> for the surgery of the aneurysm of ascending and transverse portions of the aorta. This patient died due to postoperative brain damage. Therefore, it would be assumed that such interruption of blood flow in the elderly patients relying on hypothermia alone might be too risky.

Heart lung machine is often used for the surgery of the aneurysm of ascending and transverse portions of the aorta<sup>1)</sup>. In the situation that there is no intact portion at the ascending aorta available for the attachment of temporary bypass graft and aortic interruption is needed, it would be almost the only way. When the transverse aortic arch is involved by an aneurysmal change, and innominate and common carotid arteries are to be cross-clamped temporarily, cerebral blood flow should be maintained by mean of inserting separate cannulae to these arteries. DEBAKEY and coworkers<sup>10)</sup> succeeded in the resection of fusiform aneurysm of aortic arch in 1957 for the first time in the world employing this technique. Owing to the recent improvement in the quality of prosthetic graft<sup>23)</sup> as well as to a generally adopted technique that is wrapping the replaced graft with the wall of aneurysm, the problem of bleeding tendency due to the employment of heart lung machine has become far less critical than previously been considered. However this problem can not be neglected. Moreover, if heart lung bypass lasts for a long time significant impairment of pulmonary function may occur. Therefore, up to now, there have been many attempts to shorten the time for extracorporeal circulation. The technique of HOU-YOU-LIN for the surgery of the aneurysm of aortic arch is that an end of the graft is first anastomosed to the side of the descending aorta. Successively the left subclavian artery, the left carotid artery and the innominate artery are attached by end to side anastomosis to the graft. Extra-corporeal circulation is only necessary for the last step of the operation, the anastomosis of the graft to the proximal aorta. There is another way that a bifurcated graft is first connected between ascending aorta and innominate and left carotid arteries by end to side anastomosis for permanent bypass, then under partial bypass, replacement

of aortic arch is performed<sup>17)19)</sup>.

For the surgery of descending aortic aneurysm, it is well known that DEBAKEY and coworkers<sup>2)</sup> had good operative result by means of left heart bypass technique. By the use of this technique, heparin is generally not necessary and consumption of clotting factors in the blood by use of heart lung machine can be avoided. Therefore, an advantage of this technique is that bleeding problems are less. In addition, anxieties about the respiratory impairment which may occur following the prolonged extracorporeal circulation time is reduced. INOUE and coworkers<sup>13)</sup> had excellent results for the surgery of descending thoracic aorta by employing temporary long external bypass. His technique consisted of connecting a temporary bypass graft from the left subclavian artery to a femoral artery with 10 to 14 mm graft under left thoracotomy. However, with his technique, aortic cross-clamp has to be placed to the periphery of the origin of left subclavian artery. Moreover, when aneurysm is huge, surgical manipulation to the subclavian artery becomes often difficult. Therefore, we have anastomosed the proximal end of temporary bypass graft directly to the aorta, in most cases to its ascending or transverse portion using a graft of rather wide diameter, either 14 or 16 mm. Then, aortic clamp can be placed between left subclavian artery and left carotid artery. In order to do such an attachment, however, a simple left thoracotomy may offer very limited exposure. Therefore the upper portion of the sternum was split for the purpose of exposing the proximal portion of thoracic aorta. In addition to the incision through an upper intercostal space, another incision through a lower intercostal space was placed through the same skin incision, for an easy manipulation of the aorta right above the diaphragm.

Now, in regard of the blood flow through a bypass graft to the lower part of the body, optimal flow rates seem to range between 20 ml to 80 ml per kilogram of body weight according to various reports<sup>7)13)20)</sup>. Such various flow rates for present clinical use seem to preserve postoperative renal function well in the ordinary circumstances. In our present cases too, there was no postoperative renal impairment except for a case in which renal function was impaired and extensive ischemia of a lower extremity was present before surgery. In 1955, COOLEY and others reported a patient who had surgery for the aneurysm of aortic arch employing temporary bypass technique. This patient died on the sixth day after surgery due to cerebral damage from temporary ischemia resulting from thrombosis of the right carotid shunt. Later, DEBAKEY and others<sup>9)</sup> established this surgical technique for the aneurysm of aortic arch, and has come to have the operative survival rate of 60 to 80%. In Japan the first success of this surgery was reported by KIMOTO<sup>14)</sup> in 1960. KONNO and others<sup>16)</sup> recently reported two cases who had surgery for the aneurysm of aortic arch by this method, although one of them was lost due to the thrombus generated inside of the temporary bypass. We have used heparin for such a case which needed bypass grafts to the brain. As the result there was no brain symptoms at all. Bleeding was not excessive during that surgery.

In recent years, for temporary bypass, the use of Tygon tube<sup>5)</sup> and others<sup>24)</sup> instead of

artificial graft has been attempted in order to simplify the technique. Also, there are other simplified techniques like attachment of permanent graft to the side of the aorta. In 1960, MULLER<sup>21)</sup> has succeeded in the surgery for the aneurysm of aortic arch by means of anastomosing the graft and the arteries one by one, elaborating the technique of the anastomosis between ascending aorta and the graft. BJORK<sup>3)</sup> performed the surgery in 1963 by almost same method and with hypothermia of 28°C. Recently SHU HSUN CHU<sup>6)</sup> performed the surgery by connecting a graft by side to end anastomosis only. The aneurysm was then resected and the bypass was left permanent. In our case of the aneurysm of aortic arch, the graft was replaced in the normal position. We thought that such way of replacement might be safe from the aspects of turbulence and stasis of blood stream and creation of unprotected aortic stump which might be exposed directly to the high blood pressure.

Next, in regard of the way of thoracotomy, left thoracotomy is almost always employed for the surgery of descending thoracic aorta. For the surgery of ascending aortic aneurysm, median splitting is the routine procedure. For the surgery of the aneurysm of aortic arch however, various approaches have been taken. According to DEBAKEY and others<sup>9)</sup>, aneurysms limited to the transverse aortic arch usually were approached through a bilateral anterior third intercostal space incision with transverse division of the sternum. If additional exposure became necessary, this was obtained by a superior extension of the incision and division of the sternum. In some instances in which it was necessary to attach the distal limb of the temporary bypass graft well down on the descending thoracic aorta owing to extensive involvement of its proximal segment by the aneurysm, incision was extended from the right third intercostal space across the sternum into the left fourth intercostal space in order to provide better exposure of the lower descending thoracic aorta. This approach of bilateral thoracotomy with transection of sternum was used by MULLER<sup>21)</sup>, BJORK<sup>3)</sup>, ASANO<sup>1)</sup>, SHU HSUN CHU<sup>6)</sup> and others. With this approach good exposure is provided. However, it is not denied that respiratory impairment may be more likely to occur. As a way of avoiding bilateral thoracotomy, there is an approach by median sternal splitting alone<sup>11)18)22)</sup>. With this incision however, it is rather hard to obtain good exposure, and it seems inappropriate for the surgery of aneurysm which is extensive reaching down to the descending aorta. Left thoracotomy accompanied by sternal splitting incision has been done by COOLEY<sup>10)</sup>, CARPENTIER<sup>4)</sup>, MIYAUCHI<sup>19)</sup> and KONNO<sup>16)</sup>. COOLEY transected sternum, but he did not open right pleural space. Our present approach is left thoracotomy with a longitudinal splitting of upper two thirds of sternum. We think that splitting of lower part of sternum is unnecessary.

For the manipulation of the aorta locating just above the diaphragm, it is useful to add another intercostal incision at the lower portion of thorax using the same skin incision.

It often happens that the aneurysm compresses the neighboring organs such as trachea, bronchus or esophagus<sup>9)</sup>. LEFRAK<sup>18)</sup> reported a 76-year-old man who had severe respiratory insufficiency due to tracheal compression by a large aneurysm of the ascending, transverse

and descending thoracic portions of the aorta and had resection of aneurysm. Follow up evaluation 1 year after surgery revealed the absence of all signs and symptoms of respiratory insufficiency. CARPENTIER<sup>4)</sup> reported a case who had an aneurysm of aortic arch with complete atelectasis of left lung due to the compression of left bronchus. This patient was operated using the HU-YU-LIEN's technique, followed by uncomplicated postoperative course. In such cases whose respiratory impairment was feasible to be relieved by means of the resection of aneurysm and decompression of air way as mentioned above, surgical considerations could be about same as in the ordinary surgical cases for aortic aneurysm. However, like our present case, if atelectasis is not relieved by inflating the air way, and if there is necrosis and perforation in the wall of main bronchus, it would be unavoidable to remove the lung which remained atelectatic. Therefore, in such a case, it would be the only way for the survival of the patient to reserve the function of the remaining lung as much as possible. Left thoracotomy alone, avoidance of transection of sternum and to leave the lower portion of sternum unsplit, such techniques of thoracotomy and unemployment of extracorporeal circulation which might cause respiratory trouble seemed to contribute very much to the survival.

### Summary

Temporary bypass was employed in seven cases of thoracic aortic aneurysm and the replacement with prosthetic graft was performed. Among them, one patient with acute dissection of the aorta expired. However, all the other patients took uneventful postoperative course without any significant renal and pulmonary complications. These cases were studied. Supportive techniques and approaches for the surgery of the thoracic aortic aneurysm were discussed. For the purpose of preventing from postoperative respiratory complications, our present way of approach which comprised left thoracotomy, avoidance of transection of sternum and to leave the lower portion of sternum unsplit, as well as the employment of temporary bypass in combination with hypothermia of 30°C by surface cooling method may be very appropriate.

Read at th XIII World Congress on Diseases of the Chest, Kyoto, Japan. July 2-7, 1978.

### References

- 1) Asano K, Sakurai Y et al: Separate cardiopulmonary bypass as an aid of surgery of thoracic aortic aneurysms. *Jap J Thor Surg* **23**: 77-82, 1970.
- 2) Bloodwell RD, Hallman GL et al: Aneurysms of the descending thoracic aorta: Surgical considerations. *Surg Clin North America* **46**: 901-911, 1966.
- 3) Bjork VO: Successful replacement of the total aortic arch for aneurysm. *J Thorac Cardiovasc Surg* **45**: 817-823, 1963.
- 4) Carpenter A, Guilment D et al: Aneurysm of the aortic arch. *Thorax* **23**: 349-354, 1975.
- 5) Chu SH and Lien WP: Resection of aortic arch aneurysm. A simplified technique. *J Thorac Cardiovasc Surg* **71**: 846-852, 1976.
- 6) Chu SH, Lee YT et al: Resection of aneurysm of the aortic arch without cardiopulmonary bypass. *J Thorac Cardiovasc Surg* **74**: 928-934, 1977.
- 7) Conolly JE, Kountz SL et al: Left heart bypass: Experimental and clinical observations on its

- regulation with particular reference to maximal renal blood flow. *J Thorac Cardiovasc Surg* **44**: 577-588, 1962.
- 8) Cooley DA, Hahaffey DE et al: Total excision of the aortic arch for aneurysm. *Surg Gyn & Obstet* **101**: 667-672, 1955.
  - 9) DeBakey ME, Beall AC et al: Resection and graft replacement of aneurysms involving the transverse arch of the aorta. *Surg Clin North America* **46**: 1057-1071, 1966.
  - 10) DeBakey ME, Crawford ES et al: Successful resection of fusiform aneurysm of aortic arch with replacement by homograft. *Surg Gyn & Obst* **105**: 657-664, 1957.
  - 11) Griep RB, Stinson EB et al: Prosthetic replacement of the aortic arch. *J Thorac Cardiovasc Surg* **70**: 1051-1060, 1975.
  - 12) Inoue T, Kawata K et al: Surgical treatment of the aortic disease. *Jap J Thor Surg* **31**: 91-97, 1978.
  - 13) Inoue T, Kawata K et al: Studies on temporary long external by-pass method on temporary occlusion of the descending thoracic aorta. *Jap J Thor Surg* **22**: 538-549, 1969.
  - 14) Kimoto S, Wada T et al: Surgical treatment of aneurysm of the aortic arch by temporary bypassing. *J Clin Surg (Rinshogeka)* **15**: 881-887, 1960.
  - 15) Koie H, Yasuda R et al: Successful resection and replacement of an aneurysm involving entire transverse aortic arch combined with left pneumonectomy. *Arch Jap Chir* **47**: 394-400, 1978.
  - 16) Konno S, Okumori M et al: Resection of aneurysm of the aortic arch using a trifurcation temporary bypass graft. *Jap J Thor Surg* **30**: 707-712, 1977.
  - 17) Larmi TKI and Karjola P: Resection of aneurysm of the transverse aortic arch. *J Thorac Cardiovasc Surg* **68**: 70-75, 1974.
  - 18) Lefrak EA, Stevens PM et al: Respiratory insufficiency due to tracheal compression by an aneurysm of the ascending, transverse, and descending thoracic aorta. Successful surgical management in a 76-year-old man. *J Thorac Cardiovasc Surg* **63**: 956-961, 1972.
  - 19) Miyauchi Y, Saito A et al: Resection of aortic arch aneurysm using permanent graft-bypass and partial extracorporeal circulation. *Jap J Thor Surg* **30**: 82-90, 1977.
  - 20) Morris GC, Witt RR et al: Alterations in renal hemodynamics during controlled extracorporeal circulation in the surgical treatment of aortic aneurysm. *J Thor Surg* **34**: 590-598, 1957.
  - 21) Muller WH, Warren WD et al: A method for resection of aortic arch aneurysm. *Ann Surg* **151**: 225-230, 1960.
  - 22) Nicks R: Aortic arch aneurysm resection and replacement: a protection of the nervous system. *Thorax* **27**: 239-245, 1972.
  - 23) Onishi K, Kawashima Y et al: Operative results for thoracic aneurysms. *JJSA* **7** **79**: 83-87, 1978.
  - 24) Verdant A: Shunting technique for treatment of aortic arch aneurysm. *J Thorac Cardiovasc Surg* **72**: 947-947, 1976.

## 和文抄録

## 胸部大動脈瘤の外科治療について

天理よろづ相談所病院心臓血管外科

鯉江久昭, 楠原健嗣

京都大学医学部外科学教室第2講座

日笠頼則

胸部大動脈瘤手術に於ける1時的バイパス法使用の利点は、出血量のすくない事その他、体外循環法採用時に見られる様な呼吸器合併症の発生を避け得る事であろう。我々は7例(平均年齢57才)の胸部大動脈瘤切除人工血管置換手術を本法を用いて実施した。そのうち急性解離性大動脈瘤の1症例を術後13日目に下肢の広範な壊死等に由る腎不全で失った他はすべて術後に著明な合併症を来すことなく生存退院せしめ得た。

全例で1時的バイパスの中枢端を大動脈に直接吻合し、そのうち5例で上行弓部大動脈、外腸骨動脈間に設置した。平均バイパス時間は2時間で、その間の尿量は1時間20ccないし130ccであった。30°C前後の表面冷却低体温を併用した。開胸は左第4或いは第5肋間開胸に加うるに、同一皮切下で下部肋間開胸を通常追加した。6例に於いて逆コの字形に胸骨上半の縦切開を追加したが胸骨横断せず両側開胸を避けた。胸骨下部の縦切開は不必要と考え行わなかった。

肺結核の陳旧性病巣と30年余の気管支喘息の既往を有し、術前1秒率54%、%肺活量78%であった解離性下行大動脈瘤症例で術後呼吸器合併症や著明な出血を見なかった。特記すべき1例は59才女子、上行大動脈遠位部から下行胸部大動脈下部に及ぶ紡錘状大動脈瘤の全置換と、左肺全摘を実施した症例である。術前高度の呼吸不全を有した。25mm径Y型人工血管及び16mm径人工血管を1時的バイパスに使用した。大動脈置換に加うるに、修復不能な左気管支壁壊死と左肺無気肺のため左肺全摘を余儀なくされたが、術後は全く順調で術後17時間で酸素テント等の酸素療法を必要としなくなった。

胸部大動脈瘤手術に際し我々の採用しているこの様な方法、即ち胸骨横断を避け片側のみ開胸し、胸骨下部の縦切開はおこなわず、表面冷却軽度低体温併用1時的バイパス法を採用する術式が術後呼吸器合併症を防ぐうえに大いに有効であると考えられる。