

Title	Preinvasive Adenocarcinoma of the Vermiform Appendix
Author(s)	NAGAMINE, SHINICHI; TERAJ, TAKEHISA; NAKATAKE, MINORU; YOKOTANI, KUNIIHIKO; OHARA, HIROSHI; YAMAUCHI, YOICHI; KATSURA, YOSHITAKA; IRIE, ZENICHI
Citation	日本外科宝函 (1978), 47(2): 231-239
Issue Date	1978-03-01
URL	http://hdl.handle.net/2433/208259
Right	
Type	Departmental Bulletin Paper
Textversion	publisher

症 例

Preinvasive Adenocarcinoma of the Vermiform Appendix

SHINICHI NAGAMINE*, TAKEHISA TERAJ, MINORU NAKATAKE,
KUNIHICO YOKOTANI, HIROSHI OHARA and YOICHI YAMAUCHI

Department of Surgery, National Himeji Hospital

YOSHITAKA KATSURA

Department of Clinical Pathology, National Himeji Hospital

ZENICHI IRIE

Irie Hospital

Received for Publication Dec. 5, 1977

Primary adenocarcinoma of the vermiform appendix is a rare lesion. BEGER²⁾ is generally credited as having reported the first authenticated case in 1882. Since then, less than 200 cases of adenocarcinoma of the appendix are on record in English-language literature¹⁾²⁶⁾. In Japan, IWASAKI et al.¹⁴⁾ (1976) collected 58 cases of primary carcinomas of the appendix (adenocarcinoma and malignant mucocele included). Recently, routine histologic examination of all surgical specimens has resulted in the discovery of an increasing number of cases.

This paper reports a case of preinvasive adenocarcinoma of the appendix of colonic type, which was removed incidentally at laparotomy for intestinal obstruction by angulation. It reviews some of the relevant literature, with regard to the classification, pathology, incidence, diagnosis, treatment, and prognosis of this lesion.

Case Report

The patient (MK), a seventy-six year old Japanese woman, was admitted to National Himeji Hospital on March 8, 1977 with a two week history of lower abdominal pain. The pain was initially located in the left lower abdomen, became subsequently bilateral, and gradually crampy and associated with nausea and vomiting. There had been some increased vaginal discharge for two weeks before her admission.

Physical examination revealed a pale-colored, emaciated and dehydrated female patient.

Key words : Adenocarcinoma of the appendix, Carcinoma in situ.

Present address* : The First Surgical Department, Kyoto University School of Medicine, Sakyo-ku, Kyoto, 606, Japan.

Blood pressure was 140/70 mmHg, pulse 100 beats per minute, temperature 35.0°C (95.0° F). The lower abdomen showed a general distension, the contour of the intestinal loop was clearly seen and increased intestinal peristalsis was visible. Abdominal palpation revealed slight tenderness in the lower abdomen, but muscle spasm or guarding and rebound tenderness were not elicited. Neither any definite mass could be palpated. The bowel sounds were hyperactive. A roentgenogram of the abdomen showed a pattern compatible with ileus. Preoperative diagnosis of small bowel obstruction was made.

Laboratory findings were as follows : White blood cell count 9,400/mm³, red blood cell count 282×10^4 , platelet 22×10^4 , hemoglobin 8.7 g/dl, hematocrit 29%. Blood chemistry revealed BUN of 160 mg/dl, serum creatinine 7.8 mg/dl, Na 165, K 6.4, Cl 119 mEq/l, total protein 5.7 g/dl, total bilirubin 0.6 mg/dl, GOT 16, GPT 10 Karmen unit, alkaline phosphatase 8 King-Armstrong unit, LDH 290 Wróblewski unit, serum amylase 580 IU. CRP +5. Fasting blood sugar was 107 mg/dl. Urinalysis gave specific gravity 1,015, protein 30 mg/dl, 0.5 white blood cells, 0.5 red cells, 1.5 epithelial cells per high power field in the sediment. Stools were negative for occult blood. Electrocardiogram showed tall peaked T-wave and depression of S-T segment. Arterial blood gas analysis : pH 7.331, PaO₂ 127 mmHg, PaCO₂ 18.2 mmHg, O₂ saturation 100%, base excess -14 mEq/l (the patient breathing oxygen through nasal canula, 3 liter per minute).

Operation was done on March 9, with general anesthesia. At laparotomy some turbid peritoneal fluid was found. A loop of ileum was attached to the pelvic floor. The surfaces of the ovaries, cul-de-sac and adherent bowel loop were covered with yellowish purulent exudate. The exudate culture yielded α -streptococci. Acute pelvic infection was suspected to occur at first, and then, small bowel loop was involved, resulting in the intestinal obstruction by kinking. Adhesions were freed by scissor dissection, and an "incidental" appendectomy was done, and the peritoneal cavity drained. No enlarged lymph nodes were found. Removed appendix was 5 cm long and 1cm in diameter with a grayish-white outer appearance, but showed no evidence of acute inflammation. Formalin fixed specimen showed the mucosal surface of villous appearance in the entire appendix (from the base to the tip), which was slightly elevated, resembling to "type IIa" (superficial, elevated type) early gastric cancer²¹⁾ (Fig. 1).

Histologic examination of the specimen disclosed a papillary adenocarcinoma of the appendix, which had not yet begun to invade the submucosa, or carcinoma *in situ* (Fig. 2, 3 and 4). No further surgical procedure was performed on this patient because of her poor general condition.

Postoperatively, the patient was referred for hemodialysis but died on the eighth postoperative day from renal failure. No autopsy was made.

Discussion

Classification and Pathology. COLLINS⁵⁾ (1963) surveyed 71,000 human appendices (removed for disease, incidentally, or at autopsy), and found about 20 malignant conditions




Fig. 1. Formalin fixed specimen showed mucosal surface of villous appearance in the entire appendix, where the mucosa was superficially elevated.

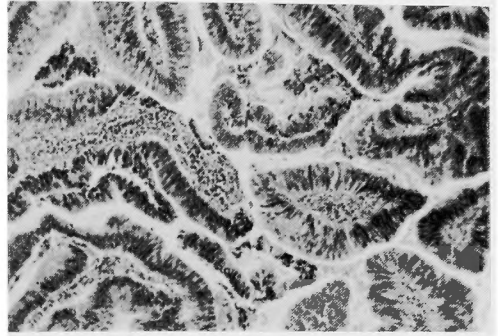


Fig. 3. Showing the structural and cellular atypism of the glands. (Hematoxylin and eosin stain, $\times 100$).

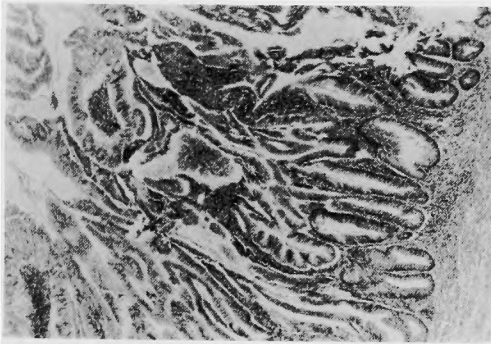


Fig. 2. Low power view of papillary adenocarcinoma *in situ* of the appendix. Lymphoid tissue is disappeared. (Hematoxylin and eosin stain, $\times 40$).

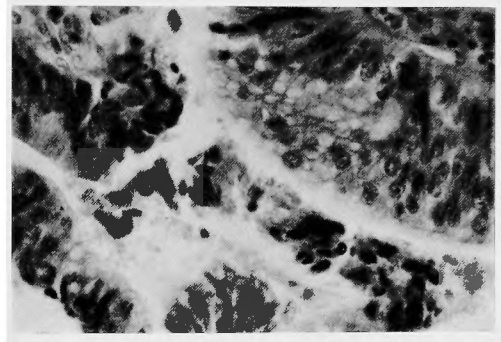


Fig. 4. High power magnification of adenocarcinoma of the appendix. (Hematoxylin and eosin stain, $\times 400$).

(Table 1). UHLEIN and McDONALD³³⁾ (1943) classified primary carcinomas of the appendix into three types : 1) carcinoma of the carcinoid type (88.2%), 2) carcinoma of the cystic type producing pseudomyxoma peritonei (8.3%), and 3) carcinoma of the colonic type which resembles, both grossly and microscopically, that found in the colon (3.5%). Today they are known as the carcinoid, malignant mucocele, and adenocarcinoma of the appendix, of which adenocarcinoma is by far the rarest and has the worst prognosis. Carcinoid tumor is most benign, and is now regarded as a distinct entity. Malignant mucocele and colonic type adenocarcinoma are histologic variants of the same tumor (MCGREGOR and MCGREGOR¹⁸⁾, 1960), and there exists some overlap in these two groups, that is, at one end of the scale are the less differentiated colonic type adenocarcinoma, and at the other end are the well differentiated, more mucus producing malignant mucocele type of tumors (WILSON³⁴⁾, 1962), but because of their different natural history and prognosis, they are also described separately.

Carcinoid tumors were first described by OBERNDORFER in 1907²⁹⁾. The tumor cells of the

Table 1. Primary malignant tumors in 71,000 human appendices (Collins⁵⁾)

	No. of cases
Pseudomyxoma peritonei (From perforated appendiceal mucocele)	305
Carcinoid tumors	(489)
Localized to appendix	417
Metastasizing and malignant	72
Primary adenocarcinoma	57*
Reticuloendothelial sarcoma	15
Follicular lymphoblastoma	15
Lymphosarcoma	11
Malignant mucosal solitary polyp	9
Fibrosarcoma	7
Undifferentiated sarcoma	(7)
Spindle-cell	4
Round-cell	3
Multiple myeloma	6
Melanoblastoma	6
Liposarcoma	6
Malignant mucosal polyp associated with congenital familial polyposis	6
Lymphangiosarcoma	5
Neuroblastoma	5
Myxosarcoma	4
Boeck's sarcoid	4
Melanoblastoma (Nonpigmented)	3
Neuroepithelioma	2
Totals	958**

* : 0.080%, ** : 1.351%

carcinoid derive from the enterochromaffin granular cells (Nicholas Kultschitzky cells) in the crypt of LIEBERKÜHN, and release serotonin (5-hydroxytryptamine), which causes the symptoms of the functioning syndrome recognized as the malignant carcinoid syndrome. The appendix is the commonest site of the carcinoid tumors, originating in the submucosa of the tip of the appendix, but metastases (2 per cent³⁵⁾) and functioning syndrome (1.2-3.4 per cent²⁸⁾) are extremely rare. Whereas initially it was felt that hepatic metastases were a sine qua non to the development of syndrome, it is now thought that milder forms of the syndrome exist in the absence of metastatic disease. In a recent study, SOGA and TAZAWA²⁹⁾ (1971) attempted more detailed classification of the carcinoids, dividing them into 5 types histologically, and 3 groups on the basis of silver impregnations. Ultrastructural observations also demonstrate several specific secretory granules in the tumor cells. Not only serotoninoma, but other polypeptide hormone-producing tumors, for example, such as motilinoma, VIPoma and GIPoma, might have been included in classic carcinoids²⁸⁾.

Mucoceles of the appendix, characterized by a cystic dilatation of the lumen containing mucinous material, comprise 3 distinctive clinicopathological entities: mucosal hyperplasia,

mucinous cystadenoma, and mucinous cystadenocarcinoma¹¹). Of the mucoceles, fewer than 10 per cent show malignant characteristics¹²). Malignant mucoceles belong, pathohistologically, to the mucinous cystadenocarcinoma group. Those tumors produce large quantities of mucus, invade the stroma, and are prone to perforation (25 per cent²³), but nodal metastasis or visceral invasion are rare. The main form of spread is by peritoneal dissemination, as in the production of so-called pseudomyxoma peritonei of appendiceal origin. Ovarian mucinous cystomas also exhibit a similar clinical picture, when spread to the peritoneum.

Adenocarcinomas of the colonic type resemble ordinary carcinomas of the large bowel, in gross appearance and biological behavior. They may occur at the base or tip of the appendix, although they are more frequent at the base^{12,33}). Grossly, they may be polypoid or papillary, ulcerative, or may infiltrate the appendiceal wall diffusely (infiltrative)^{27,33}). They have been referred to previously as of low grade malignancy and often remain confined to the mucosa for a long time¹⁸), but recent reviews suggest that they behave as aggressively as any other colonic cancers. The muscular layers of the appendix are frequently incomplete in some instances, where the submucosa becomes adjacent to the subserosa, and submucosal invasion of the tumor is actually subserosal extension. The colonic type of adenocarcinoma metastasizes to lymphatics, liver, peritoneum, and lung. Ten per cent of the patients had wide spread metastatic disease when first seen²⁴). The lymphatic spread is initially to the ileocolic nodes, later to the nodes on the anterior surface of the third portion of the duodenum and the para-aortic nodes.

QIZILBASH²⁶) (1975) reported two cases of "linitis plastica carcinoma" of the appendix, of which the entire wall was diffusely infiltrated by signet-ring cells. KLEIN¹⁵) (1974) has proposed that signet-ring cell tumors of the appendix (which are morphologically identical to microglandular type tumor described by WOLFF and AHMED³⁶), 1976) are "mucinous variants of appendiceal carcinoid tumors" rather than adenocarcinoma. SUBBUSWAMY et al.³¹) (1974) described "goblet cell carcinoid" of the appendix, which clearly resembles the goblet cell in the epithelium of the intestinal tract. These investigators consider this group of neoplasms to represent a distinctive type, which may well be related to carcinoid.

Incidence. Carcinoid tumors of the appendix are most common, and are found in approximately every 500 routine appendectomies¹⁸). Malignant mucoceles are found once in every 2,000 to 5,000 appendectomies³²).

Incidence of colonic type adenocarcinoma varies from 0.02 to 0.25 per cent of appendectomies. STEINBERG and COHN³⁰) (1967) found 3 cases of adenocarcinoma in 15,000 cases or with an incidence of 0.02 per cent. MOSS²²) (1974) reported 10 cases in a survey of 3,989 cases, in which the incidence was 0.25 per cent. COLLINS⁵) (1963) found 57 cases of adenocarcinoma in 71,000 cases, an incidence of 0.08 per cent (one in every 1,250 appendices); this possibly represents the incidence. Adenocarcinoma of the appendix accounts for 0.2 to 0.5 per cent of all tumors of the gastrointestinal tract²⁴).

The age range of the adenocarcinoma of the appendix is from 17 to 84 with the majority occurring in the fifth to the seventh decades of life²⁴). There probably is no sig-

nificant sex predominance, but several reports slightly favor the male¹⁾⁴⁾¹²⁾²⁵⁾²⁷⁾. Preinvasive appendiceal adenocarcinoma is very rarely reported¹⁷⁾²⁷⁾.

Symptoms and Diagnosis. The diagnosis of appendiceal adenocarcinoma has never been made preoperatively, since there is no specific clinical or pathognomonic sign and symptom. Most of it is found by the pathologist in specimen removed. The early clinical signs are a vague abdominal discomfort or pain especially in the right lower quadrant, and a palpable mass may be the late metastatic and invasive symptoms. HESKETH¹⁰⁾ (1963) reported a series of 95 cases in which 69 per cent were presented as benign appendiceal disease, 11 per cent in a terminal phase, and 14 per cent had an "incidental" appendectomy in association with other abdominal operations, with subsequent histological discovery of an adenocarcinoma (Table 2). The recently developed diagnostic procedure, such as double-contrast enema, fibro-optic colonoscopy, and selective angiography of superior mesenteric artery, may be used for the early detection of neoplastic lesions of the appendix⁷⁾. Fibro-optic colonoscopy could be of some help by visualization of the mucosal pattern of the cecum and of the ostium of the appendix, or by direct biopsy, aspiration biopsy, and brush biopsy for cytological studies, instead of exploratory laparotomy which is usually performed at a later stage of the disease with metastases. No effort should be spared in attempting to diagnose malignancy in its earliest stage⁷⁾.

Table 2. Preoperative diagnosis of adenocarcinoma of colonic type of the appendix (Hesketh¹⁰⁾)

Acute appendicitis	42 cases
Appendix abscess	13
"Chronic appendicitis"	8
Terminal phase with wide spread metastases	8
"Incidental" appendectomy	13

In some instances of malignant mucocoeles, "calcium flecks" in the walls may suggest the diagnosis¹⁸⁾²⁷⁾.

Treatment and Prognosis. At present, the only definitive measure for control of adenocarcinoma of colonic type of the appendix is surgery. The recommended operation is right hemicolectomy with node dissection. Initially, it was thought that simple appendectomy was sufficient treatment if the lesion was limited to the mucosa. However, recent studies suggest that more radical surgery is proper procedure, offering a better prognosis⁴⁾⁸⁾⁹⁾¹⁰⁾¹²⁾²⁴⁾. COHEN and WOLFMAN¹⁾ (1974) reported a three year survival rate in case of appendectomy alone ranged from 20 to 73 per cent, and in case of right hemicolectomy, from 63 to 92 per cent. HESKETH¹⁰⁾ (1963) reported that only 4 out of 19 patients treated by appendectomy alone were alive at the end of five years (five year survival rate of 21 per cent), whereas 19 out of 31 patients who underwent right hemicolectomy were alive and well for five years (five year survival rate of 61 per cent).

Radiotherapy and immuno-chemotherapy have been used on inoperable patients, but the results are not encouraging.

Is appendectomy followed by increase of cancer risk? McVAY¹⁹⁾ (1943) showed a possible relationship between appendectomy and subsequent development of cancer. McVAY

surveyed autopsy records and clinical histories (all patients older than 30 years), and found that the incidence of appendectomy in patients dying of carcinoma, especially of the colon, was significantly higher than in a comparable control group (patients who died of vascular disease). His report shows the incidence of previous appendectomy in patients dying of colon carcinoma (229 cases), other malignant neoplasms (198 cases), and vascular disease (271 cases) are 18.3 per cent, 12.6 per cent, and 7.7 per cent, respectively. McVAY offered a hypothesis that the appendix may act as a protective device against enteric viruses that may initiate malignant change in the colon and possibly at various other sites in the body. MOERTEL et al.²⁰⁾ (1974), however, demonstrated no apparent predisposition for the development of cancer in those patients who had undergone appendectomy, based on a prospective study of 1,779 patients who were all over the age of forty years.

Summary

A case report of preinvasive appendiceal adenocarcinoma of the colonic type is presented. The literature dealing with primary carcinomas of the appendix is reviewed. Preoperative diagnosis is all but impossible. Acute obstructive appendicitis or appendiceal abscess are the clinical picture most often seen¹⁰⁾¹²⁾. Some patients have an "incidental" appendectomy with subsequent histological discovery of an adenocarcinoma. It should be emphasized that all appendices removed should be subjected to microscopic examination. Right hemicolectomy is the treatment of choice, offering the best prognosis for adenocarcinoma of colonic type of the appendix. But, it has a poor prognosis unless discovered early.

References

- 1) Andersson A, Bergdahl L, et al . Primary carcinoma of the appendix. *Ann Surg* **183** : 53-57, 1976.
- 2) Beger A . Ein Fall von Krebs des Wurmfortsatzes. *Berl Klin Wochenschr* **19** : 616-618, 1882. Cited by 27) Sieracki and Tesluk.
- 3) Berman AT, James PM Jr : Adenocarcinoma of the vermiform appendix. *Am J Surg* **119** : 733-736, 1970.
- 4) Cohen SE, Wolfman EF Jr : Primary adenocarcinoma of the vermiform appendix. *Am J Surg* **127** : 704-707, 1974.
- 5) Collins DC : 71,000 human appendix specimens. A final report, summarizing forty years' study. *Am J Proctol* **14** : 365-381, 1963.
- 6) Delgado RR Jr, Mullen JT, et al : Primary adenocarcinoma of the appendix. *South Med J* **68** : 976-978, 1975.
- 7) Dross VP, Hipsley RW : The problem of carcinoma of the vermiform appendix. Review of literature proposals for use of new diagnostic techniques (case report). *W Va Med J* **70** : 80-87, 1974.
- 8) Flint FB, Kahn AM, et al : Adenocarcinoma of the appendix. *Am J Surg* **120** : 707-709, 1970.
- 9) Gamble HA II : Adenocarcinoma of the appendix: An unusual case and review. *Dis Colon Rectum* **19** : 621-625, 1976.
- 10) Hesketh KT: The management of primary adenocarcinoma of the vermiform appendix. *Gut* **4** : 158-168, 1963.
- 11) Higa E, Rosai J, et al : Mucosal hyperplasia, mucinous cystadenoma, and mucinous cystadenocarcinoma of the appendix. A re-evaluation of appendiceal "mucocele". *Cancer* **32** : 1525-1541, 1973.
- 12) Hopkins GB, Tullis RH, et al : Primary adenocarcinoma of the vermiform appendix : Reports of seven cases and review of the literature. *Dis Colon Rectum* **16** : 140-144, 1973.
- 13) Ishikawa K, Hachisuka K, et al : Primary adenocarcinoma of the vermiform appendix. *Gan no Rinsho* **17** : 895-898, 1971. (Jpn)

- 14) Iwasaki M, Matsumine K, et al : Primary carcinoma of the appendix. Report of a case and re-investigation of pathological classification. *Nihon Rinsho Geka Igakkai Zasshi* **37** : 66-72, 1976. (Jpn)
- 15) Klein HZ Mucinous carcinoid tumor of the vermiform appendix. *Cancer* **33** : 770-777, 1974.
- 16) Matsuo T, Yao T, et al : Two cases of carcinoma of appendix with different mode in metastasis. *Stomach and Intestine* **8** : 1381-1385, 1973. (Jpn)
- 17) McCollum W, Pund ER : Preinvasive adenocarcinoma of the appendix. Report of sixteen cases. *Cancer* **4** : 261-264, 1951.
- 18) McGregor JK, McGregor DD : Adenocarcinoma of the appendix. *Surgery* **48** : 925-935, 1960.
- 19) McVay JR Jr The appendix in relation to neoplastic disease. *Cancer* **17** : 929-937, 1964.
- 20) Moertel CG, Nobrega FT, et al : A prospective study of appendectomy and predisposition to cancer. *Surg Gynecol Obstet* **138** : 549-553, 1974.
- 21) Morson BC : The Japanese classification of early gastric cancer. *In* The gastrointestinal tract, edited by Yardley JH, Morson BC, Abell MR, Williams & Wilkins Co., Baltimore, 1977, pp. 176.
- 22) Moss DI Adenocarcinoma of the appendix vermiformis. *Aust NZ J Surg* **44** : 140-142, 1974.
- 23) Nishida Y, Shishido M, et al : A case of adenocarcinoma of the appendix. *Toho Igakkai Zasshi* **21** : 99-102, 1974. (Jpn)
- 24) Otto RE, Ghislandi EV, et al . Primary appendiceal adenocarcinoma. *Am J Surg* **120** : 704-706, 1970.
- 25) Payumo IV, McManus JE : Primary carcinoma of the appendix associated with carcinoma of the colon : Report of a case. *Dis Colon Rectum* **13** : 42-46, 1970.
- 26) Qizilbash AH : Primary adenocarcinoma of the appendix. A clinicopathological study of 11 cases. *Arch Pathol* **99** : 556-562, 1975.
- 27) Sieracki JC, Tesluk H : Primary adenocarcinoma of the vermiform appendix. *Cancer* **9** : 997-1011, 1956.
- 28) Soga J The carcinoid syndrome. *Nihon Rinsho* **35** : 892-893, 1977. (Jpn)
- 29) Soga J, Tazawa K Pathologic analysis of carcinoids. Histologic reevaluation of 62 cases. *Cancer* **28** : 990-998, 1971.
- 30) Steinberg M, Cohn I Jr : Primary adenocarcinoma of the appendix. *Surgery* **61** : 644-660, 1967.
- 31) Subbuswamy SG, Gibbs NM, et al : Goblet cell carcinoid of the appendix. *Cancer* **34** : 338-344, 1974.
- 32) Takamatsu T, Inokuchi H, et al : Experience of appendiceal carcinoma. *Geka* **35** : 850-856, 1973. (Jpn)
- 33) Uihlein A, McDonald JR : Primary carcinoma of the appendix resembling carcinoma of the colon. *Surg Gynecol Obstet* **76** : 711-714, 1943.
- 34) Wilson R : Primary carcinoma of the appendix. *Am J Surg* **104** : 238-249, 1962.
- 35) Wilson H, Cheek RC, et al : Carcinoid tumors. *Curr Probl Surg Nov.* 1970, pp. 4-31.
- 36) Wolff M, Ahmed N Epithelial neoplasms of the vermiform appendix (exclusive of carcinoid). I. Adenocarcinoma of the appendix. *Cancer* **37** : 2493-2510, 1976.

和文抄録

原発性虫垂腺癌の1例

国立姫路病院外科

長嶺 慎一, 寺井 武寿, 中武 稔
横谷 邦彦, 小原 弘, 山内 陽一

国立姫路病院 病理

桂 栄 孝

入江病院

入 江 善 一

虫垂腺癌はまれな疾患とされ, Beger (1882) の報告以来, 現在までに 200 例くらい報告があるにすぎない。

われわれは最近, 76才女子の癒着性イレウスで開腹中に切除した虫垂の上皮内腺癌を経験したので報告するとともに, 虫垂癌の分類, 病理, 頻度, 症状, 診断, 治療, 予後について若干の考察を加えた。

Uihlein & McDonald (1943) は, 虫垂癌をカルチノイド型 (88.2%), 嚢腫型 (cystic type, 8.3%), 結腸型 (colonic type, 3.5%) の 3 型に分類した。現在では, これらは各々 1) carcinoid, 2) malignant mucocele (破裂するといわゆる pseudomyxoma peritonei を生ずる。病理組織的には mucinous cystadenocarcinoma である), 3) adenocarcinoma として知られている。

虫垂腺癌は, 虫垂の基部に多くみられ, 肉眼的には大腸癌と同様, ポリープ型又は潰瘍型を呈する。われわれの症例は, ホルマリン固定標本で, 早期胃癌の IIa 型を想わせる表在性の隆起を認めた。虫垂腺癌は頻度は少ないが, 悪性度は一番強く, 粘膜下まで浸潤がおよぶと, リンパ節や, 肝, 腹膜, 肺に転移を形成しやすい。虫垂の malignant mucocele と結腸型腺癌とは, 同一起源の腫瘍の組織学的な variant とみなされ, 両者の相異は分化度の差によるものと考えられ

ている (前者の方が分化度が高い) が, 臨床経過と予後が異なるので, 区別して記載される。なお, Qizilbash (1974) は, 虫垂壁の全層が signet-ring cell で浸潤された linitis plastica carcinoma の 2 症例を報告しているが, 最近の研究によると, 虫垂の signet-ring cell tumor は実際は carcinoid であるかも知れないという。

虫垂腺癌の頻度は, 虫垂標本の 0.02~0.25% にみられ, Collins (1963) は 71,000 例中 57 例, 0.08% に認めた。全消化管腫瘍の 0.2~0.5% を占める。

術前に虫垂癌を診断することは困難である。急性虫垂炎, 虫垂周囲膿瘍, 回盲部腫瘍などの診断のもとに開腹される。ほかの疾患で開腹したついでに切除され, 組織検査で癌を発見されることもある。開腹した時には必ず虫垂を検索し, また虫垂を切除した時は必ず病理組織検査を行なう必要がある。

虫垂腺癌の治療は, 右半結腸切除術と所属リンパ節廓清が適応である。リンパ節は十二指腸前面まで精査する必要がある。

予後は, 虫垂腺癌の 3 年生存率は, 虫垂切除のみでは 20~73%, 右半結腸切除で 63~92% である。5 年生存率は Hesketh (1963) によると, 虫垂切除のみでは 21%, 右半結腸切除を行なっても 61% であって, 決して良好とはいえない。