

| | |
|-------------|---|
| Title | Surgery of the Adrenal Gland |
| Author(s) | TANIMURA, HIROSHI; NAGASE, MASAO; HIKASA, YORINORI |
| Citation | 日本外科宝函 (1977), 46(4): 466-483 |
| Issue Date | 1977-07-01 |
| URL | http://hdl.handle.net/2433/208194 |
| Right | |
| Type | Departmental Bulletin Paper |
| Textversion | publisher |

Surgery of the Adrenal Gland

HIROSHI TANIMURA, MASAO NAGASE and YORINORI HIKASA

Second Surgical Department, Kyoto University School of Medicine,

(Director : Prof. Dr. YORINORI HIKASA)

(Received for Publication Mai. 7, 1977)

Adrenal diseases are the most frequent and important among the endocrine diseases with hypertension, and up-to-date knowledges are needed for their surgical treatment, since the patients are in peculiar endocrine milieus. Until recently, diagnosis of endocrine diseases has been left in endocrinological physician's hand, but a definite diagnosis not infrequently has been obtained only after surgical exploration, in which surgeons have been content to act the part of technicians¹⁻²⁾. Nowadays, surgeons dealing with endocrinological disorders, like every other member of the therapeutic team, should have thorough knowledges not only on surgical techniques but also on pathophysiology of the hormonal diseases. Without the latter knowledge, adequate pre- and post-operative cares can not be performed³⁾.

Table 1. Adrenalectomy in our clinic.

| | —1970 | 1971—1975 | Total |
|-----------------------|-------|-----------|----------|
| Primary aldosteronism | 13 | 9 | 22 |
| Pheochromocytoma | 11 | 12 | 23 |
| Cushing's syndrome | 14 | 15 | 29 |
| Hyperplasia | | 8 | |
| Adenoma | | 7 | |
| | 38 | 36 | 74 cases |

The surgeon is an expert in the management of endocrine disease in a restricted field relating to one gland. However, the surgeon willing to treat the endocrine disorders should study all round on every endocrine organs, since the endocrine organs have intimate relationships with each other, a typical example being multiple endocrine adenopathy (MEA).

Localization

Localization of the adrenal disorders is a prerequisite for surgical treatment. Scintiscanning after administration of ¹³¹I-labelled cholesterol or adosterol is one of the noninvasive method⁴⁾. A functioning adrenal cortical tumor shows up as a "hot spot" on one side, and bilateral hyperplasia is characterized by bilateral increased concentration of radioactivity.

Key words ; Adrenalectomy, Primary Aldosteronism, Cushing's Syndrome, Pheochromocytoma.

Present address : Second Surgical Department, Kyoto University School of Medicine. Sakyo-ku, Kyoto, 606, Japan.

After suppression of the thyroid uptake by oral administration of KI tablets, 1.5 mCi of ^{131}I -19-Cholesterol is injected and a scintigram is taken in the prone position 7 days later.

Upper left of Fig. 1 shows a small left-sided aldosterone producing tumor. After administration of dexamethasone which inhibits the uptake of labelled cholesterol by the normal or hyperplastic adrenal tissues, localization of a small tumor is further clearly demonstrated (upper right of Fig. 1). In cases of adenoma with Cushing's syndrome, contralateral adrenal cortex atrophies so markedly that it can be diagnosed easily (middle right and left of Fig. 1). Bilateral hyperplasia can be also diagnosed easily (lower left of Fig. 1). A large pheochromocytoma with atrophy of the adrenal cortex may be detected as a cold spot

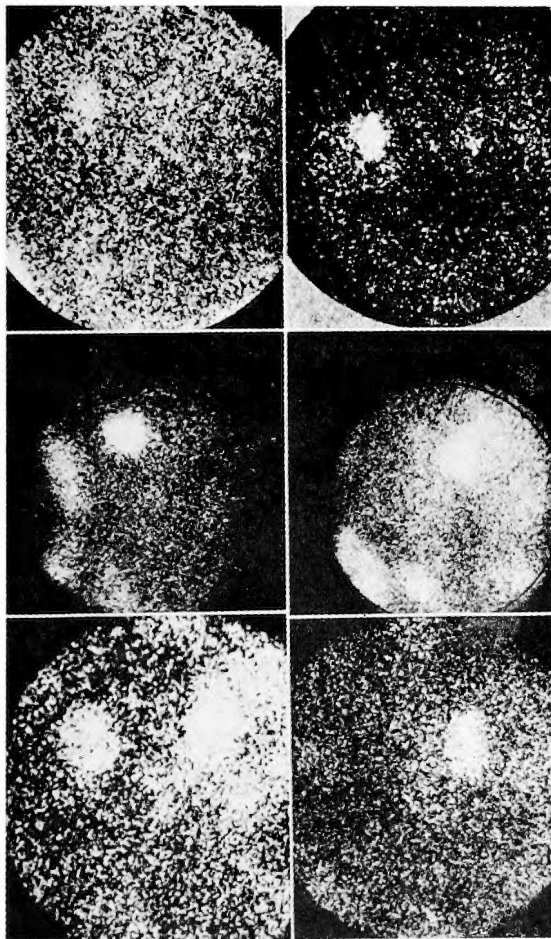


Fig. 1. ^{131}I -19-cholesterol adrenal scintiscanning
 Upper left ; left aldosterone producing adenoma
 right ; right aldosterone producing adenoma
 (Dexamethasone-modified scintiscan)
 Middle left ; left adenoma with Cushing's syndrome
 right ; right adenoma with Cushing's syndrome
 lower left ; bilateral hyperplasia with Cushing's syndrome
 right ; Suppression due to large left pheochromocytoma

(lower right of Fig. 1). It should be remembered that the right adrenal gland may be depicted more densely because of its anatomical position. Although the scintigraphy would seem to have obvious advantages over adrenal angiography as a noninvasive technique, its use is not recommended for the pre-adolescent patients because of its rather large doses of radiation to sexual organs.

Among the localization studies using Xray, pneumoretroperitoneography is most reliable. As insufflating gas, the authors prefer to use rapidly diffusing carbon dioxide for examination of pheochromocytoma and to use more radiolucent oxygen for obese Cushing's syndrome. From several routes to the retroperitoneal space, we prefer to go through the presacral rout keeping the patient in the prone position and upper body being held up. Usually, 1200 ml of gas is insufflated and intravenous pyelography is done simultaneously and tomograms are taken. Additional films are taken in the erect position allowing gas to collect in the subphrenic space and the kidneys to shift down. By this technique, aldosterone producing tumor of 1 cm or less in diameter can be detected as shown clearly in Fig. 2.

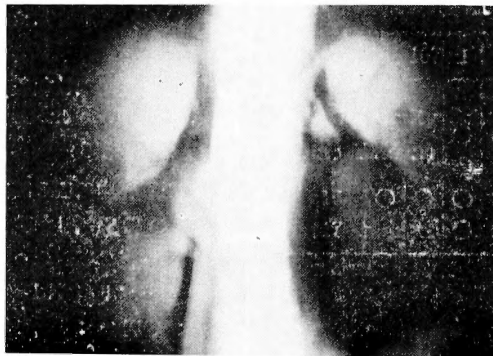


Fig. 2. Pneumoretroperitoneography
(less than 1cm small aldosterone producing adenoma)

Retrograde adrenal venography may be used for rather large adrenal tumors. It can be done more easily on the left side as shown in Fig. 3. It should be remembered, however, that the adrenal necrosis can occur when the dye is injected too forcefully.

Since the adrenal glands received many small arterial branches from the aorta, renal and inferior phrenic arteries, aortography is done first and then the suitable arteries are selected for adrenal arteriography. Aldosteronoma is depicted as an avascular spot by arteriography. Pheochromocytoma with rich blood supply can be clearly shown as in Fig. 4. If the arteriography failed to depict an adrenal tumor in spite of high suspicion of pheochromocytoma, inferior mesenteric arteriography should be done in order to find out any paraganglioma, especially that in Zuckerkandle's organ. When localization of the tumor can not be decided by angiography, blood samples are obtained either from the adrenal veins or from various levels of the inferior vena cava by a venous catheter introduced through the major saphenous or femoral vein, and are analyzed for assay of adrenal hormones. This is particularly valuable for detecting any ectopic pheochromocytoma.

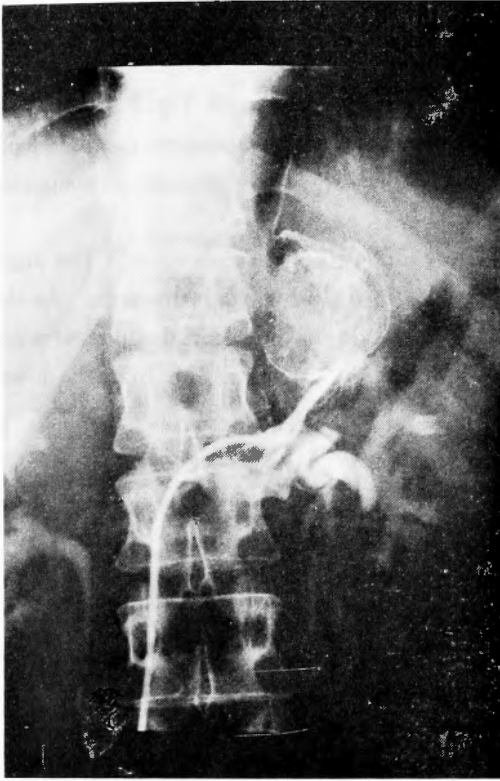


Fig. 3. Retrograde adrenal venography
(Pheochromocytoma)

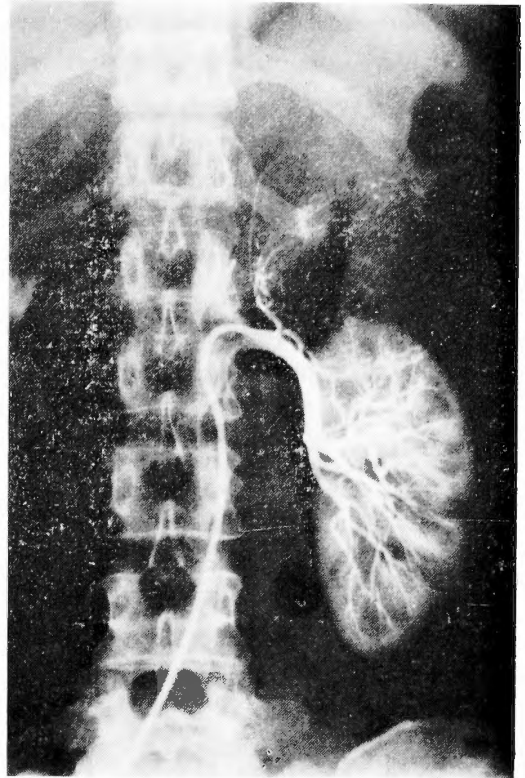


Fig. 4. Angiography
(Pheochromocytoma)

Ultrasonic tomography has been recently recommended and computed tomography can be used for localization of the adrenal tumor.

Operative techniques

Since the surgical approach to the adrenal glands is rather difficult because of their anatomical position, several routes are used. The approaches which permit both rapid arrival at the adrenal glands and easy ligation of the adrenal veins should be employed.

In our country, the posterior extraperitoneal approach⁵⁾ is generally choiced by urologists for Conn's syndrome (aldosteronoma) and obese Cushing's syndrome. However, this approach can be used neither for ectopic tumor nor large malignant tumor. Moreover, accidental pneumothorax due to an inadvertent pleural injury does not infrequently occur and the resection of the ribs may aggravate compression fracture of the spine (Th₁₀-L₁) associated with osteoporosis in Cushing's syndrome. Therefore, we have not choiced this approach.

1. *Anterior transperitoneal approach*

We carry out this approach by a bucket handle incision⁶⁾ in the upper abdomen. In pheochromocytoma, the whole abdomen should be always explored in searching for

extra-adrenal tumors which may exist in about 10% of cases. Moreover, cholecystectomy may be also necessary for cholelithiasis coincident not infrequently with pheochromocytoma. So, this anterior approach is most suitable for surgery of pheochromocytoma⁷⁾.

In recent years, we favor a sharp mount-shaped incision as shown in Fig. 5. By turning over the skin flap down and fixing it to the pubic region, the whole abdomen can be easily explored⁸⁾ We have found out and resected successfully by this approach a malignant pheochromocytoma which originated in the urinary bladder wall⁹⁾.

On the right side, the retroperitoneum is entered after Kocher's maneuver. The right kidney is pushed downwards and the right lobe of the liver is retracted upwards. As the upper half of the right adrenal gland is covered by the posterior lower edge of the liver, it is not infrequently difficult to ligate the right adrenal vein. And the venous return from the lower

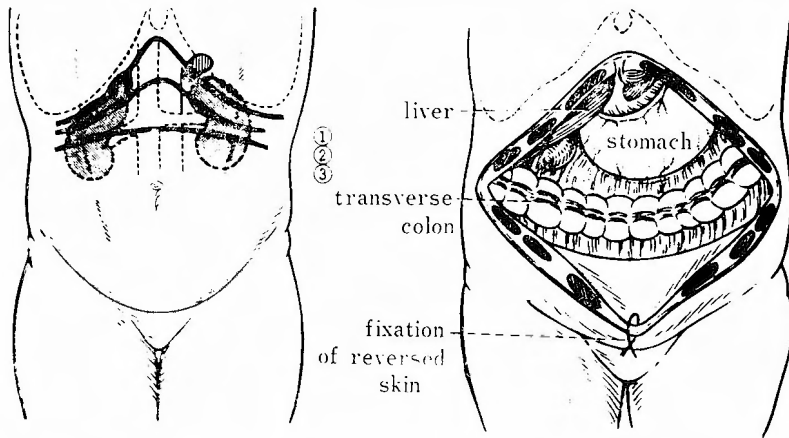


Fig. 5. Anterior transperitoneal approach

- ① bilateral subcostal incision
- ② bucket handle incision
- ③ upper transverse incision

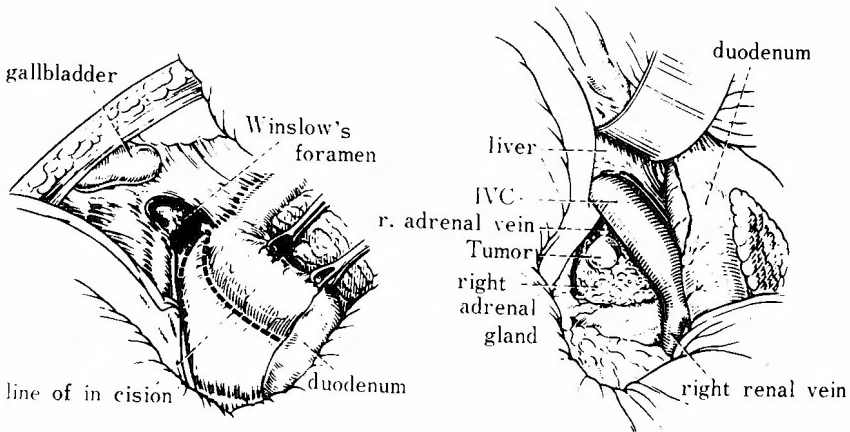


Fig. 6. Exposure of right adrenal gland (anterior transperitoneal approach)

body may be hampered by inadvertent pressure on the inferior vena cava (Fig. 6).

The left adrenal gland can be exposed easily either by turning over the spleen and the tail of the pancreas (Fig. 7) or by retracting the body of the pancreas upwards (Fig. 8).

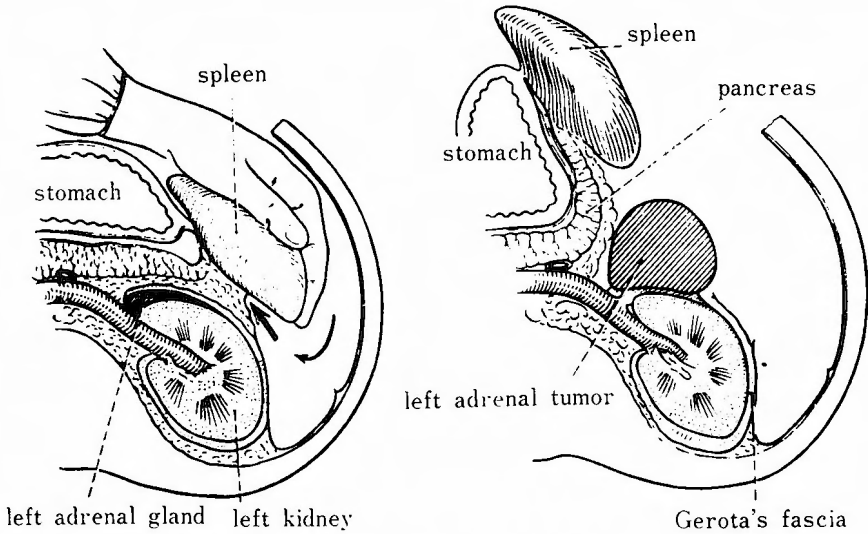


Fig. 7. Exposure of a tumor of the left adrenal gland (anterior transperitoneal approach)

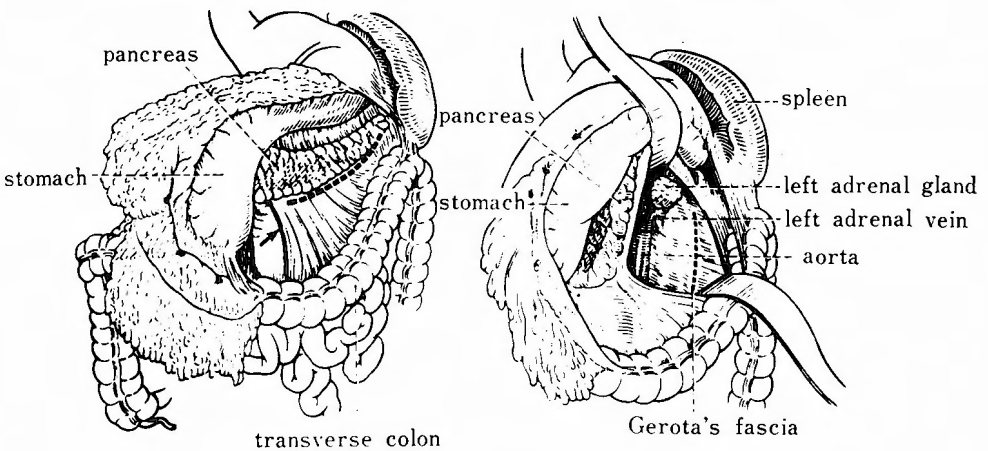


Fig. 8. Exposure of left adrenal gland (anterior transperitoneal approach)

2. *Thoracoabdominal approach*

In the last two years, we have preferred thoracoabdominal (transthoracic transdiaphragmatic) approach for the cases of definite affected side¹⁰). The ligation of the right adrenal vein, to prevent release of catecholamines into the general circulation as the tumor is manipulated, can be done very easily and securely by this approach. The right thorax is entered by the IX th intercostal incision and the diaphragm is cut in the same direction to the centrum tendineum. The right triangular ligament is cut and the posterior lower edge of

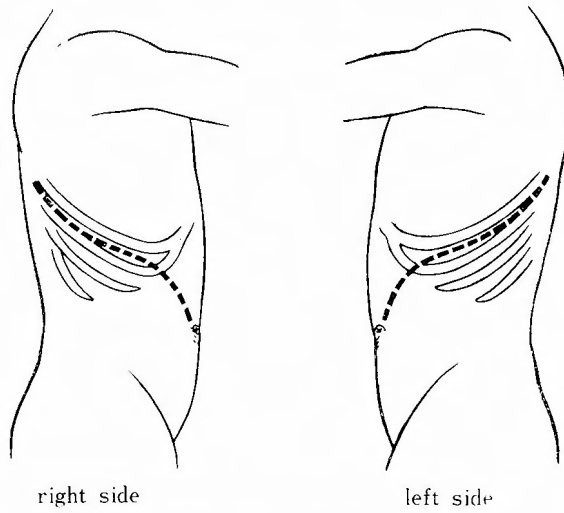


Fig. 9. Incision of thoracoabdominal approach.

the liver is freed from the retroperitoneum and is retracted upwards, as this retraction is done very easily because the diaphragm is cut across. On the left side, after thoracoabdominal incision through the IXth intercostal space, the spleen and the tail of the pancreas are reflected forwards and the left adrenal gland can be easily exposed.

Among 25 cases of adrenal surgery performed during last two years, 15 cases were subjected to anterior approach and 10 cases (right side 8 cases, left side 2 cases) to thoracoabdominal approach. In comparative studies on the time needed for operation, variation of blood pressure, volume of blood loss, and postoperative course (urinary amylase, serum level of LDH, recovery of intestinal motility and so on), the thoracoabdominal approach was superior to the anterior approach¹¹⁾. The thoracoabdominal approach is especially preferable for obese Cushing's syndrome, in which ligation of uniformly short and wide right adrenal vein, a delicate step in adrenal surgery, is not facilitated and accompanied by serious bleeding from fragile fatty tissue. We have operated on a case of obese Cushing's syndrome due to bilateral hyperplasia by combination of right thoracoabdominal and left anterior approaches. Operative insult of thoracotomy, which might be feared by some surgeons, is almost negligible except for requiring thoracic drainage for about two days after the operation.

3. Comparison of postoperative complications following various approaches.

By the posterior extraperitoneal approach, pneumothorax due to inadvertent pleural injury can occur in 8 to 14 per cent. In the anterior approach, splenic injury can occur in 15 to 17 per cent. Although injuries of major veins such as the inferior vena cava and renal veins can occur in 5 to 6 per cent either by anterior or posterior approach, these injuries can be securely avoided by thoracoabdominal approach. In Cushing's syndrome associated cardiac hypertrophy and central obesity, pulmonary complications, such as atelectasis, pulmonary thrombosis, pneumonitis and so on, can occur in 16.7 per cent after

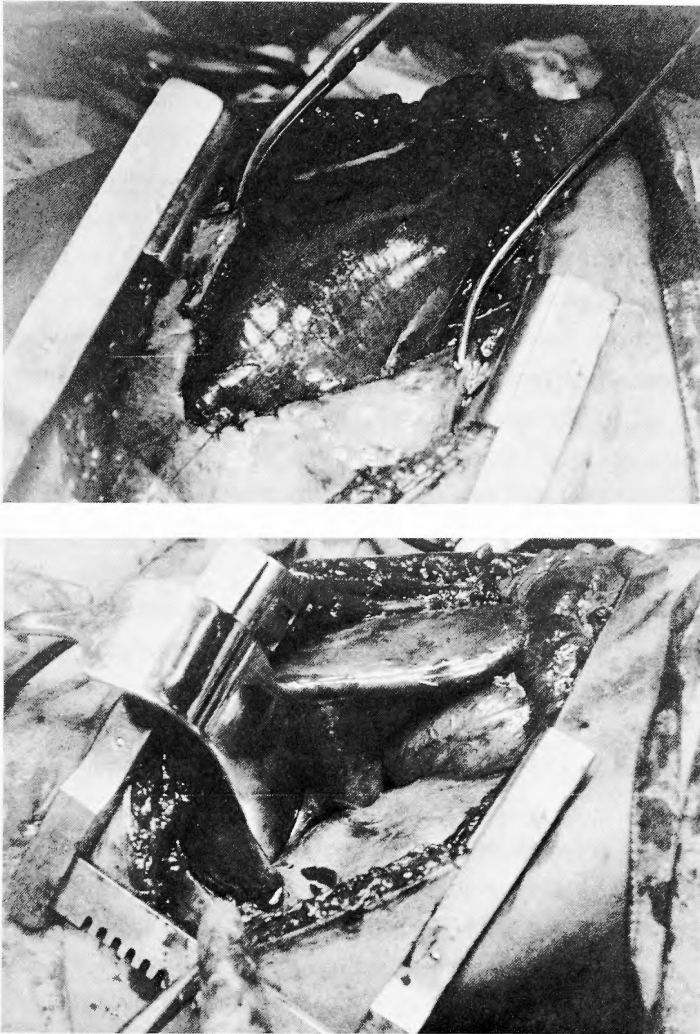


Fig. 10. Thoracoabdominal approach-resection of right adrenal tumor.

anterior approach¹²⁾.

Wound infection occurs in 12.9 per cent after posterior approach and in 10.7 per cent after anterior approach. Subphrenic abscess has been reported to occur only after left anterior approach. We usually drain the left subphrenic space for about three days after the left anterior approach.

Primary aldosteronism

Primary hyperaldosteronism is renin-independent aldosterone hypersecretion in hypertensive, nonedematous patients. Among surgically correctable hypertension, renovascular hypertension also shows abnormality in renin-angiotensin-aldosterone system. Structural changes of the renal artery demonstrated by arteriography and plasma level of renin activity do not always correlate.

Assumption of the upright posture, which stimulates renin release, sodium-restricted diet and diuretic drugs have been used as differential diagnosis. Recently, we have devised a new method of intravenous infusion of angiotensin III (20mg/kg/min) or angiotensin II analogue (500ng/kg/min) during a period of 30 minutes¹³⁾. Blood pressure rises in primary aldosteronism, but falls to normal levels in renovascular hypertension.

While primary aldosteronism due to aldosteronoma is an absolute indication of adrenalectomy of the affected side, total bilateral adrenalectomy is not indicated for bilateral hyperplasia. Primary aldosteronism suspected bilateral hyperplasia should be first treated with anti-aldosterone drug (spironolactone). Adrenal hyperplasia causing primary aldosteronism (idiopathic hyperaldosteronism, IHA or non-neoplastic aldosteronism) is divided to adrenocortical nodular hyperplasia (45 cases have been reported in Japan) and diffuse hyperplasia (21 cases reported in Japan). Nodular hyperplasia is rather frequently seen in females of about 40 years old and can be treated by bilateral subtotal adrenalectomy. Diffuse hyperplasia is often seen in younger decades and surgical treatment is not indicated except for biopsy.

In determination of localization of adenomas, it should be remembered that aldosteronoma is usually less than 3 cm in diameter and less than 6 gm in weight, and that most adenomas are found on the left side. However, two cases of bilateral adenomas in Japan and two cases of ectopic tumors have been reported in the world¹⁴⁾. So, we prefer anterior transperitoneal approach in order to excise the affected adrenal gland and to biopsy from the other side.

Preoperative care : Hypokalemic and metabolic alkalotic patients show often U-wave and/or extrasystols in ECG. Preoperative preparation is important since hypokalemia may develop ventricular fibrillation under anesthesia. Potassium should be supplemented by administration of Aspara K[®] 12 tablets (20mEq K) or Gluconsan K[®] 6 tablets (30mEq K) in combination with spironolactone 150mg (Aldactone-A[®] 6 tablets) daily during 7 to 10 days before operation. By drip infusion of 60 mEq/liter/day of potassium chloride in glucose solution for 3 days before operation elevation of 2.0 mEq/liter in serum potassium level can be gained. Sodium is restricted, and administration of potassium alone should be avoid since it stimulates aldosterone secretion.

Postoperative care : Corticoid supplement usually is not needed before or after unilateral adrenalectomy for aldosteronoma. Although fludrocortisone, 0.1mg/day orally, is recommended for postoperative aldosterone deficiency in American literatures¹⁴⁾, it is unnecessary in our country probably because of a larger daily intake of sodium chloride. The patients generally comes to operation with increased total body salt and hypervolemia. Therefore, postoperative fluid therapy in routine volume is enough except after excessive bleeding at operation. Sodium is restricted in the postoperative period, too. Potassium is given only to the patients who had an insufficient potassium supplement before operation. Hypertension due to pure hyperaldosteronism is cured rapidly within 3 to 7 days after resection of an adenoma, since the vascular damage usually is very slight. Although some patients with longstanding course

retains hypertension even after the operation, they respond well to anti-hypertensive drugs.

Cushing's syndrome

Once the diagnosis of hyperadrenocorticism has been established, it is necessary to determine the cause of Cushing's syndrome before surgical treatment. Although Cushing's syndrome due to adrenal adenoma can be cured completely by adrenalectomy, hypophyseal or ectopic lesions with Cushing's syndrome causing bilateral adrenal hyperplasia can not be eradicated by adrenal surgery. But up to now total bilateral adrenalectomy is the safest and surest treatment of Cushing's syndrome due to bilateral hyperplasia because the manifestations of excessive cortisol secretion subside rapidly after surgery. After total adrenalectomy, lifelong corticosteroid replacement therapy become necessary, but this must be accepted in favor of relief from life-threatening complications of Cushing's syndrome.

In Cushing's syndrome due to adrenal adenoma, the contralateral adrenal cortex has been depressed to marked atrophy, so localization of the tumor can be determined easily by adrenal scintigraphy as shown in Fig. 1. Bilateral hyperplasia also can be diagnosed by scintigraphy, but nodular hyperplasia may be differentiated from diffuse hyperplasia by measurement of plasma ACTH levels with radioimmunoassay, which shows a higher level in the latter¹⁵.

Sometimes, in order to avoid corticosteroid supplement of lifelong duration, subtotal adrenalectomy, that is unilateral adrenalectomy in combination with contralateral partial adrenalectomy, is performed in young patients with bilateral hyperplasia. Although a few cases have been reported to be cured completely by this operation, it is practically very difficult to reserve a just enough and necessary amount of adrenocortical tissue, and the disease may recur if the remained adrenal tissue hypertrophies again in response to excessive ACTH, or adrenal insufficiency may ensue if the reserved tissue is too small or mortified by vascular damage.

Recently same as in other endocrine disorders such as parathyroid hyperplasia, autotransplantation of the adrenal tissue into the abdominal rectus or thigh muscles after total adrenalectomy have been attempted and enabled some cases to curtail the corticosteroid replacement therapy.

Preoperative care : In United Kingdom³), some drugs which inhibit in steroid biosynthesis such as 6-aminoglutethimide, metyrapone and occasionally mitotane (o, p'-DDD) have been given for 2 to 3 months before operation and reported to improve the manifestations of Cushing's syndrome preoperatively and to render the postoperative uneventful course. Since metyrapone and aminoglutethimide stimulate ACTH secretion from the pituitary, they should not be used for the cases of hyperplasia. Among 138 cases of Hunter's series and 118 cases of Lubitz's experience, clinical success by o, p'-DDD was obtained only in 34 to 54 per cent and serious side-effects were common at effective doses (anorexia 80 per cent, drowsiness 34 per cent, dermatitis 20 per cent). Although these drugs are not used for preoperative treatment in our country, certain more effective new drugs without side-

effects, such as antithyroid or antialdosterone drugs, are awaited.

Some patients of Cushing's syndrome consult first psychiatrist because of depression and often need the psychiatric treatment before operation¹⁶⁾.

Management during operation : Hydrocortisone (Solu-Cortef®) 300 to 500mg in 500ml of 5 per cent glucose solution is dripped intravenously in order to prevent hypotensive shock during anesthesia. Sodium overload should be avoided to prevent occasional occurrence of cardiac failure.

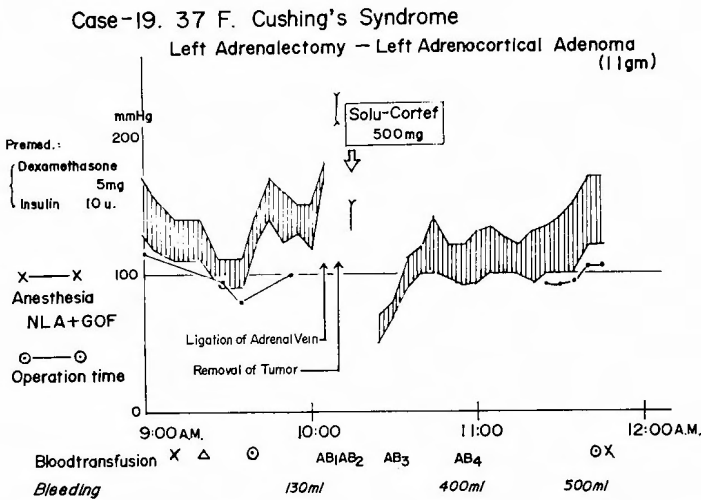


Fig. 11. Management during the operation of Cushing's syndrome.

Postoperative care : Hyperadrenocorticism is turned abruptly to hypoadrenocorticism by adrenalectomy. The basic principle of postoperative adrenal replacement therapy is to fall down slowly the abrupt decrease of plasma corticosteroid levels induced by adrenalectomy. After resection of an adenoma, an excess supplement of corticosteroid should not be given in order to promote regeneration of the atrophic contralateral adrenal cortex. After surgery for bilateral hyperplasia, on the contrary, supplemented corticosteroid should be given in sufficient quantities.

Postoperative maintenance therapy of corticosteroid after total bilateral adrenalectomy is as follows ;

- i) Just after the operation : hydrocortisone 50 mg per 6 hours intramuscularly.
- ii) 2nd day : hydrocortisone 50 mg per 8 hours.
- iii) 3rd day : hydrocortisone 50 mg per 12 hours.
- iv) 4th day : hydrocortisone 50 mg per 12 hours intramuscularly, or 60 mg in the morning and 40 mg in the evening orally.

v) Successive days : the hydrocortisone dose is reduced by 20 mg daily until the maintenance dose of 20 mg daily is reached. This maintenance dose is calculated from the daily secretion of normal adrenals ranging from 18.5 to 26.1 mg, average 22.3 mg.

After surgery of adenoma, rather rapid withdrawal from supplement of corticosteroid is desired to activate the reserved adrenal cortex. Therefore, the dose should be tapered downward as tolerated. If three or more symptoms and signs of acute adrenal insufficiency¹⁷⁾, such as slight fever, hypovolemia, and abdominal pain, appear in the postoperative course, 50 to 100 mg hydrocortisone should be given promptly. Before discharge from the hospital, the patients and their relatives should be instructed about the probable occurrence of adrenal insufficiency and be taught what they should do at the events.

Although early administration of synthetic ACTH (Cortrosyn Z[®]) has been recommended to induce the rapid regeneration of the atrophic reserved adrenal cortex, recovery of plasma cortisol level is not so rapid as might be expected and adverse effects such as allergic reaction or pigmentation by MSH-like action of synthetic ACTH is often seen. Basic body temperature in the morning is one of the most easily obtainable sign to indicate the improvement of Cushing's syndrome. The menstrual cycles come back rather early even when the adrenocortical response with ACTH is still very slight¹⁸⁾.

Adrenalectomy per se does not mean prompt recovery from Cushing's syndrome, but means only the first step to recovery demanding for 3 to 6 months after surgery. At least during the first two weeks after surgery, the patient is in a state of "Cushing's syndrome sustained an operative insult". Therefore, renal damage with hypertension, cardiac failure, pulmonary edema, cerebral apoplexy, wound infection, wound dehiscence and so on, should be carefully watched. Moreover, after surgery for bilateral hyperplasia, severe acute postoperative pancreatitis sometimes occurs (steroid pancreatitis)¹⁹⁾.

Pheochromocytoma

Pheochromocytoma accompanying paroxysmal hypertension may cause death from cerebral bleeding or myocardial infarction with or without blindness due to retinal arterial spasms. Therefore, treatment with alpha-adrenergic blocking agents (α -blockers) should be started to prevent severe attacks as soon as excessive secretion of catecholamines is detected by urinary chemical analysis. Thereafter, localization the tumor can be determined safely by this treatment to relieve the patient from the danger of a severe attack with its potential complications during the examinations. In the past α -blockers were not available, over half the deaths (14 in 26 cases) occurred before operation, for example during angiography. We have lost two patients before operation and a patient during angiography, but lost none after liberal use of α -blockers²⁰⁾.

Recently stimulation tests by histamine, tyramine, or glucagon have been discarded, and blood pressure response test to short acting α -blocker such as phentolamine (Regitine[®]), is used predominantly. Suppression by Regitine of high blood glucose level following glucose loading (Regitine-GTT²¹⁾) is also used as a confirmatory test.

Preoperative care : Preoperative administration of α -blocker is indicated not only for preventing severe complications due to attacks but also for replenishing the circulating blood volume, which has been depleted markedly by vasoconstriction due to excessive

catecholamines. Beta-adrenergic blocking agents (β -blockers) are used against arrhythmia and tachycardia in combination with α -blocker, which is prone to induce a somewhat β -hypersensitive state. As shown in Fig.12, almost all symptoms of pheochromocytoma can be improved by combined use of α - and β -blockers. Because of its longer action, phenoxy benzamine (10mg tablet) 1 mg/kg as an α -blocker, and propranolol (Inderal®), pindrol (Carvisken®), bufetrol (Adbiol®), or Carteolol (OPC-1085) 0.3 to 0.5 mg/kg as β -blockers are the most frequently used drugs.

Effects of combined use of α -blocker and β -blockers are evaluated by radiocardiogram using ^{131}I -RISA²²⁾. Fall of blood pressure, decrease in pulse rate, peripheral vascular resistance and blood turn over rate, and increase in circulating blood volume indicate that stable circulatory dynamics are obtained by the regimen. Cardiac depressant effect of β -blockers

Table 2. Radiocardiogram in pheochromocytomas

| BLOOD VOLME (L/SQM) | | | |
|---|--------|------------------------------|-----------------|
| | Before | α -, β -Blocker | Postoperative |
| Adrenal Pheochr. | 2552 | 3211 \square | 2897 \uparrow |
| Paraganglioma | 2144 | 1931 | 2339 \uparrow |
| Sipple's Syndrome | 3031 | 3107 \uparrow | 3509 \square |
| PLASMA VOLUME (L) | | | |
| | Before | α -, β -Blocker | Postoperative |
| Adrenal Pheochr. | 2546 | 3403 | 3111 |
| Paraganglioma | 1849 | 1724 | 1974 |
| Sipple's Syndrome | 3213 | 3206 | 3390 |
| CARDIAC INDEX (L/MIN/SQM) (3.63 \pm 0.48) | | | |
| | Before | α -, β -Blocker | Postoperative |
| Adrenal Pheochr. | 4, 37 | 5, 02 | 4, 82 |
| Paraganglioma | 4, 84 | 3, 46 | 4, 40 |
| Sipple's Syndrome | 5, 60 | 5, 70 | 5, 18 |
| STROKE INDEX (ML/BAET/SQM) (51.0 \pm 6.8) | | | |
| | Before | α -, β -Blocker | Postoperative |
| Adrenal Pheochr. | 66. 1 | 73. 9 | 65, 2 |
| Paraganglioma | 45. 6 | 43. 3 | 50. 0 |
| Sipple's Syndrome | 56. 0 | 57. 0 | 61. 7 |
| PERIPHERAL VASCULAR RESISTANCE (DYNE. SEC. CM-5, SQM) | | | |
| | Before | α -, β -Blocker | Postoperative |
| Adrenal Pheochr. | 1452 | 1241 | 1436 |
| Paraganglioma | 2588 | 2399 | 1695 |
| Sipple's Syndrome | — | 1242 | 1274 |
| BLOOD TURN-OVER RATE (F/V) (1.46 \pm 0.21) | | | |
| | Before | α -, β -Blocker | Postoperative |
| Adrenal Pheochr. | 1. 71 | 1. 56 | 1. 66 |
| Paraganglioma | 2. 26 | 1. 79 | 1. 88 |
| Sipple's Syndrome | 1. 85 | 1. 84 | 1. 48 |

CASE 15 PREOPERATIVE TREATMENT

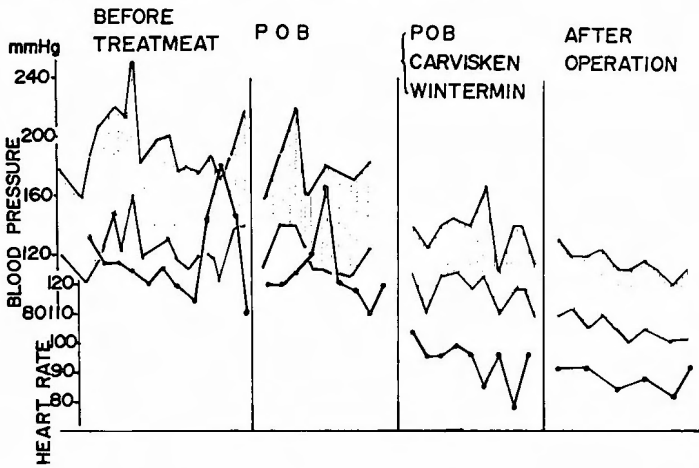


Fig. 12. Preoperative treatment of pheochromocytoma

is not seen so far as viewed from stroke volume and minute volume. However, Inderal with a violent cardiac depressant is not used nowadays. β -blockers are withheld 48 hours and α -blocker 24 hours before operation. Just before surgery, scopolamine is given in combination with Ravona® or Ional®. Atropine should not be given since it may cause arrhythmia by inducing high secretion of noradrenaline from sympathetic system.

Management during operation : Management of anesthesia for pheochromocytoma is very difficult, and a successful operation can be accomplished only under continuous

CASE 12 NLA & GOP ANESTHESIA

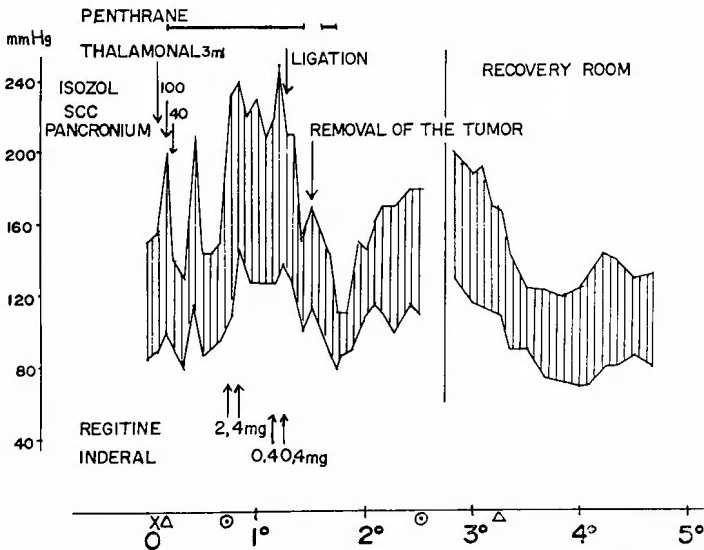


Fig. 13. Management during the operation of pheochromocytoma.

surveillance of circulatory dynamics with prompt and appropriate treatment. Electrocardiography, electric recording of blood pressure by puncture of the radial artery, central venous pressure, rectal temperature, urine volume and so on should be monitored continuously during the operation.

Manipulation of the tumor may induce prompt release of catecholamines in the body circulation. To treat sudden hypertension phentolamine is infused in drip, and for cardiac arrhythmias β -blocker is given intravenously. It should be noted that noradrenaline for hypotension following extirpation of the tumor was not required in the well-prepared patient whose circulatory blood volume has been preoperatively replenished by α - and β -blockers.

Since halothane and succinyl choline chloride induce arrhythmia, and methoxyflurane (Penthane[®]) has been implicated as a cause of renal failure, neuroleptic analgetics with some α -blocking effects are preferred for anesthesia²³.

Blood pressure almost always fall when all functioning tissue has been removed. Since multiple and ectopic pheochromocytoma can occur not infrequently, if blood pressure did not fall after extirpation of a tumor, the contralateral adrenal region, para-aortic and pelvic areas including the urinary bladder wall should be surveyed for any remained tumors.

Postoperative care : During the first 24 hours after surgery, very intensive care should be given under constant monitoring of blood pressure. If excessive fluids are given for fear of hypotension, acute pulmonary edema may occur. Postoperative diuresis usually occurs since renal vessels dilate after extirpation of tumors. In regard to urinary excretion of catecholamines after operation, adrenaline and VMA decrease rapidly and reach almost normal levels on the third day, but total metanephrine and noradrenaline decrease more slowly and reach the normal levels on the 10 to 14th day.

Visual disturbance, Raynaud's phenomenon and sexual impotency are improved by one week.

Blood pressure falls to the normal level usually within 48 hours after operation. In our country, blood pressure in 75 cases among 103 cases with pheochromocytomas fell to normal levels immediately after operation. Remaining 28 cases, however, continued to be hypertensive over one year after operation. In our own 23 cases, all symptoms including hypertension have been improved sufficiently by operation. Prognosis can usually be predicted fairly accurately by the effects of preoperative administration of α - and β -blockers.

Malignant pheochromocytoma has been reported at the incidence of 19 cases (10.7 per cent) among 177 cases of pheochromocytoma in our country. Prognosis of malignant pheochromocytoma originating in the adrenal gland is relatively fair, but the prognosis of extraadrenal malignant tumor, especially that with lung metastasis, is very grave.

We have treated a case of malignant pheochromocytoma originating in the urinary bladder wall by administration of fusaric acid, a depressant of catecholamine biosynthesis, α -, and β -blockers²⁴. Symptomatic relief was obtained and attacks were prevented until the death. Three cases of malignant pheochromocytoma have been reported to survive for 20 years. Therefore, it is valuable clinically to prevent complications and attacks by fusaric

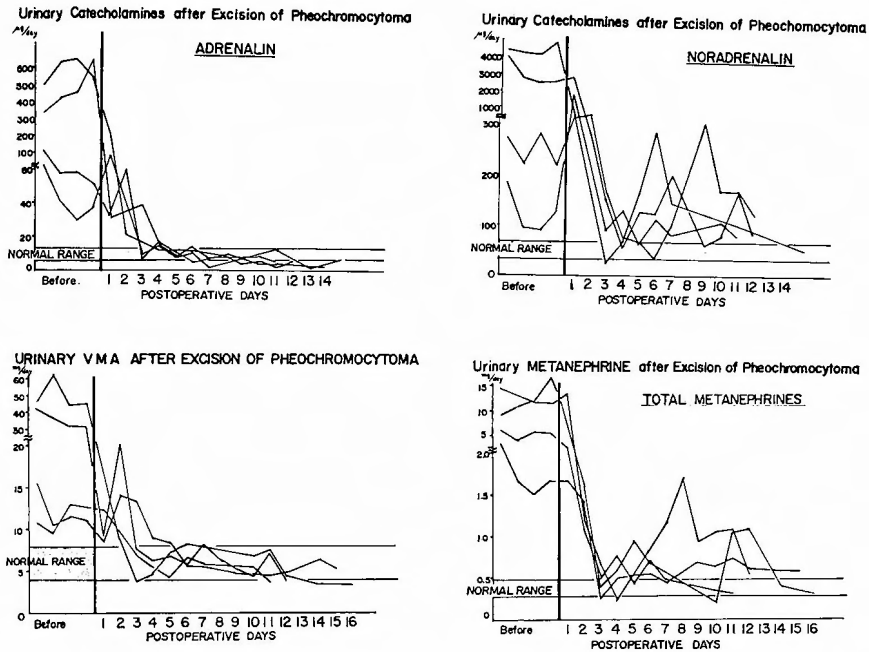


Fig. 14. Catecholamines metabolism in pheochromocytoma

acid, α -, and β -blockers.

Multiple endocrine adenopathy (MEA) with pheochromocytoma

Pheochromocytoma accompanying medullary thyroid cancer and chief cell hyperplasia of the parathyroid is called MEA type II (Sipple's syndrome) and mucosal neurinoma accompanying pheochromocytoma and/or medullary thyroid cancer is called MEA type IIb or type III⁽²⁵⁾⁽²⁶⁾. We have done adrenalectomy in two cases of Sipple's syndrome. The one case of medullary thyroid cancer was detected to have an adrenal pheochromocytoma, because the patient's family history. The other case with multiple pheochromocytomas was detected to have a mudullary thyroid cancer.

Since increased serum calcitonin level is pathognomonic in medullary thyroid cancer except renal failure, the disease can be diagnosed even when a thyroid tumor cannot yet be plapated. Serum calcitonin level returns to normal after extirpation of medullary cancer. Its high level after operation, therefore, can predict metastatic or recurrent tumors. Serum calcitonin levels should be measured in patients of pheochromocytoma, and pheochromocytoma should be suspected in patints with medullary thyroid cancer.

Conclusion

Among the endocrinological disorders with hypertension, adrenal diseases are most important. Recent progress in surgery of the adrenal gland has been reviewed on the basis of our experience on 74 cases.

i) Adrenal scintigraphy is one of the effective examination on localization of the tumor.

ii) Surgical approach being safest and surest without any severe complications should be employed. We prefer anterior transperitoneal approach, but do sometimes thoracoabdominal approach, especially on the right side, in which we have gained a remarkable success in 10 cases.

iii) Surgical indications for bilateral adrenal hyperplasia in both primary aldosteronism and Cushing's syndrome are still debatable.

iv) Surgery for pheochromocytoma has become a safe one since the preoperative introduction of α - and β -blockers.

v) The surgeons dealing with adrenal diseases should be sufficiently acquainted with whole round of endocrinological disorders and should participate actively in diagnostic study working as a member of "endocrinological team".

This paper was presented at symposium on "Hypertentions to be curable by surgical treatment" of 76th annual meeting of Japanese Surgical Association on April 7, 1976 in Tokyo.

References

- 1) Kimura, C. and Yamane, M. : Surgery in endocrinological disorders. Saishin-igaku, **21** : 2184, 1966. (Jpn)
- 2) Kimura, C. and Yamane, M. : Surgery of adrenal gland. Surg. Dig. Teat., **10** : 79, 1968. (Jpn)
- 3) Hamilton, W. : Surgical treatment of endocrine disorders. Butterworths, London, 1976.
- 4) Tanimura, H. : Surgery and its management of the adrenal diseases with hypertention. Operation (Tokyo) **31** : 273, 1977. (Jpn)
- 5) Edis, A. J. et al. Manual of endocrine surgery. Springer-Verlag, Berlin, 1975.
- 6) Zollinger, R. M. et al. Atlas of surgical operation. Vol. II. MacMillan, New York, 1967.
- 7) Nora, P. F. : Operative surgery. Lea & Febiger, Philadelphia, 1974.
- 8) Tanimura, H. : Surgery of pheochromocytoma. 110th Kinki Surg. Assoc., 1971. (Jpn)
- 9) Shimbo, S. et al. : Bladder pheochromocytoma. Jap. J. Clin. Med., **28** : 2507, 1970. (Jpn)
- 10) Hikasa, Y. et al. : Surgery of the adrenal gland—thoracoabdominal approach. Surg. Dig. Treat., **17** : 1269, 1976. (Jpn)
- 11) Tanimura, H. : Some problems in the adrenal disorders with hypertension. Jap. J. Surg. Assoc., **77** : 1160, 1976. (Jpn)
- 12) Artz, C. P. and Hardy, J. D. Management of surgical complications. 3rd Ed. W. B. Saunders, Philadelphia, 1975.
- 13) Kono, T. et al. Blood pressure fall by angiotensin II antagonist in patients with Bartter's syndrome. J. Clin. Endocrinol. Metab., **43** : 692, 1976.
- 14) Dunphy, J. E. and Way, L. W. Current surgical diagnosis and treatment. 2nd Ed. Lange, 1975.
- 15) Tanimura, H. Some problems in postoperative management of adrenal surgery (III). 114th Kinki Surg. Assoc., 1973. (Jpn)
- 16) Endo, M., Tanimura, H. et al. : On psychiatric elements in Cushing's syndrome. Clin. Psych., **17** : 1179, 1975. (Jpn)
- 17) Nagase, M. and Tanimura, H. : Acute adrenal insufficiency and its treatment. Surg. Therapy, **36** : 446, 1977. (Jpn)
- 18) Tanimura, H. Surgery and survivals in Cushing's syndrome. 111th Kinki Surg. Assoc., 1972. (Jpn)
- 19) Tanimura, H. Postoperative pancreatitis and LDH in Cushing's syndrome. J. Jap. Acad. Surg. Metab. Nutr., **9** : 355, 1975. (Jpn)
- 20) Tanimura, H. Preoperative management and surgery of pheochromocytoma. Folia Endocr. Jap., **50** : 526, 1974. (Jpn)

- 21) Shimbo, S. et al. : Regitine-GTT on pheochromocytoma. Foia Endocr. Jap., **50** : 527, 1974. (Jpn)
- 22) Nakano, Y. et al. : β -adrenergic blocking agents. ed. by Hashimoto. Yoshimoto Co., Tokyo, 1975. (Jpn)
- 23) Stamenković, L. et al. : Anaesthesia in patients with phaeochromocytoma. Anaesthesia, **31** : 941, 1976.
- 24) Shimbo, S. et al. : Treatment of pheochromocytoma with fusaric acid. Clin. Endocrinol., **24** : 571, 1976. (Jpn)
- 25) Carney, J. A. et al. : Adrenal medullary disease in multiple endocrine neoplasia, type 2. pheochromocytoma and its precursors. Am. J. Clin. Pathol., **66** : 279, 1976.
- 26) Miyazaki, T. et al. : Multiple endocrine neoplasia, type 2. Jap. J. Clin. Med., **34** : 3003, 1976.

〔和文抄録〕

副 腎 の 手 術

京都大学医学部外科学教室第2講座（主任：日笠頼則教授）

谷 村 弘，長瀬正夫，日笠頼則

副腎疾患は、高血圧を惹起する内分泌疾患として最も重要なものであり、外科的治療により治癒せしめ得る疾患でもある。それらは特異な内分泌環境にあるため、その手術に際しては、個々の症例に最も適した処置を講ずる必要がある。

われわれの教室では74例の高血圧を伴う副腎疾患の手術を経験した。原発性アルドステロン症22例、Cushing症候群29例、褐色細胞腫23例である。これらの自験例を通じて、最近の副腎疾患の外科的治療に関する諸問題と、それに対するわれわれの2、3の工夫について述べた。

- 1) 腫瘍局在診断として副腎シンチグラムがすぐれている。
- 2) 副腎到達法として手術操作を安全、確実にし、

合併症を惹起しないような方法を選ぶべきである。われわれは原則として前方経腹膜法、時に経胸腹法を行っている。

3) 原発性アルドステロン症や Cushing 症候群では両側副腎過形成が手術適応として問題が多く残されている。

4) 褐色細胞腫の手術は α , β 両遮断剤の併用による術前管理によりいちじるしく安全に行えるようになった。

しかし最も大切なのは「内分泌疾患治療チーム」の一員として、常に内分泌疾患全体の進歩に目を向け、他のメンバーとも積極的に術前から診断治療に参加、協力して行く姿勢を堅持することである。