

Title	A CASE OF RETROPERITONEAL FIBROSARCOMA (CLINICAL AND PATHOLOGICAL FINDINGS)
Author(s)	TSUNEKAWA, KENGO; TAKEDA, HARUO; MIYAWAKI, HIDETOSHI
Citation	日本外科宝函 (1958), 27(4): 964-968
Issue Date	1958-07-01
URL	http://hdl.handle.net/2433/206659
Right	
Type	Departmental Bulletin Paper
Textversion	publisher

症 例

A CASE OF RETROPERITONEAL FIBROSARCOMA (CLINICAL AND PATHOLOGICAL FINDINGS)

by

KENGO TSUNEKAWA, HARUO TAKEDA and HIDETOSHI MIYAWAKI

From the 2nd Surgical Division, Kyoto University Medical School

(Director: Prof. Dr. YASUMASA AOYAGI)

Received for publication Apr. 14, 1958

Fibrosarcoma is a malignant neoplasm which arises from fibroblasts. Its occurrence is extremely rare in the retroperitoneal space and most frequently develops on the extremities.

In this paper, a case of retroperitoneal fibrosarcoma is reported along with a brief review of the literature pertaining to this rare tumor.

CASE REPORT

A. I., a 70-year-old man, was admitted to our surgical clinic on June 3, 1957, with the chief complaint of a painless tumor in the lower abdomen.

Two years before admission he noticed a painless tumor as large as an egg in the hypogastrium. The tumor gradually grew and attained the size of a child's head one year ago and the tumor was removed by a surgeon with the diagnosis of retroperitoneal tumor. After the operation he recovered pretty well, and remained relatively free from discomfort until April, 1957, when a new firm mass was noticed in the same hypogastric region. The new tumor was about the size of child's head, and the size was almost constant for a period of three months before admission.

Recently definite loss of weight was noted. He did not complain of any abdominal pain, nausea, vomiting or jaundice. The stool and urine were normal in color and frequency.

CLINICAL FINDINGS:

The patient was an ill-nourished, moderately skeletal man. On admission, the temperature was 36.5° C, the pulse rate 60 per minute, the respiratory rate 17, and the blood pressure 166/82 mmHg. The heart was normal in size and position, there were no murmurs or abnormal sounds. The lungs were clear. There was no abnormality in the skull or skeletal system.

The abdomen neither distended nor hollow. A circumscribed distension was observed in the ileocecal region under the scar of the previous operation. On palpation, the abdominal wall was slightly rigid in the hypogastrium, and a large tumor about the size of a child's head was palpable in the right lower quadrant. It ex-

tended upward to the umbilicus, downward to the right inguinal ligament and medially toward the midline, and had a firm elastic consistency, smooth surface and no tenderness. The tumor did not show any movement on respiration and also could not be moved passively. The liver, kidney and spleen were not palpable. Rectal examination revealed no abnormalities, and normal brown stool was present in the rectum. Percussion of the abdomen revealed the presence of ascites, and the area covering the tumor was dull.

Urinalysis showed no protein or sugar, and numerous white blood cells and colon bacilli were found in the sediment. The blood count was: red blood cells, 3,84 million and white blood cells, 6400. Hemoglobin content was 80 per cent and blood proteins were normal. Electrocardiograms showed no significant abnormality. Roentgenologic examination, with contrast medium given by the oral route, showed marked medial displacement of the cecum, the ascending colon and the hepatic flexur; they were compressed by the tumor.

The diagnosis of retroperitoneal tumor was made from these clinical and roentgenological findings.

OPERATION (Fig. 1):

The operative procedure was carried out on June 5, 1957, under general anesthesia with nitrous oxide. A right paramedian incision was made, and clear non-hemorrhagic ascitic fluid flowed out when the congested partially scarred peritoneum was opened.

A huge tumor was found situated retroperitoneally lateral to the ascending colon, consisting of several masses adhering loosely to each other. Furthermore, we recognized a number of metastatic round tumors disseminated in the mesentery and the intestinal wall, about the size of a pea or a cherry.

Separating the iliac artery and the right ureter passing near the tumor, we removed all retroperitoneal masses completely but did not attempt to remove the metastatic mesenteric tumors.

POSTOPERATIVE COURSE:

From 4-24 days after the operation, a total of 650 mg of "NITROMIN (Nitrogenmasturd mono-oxide)" was administered. About one month after the operation retention of ascites became noticeable, and a large amount of fluid flowed out through the partially opened operative wound. Two months later, new tumors the size of a man's fist became palpable in the ileocecal and umbilical regions. They did not increase in size up until the 90th hospital day when the patient was discharged. Now, 5 months after the operation, the patient is being treated by the administration of 2 mg of radioactive phosphorus (P^{32}) once monthly without showing marked growth of the tumor.

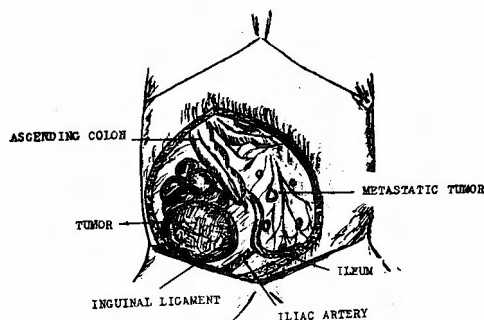


Fig. 1 Schematic illustration of the tumors.

PATHOLOGICAL EXAMINATION (Fig. 2, 3):

The specimen consisted of ten tumors weighing 1500 g in total, and the largest mass weighed 700 g and measured $11 \times 10 \times 10$ cm. Some of these tumors showed a smooth surface and a yellowish-red color, others were nodular and dark red. Each mass of the tumor was parenchymatous with a firm elastic and partially soft consistency. A little necrosis and hemorrhage were observed on their cut surfaces.

The histological diagnosis was "Fibrosarcoma".

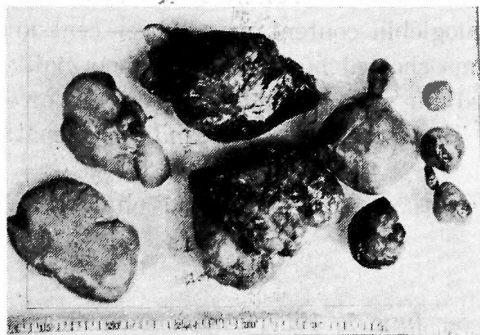

Fig. 2 Specimen consists of ten tumors.




Fig. 3 Cut surfaces

DISCUSSION

A review of the literature has revealed that only a few cases of retroperitoneal fibrosarcoma have been reported. In Japan, the first case was reported in 1952 by KURAKAMI, and the second case by IZUKA, who collected 6 cases of fibroma. In foreign reports, of the 120 retroperitoneal tumors reported by PACK and TABAH, only 6 were fibrosarcoma.

As has been well pointed out by PACK and TABAH, there has been considerable confusion about the specific limitation of the fibrosarcomas and their histologic distinction from other soft somatic sarcomas containing a moiety of fibroblastic elements. Fibrosarcomas are usually included in the category of "spindle cell sarcomas", some of which may be synoviomas, rhabdomyosarcomas and malignant neurilemomas. For this reason, in order to strictly differentiate our case from other malignant neoplasms arising from primitive mesenchyme, we used for histological examination not only the usual hematoxylin-eosin staining, but also special staining techniques such as BIELSCHOWSKY'S silver impregnation and VAN GIESON'S acid fuchsin method.

The microscopic features of our case are as follows.

In the hematoxylin-eosin preparation (Fig. 4, 5), the tumor cells are arranged vortically. Their shape and size are not uniform, for example, some are ovoid and others spindle-shaped. The nuclei are markedly hyperchromatic and numerous nucleoli are observed. Mitoses can be found occasionally. In a few portions of the specimens, fatty degeneration and necrosis are noted.

Observing the silver stained preparation (Fig. 6), we recognized that each

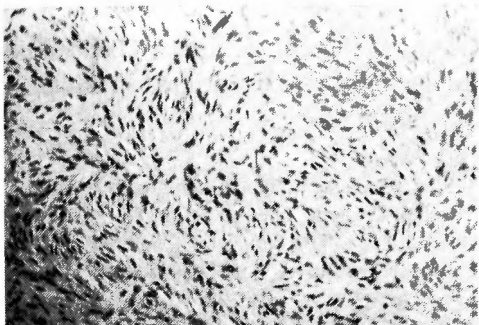


Fig. 4 Tumor cells are arranged vortically. Hematoxylin-eosin stain.

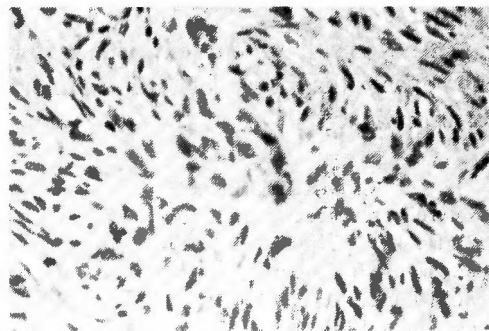


Fig. 5 Mitoses are seen. Hematoxylin-eosin stain.

cell is contained within a wrapping of fine argyrophilic fibrils.

In VAN GIESON'S acid fuchsin preparation, an abundance of collagen stroma which waves into an interdigitating pattern is proved.

The above mentioned histological features are those of fibrosarcoma.

As PACK describes, retroperitoneal fibrosarcomas metastasize less frequently than other mesodermal tumors. The usual route is via the blood stream but sometimes metastasis is via the lymphatics. In our case, a number of small metastatic tumors were observed in the abdominal cavity. These may be considered the result of direct dissemination of the tumor cells.

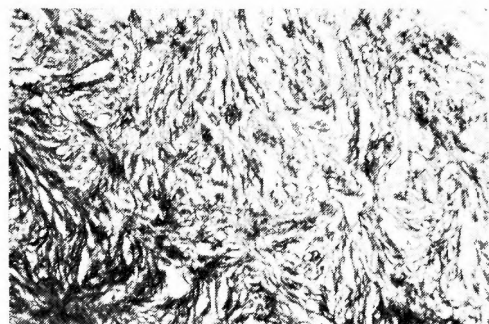


Fig. 6 Argyrophilic fibrils. BIELSCHOWSKY'S stain.

Some authors claim that the radical surgical excision of the retroperitoneal tumors is extremely difficult and so the recurrences are observed in about one third of the cases. Our patient had his initial surgical excision about one year ago, and recurrences developed subsequently. In the second operation, the main recurrent tumors were resected but the metastatic tumors were left in the abdominal cavity. The remaining metastatic tumors have been growing progressively for three months since the last operation. This malignant feature of the clinical course agreed with the malignancy of the histological findings.

Deep x-ray, chemotherapy or radioactive isotopes are usually employed for the palliative therapy. In our case "NITROMIN" was used and now P^{32} is being administered. The remarkable effect of these therapies has not been recognized up to date.

SUMMARY

A case of retroperitoneal fibrosarcoma is described, and its histological features are discussed.

We could find only two cases of this disease reported in the literature in

Japan.

As a result of our experience and a review of the literature, we believe that the exact diagnosis of this tumor is possible only with accurate histological examination.

REFERENCES

- 1) Anderson, W. A. D.: Pathology. 1948.
- 2) Howard, H. and Howard, S.: Perirenal Fibrosarcoma. J. Urol., **40**, 491, 1938.
- 3) Iizuka, M. and Okui, R.: One Case of Retroperitoneal Fibrosarcoma. Rinsyogeka, **12**, 757, 1957.
- 4) Kurakami, T. and Ogawa, M.: A Case of the Retroperitoneal Fibrosarkoma. Geka, **14**, 533, 1952.
- 5) Pack, G. T. and Tabah, E. J.: Primary Retroperitoneal Tumors. Surg. Gynec. & Obst., **99**, 209, 1954.
- 6) Pack, G. T. and Ariel, I. M.: Fibrosarcoma of the Soft Somatic Tissues. Surg., **31**, 443, 1952.
- 7) Willis, R. A.: Pathology of Tumors. 1953.
- 8) William, B.: A Text-book of Pathology. 1952.

和文抄録

後腹膜線維肉腫の1例

京都大学医学部外科学教室第2講座 (指導: 青柳安誠教授)

恒川謙吾・武田温雄・宮脇英利

70才の男, 無痛性下腹部腫瘍を主訴として入院した。手術により10箇の腫瘍が互に癒着して成る小児頭大の後腹膜腫瘍を剔出した。組織学的に線維肉腫であ

るが, 後腹膜腔に線維肉腫の発生する事は極めて稀なものである。此の腫瘍について組織学的及び文献的考察を行つた。