

Title	NEW SURGICAL APPROACH TO THE URETHRA : SUPRA-AND ANTE-PUBIC URTHROTOMY
Author(s)	HARADA, NAOHIKO; SANO, NOBUO; SAWADA, SOZO; NARIKAWA, YASUO; TSUDA, TOSHINOBU; IWADE, TIZUKO; FUKUYAMA, KENSHIRO; ODA KAZUO
Citation	日本外科宝函 (1957), 26(5): 767-774
Issue Date	1957-09-01
URL	http://hdl.handle.net/2433/206406
Right	
Type	Departmental Bulletin Paper
Textversion	publisher

 臨 床

NEW SURGICAL APPROACH TO THE URETHRA : SUPRA- AND ANTE-PUBIC URTHROTOMY

NAOHIKO HARADA, NOBUO SANO, SOZO SAWADA, YASUO
NARIKAWA, TOSHINOBU TSUDA, TIZUKO IWADE,
KENSHIRO FUKUYAMA and KAZUO ODA

Department of Surgery, Osaka City University Medical School
(Director : Prof. Dr. YAEMON SHIRAHARA)

The correction of urethral obturation which is caused by urolithiasis, injuries and inflammation is directed toward removal of the obstruction and re-establishment of the continuity of the urethra. The simplest procedure which can fulfil these objectives is a insertion of an urethral catheter. But, generally, a catheter can not be passed easily in cases of deformed male urethra. In such a case, one has to incise both the suprapubic region and the perineum. A catheter is passed through the external orifice of the urethra toward its lesion, and if, after exposure of the lesion, the catheter can be directed into the proximal segment of the urethra and on into the bladder, only this is necessary (Fig. 1 & 2). However, it is often impossible to find the proximal segment of the urethra, and in such instances a catheter has to be passed retrograde into the posterior urethra to the lesion transvesically through a suprapubic incision. When the two ends of the urethra have been identified, the two catheters are connected (Fig. 3), and the catheter in distal portion from the lesion is drawn into the bladder. By this procedure, it is inconvenient that 2 teams of operators, that is, a suprapubic- and a perineal-team, work simultaneously. However, it is often necessary to use this procedure in practice.

Therefore, if a urethral catheter can be passed through by only one incision, its practical value would be enormous. Recently, we have devised a new surgical approach to the urethra named supra- and ante-pubic urethrotomy (Fig. 4, 5, & 6). We wish to describe in details the technique of this operation and our clinical experiences in this paper.

1. AN ANATOMICAL ILLUSTRATION OF THE TECHNIQUE

Posterior half of the urethra is generally apt to be affected by various causes (Fig. 1). An obturation of this portion has been ordinarily handled by both the external and the suprapubic transvesical urethrotomy. However, we have devised a procedure of access to the urethra by the supra- and ante-pubic approach (Fig. 4,

5, & 6). The approach needs only a suprapubic incision, and has the same advantage that has been formerly achieved by means of those two approaches. Furthermore, it is remarkable that the approach combined with the symphysectomy is capable to present a wider field for operation, even though the posterior urethra may be deformed seriously. But the approach is not recommended for lesions in the short urethra of the female (Fig. 7).

2. OPERATIVE TECHNIQUE

1) Position of the patient: As it is unnecessary to incise the perineum and to divide the operators into two teams, the patient is placed in an ordinal Trendelenburg's position (Fig. 8).

2) Anesthesia: The spinal anesthesia is recommended and sufficient.

3) Incision: A long suprapubic mid line incision is made and extended downward to the caudal, passing over the anterior surface of the pubic symphysis, round the root of the penis, and reaches the midpoint of the scrotum at the median raphe. The penile suspensory ligament should not be incised carefully (Fig. 9).

4) Dissection of the Bladder: The incision is carried out serially through the skin, subcutaneous tissue, the fascia of the rectus muscle, and the muscle itself. Then the location of the peritoneal reflection is recognized and this is displaced upward (Fig. 10). Thus the superior wall of the bladder is exposed, and is incised sharply. As the bladder is usually expanded with large quantity of stagnated urine at the time of urethral obturation, dissection of the bladder is easy to practise. When the urine is sucked up through the bladder opening, the patient is apt to feel well being and his general condition is recovered immediately (Fig. 11).

5) Observation of the Urethra and its Lesion: Inside of the bladder, especially the trigone, should be observed carefully. In case of urethral obturation, the ureters demonstrate a strong peristalsis, and the urine springs from their orifices actively, and the internal urethral orifice is extremely expanded. A catheter is then inserted into the urethra retrogradely, until it arrives at the affected area. This will indicate the orientation of the injured portion.

6) Exposure of the Urethra:

a) The anterior Urethra: The area between the spermatic cord and the penile suspensory ligament is developed by blunt dissection, until the bulb of urethra is exposed in the field at the root of the median raphe. The resistance of the urethral catheter can be palpated along the anterior urethra in both corpora cavernosum.

b) The Posterior Urethra: The posterior urethra is so difficult of access because of its anatomical situation that either symphysectomy or symphyseotomy is necessary to reach the affected area. The symphysis has 4 feet (Fig. 12). The cutting lines of these 4 feet must be placed near the medial side in order to dissect a portion as small as possible. The penile suspensory ligament, puboprostatic ligament, and levator ani muscle need not to be cut, when the resection is subperiostally applied. But, when two inferior feet which run lateroposteriorly, are cut off,

the fibres of the levator ani muscle are sometimes severed. Cares should be taken to denude the inner layer of the priost in order to prevent the side-injuries. After the periostal denudation of the pubic bone, symphysectomy is easily done with a saw, and the posterior urethra can be demonstrated under direct vision in the space where the symphysis had been situated (Figg. 13 & 14). It is preferable that the resected symphysis is put back and fixed with suture in the original place after the completion of intrapelvic procedures. However, its defect would never cause such complications as deformity of the pelvis, disturbance of gait or impossibility of erection of the penis.

If the resected bone is abandoned, the attached point of these ligaments has to be anchored with silk suture at both the inner and the outer layer of the remnant periost, in order to increase its strength and to promote regeneration of the bone from it.

7) Removal of the Obturating Agent : After the obturated lesion of the urethra is exposed, the obturating agent is removed by urethrotomy or by urethrectomy.

8) Reconstruction of the Continuity of the Urethra : The catheter which is inserted in the urethra retrogradely is connected with another one normogradely inserted at the lesion where the obturating agent has been found, and the catheter is pulled into the bladder in such a manner that the retrograde catheter would be utilized as a guiding catheter (Fig. 15). A metal sound for the catheter is convenient as a guide.

9) Closure : The urethra is sutured with fine silk and the wound of the abdominal wall is also closed. The bladder and the antepubic space are drained after this procedure. One of the authors (Sawada) devised an effectful drainage. Namely, the urethral catheter is drawn out through the suprapubic fistula and several holes are made on the side wall of its intravesical portion. Then both ends of the catheter are connected with a suction. This looped drainage is convenient to prevent an accidental falling (Fig. 16).

10) Postoperative Treatment : The urine must not be laid pool in the baldder. If the suction is effective, the sutured wound will be dry and clean. The loop-drain should be left in situ more than 3 weeks postoperatively, but the antepubic drain can be drawn out earlier.

3. CASE REPORT

1) K. M., age 61, Japanese male; The patient has been complaining of a urinary obturation, and admitted to our hospital, on August 24, 1956. He had suffered from gonorrhoeal urethritis 40 years ago. For the last 20 years, he has been treated frequently for dysuria and a sense of suprapubic expansion by external urethrostomies. For 2 days, he could not micturate urine on account of the urethral stenosis.

Clinical Findings : The suprapubic region was expanded extremely, and the urethra completely obturated at the point of 6 cm from the glans. The ventral side of the penis had a hard cicatricial induration. The urethra was not palpated,

but a urethral stone was palpated.

Operation : The bladder was opened with a suprapubic incision, and about 900 cc of urine was sucked up through the opening. A sound was inserted retrogradely from the internal urethral orifice to demonstrate the urethral stone (Fig. 17). Then a supra- and ante-pubic urethrotomy which is reported by the authors in the paper was performed. Thus the stone in the urethra was taken out and a urethral catheter was inserted for the re-establishment of the injured urethra. About 110 days was necessary postoperatively to close the urethra.

Discussion : This case had a stone with a stenosis in the urethra as a result of the former operation. Usually, in routine, surgeon prefers to an external urethrotomy in such a case. But the thick cicatricial tissue made the authors give up to take an ordinary procedure, and selected our new technique in the area where there was no scar.

2) H. G., age 28, Japanese male; The patient had been complaining of a stenosis of the urethra, and was admitted to our hospital, on February 11, 1955. He had a trauma at the perineum and was submitted to external urethrotomy 10 years ago. After the first operation, a fine urethroperineal fistula was built and could not be closed with dyspareunia and leakage of urine. Since then he had been operated 7 times and his urine was not clear.

Clinical Findings : The patient had a wide cicatricial surface on the abdomen, perineum, and penis shaft. The urethra had a stricture at the membranous portion and his bladder was extremely expanded.

Operation : The abdominal skin and fascia was incised. The tissue of the lesion had been changed into a thick scar and adhered to the symphysis. We could expose the pubis with much effort, and cut off the pubic bone, demonstrating a retropubic periurethral abscess due to the injury on the posterior urethra (Fig. 18). The abscess was cleaned, and plasty of the urethra was performed. A catheter was passed through the full length of the urethra with a guide-catheter. The bladder was closed. A drainage catheter was left in the Retzius' space. After 60 days following the operation, the patient was recovered completely.

Discussion : External urethrotomy and sectio alta are not preferable in such a case as there is a retropubic periurethral abscess. But one could find the abscess by symphysectomy. It was another convenient advantage that we could get a wider operating field in the retropubic space by this approach with symphysectomy.

CONCLUSION

The authors give a report on the details of their new operative technique for deformed urethra, named supra- and ante-pubic urethrotomy, and its clinical application on a few cases, discussing its special advantages.

REFERENCES

1) Baird, S. S. : Urethrectomy subsequent to total cystectomy. *J. Urol.*, **74**; 621: 1955.

2) Comarr, A. E. : An adjunct in the management of the penoscrotal abscess. *J. Urol.*, **74**; 818: 1955.

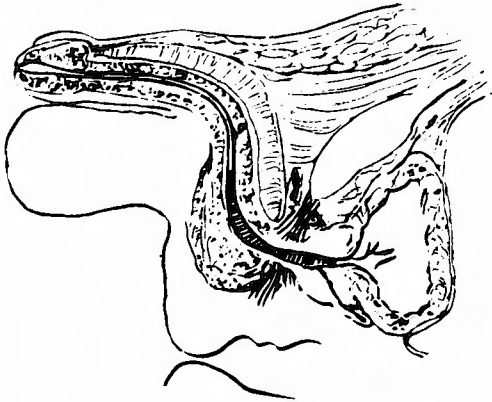


Fig. 1. Posterior half of the urethra is generally apt to be affected by various causes.

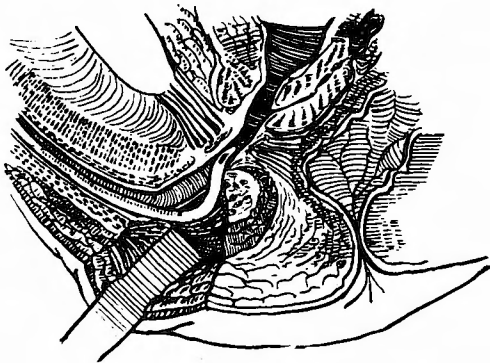


Fig. 2. A catheter can be directed into the proximal segment of the urethra.

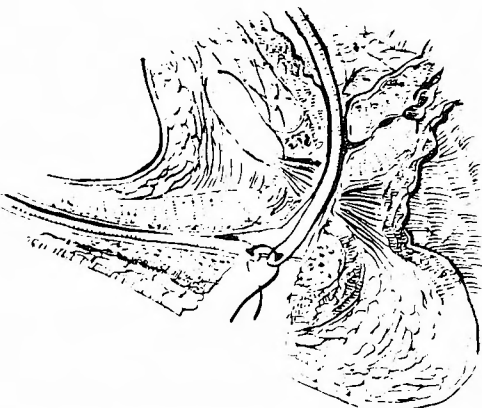


Fig. 3. Two catheters are connected and the catheter in distal portion from the lesion is drawn into the bladder.

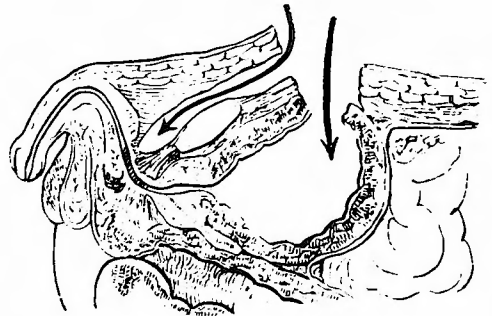


Fig. 4. Retropubic and transvesical approaches to the urethra.

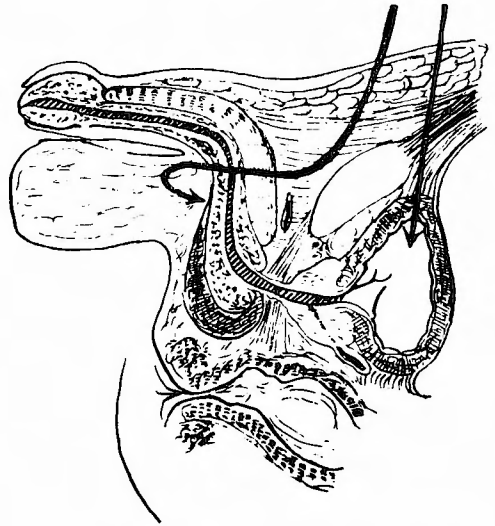


Fig. 5. Supra- and ante-pubic approach to the urethra.

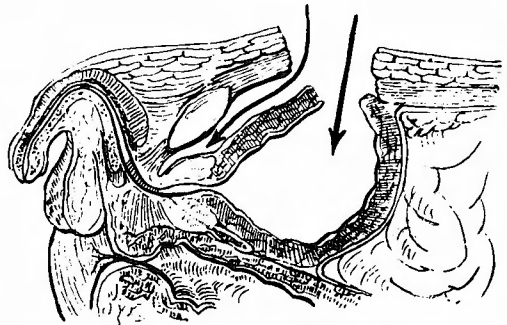


Fig. 6. Supra- and ante-pubic approach to the urethra.

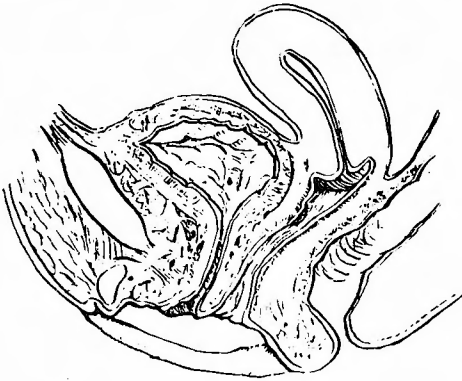


Fig. 7. Female's short urethra.



Fig. 8. Trendelenburg's position.

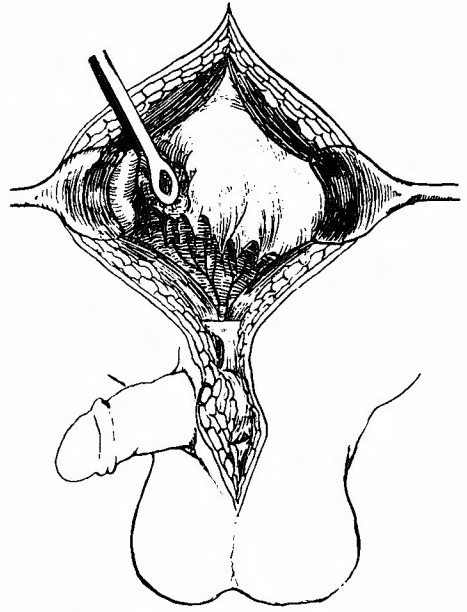


Fig. 10. The peritoneal reflection is displaced upward.

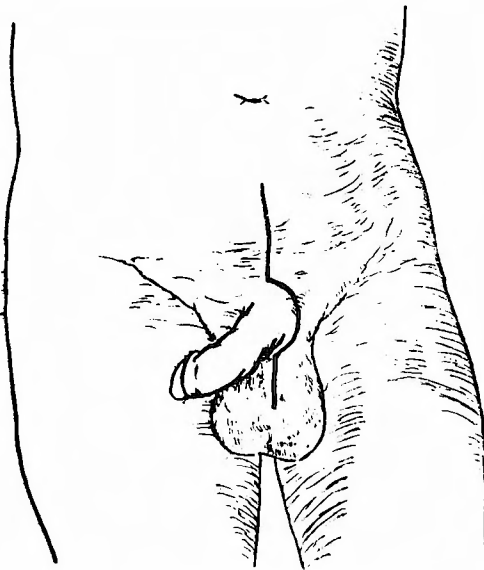


Fig. 9. A long suprapubic midline incision is made.

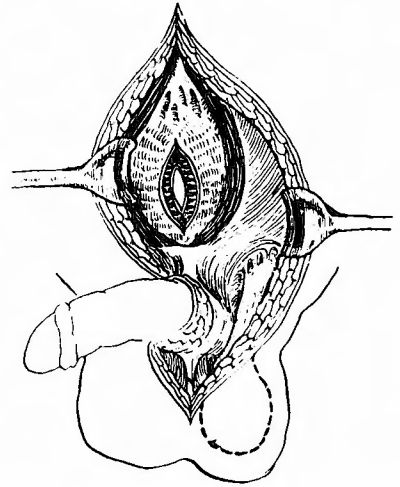


Fig. 11. The superior wall of the bladder is incised sharply.

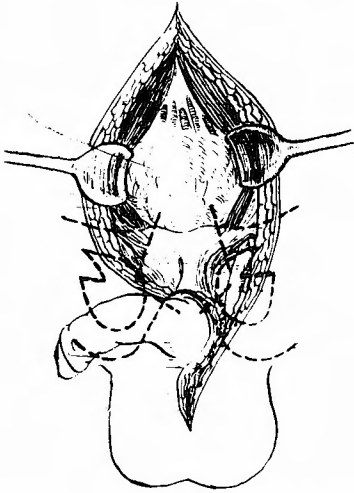


Fig. 12. The symphysis has 4 feet.

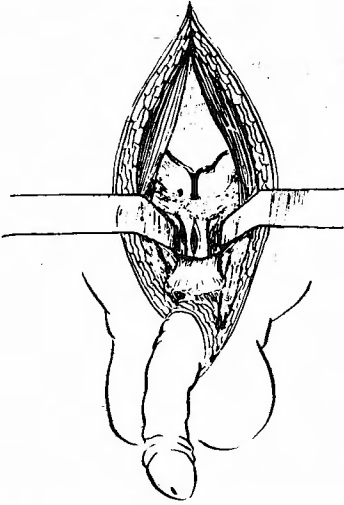


Fig. 13. The posterior urethra can be demonstrated under direct vision in the space where the symphysis was situated

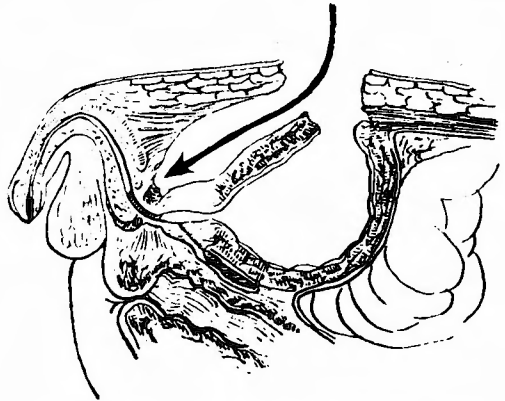


Fig. 14. Symphysectomy is easily done and the posterior urethra can be demonstrated.

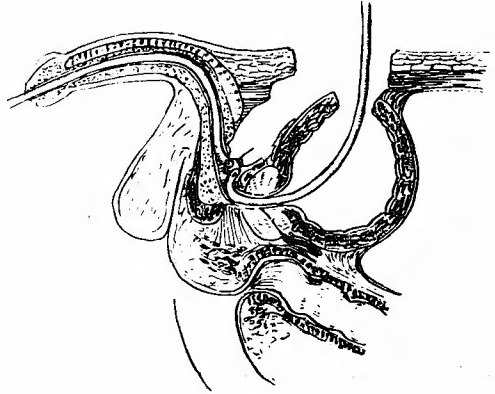


Fig. 15. The normograde catheter is pulled into the bladder in such a manner that the retrograde catheter would be utilized as a guide-one.

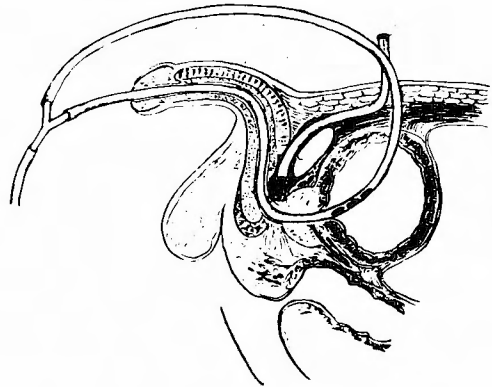


Fig. 16. The both ends of the catheter are connected with a suction. This looped drainage is convenient to prevent an accidental falling.

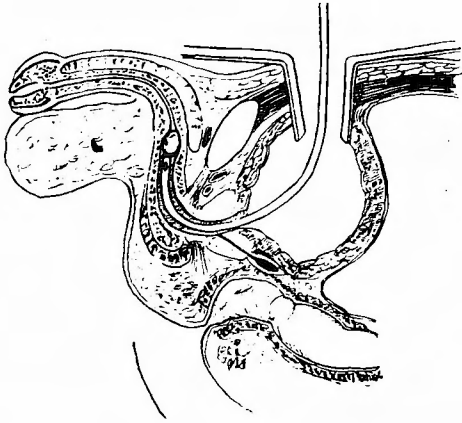


Fig. 17. An urethral stone was demonstrated.

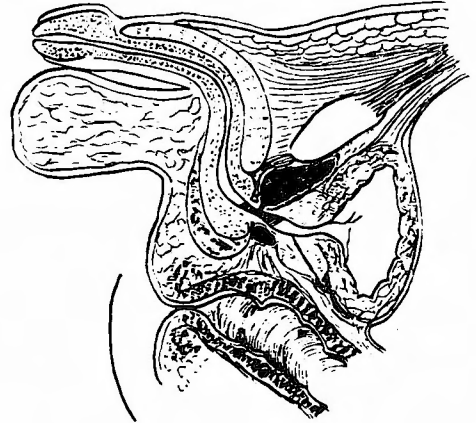


Fig. 18. A retropubic periurethral abscess due to the injury on the posterior urethra was discovered.

和文抄録

恥骨上恥骨前尿道切開術

大阪市立大学医学部外科学教室（主任：白羽弥右衛門 教授）

原田 直彦・佐野 信雄・沢田蘇心三・成川 康夫
津田 利信・岩出千鶴子・福山謙四郎・小田 和夫

従来、尿道に対する外科的進入路としては、外尿道切開術、経尿道進路、恥骨後部進路、ならびに経膀胱的進路の4者があつた。とくに尿道の変形が甚しい症例においては、経膀胱的進入路と、外尿道切開術との、合併術式が多く用いられてきた。しかし、この術式には、術者を2分しなければならない欠点がある。

最近、私達は、恥骨前から尿道に達する術式を考案し、恥骨上恥骨前尿道切開術と名づけた。この術式に

おいては、すべての例において、1つの手術野で手術を遂行することができる利点があり、さらに、必要に応じては、手術野中に露出している恥骨縫合を切除することによつて、後部尿道のすべてを直視下に露出することもできる。

私達は、この術式の詳細と、その臨床応用例とをここに報告した。