

Title	CONSTRUCTION OF VENOUS VALVES AS A TREATMENT OF VARICOSE VEINS
Author(s)	Harada, Naohiko; Inoue, Hisashi; Tsukuda, Mitsuo; Kogame, Kiyotaka
Citation	日本外科宝函 (1956), 25(1): 29-34
Issue Date	1956-01-01
URL	<a href="http://hdl.handle.net/2433/206241">http://hdl.handle.net/2433/206241</a>
Right	
Type	Departmental Bulletin Paper
Textversion	publisher

---

 臨 床
 

---

## CONSTRUCTION OF VENOUS VALVES AS A TREATMENT OF VARICOSE VEINS

by

NAOHIKO HARADA, HISASHI INOUE, MITSUO TSUKUDA and KIYOTAKA KOGAME

From the 2nd Surgical Division, Kyoto University Medical School

Director : Prof. Dr. YASUMASA AOYAGI

### INTRODUCTION

Varicose veins of the lower extremities as a postphlebotic syndrome are frequently observed clinically, and in the pathogenesis of this disease the valvular incompetency of the venous system is one of the factors presumed to be of great importance. Various kinds of operative procedures have been proposed for the treatment of varicose veins since Trendelenburg's report. They are summarized as follows.

- 1, High saphenous ligation with or without stripping of veins (HOMANS, De TAKATES, LINTON)
- 2, Lumbar sympathetic block or sympathectomy (LERICHE, OCKSNER, De BAKEY)
- 3, Ligation or segmental resection of the femoral vein (HOMANS, LINTON)
- 4, Ligation of deep vein (BAUER)

These procedures are, however, merely expectant treatments, which never serve to cure the valvular incompetency directly. We are convinced that the active treatment of varicose veins must be performed on venous valves themselves. Therefore, the construction of venous valves would be a more active and more satisfactory treatment, if the valves constructed operatively could maintain complete competency.

EISEMAN, in 1953, described a method for the construction of a venous valve by creating a permanent intussusception in a short segment of the inferior vena cava of the dog. We have used this principle for the construction of venous valves as a treatment of varicose veins. Successful results have been obtained in 2 cases, in which venous valves have been constructed in the great saphenous veins.

### CASE REPORT

Case 1 : Mr. S. M., aged 17 years, a machine repairer, was admitted complaining of a slight pain in the left leg. He had noticed a painless swelling in the left lower extremity 4 years previously, which had a snake-like appearance over the medial and anterior portion of the left limb in the upright position but disappeared in the supine position. For the last 2 years he had been a machine repairer and this occupation had required him to keep standing for many hours. The appearance of this swelling had become gradually more frequent and slight pain had developed recently. However neither ulceration nor eczema was observed.

Physical examination revealed a moderately nourished middle-sized man with neither cardiac failure nor blood disease. In the upright position, a tumor (5 cm × 6 cm in size) was recognized in his left limb which extended from the medial posterior to the lateral surface beyond the anterior margin of the tibia. The tumor did not disappear but did diminish in size when the patient lay in bed. Slight brownish pigmentation was seen over the tumor. Inspection of the tumor showed that it consisted of abnormally dilated and tangled subcutaneous veins, the diameter of which was about 1 cm. Trendelenburg's test was positive, and phlebography showed an abnormally dilated great saphenous vein. (See Fig. 1. 2)

Case 1.

Operation : In the middle 1/3 of the thigh, the skin was incised for about 10 cm in length along the great saphenous vein, and the great saphenous trunk was completely mobilized by ligating two tributary veins. The trunk showed a marked contraction after this manual procedure alone and its diameter diminished to about 0.5 cm. Then intussusception was attained by placing arterial sutures along the longitudinal axis of the vein with the second bite of the suture placed 3 cm proximal to the first. Depending on the size of the vein, 6 such sutures were placed circumferentially around the vein. Intussusception was achieved by proximal guidance of the point of the intussusception into the lumen of the vein with a dull pointed probe, therefore the valve cusp consisted of the intussuscepted vein wall itself. (See Fig. 3)

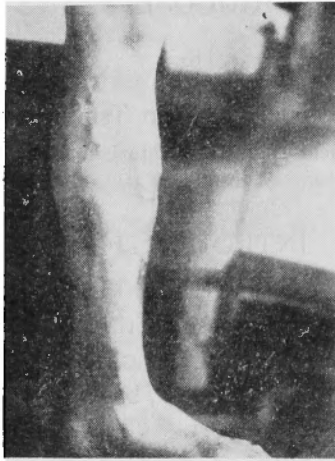

Fig. 1

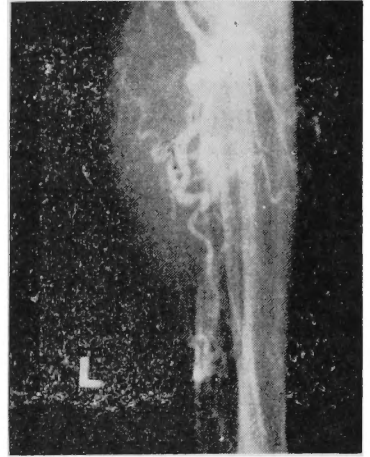


Fig. 2

Operation : In the middle 1/3 of the thigh, the skin was incised for about 10 cm in length along the great saphenous vein, and the great saphenous trunk was completely mobilized by ligating two tributary veins. The trunk showed a marked contraction after this manual procedure alone and its diameter diminished to about 0.5 cm. Then intussusception was attained by placing arterial sutures along the longitudinal axis of the vein with the second bite of the suture placed 3 cm proximal to the first. Depending on the size of the vein, 6 such sutures were placed circumferentially around the vein. Intussusception was achieved by proximal guidance of the point of the intussusception into the lumen of the vein with a dull pointed probe, therefore the valve cusp consisted of the intussuscepted vein wall itself. (See Fig. 3)

Prior to closing the incision the competency of the valve was tested as follows. Blood flow was stopped by applying pressure to the vein above and blow the valve, and normal saline solution was injected into the collapsed vein above and below the valve. The solution injected into the proximal portion of the

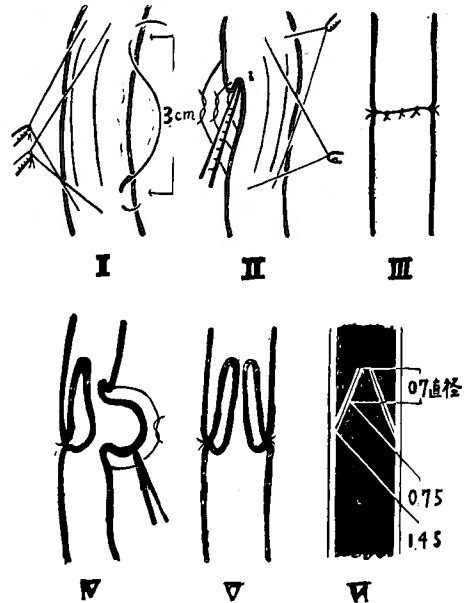


Fig. 3  
Operation Method

valve did not pass through the valve, and dilatation of the proximal portion was observed without any dilatation of the distal portion. The solution put into the distal portion of the valve flowed through the valve without resistance, and caused the proximal portion of the vein to dilate markedly but the distal portion was not dilated. This definitely proved that the constructed valve demonstrated a complete competency and that reflux blood flow did not occur.

Postoperative course : Immediately after the operation, 10cc of Heparin-Natrium solution diluted in 1000 cc of 5 % glucose solution was administered by continuous intravenous infusion. The patient was kept in bed for 3 days after the operation. Varicose veins disappeared when he stood up on the 4 postoperative day, so he was allowed to walk without elastic bandage. On the 8th day, the wound opened spontaneously due to subcutaneous hematoma and secondary sutures were applied ; palpation and phlebography revealed the existence of a thrombus in the great saphenous vein, which extended 15 cm proximally and 5 cm distally from the valve. Therefore, it was evident that the disappearance of varicose veins was not due to the competency of the valve but to the obliteration of the vein. But the wound showed primary healing, the patient was discharged with no complaint 24 days following operation, and he returned to his work. On the 30th post-operative day, he noticed the sudden appearance of varicose veins on the left limb again, which extended over about 1/2 the area of the previous tumor. Though they disappeared spontaneously after resting in bed for 3 days, he suffered from dyspnea, tachypnea and chilliness for a few days. However, he recovered rapidly from these chest symptoms, and no abnormalities were recognized on the 35th postoperative day. Physical examinations and phlebograms on the 32, 48, 52, and 63. postoperative days revealed neither the recurrence of the varicose veins nor the existence of the thrombus in the great saphenous trunk. (See Fig. 4) Blood was flowing in the slightly dilated vein without resistance through the valve, which demonstrated complete

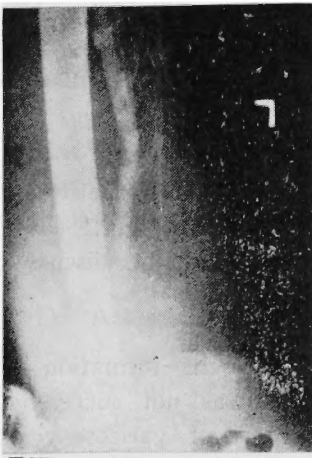

Fig. 4  
after operatin

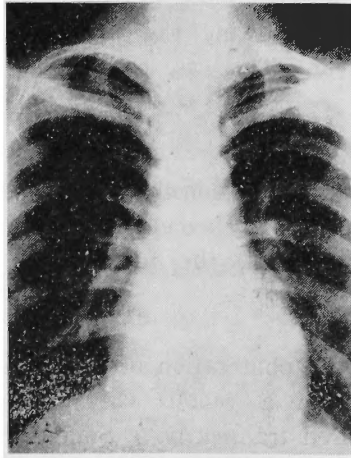


Fig. 5

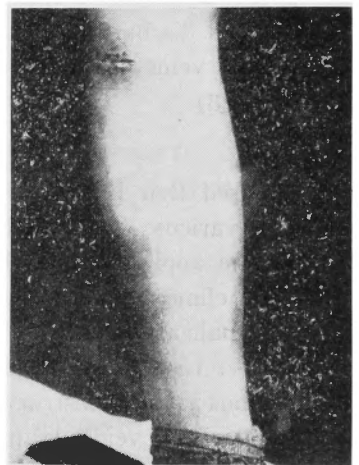

Fig. 6

competency against reflux blood flow. X-Ray examination of the lung revealed no sign suggesting an embolic infarct. (See Fig. 5) These findings indicate the complete healing of varicose veins. (See Fig. 6)

Case 2 : Mr. T. M., aged 46 years, a farmer, was admitted suffering from varicose veins of both legs, which had appeared during the preceding 20 years. Physical examination revealed a middle-sized and well-nourished man, with neither cardiac disease nor blood anomaly.

Painless varicose veins were recognized over the medial portions of both legs. Trendelenburg's test was positive on both sides, and the phlebography on the right side revealed an abnormally dilated and tangled great saphenous vein. (See Fig. 7)

Operation : Venous valves were constructed in both great saphenous trunks by the same method as in Case 1.

Postoperative course : Observation on the 3rd postoperative day showed complete disappearance of varicose veins on the right side, but those on the left side did not disappear, though they diminished. Phlebography on the left side, which was performed on the 6th post-operative day, revealed obliteration of the valve and also the existence of several collateral veins, which extended proximally beyond the portion of valve construction. Therefore, a venous valve was constructed again on the left great saphenous trunk at a point close to the saphenofemoral junction. The patient was discharged 2 weeks following the first operation with no appearance of varicose veins on either sides. This case complained of no chest symptoms. (See Fig. 8)

## DISCUSSION

We used Ben Eiseman's method of construction of venous valves for the treatment of varicose veins, and surprisingly excellent results were obtained in 2 cases. As for the application of this method, the following problems must be discussed from the clinical point of view.

### 1) Recanalization of thrombus

In case 1., we recognized the obliteration of the vein due to the formation of a thrombus; the construction of a venous valve, therefore, was not successful, though varicose veins disappeared transiently. Sudden recurrence of varicose veins and temporary chest symptoms were considered to be the result of an embolus due to the recanalization of the thrombus in the great saphenous vein. The displace-

Case, 2

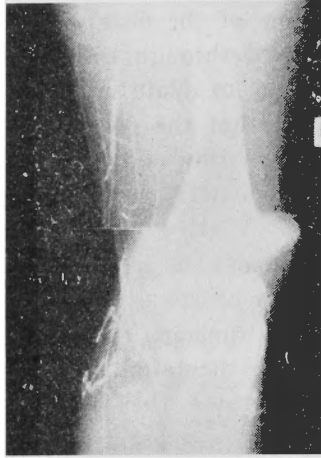


Fig. 7 Before operation

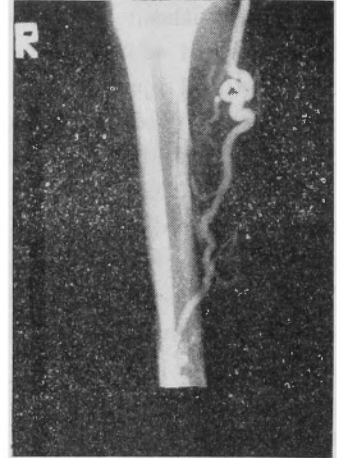


Fig. 8 After operation

ment of the thrombus, which was not closely adherent to the vessel wall, must have been caused by the sudden rise in arterial pressure due to muscle exercise. The chest symptoms were, of course, considered to be a sign of lung embolus; but fortunately it was not fatal. It's a well-known fact that a thrombus without infection is not dangerous to life because it disintegrates gradually and easily. Examination after the recanalization of the thrombus revealed the complete competency of the venous valves, and this finding we had not expected. It could be stated from our results that thrombus formation did not influence the competency of the venous valves. EDWARDS maintained that the thrombus without ligation always showed spontaneous recanalization, and the result of our study was in agreement with his opinion. Thrombus formation and its spontaneous recanalization were points which differ from the results of EISEMAN's experiment.

#### 2) Location of the valve construction

Varicose veins are considered to be caused by the incompetency of venous valves, namely by the decreased resistance against the sudden rise of blood pressure. Therefore, the construction of venous valves for the treatment of varicose veins should be performed in the portion as high as possible close to the saphenofemoral junction, if the deep venous system is competent as in these cases. However, the great saphenous trunk must be mobilized for about 10 cm for the intussusception, therefore the valve construction is impossible at a distance less than 5 cm from the saphenofemoral junction. In our cases, the valves were constructed about 10 cm distal to the junction, and two tributary veins were sectioned. We are convinced that it will be possible in future to construct a valve at the point of the junction, and that it would be much easier and more rational to construct a valve in the common iliac vein.

#### 3) Control of intussuscepting the vein wall

Because of the contraction of veins, the procedure of intussuscepting the distal portion into the proximal portion, especially in the case of fine veins, is unexpectedly difficult, and the endothelium is fairly damaged by the procedure. Therefore, it is reasonable fact that a thrombus is formed after the operation.

#### 4) Application of this method for other organs.

This principle of venous valve construction may be applied to constructing valves in other organs, e. g. the intestine, cholodochus, for the treatment of their valvular incompetency.

### SUMMARY

1) According to Eiseman's intussuscepting method, the construction of venous valves in the great saphenous vein was performed in patients with varicose veins, and successful results were obtained in both cases.

2) After the construction of a venous valve a thrombus was formed transiently, but it showed spontaneous recanalization. The valve demonstrated complete competency after its recanalization, and varicose veins completely disappeared.

3) The construction of a venous valve is the most active treatment of varicose

veins of the lower extremities.

#### Reference

1) Eiseman, B. : An Operative Technique for the Construction of Venous Valves ; Surg. Gynec. & Obst. 2) Aycock, T. B. : The Problem of Venous Thrombosis : J.A.M.A., 133, 1258 ; 1947 3) Edward, E.A. : The Treatment of Varicose Veins : S.G.O., 59, 916 ; 1934 4) Eisemsn, B. : An Operative Technique for the Construction of Venous Valves : S.G.O., 67,

731 ; 1953 5) Ensenat, L.A. : The Postphlebitic Syndrome: Discussion of Surgical Treatment : Angiology, 4, 217 ; 1953 6) Mc Lachlin, J. : Some Basic Observations on Venous Thrombosis and Pulmonary Embolism : S. G. O., 93, 1 ; 1951 6) Paterson, J.C. : Precipitating Factors in Venous Thrombosis : S.G.O., 98, 96 ; 1954

(和文抄録)

## 下腿静脈瘤の治療法としての静脈弁造設術

京都大学医学部外科学教室 (指導 青柳安誠教授)

原田直彦・井上尙史・佃 光雄・小亀清孝

[原稿受付：昭和30年11月4日]

静脈炎の後遺症状として、下腿静脈瘤が発生する。この治療法は古くから多くの方法が発表されているが、多くは対症的に、当該血管の血流をとめて、静脈瘤を消失せしめようと言う方向に向っている。所が最近 Eiseman (1953) は、もつと積極的に当該静脈管内に存在して機能を失つて了つた静脈弁の代りに、新しく静脈弁をつくり、それによつて下腿静脈瘤を根治しよ

うと言う実験を報告している。

私達は、この Eiseman の原法に則り、2例の下腿静脈瘤の患者に、重疊法によつて静脈弁を造設した。弁を造設した後、一時的栓塞を来したが、まもなく再開通し、静脈弁としての機能を充分果し満足すべき結果を得た。この重疊法による弁造設術は、他の方面にも利用し得る方法であると信じられる。