

Title	OSTEOPLASTIC LAMINECTOMY FOR LUMBAR DISC PROTRUSION
Author(s)	Kondo, Eishi; Yamada, Kengo; Kirita, Yoshito; Fujita, Yoshitaka; Ayani, Tomiya; Ando, Keizo; Fujita, Hidekazu
Citation	日本外科宝函 (1954), 23(4): 287-294
Issue Date	1954-07-01
URL	http://hdl.handle.net/2433/206110
Right	
Type	Departmental Bulletin Paper
Textversion	publisher

日本外科寶函 第23卷 第4号

ARCHIV FÜR JAPANISCHE CHIRURGIE

XXIII. BAND, 4. HEFT, 1. JULI. 1954.

総 説

OSTEOPLASTIC LAMINECTOMY FOR LUMBAR DISC PROTRUSION

by

EISHI KONDO

&

KENGO YAMADA

YOSHITO KIRITA

YOSHITAKA FUJITA

TOMIYA AYANI

KEIZO ANDO

HIDEKAZU FUJITA

From the Orthopedic Division, Kyoto University Medical School.

Introduction

Judging from the results in our clinic (Tab. 1) and from reports by European and American authorities,^{2,3,4)} (Tab. 2) the results of the surgical treatment for lumbar disc protrusion are unquestiona-

Tab. 1 End-result study in our clinic
(280 cases of lumbar disc protrusion)

Cured	Improved	Unimproved	Died
218	41	16	5
78.0%	14.6%	5.6%	1.8%

Notes :

Cured : Freedom from low-back and sciatic pain and no restriction of activities.

Improved : Moderate reduction in severity of pain and in capacity for work.

Unimproved : Presence or augmentation of pre-operative complaints.

Died : Death for any reason.

Tab. 2 End-result study in other clinics

A) DANDY : (483 cases)

Cured	Improved	Unimproved
299	102	82
61.9%	21.1%	17.0%

B) O'CONNELL : 443 cases)

Capacity for work		
Full	Reduced	Incapacitated
411	29	3
92.8%	6.5%	0.7%

C) LOVE :

Capacity for work	
Full	Reduced
64.4%	35.6%

bly good, but it is widely known that many improvements in the form of operation⁵⁾ (Tab. 4) have been tried to relieve uncomfortable back symptoms¹⁾ (Tab. 3) which are often post-operative complications.

In order to obtain the maximal operative field for exploration with the minimal invasion and without disturbing the normal anatomical structures of local vertebrae

Tab. 3 Lumbar symptoms after operation

-
1. Inability to keep half-bending posture longer than half an hour.
 2. Inability to keep the same posture over one hour.
 3. Dullness and fatigue in the lumbar region after a few kilo-meter's walk.
 4. Fatigue in the lumbar region soon after work.
 5. Inability to lift up a heavy load.
 6. Sensitiveness in the lumbar region to vibration when riding in a vehicle.
 7. Difficulty in lying prone.
 8. Sensitiveness to cold.
 9. Difficulty in running fast or jumping high.
 10. Difficulty in bowing.
-

Tab. 4 Several methods of laminectomy

- A) With least degree of invasion
 - Hemilaminectomy (LOVE)
 - Unilateral laminectomy (SPURING)
 - Partial laminectomy (O'CONNELL)
 - Hemilaminectomy with facetectomy (KONDO)
- B) With fusion
 - Modification of Albee's spinal fixation (LOVE)
 - Bone-chip fusion (BRIGGS)
 - Clothes-pin method (BOSWARTH)
 - Hibbs's method (HIBBS)
- C) With osteoplastic process
 - Osteoplastic facetolaminectomy (KONDO)
 - Osteoplastic hemilaminectomy with facetectomy (KONDO)
 - Osteoplastic partial laminectomy with facetectomy (KONDO)

after the operation, we tried three forms of osteoplastic laminectomy: osteoplastic facetolaminectomy,⁵⁾ osteoplastic hemilaminectomy⁶⁾ with facetectomy, and osteoplastic partial laminectomy⁷⁾ with facetectomy.

Here we will introduce the history of their development, discussing their results and hope to have our methods criticized by other orthopedic surgeons.

Osteoplastic Facetolaminectomy (KONDO)

The main point of this method is to perform laminectomy osteoplastically in order to keep the local bones in more physiological relationship after operation.

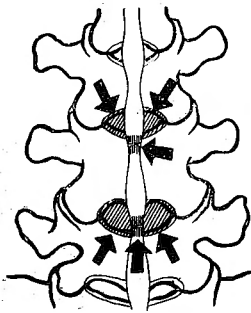
For this, we remove the spinal neural arch as a block of bones, and, after enucleation of the protruded disc is completed, replace it in its former position.

The principles of this method are as follows⁵⁾: (Fig. 1)

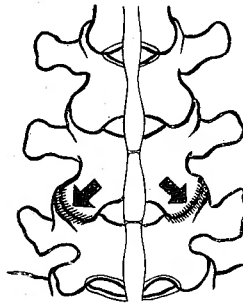
- 1) Incise the skin of the low back for about 10cm. along the spinous processes.
- 2) Strip off the muscles completely from their attachments along both sides of the processes, and the surfaces of the arches.

Fig. 1 The main points of osteoplastic facetectomy

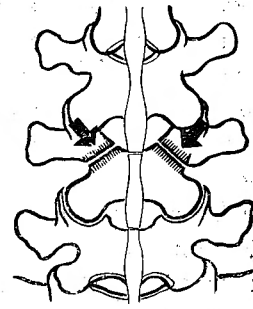
A. Excise the ligamenta flava.



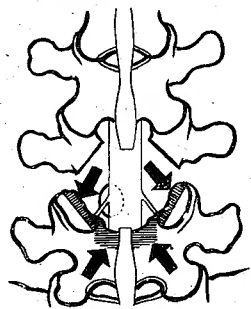
B. Open the intervertebral articular capsulés



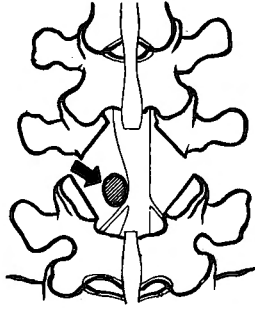
C. Excise the upper articular processes



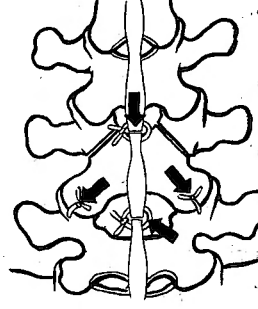
D. Excise the inner part of the intervertebral facets and the upper edge of the next lamina



E. Enucleate the protruded cartilage



F. Replace the removed lamina



3) Excise the ligamenta flava, situated at the upper and lower parts of the corresponding laminae, and cut down the supraspinal and interspinal ligaments. (A)

4) Expose the intervertebral articular facets by opening their capsules. (B)

5) Inject 0.5% procain solution of light specific gravity directly into the subarachnoid space.

6) Excise the spinal lamina with chisel directly below the upper articular processes. (C)

7) Remove the excised lamina, holding it with bone-forceps.

8) Excise the inner part of the intervertebral articular facets and the upper edge of the next lamina in order to spread the visual field and to remove the remaining ligamenta flava (D)

9) Enucleate the protruded cartilage completely with annulus fibrosus and nucleus pulposus. (E)

10) Replace the previously removed lamina to its normal position and fasten it to the intervertebral joints and to the supraspinal ligaments. (F)

11) Close the operative wound.

12) Remove the stitches 7 days after the operation, and 2 weeks later, stretch the sciatic nerves and then fix the trunk in a plaster cast. After 6 weeks, a corset

is employed if necessary.

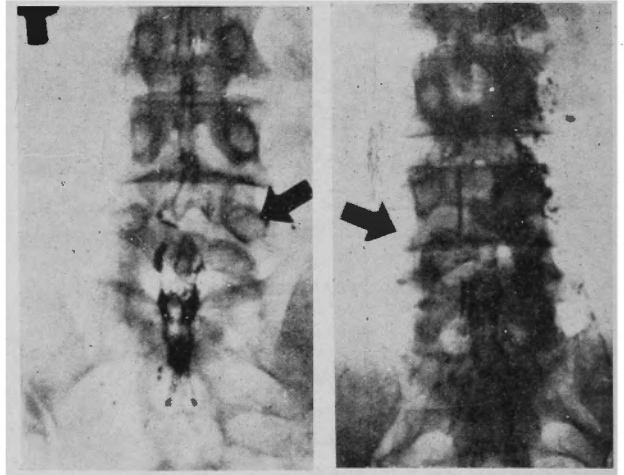
More than 150 cases of osteoplastic facetolaminectomy have been performed by this method since 1948 and more excellent results than before were obtained. However, regrettably, we found the following faults.⁹⁾

1) Consolidation of the excised laminae is delayed much more than expected, and occasionally "Artificial spondylolysis" is seen in roentgenological findings. (Fig. 2)

2) The replaced laminae are often dislocated, as they are fixed only on both sides of the intervertebral articular facets and its consolidation delayed. (Fig. 3)

Then we progressed to the next stage and employed a new type of modified method called "Osteoplastic hemilaminectomy with facetectomy", so as to avoid these two faults.

Fig. 2 Artificial spondylolysis **Fig. 3** Dislocation of replaced lamina



Osteoplastic hemilaminectomy with facetectomy (KONDO)

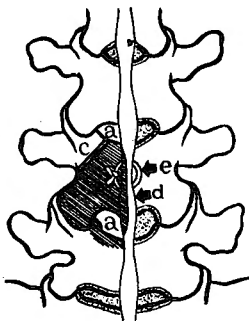
The principal object of this modified method is not only to keep the physiological connection of the local spinal bones, as we hoped to do by the former method, but also obtain comparatively maximal visual fields with minimal invasion and complete consolidation of replaced laminae.

The different points of this from the former are as follows⁹⁾: (Fig. 4)

Fig. 4 The different points of two types of laminectomy

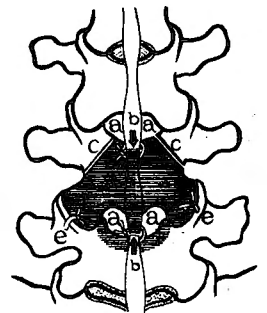
Osteoplastic hemilaminectomy with facetectomy

- a) Excise the ligg. flava only on one side
- b) Supra- and interspinal ligaments are not sected
- c) Excise the upper articular processes on only one side
- d) Half of the spinous processes remain untouched
- e) The replaced lamina is fixed on the saggital plane of the spinous processes



Osteoplastic facetolaminectomy

- a) Excise the ligg. flava on both sides
- b) Supra- and interspinal ligaments are sected
- c) Excise [the upper articular processes on both sides
- d) The spinous processes are not remain untouched
- e) The replaced lamina is fixed on the intervertebral joint



- 1) Excision of ligamenta flava is enough only on one side.
- 2) Section of the supraspinal and interspinal ligaments is not required.

- 3) Excision of the upper articular processes is also sufficient on only one side.
- 4) After sagittal section of the spinous processes, half of them remained untouched.
- 5) The replaced lamina is fixed not on the intervertebral joint, but on the excised sagittal plane of the spinous processes which has a very spongy substance.

Compared with the former technic, this has many excellent points and brings much better results :

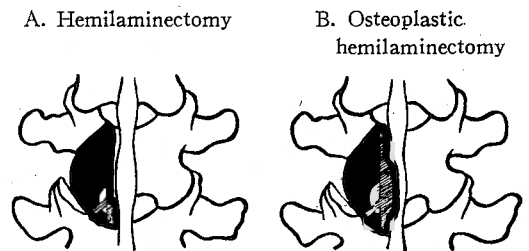
1) Capacity of weight bearing after the operation seems to be sufficiently strong, because the column of spinous processes on the other side is completely retained.

2) Compared with traditional hemilaminectomy, the visual field is somewhat wider, because the bases of the spinous processes are exposed by sagittal cutting. (Fig. 5)

3) Bony consolidation is better, because the replaced arch is fixed on the spongy wider plane of the excised spinous processes. (Fig. 6)

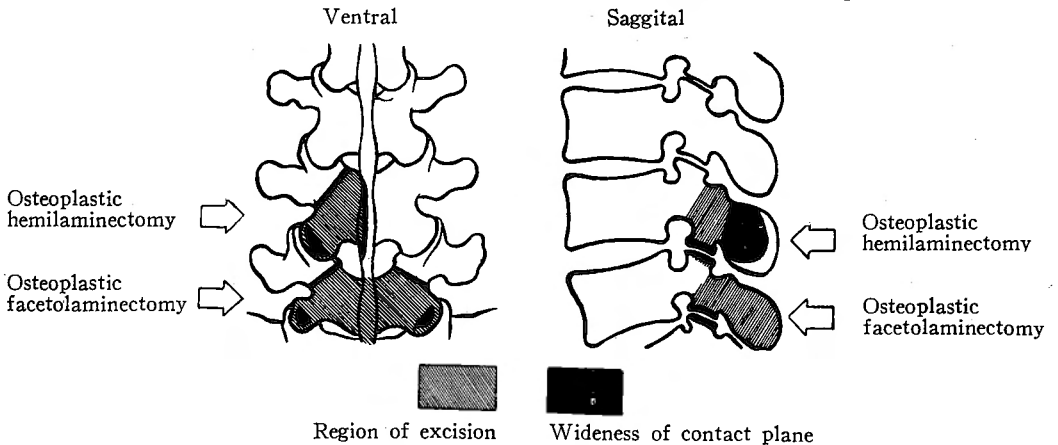
4) Mobility of the spine is not damaged, as the invasion is small.

Fig. 5 Visua' field



The visual field of A is not only wider than that of B but also the nerve root and the protruded disc are much more exposed in the case of B.

Fig. 6 The region of excision and the wideness of contact plane



- 5) No dislocation of the replaced arch is ever seen.
- 6) The period of fixation with plaster cast can be shortened about 3 weeks.

Since 1952, we have obtained further excellent results by this method in the point of bony union which had been the most difficult problem of osteoplastic laminectomy.

But we did not content ourselves with this success and tried another reformation, osteoplastic partial laminectomy, in order to decrease the surgical invasion, to facilitate bony union of replaced lamina and to keep spinal mobility as normal as possible.

Osteoplastic partial laminectomy with facetectomy(KONDO)

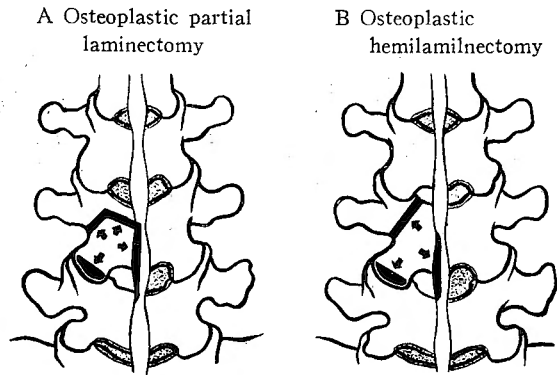
The aim of this modification is to make the range of laminectomy as small as possible, to make a better consolidation of replaced lamina and to keep the mobility of the spine in even better condition.”

For this purpose, we removed only the lower half of the lamina, necessary to expose the root of lumbar nerve and to enucleate the herniation, and avoided cutting the upper part of the the ligamentum flavum of the corresponding lamina.

The superiorities of this technic are as follows :

- 1) The visual field is wide enough even with this method.
- 2) Avoiding invasion of the upper part of the ligamentum flavum brings better results of spinal capacity and shortens the time of operation.
- 3) The wide area of contact of the excised surfaces with each other in the

Fig. 7 The wideness of contact of the excised surfaces



replacement of removed lamina helps its bony consolidation and makes its fixation complete. (Fig. 7)

To perform this method, we invented a special wound-hook to abridge the unnecessary invasion. (Fig. 8)

By using this hook, we do not need to separate the opposite side of the spinal muscles and can prevent the patient from having uncomfortable back symptoms.

We have tried this new technic on more than 40 cases since 1953 and evaluated its end-results in 17 cases whose post-operative course has been more than 2 months.

Among them, 9 cases were completely cured, 4 were improved. Premature bony unions were also noticed roentgenologically. (Fig. 9)

Fig. 8 Our new wound-hook

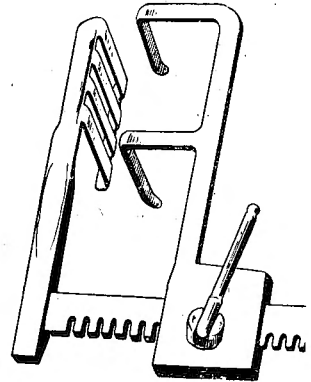
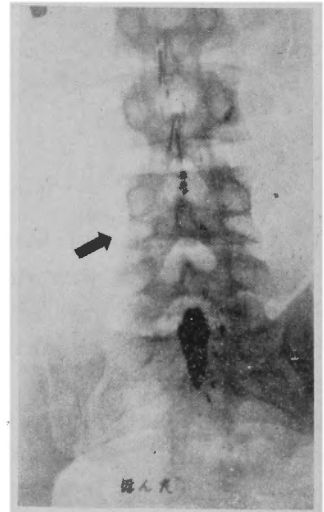


Fig. 9 Premature bony union (40 days after operation)



Summary

Now we here discuss the superiority or inferiority of various types of laminectomy from 2 points of view :¹⁾²⁾

- a) The sciatic syndrome (nerve roots symptoms)
- b) The low back symptoms (lumbar symptoms)

The healing rate of the sciatic syndrome in lumbar disc protrusion is shown in Tab. 5, in which the worst end-results were obtained in the partial laminectomy

Tab. 5 Healing rate of sciatic syndrome

	Cured	Improved	Unimproved	Died
Bilateral laminectomy	51 (78.5%)	9 (13.8%)	2 (3.1%)	3 (4.6%)
Hemilaminectomy	38 (74.5%)	8 (15.7%)	4 (7.8%)	1 (2.0%)
Partial laminectomy	18 (60.0%)	10 (33.3%)	2 (6.7%)	0
Osteoplastic facetolaminectomy	72 (83.7%)	6 (7.0%)	8 (9.3%)	0
Osteoplastic hemilaminectomy	23 (88.5%)	3 (11.5%)	0	0
Osteoplastic partial laminectomy	17 (73.9%)	6 (26.1%)	0	0

performed with minimal visual field.

Therefore, for the elimination of root symptoms alone, a technic assuring wider vision is desirable. Our osteoplastic facetolaminectomy is rational from this point of view.

But the other 2 types of osteoplastic laminectomy are also not inferior to it.

The rate of remaining lumbar symptoms is shown in Tab. 6, but by this data

Tab. 6 The rate of remaining lumbar symptoms

	Cases remaining lumbar symptoms			Total	
	in cured cases	in improved cases	in unimproved cases	numbers of cases	%
Bilateral laminectomy	27/51	8/9	1/2	36/62	58.0
Hemilaminectomy	20/38	6/8	4/4	30/50	60.0
Partial laminectomy	3/18	8/10	2/2	13/30	43.3
Osteoplastic facetolaminectomy	32/72	6/6	5/8	43/86	50.0
Osteoplastic hemilaminectomy	15/23	3/3	0	18/26	69.3
Osteoplastic partial laminectomy	0	6/6	0	6/23	26.1

it is difficult to decide which method is the best. The post-operative low-back symptoms do not only depend upon the magnitude of invasion, but also upon the damage to soft tissue and the narrowing of the intervertebral disc. Our osteoplastic partial laminectomy performed with its special wound-hook seems to be the most rational procedure.

In the future, after a certain period has passed, more obvious differences between the three types of osteoplastic laminectomy will be discovered.

Conclusion

We want to introduce in this report three types of osteoplastic laminectomy tried in our clinic since 1948 and to discuss their superiority in order to explain the last one's rationality.

Further trial by other orthopedic surgeons is desirable.

References

- 1) Yamada, K. & Ito, T., Pathogenesis and Therapy of so-called Radicular Sciatic Pain. Arch. für Jap. Chir., **23**, 1, 1954
- 2) Lenhard, End-result Study of the Intervertebral Disc. J. Bone & Joint Surg., **29**, 2, 1947
- 3) O'Connell, Protrusion of the Lumbar Intervertebral Disc, A Clinical Review based on 500 Cases treated by Excision of the Protrusion. J. Bone & Joint Surg., **33-B**, 1, 1951
- 4) Love, The Disc in Low-back Pain with or without Sciatica. J. Bone & Joint Surg., **29**, 2, 1947
- 5) Kondo, E. & Ando, K., Reformation of Operative Method for Lumbar Disc Protrusion. Shujutsu, **1**, 6, 1949
- 6) Kondo, E. & Fujita, Y., Ayani, T., Osteoplastic Hemilaminectomy with Facetectomy. 70th Surg. Assoc. of Kinki District. 1952
- 7) Kondo, E. & Kirita, Y., Reformation of Osteoplastic Hemilaminectomy with Facetectomy (Osteoplastic Partial Laminectomy with Facetectomy). 27th Orthopedic Assoc. of Jap., 1954
- 8) Ayani, T., End-result Study of Osteoplastic Facetolaminectomy for Lumbar Disc Protrusion. Rinsho-Geka, **7**, 7, 1952
- 9) Fujita, H., Clinical and Experimental Studies on Osteoplastic Laminectomy. Arch. für Jap. Chir., **22**, 6, 1953