

Title	CONSIDERATIONS ON SENSORY AND MOTOR DISTURBANCES IN NEURAL LEPROSY
Author(s)	Taketomo, Takao; Ishii, Shozo; Araki, Chisato
Citation	日本外科宝函 (1954), 23(3): 237-245
Issue Date	1954-05-01
URL	http://hdl.handle.net/2433/206088
Right	
Type	Departmental Bulletin Paper
Textversion	publisher

 臨 床

 CONSIDERATIONS ON SENSORY AND MOTOR DISTURBANCES
 IN NEURAL LEPROSY

by

TAKAO TAKETOMO, SHOZO ISHII, & CHISATO ARAKI

 From the 1st Surgical Division, Kyoto University Medical School
 (Director : Prof. Dr. CHISATO ARAKI)

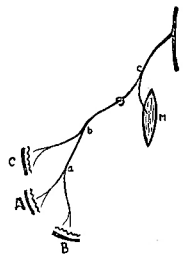
INTRODUCTION

Since several years ago we have had opportunities to investigate patients of leprosy received in the Colony, KIKUCHI-KEIFUEN, KUMAMOTO Prefecture. We hoped to know how sensory and motor disturbances in leprosy differed from those in peripheral nerve injuries with which we have had many years' experiences.

For the reason of neurological interest we studied only neural leprosy, because the neural changes are the most intense in this group, and intended to examine by clinical means where the sensory and motor paralyses initiated and how they spread thereafter.

According to the view supported by most leprologists, pathological changes begin in the skin, where a macula appears at first associated anesthesia as a result of the affection of sensory nerve endings. Then leprosy process ascends along nerve fibers from those nerve endings, and when it reaches a point of ramification, the change involves also the fibers of a joining nerve branch, thus causing sensory paralysis in the territory of that branch. Suppose that anesthesia arises in the area A of the skin in Fig. I, then the illness ascends from A to point a, where another branch is also involved, so that the area B of the skin is anesthetized. Further, on reaching point b the affection results in anesthesia of the skin C and at the point c, which is reached after penetrating through the superficial fascia, paralysis of muscle M ensues. This has been supposed to be the way in which the motor and sensory disturbances gradually spread in leprosy. We should like to call it the ascendance theory. Another possible mode of spread may be the hematogenic metastasis of leprosy bacilli, by which a focus of acute inflammation develops somewhere in the trunk of a peripheral nerve, causing the motor and sensory paralyses in the distribution areas of the trunk. It is also possible that the manifestations of neural leprosy are due to the combination of these two mechanisms.

Fig. 1



Though the ascendance theory seems to have been generally accepted, it seems to us questionable whether this theory is true or not. For the evaluation of this theory, it would be necessary to follow up the changes of neurological symptoms in individual patients in the long course of time. But we had not sufficient time to do it. Therefore, by making the thorough examination of sensory and motor

disturbances in as many cases as possible on one or two occasions, we presumed the probable mechanism of the spreading of leprous changes.

MATERIALS AND METHODS

We examined at first the extent of the sensory impairment in patients of neural leprosy. Patients examined were totally 54. All of these patients were fairly intelligent, so that their answers at the time of sensory stimulation would be reliable. In most patients more than one area of anesthesia were found, thus the number of the areas examined, e. g. in the face and the limbs, being 83. The examination of sensations was done by usual clinical methods—the prickle with an injection needle for the pain sense, the KAWAHARA'S tactometer for the sense of touch, and a specially hand-made apparatus with an extremely narrow surface of contact for the temperature sense.

We could see that the results of the examination were quite reliable even though by means of these simple apparatus, if the use was appropriately planned. For instance, the stimulation was applied successively from the anesthetic area toward the intact at the examination of pain and temperature senses, while in the reverse way at the examination of the sense of touch. Then, if an area was repeatedly examined, the results were always the same.

The limiting lines of anesthesia thus examined were traced on a chart with figures representing the anatomical distributions of peripheral nerves, thus making the comparison easier. To be sure, individual differences in the distributions of peripheral nerves are found to a considerable degree, and the extent of anesthesia becomes often reduced in the course of time in consequence of the functional compensation of adjacent intact nerves, without any anatomical regeneration. These facts should always be kept in mind in such studies as ours.

FLECK

The definite sensory disturbance is usually proved within the limit of every solitary fleck which is relatively fresh and distinct. The fleck is irregular in shape and does not coincide with the distributions of skin nerves at all. In most cases, the loss of sensation within a fleck is sharply demarcated from the surroundings of the fleck. However, in not a few cases we found a shadow-like hypesthetic zone, extending from a fleck for a distance toward the periphery of the skin nerves innervating the fleck area (Fig. 2). From this fact, it may be surmised that the pathological changes in a fleck involve not only nerve endings, but also a little larger nerve branchlets in the deeper layer of the skin.

There have been various opinions about the mechanisms of the development of a fleck. For example, a fleck was supposed to be secondary to a nerve lesion. But, we cannot agree to such an opinion, because any nerve lesions other than leprosy do not bring about a fleck and there are at times flecks without sensory disturbances. No doubt, a fleck should be regarded as a primary affection of the skin.

Even the complete anesthesia in a fleck may recover spontaneously after a long period of time. The recovery seems to occur out of proportion to the size of a fleck. Accordingly, it should be assumed that the nerves, once degenerated due to

leprous affection, can regenerate to a more or less extent.

Fig. 2

Fig. 3

Fig. 4

Fig. 5

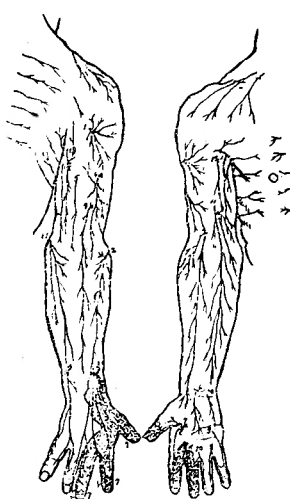
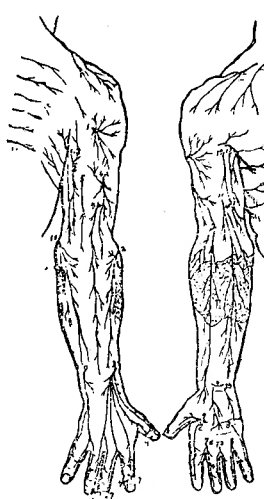
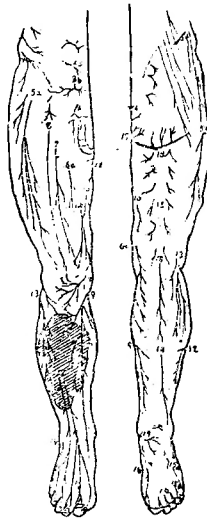
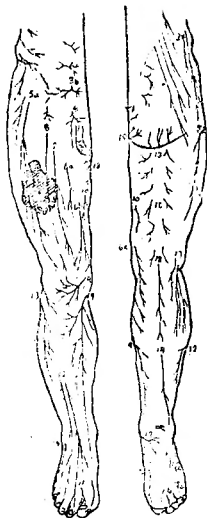
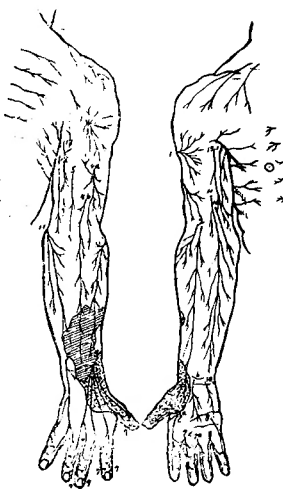
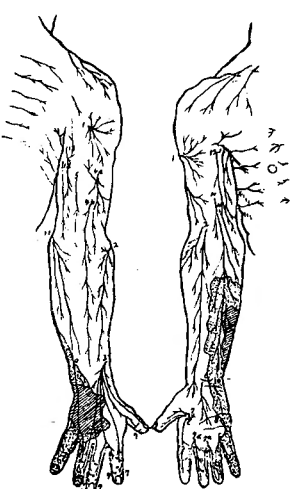
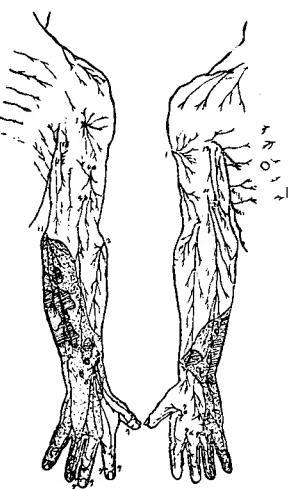
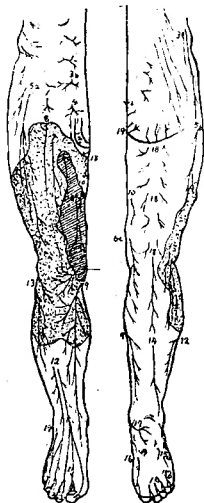


Fig. 6

Fig. 7

Fig. 8

Fig. 9



Dotted areas : anesthetic.
Hatched areas : flecks.

Explanation of numerals in Figures (lower extremity).

- | | | | | | |
|-----------|-------------------------------------|-------------------------|---------------------------------------|-----------------------------|-------------------|
| 1. | N. lumboinguinalis | } ...N. genitofemoralis | 11. | N. fibularis profundus | } ...N. fibularis |
| 2. | genital branch | | 12. | N. fibularis superficialis | |
| 3(a,b). | N. iliohypogastricus | } ...N. femoralis | 13. | N. cutaneus surae lateralis | } ...N. tibialis |
| 4. | N. ilioinguinalis | | 14. | N. suralis | |
| 5(a,b). | N. cutaneus femoris lateralis | } ...N. femoralis | 15(a,b). | N. plantaris lateralis | } ...N. tibialis |
| 6(a,b,c). | internal cutaneous nerve | | 16. | N. plantaris medialis | |
| 7,8. | middle cutaneous nerve | 17. | Rr. calcanei mediales | } ...N. tibialis | |
| 9. | N. saphenus | 18. | N. cutaneus femoris posterior | | |
| 10. | R. superficialis ...N. obturatorius | 19. | N. perforans ligamenti sacrotuberosum | | |

Explanation of numerals in Figures (upper extremity).	
1. N. cutaneus brachii lateralis...N. axillaris	8. R. superficialis
2. N. cutaneus antebrachii lateralis... ...N. musculocutaneus	9. R. dorsalis manus } N. ulnaris
3. R. superficialis	10. R. cutaneus palmaris }
4(a,b). N. cutaneus antebrachii dorsalis }N. radialis	11. N. cutaneus antebrachii medialis
5. N. cutaneus brachii posterior }	12. N. cutaneus brachii medialis
6. Ramus palmaris } N. medianus	13. N. intercostobrachialis
7. (a,b,c,d,e).....	

SENSORY DISTURBANCES IN THE SKIN AREAS OTHER THAN FLECKS

In many cases, the definite sensory disturbances in a wide area of the skin are found without any recognizable fleck. The extent of this area is not usually similar to that following a lesion of a peripheral nerve trunk. Even if it appears so at a glance, it is not the case on exact examination. There are beyond expectation seldom the cases, in which the sensory disturbances suggest a lesion in the trunk of ulnar, median or fibular nerve etc. or their combined affections. Then, are the sensory disturbances in leprosy not at all related to the distribution of a peripheral nerve? That is the case as will be mentioned in the following.

According to our study, the sensory disturbances in areas other than flecks can be classified into the following 2 types.

The first type :

To this type belong the sensory disturbances of irregular extent, independent on the distribution of skin nerves, just as in the case of a fleck. This type of spreading of anesthesia is usually found in the cases where an area of the sensory deficit is small sized (Figs. 3, 4, 5), or it extends outwards beyond the limit of a fleck (Figs. 6, 7, 8, 9).

The pathological changes of nerves in this type seem, as in the case of a fleck, to remain largely within the skin, spreading diffusely in the superficial layer of the skin similarly to the spreading of erysipelas. Therefore it may be called "neuritis terminalis".

The second type :

As the result of the precise examination of the borderline of an anesthesia — especially of the peripheral borderline of an extensive anesthesia in the limbs, we have come to the following postulation. Each branchlet of peripheral nerves, which penetrates the superficial fascia and then ramifies in the subcutaneous tissue, should be regarded as a pathophysiological unit of sensory paralysis in leprosy, i. e. one or more skin areas innervated by one or more unit nerve branchlets become anesthetic or remain intact. The same seems to be true of the proximal borderline of anesthesia, but, since flecks or residues of flecks often constitute this proximal line, the upper limit of anesthesia has actually in many cases no relation to the skin nerve distribution.

Even the most extensive anesthesia in leprosy appears to have developed in most cases by a confluence of many units of paralysed skin nerves (Figs. 10, 11, 12, 13,

14, 15, 16). In this connection it is interesting that in some cases an island of intact skin area corresponding to the distribution of a unit nerve branchlet is left amidst the lake of anesthesia (Figs. 17, 18). The spreading of this type occurring in the subcutaneous tissue may be comparable to that of "erysipelas phlegmonosum".

We believe that the sensory impairment in neural leprosy spreads in the two types mentioned above. The thickening, tenderness and sclerosis of major nerve trunks, which are usually found in leprosy, are unlikely to be the cause of anesthesia in most cases. Thus, the ascendance theory is hardly applicable to larger nerve trunks inside the superficial fascia. In other words, the sensory disturbances in most cases of leprosy seem to be caused by lesions in the cutaneous and subcutane-

Fig. 10

Fig. 11

Fig. 12

Fig. 13

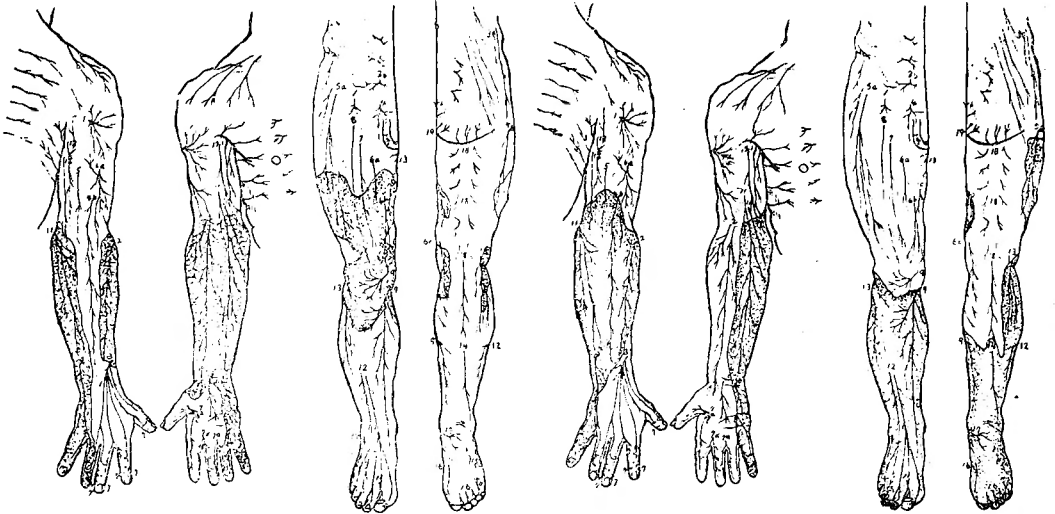


Fig. 14

Fig. 15

Fig. 16

Fig. 17

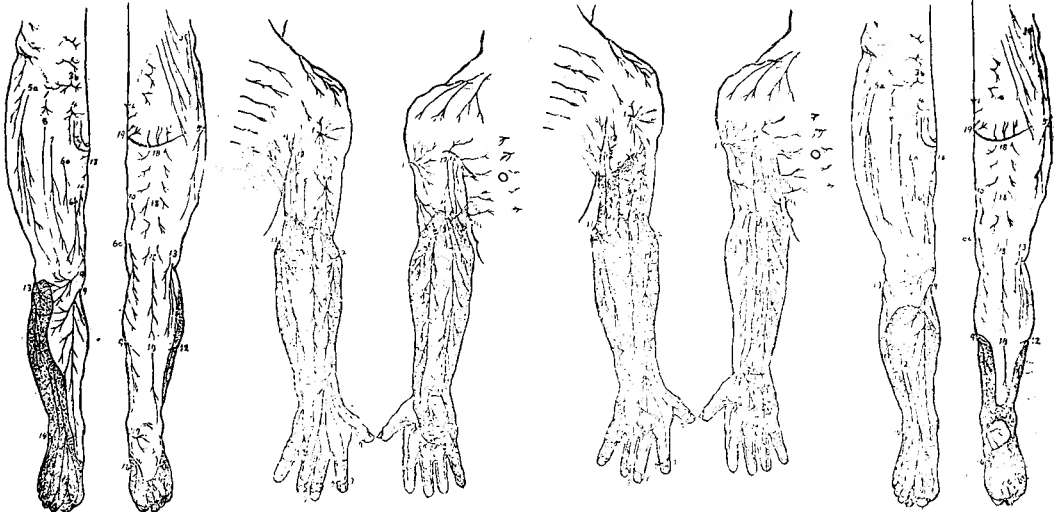


Fig. 18

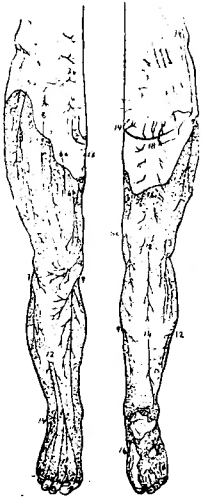


Fig. 19

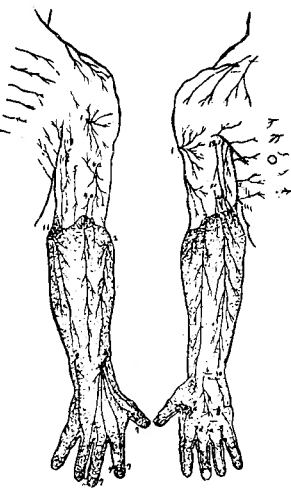


Fig. 20

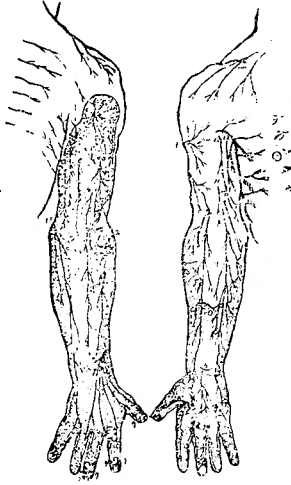

Fig. 21

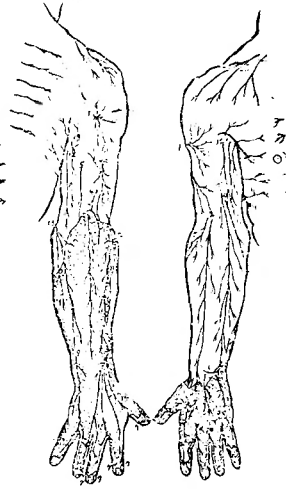


Fig. 22

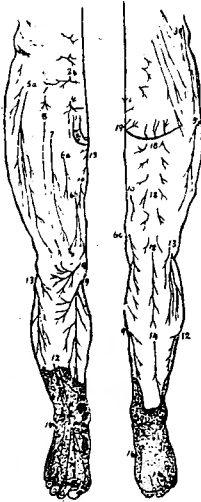


Fig. 23

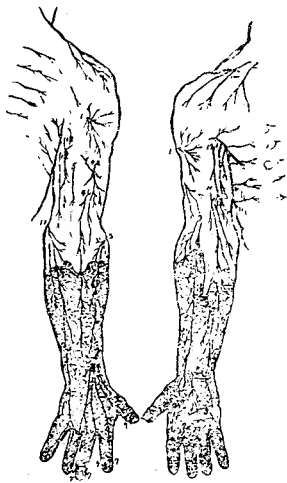
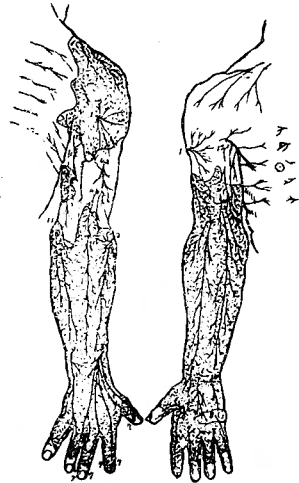


Fig. 24



ous layers.

But, in the sensory disturbances of the second type we find sometimes small intact areas, especially in the distal part of extremities, which are irregular in extent and hardly correspond to any unit nerve branchlets (Fig. 19-24). The reason may be that nerve fibers reaching the distal end of extremities are supposed to recover more easily, because they are centrally placed within a subcutaneous nerve branch, tending therefore to be affected to a lesser degree; for the same reason they may remain free from paralysis until the later stage. However there are cases, though rarely, in which the sensory disturbances are caused by a lesion in a major nerve trunk. For instance, typical ulnar or fibular paralysis is found in

such a case when the paralysis has occurred suddenly in a night. In a lesion of a major nerve trunk, not only sensory but also motor paralysis takes place in the regular areas of distribution of the nerve. The degree of sensory deficit usually increases towards the distal end of the limb. The lesion may probably be the result of the hematogenic metastasis of lepra-bacilli rather than of the continuous ascending of the lesion from the periphery.

The severity of the impairment of various modalities of sensations, e. g. pain, temperature, touch and deep sensation, is not to be compared with each other. But, there appears to be some dissociation among them, if the comparison is made using a stimulus which is too intense for the intact skin, but makes no response in the affected skin. However the borderlines of the anesthetic areas of each modality run almost parallel, though it is impossible to say, which modality is more widely impaired. For instance, though many patients of neural leprosy have some experiences of burns as a result of the impairment of the thermal sensation, there are patients on the other hand, in whom despite severe impairment of touch and pain in extremities, the sense of temperature alone is well reserved, and so no burns have ever been experienced.

We could not precisely examine the deep sensation in the present study. But, in some cases, while the cutaneous sensation is intensely impaired, the deep sensation seems to be normal or even hyperesthetic. Foerster stated that deep sensibility for pain may be exaggerated in the area where the cutaneous nerves have been cut, and so the skin is anesthetic. But it is our impression that by the strong digital compression against the bone at the site of cutaneous anesthesia, pressure is felt at first and far later pain. And in those parts where both the cutaneous sensation and the muscular motility are lost, especially at the distal end of extremities, the deep sensibility is also markedly diminished.

PARALYSIS AND ATROPHY OF MUSCLES

In neural leprosy, motility is usually less severely impaired than sensibility. Even patients with anesthesia covering almost the whole skin of both legs are able to walk without support. Such a fact is never experienced in usual lesions of peripheral nerves. Dissociation of sensory from motor paralysis is characteristic of leprosy. However, motor disturbances are also quite common. Small muscles in the distal part of the limbs and in the face are predilected. On close observation the motor disturbances in leprosy are somewhat different from those in usual ulnar, median, fibular or other nerve paralysis. For example, in case of typical ulnar nerve palsy, the contracture takes the form of "claw-hand", in which the hyperextension of proximal phalanges of IV and V fingers is usually seen, but that of other fingers is not, while in neural leprosy all fingers tend to contract to the same and high degree. Moreover, leprous contractures occur not only successively in the order from the little finger to the thumb, but also simultaneously in all fingers. These facts indicate that both ulnar and median nerves should be paralysed in this case. If the two nerves are paralysed at the appropriate levels of major trunks,

sensory disturbances corresponding to their distribution should exist at the same time. But it is usually not the case. For instance, in a case shown in Fig. 10, the high-graded claw-hand-like contracture of all fingers and atrophy of all hand muscles are seen without any sensory disturbances in the distribution of median nerve. Such cases are rather common.

The same is true of muscles in the face and the legs. In the face, muscles, such as *M. frontalis*, *Mm. orbicularis oculi et oris* etc. are usually paralysed with anesthesia of the skin overlying these muscles, while in some cases paralysis of these muscles is not associated with any corresponding sensory disturbances. Sometimes the whole muscles on one side of the face (hemifacial paralysis) and sometimes an isolated group of small muscles are paralysed. If the paralysis should ascend from the skin along a sensory nerve (trigeminal), it does not meet anywhere a motor nerve (facial). Therefore, it is evident that the ascendance theory cannot interpret the motor paralysis in the face.

In considering these facts, the muscular paralysis in neural leprosy seems to be the paralysis of an unit or a group of units of muscles. That is the same as in the second type of the spreading of sensory disturbances.

From the fact that the skin area overlying the paralysed muscles is frequently anesthetized, it would be suspected that muscle paralysis would occur by the direct or continuous spreading of the leprosy inflammation from the skin to the muscles. But there are some cases in which the anesthetized skin areas are apart from the paralyzed muscles. Also in the case of Fig. 10, the thumb-ball has fallen into severe atrophy, without any sensory disturbances of the skin in that area. Thus the precise mechanism of the development of muscular paralysis is unknown, although hematogenous metastasis may be possible.

CONCLUSION

We have presented many evidences showing that the ascendance theory is not valid for the explanation of the spreading of the sensory and motor disturbances in neural leprosy. The sensory deficit occurs usually from nerve lesions in the skin or in the subcutaneous layer, only exceptionally from lesions in major nerve trunks. The dermatogenic anesthesia spreads quite irregularly, while the desmogenic anesthesia spreads with some regularity in such a way that an unit or a group of units of nerve branchlets in the subcutaneous layer are involved and paralysed, thus the borderline of anesthesia roughly corresponding to the distribution areas of the nerve branchlets.

In the latter type, the whole extent of anesthesia would be equal to the sum of the distributions of these unit nerve branchlets involved, and the lesions responsible for sensory paralysis should not extend deeper than the superficial fascia. The reason for this is as follows. It is well known that the thickening, tenderness and sclerosis etc. of major nerve trunks, e. g. *N. ulnaris*, *N. medianus*, *N. auricularis magnus* and *N. supraorbitalis* etc., are usually found in neural leprosy. However such nerves are often functionally normal despite distinct organic changes. Hence,

it seems that the morphological leprosy changes per se would not be the cause of the sensory defect in the absence of additional factors. One of the most important co-factors may be the self-strangulation of these swollen nerves at the slit of superficial fascia, through which the nerves should pass. Of course, this assumption must be confirmed histologically in the future.

Similar paralysis has been informed in diseases other than leprosy; for example in Bernhardt's sensory paralysis, which occurs in the convalescence of typhoid fever etc., the skin area in the distribution of N. cutaneus femoris lateralis becomes anesthetic. Also is known the sensory disturbance in the distribution of the lower branch of N. cutaneus antebrachii dorsalis (N. radialis). But in these conditions the illness is not progressive as in the case of neural leprosy.

As regards the muscular paralysis, an unit or a group of units of muscles suffer paralysis and atrophy, without any correlation to the sensory disturbances. The motor paralysis is usually slighter in degree than the sensory disturbance.

Against our opinion, that in neural leprosy both anesthesia and motor paralysis should be caused by lesions in the most peripheral branches of nerves, the following objection will be made. "It would not be impossible to consider that the sensory and motor disturbances are the result of lesions in major nerve trunks, if one assumes 1) that motor fibers in nerve trunks may stand more strongly against leprosy affection than sensory fibers, and consequently the former may be more difficult to paralyse, or 2) that only one or more nerve fascicles going to some skin nerve branches are isolatedly anesthetized within a nerve trunk." However, it is doubtful that motor fibers are more resistible against leprosy process than sensory fibers, because in some cases of leprosy motor paralysis makes a predominant manifestation without any sensory impairment. There is another powerful evidence, by which the objection can be discarded, that the anesthesia in the limbs or the face usually occupies one continuous skin area, extending independently of the distributions of major nerve trunks. It would be quite improbable to consider that such an anesthesia should be caused by multiple partial lesions in two or more major nerve trunks.

This study has been aided by a grant from the Educational Department Science Research Foundation.

(和文抄録)

神経癩に於ける知覚運動麻痺

熊本菊池患癩園に収容中の神経癩患者54名について、知覚麻痺の綿密なる検査を行うと共に、運動麻痺並びに筋萎縮の状態を観察し、私共の末梢神経外傷に関する経験を基礎として、これ等の検査成績を検討した結果次の如き結論に到達した。

1) 知覚麻痺の大部分は次の二型の何れか又は両型の組合せとして説明し得る。第一型：皮膚神経支配とは無関係に不規則な拡り方を示すもので、皮膚表層の神経末端部が慢性におかされた結果と考える。第二型：表層筋膜を貫いて皮下に分布する一つ一つの神経小枝を単位として麻痺する。これは神経が筋膜裂孔で絞扼される結果であろうと推論した。

2) 筋麻痺及び萎縮も、個々の筋が単位となつて行われる。丁度知覚麻痺の第二型式に匹敵する。

3) 従来の麻痺上行説に従う拡り型式をとるものは極めて少い。従つて神経大幹性麻痺は極めて少いものであることを知つた。即ち神経癩に於いては、如何に広範な知覚麻痺も或は運動麻痺も、それぞれ末梢神経の末梢部で麻痺する結果であると考えられる。

4) 知覚解離は若干認められるが、一定の傾向は認められない。

5) 表面知覚が麻痺している部分で、深部知覚がよく保たれ或は却つて鋭敏になつている場合が多い。