

Title	CHONDROSARCOMA OF THE RIB LOCATED IN THE RETROPERITONEAL CAVITY
Author(s)	AMANO, TAKEHIKO
Citation	日本外科宝函 (1962), 31(4): 674-680
Issue Date	1962-07-01
URL	<a href="http://hdl.handle.net/2433/205453">http://hdl.handle.net/2433/205453</a>
Right	
Type	Departmental Bulletin Paper
Textversion	publisher

---

## 症 例

---

# CHONDROSARCOMA OF THE RIB LOCATED IN THE RETROPERITONEAL CAVITY

by

TAKEHIKO AMANO

From the 2nd Surgical Division, Kyoto University Medical School

(Director : Prof. Dr. YASUMASA AOYAGI)

Tomita Hospital (Director : Dr. KUWASHI TOMITA)

Received for publication Apr. 16, 1962

The pathology of bone tumor is very complicated and the classification of this tumor is confused even in recent years. The diagnosis of bone tumor is based both on the microscopical findings and simultaneously on the clinical features, such as the site of tumor, ages of the patients at the time of occurrence of bone tumors etc.

The pathological features of bone tumors resemble in some respects those of brain tumor. It appears that the diagnosis of chondrosarcoma is influenced by the clinical course rather than based on an adequate pathological assessment.

In this report, the characteristic features of the patient who had been diagnosed as a secondary chondrosarcoma from the clinical course and pathologically as a chondrom or a benign form of chondrosarcoma, are presented.

### REPORT OF CASE

A forty-four-year old man was admitted to the hospital because of a large mass in the lumbar portion. About one year and a half ago he noticed a hard mass at the right lumbar portion. This mass caused no pain nor revealed any significant symptoms, but gradually increased in size and four months before admission, there was a hypesthetic sensation in the right buttock with a numbness in the right leg. There was slight weight loss and weakness before entry. The stool was normal. There was no hereditary disease in his family.

The patient was a moderately nourished man. Examination of the abdomen revealed the large, hard mass which could not be identified as a liver at the site of the right upper abdominal portion. The mass extended to the anterior fourth rib at the upper limit, five-finger breadth in the anterior right mamillar line, ten centimeters breadth beneath the costal margin on the right axillary line, the posterior eighth rib to the upper limit and twenty centimeters from the costal margin on the scapular line. The surface of the tumor was nodular and it was not movable at the base. The color of the skin over the tumor was normal; pigmentation, venedilatation, fluctuation, compression pain, and heat sensation were all not detectable. At the right buttock, slight hypesthesia was

found. Peristalsis was normal. There was no edema of the ankles and feet. The peripheral pulse were normal. The temperature was 36.4° C, the pulse 80, and the respirations 20. The blood pressure was 124 systolic, 80 diastolic. The urine was normal. Examination of the blood showed a hemoglobin of 1.6 mg per 100 ml and a white cell count of 6000, a red cell count of  $198 \times 10^5$ , the total protein 6.0 mg, the albumin 2.3 mg, the globulin 3.7 mg, the calcium 4.54 mg, the phosphor 2.8 mg, the alkaline phosphatase 5.0 Bodansky units, the B. S. P. test 5%, the Cadmium reaction R5, the Cobalt reaction R 5, the serum electrophoretic pattern revealed a increase of gamma and beta globulin and a decrease of albumin.

The X ray film of the chest disclosed a marked elevation of the right leaf of the diaphragm. (Fig. 3) The film of the upper abdomen showed a mass that measured 20×25 cm on the right side; there were dense calcifications over the upper portion and the cloudy calcification throughout the lower and the medial portion of the mass; the liver was markedly displaced downward and forward by the mass, which was not distinguished from each other in the X ray film. An upper gastrointestinal series demonstrated compression and displacement of the gastric antrum to the midline; the duodenum and the flexura hepatica a downward displacement.

An intravenous pyelogram showed a displacement of the right kidney inferiorly by the mass and the mass was not roentgenologically separated from the right kidney, because the calyceal pattern was not clear especially at the upper part. (Fig. 4)

### OPERATION

The mass proved to be a huge retroperitoneal tumor, occupying the whole upper retroperitoneal cavity, compressing the liver forward and median side thereby, reducing the liver to half of its normal size; the right kidney displaced downward, its upper portion was infiltrated by the mass; the right leaf of diaphragm and the pleura were closely adherent to the mass; at the reverse side of the liver, the mass was closely adherent to the inferior vena cava and the radical operation was not controlable.

### PATHOLOGICAL FINDINGS

In the gross appearance of the specimen resected, the tissue of the tumor bore a partial resemblance to cartilage, partially to hyalinous tissue and the calcifications were observed to be scattered throughout the tumor. Microscopically, the tissue of a specimen revealed a cartilaginous tissue in the qualification of chondroma, and in some specimens, the degenerated changes were markedly visible, and from the cytological pictures secondary chondrosarcoma was suspected.

### DISCUSSION

The bone tumors reveal much diversity and many polymorphisms in pathology and in the clinical features. The clinical prognosis and the malignancy of this tumor are not decided only by the pathological findings but depend on the origin of the tumor and the ages of the patients. The classification of bone tumor greatly differ according to the

investigators.

ONEAL and ACKERMAN in defining chondrosarcoma pathologically, introduced the following cytological criteria: Calcified or obviously degenerated area should be excluded. The nuclei considered abnormal in determining the various categories of cartilaginous tissue: 1) any double nucleus in a single cell, regardless of the size of the nuclei: 2) nuclei more than twice the size of the usual large nucleus seen in the tumor under consideration. In addition, one should be watchful for a general plumping up of all nuclei. The usual large nucleus of a chondrosarcoma is larger than in a benign tumor, and the binucleated cells of a chondrosarcoma are often plump, while in benign tumor they are not. It is not necessary to find mitosis to make a diagnosis of a malignant bone tumor. A diagnosis of chondrosarcoma may be made by finding scattered areas in which a moderate number of atypical nuclei are found, even if the bulk of the tumor appears benign.

The serum alkaline phosphatase level rises in the osteogenic sarcoma, especially in the hematopoietic osteosarcoma. The serum acid phosphatase level rises in the abnormalities of fibrinogenesis and metastatic bone carcinoma. Serum calcium increases in multiple myelom, and serum inorganic phosphor increase in osteogenic sarcoma, giant cell sarcoma, and metastatic sarcoma. In some bone tumors, changes of globulin and albumin fraction are observable.

In this case, the laboratory findings and data revealed no specific findings of a chondrosarcoma, but the X ray films and the clinical course revealed a malignant bone tumor or a teratoma, suggesting a large tumor of a relatively short duration and originating from the ribs or the vertebral column.

According to the classification of chondrosarcoma by ONEAL and ACKERMAN this tumor belongs to a low grade chondrosarcoma, presenting occasionally very plump nucleus, general plumping of many nuclei, low incidence of double nuclei, and the marked calcification.

A chondroma, and even a secondary chondrosarcoma, the prognosis may be favourable after radical operation. But the prognosis of this patient will be unfavourable with the local occurrence of the tumor and the inducement of a high grade malignant tumor.

## RUMMARY AND CONCLUSION

The secondary chondrosarcoma which seemed to have originated from the spine or the lower ribs was reported.

## REFERENCES

- 1) O'Neal, L. W. and Ackerman, L. V.: Chondrosarcoma of Bone, *Cancer*, **5**, 551, 1952.
- 2) Jaffe, H. L., Lichtensten, L.: Chondromyxoid Fibroma of Bone; a distinctive benign tumor likely to be mistaken especially for chondrosarcoma, *Arch. Path.*, **45**, 541, 1948.
- 3) Geschickter, C. F., and Copeland, M. M.: *Tumors of Bones*. Lippincott Co. London, 1949.
- 4) Hashimoto, M.: The Studies of bone tumors on the gross specimens, the Japanese Journal of Clinical Pathology, **9**, 108, 1961. (In Japanese)
- 5) Maeyama, I.: The Chemistry of Bone Tumor, the Japanese Journal of Clinical Pathology, **9**, 105, 1961. (in Japanese)
- 6) Maeyama, I.: The Prognosis and the Therapy of the Osteogenic Sarcoma, *Geak*, **23**, 1157, 1962. (in Japanese)
- 7) Murata, M.: Systemische Pathologische Histologische Untersuchung uber Knochengeschwulst (in

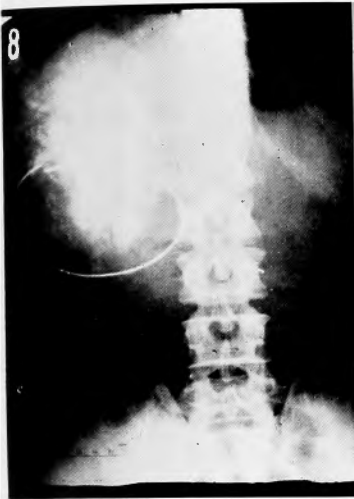


Fig. 1

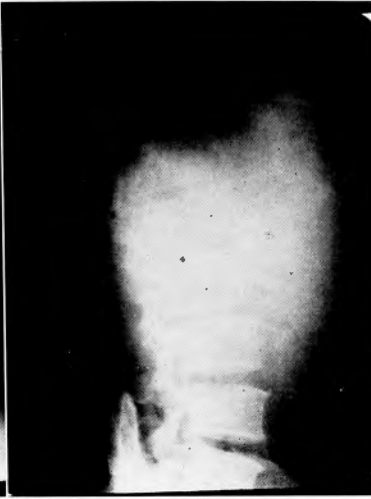

Fig. 2

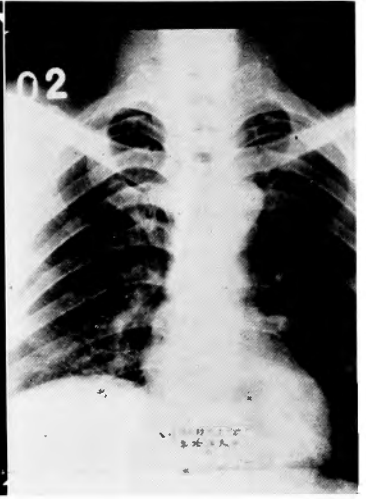


Fig. 3

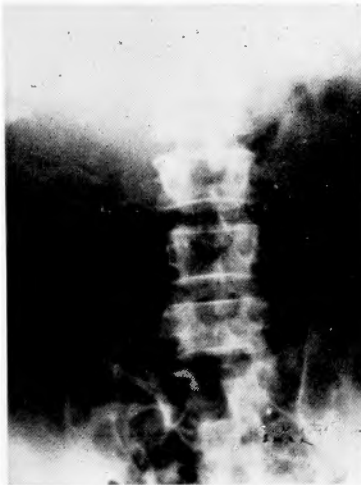


Fig. 4

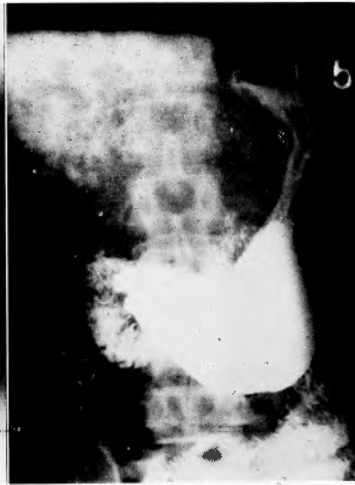

Fig. 5

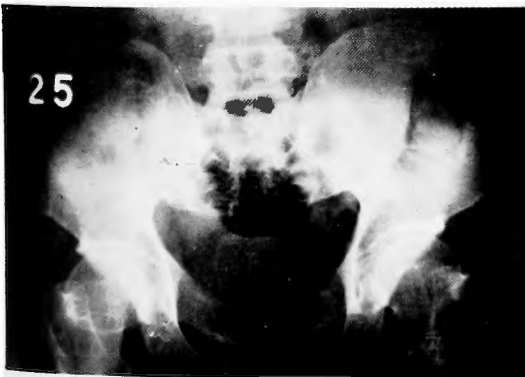

Fig. 6

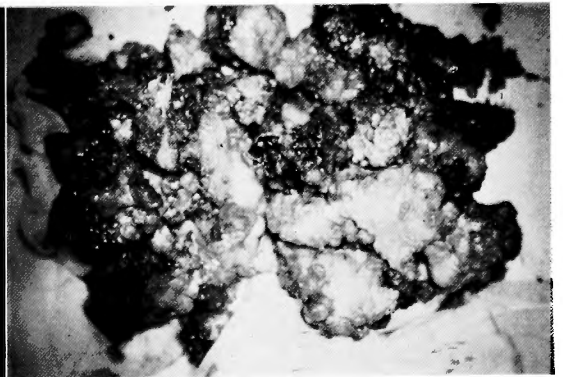


Fig. 7

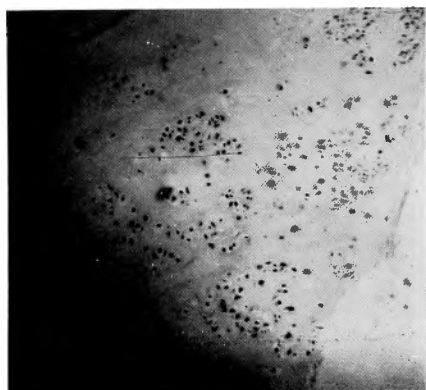


Fig. 8

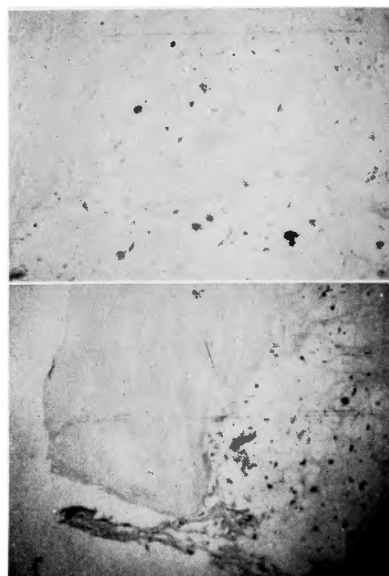


Fig. 9

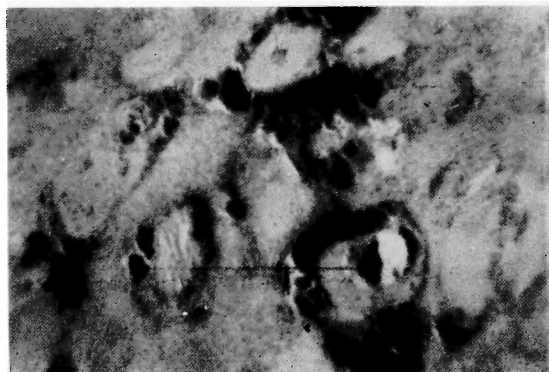

Fig. 10

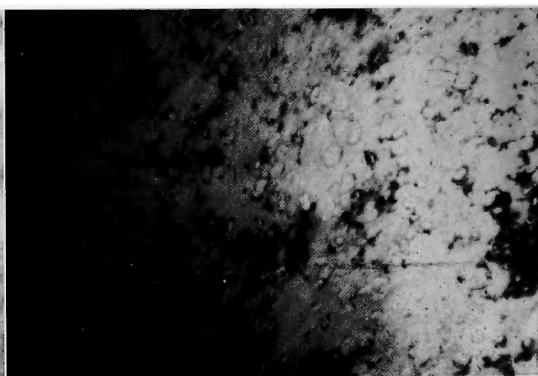


Fig. 11

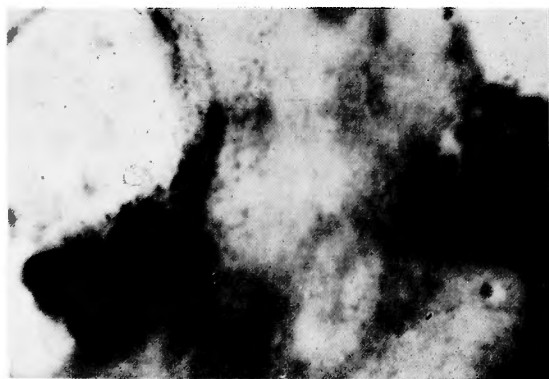


Fig. 12

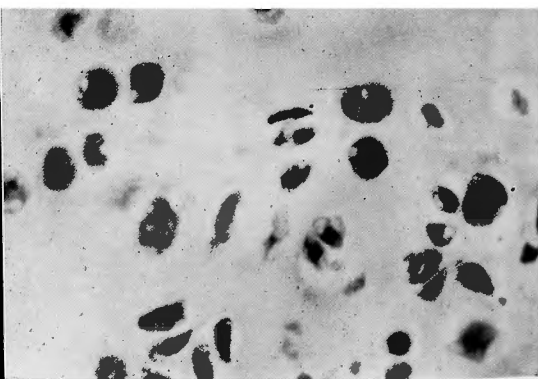


Fig. 13

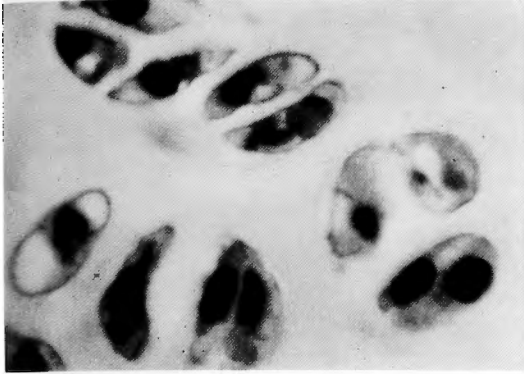


Fig. 14

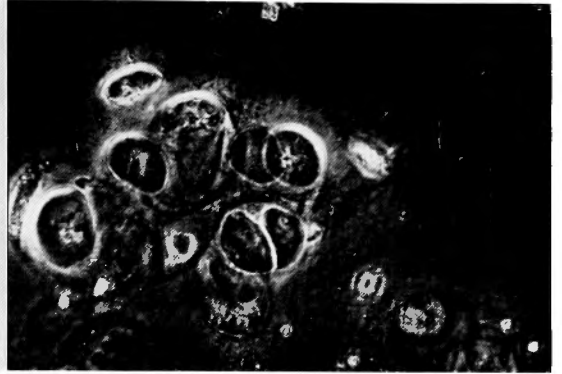


Fig. 15

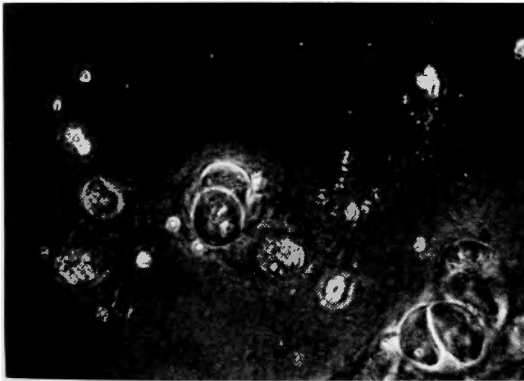


Fig. 16

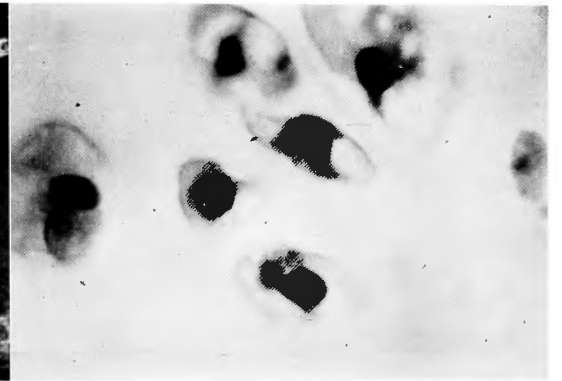


Fig. 17

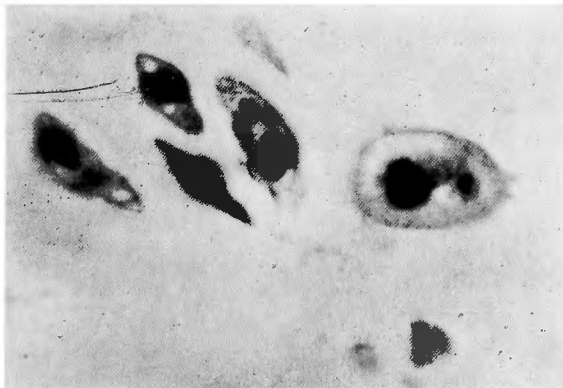


Fig. 18

japnisch), Tr. Soc. Path. Jap. 49, 237, 1956.

- 8) Takeuchi T.: The Pathology of Bone Tumor (In Japanese). Operation, 15, 1061, 1961.  
9) Willis, R. A.: Pathology of Tumor, Butterworths. London, 1961.

#### ILLUSTRATIONS OF FIGURES

- Figure. 1** Anteroposterior film of the upper abdomen.  
**Figure. 2** Lateral film of the tumor.  
**Figure. 3** Posteroanterior film of the chest.  
**Figure. 4** Intravenous Pyelogram.  
**Figure. 5** Film of the stomach and the duodenum.  
**Figure. 6** Anteroposterior film of the pelvis.  
**Figure. 7** Gross specimen of the tumor resected.  
**Figure. 8** Photomicrograph of the tumor; area of chondroma or chondrosarcoma.  
**Figure. 9** Capsule of the tumor.  
**Figure. 10** Calcified area of the tumor.  
**Figure. 11** Calcified area of tumor.  
**Figure. 12** Calcified area of tumor.  
**Figure. 13** Chondroma or chondrosarcoma cells.  
**Figure. 14** Tumor cells.  
**Figure. 15** Tumor cells with phase contrast microscopy.  
**Figure. 16** Tumor cells with phase contrast microscopy.  
**Figure. 17** Tumor cells.  
**Figure. 18** Tumor cells.

#### 和文抄録

### 肋骨より発生した巨大な軟骨肉腫の一例

京都大学医学部外科学教室第2講座 (主任; 青柳安誠教授)

富田病院 (院長; 富田 精博士)

天 野 武 彦

44才の男子, 右腰部の腫瘍及び右臀部の知覚異常を主訴として入院し, X線所見, 及び臨床検査所見によつて, 右腹膜腔に存在する巨大な2次性軟骨肉腫を診

断し, 手術により悪性度の極めて低い軟骨肉腫と病理組織学的に診断された1例を報告し, 一般の2次性軟骨肉腫の臨床像と組織像について言及した。