

Title	Lymphangioma of the Jejunum : Report of a Case
Author(s)	MASHIMO, ROKURO; YAMAZAKI, TORU; HAYASHI, KAZUSHI; SAKAMOTO, TADAHIRO; ASANO, MOTOKAZU; KANAYAMA, TERUJI; IDA, TAKESHI; SAKAMOTO, TSUTOMU
Citation	日本外科宝函 (1990), 59(5): 402-407
Issue Date	1990-09-01
URL	<a href="http://hdl.handle.net/2433/204468">http://hdl.handle.net/2433/204468</a>
Right	
Type	Departmental Bulletin Paper
Textversion	publisher

---

症 例

---

## Lymphangioma of the Jejunum: Report of a Case

ROKURO MASHIMO, TORU YAMAZAKI, KAZUSHI HAYASHI, TADAHIRO SAKAMOTO, MOTOKAZU ASANO  
TERUJI KANAYAMA, TAKESHI IDA and TSUTOMU SAKAMOTO\*

Department of Surgery, Department of Radiology\*, Kouga Public Hospital  
Received for Publication, June 12, 1990.

### Summary

We report a very rare case of jejunal lymphangioma. A 16-year-old male sustained injuries to abdominal internal organs in a traffic accident. During emergency operation, a cystic tumor was incidentally detected in the jejunum and adjoining mesentery and treated by segmental resection of the jejunum. The cystic tumor (5.0×7.0 cm) was multilocular and demonstrated to be a cavernous lymphangioma by histopathological examination. The pathology, diagnosis, and treatment of this disease described in the literature are reported.

### Introduction

Among benign tumors in the small intestine, lymphangiomas are very rarely observed. Only 13 cases have been reported in Japan for the 16-year period since 1974 to the present<sup>1,2)</sup>. Recently, we incidentally detected a lymphangioma in the jejunum at operation in a patient with injuries to abdominal internal organs sustained in a traffic accident and performed segmental resection of the intestine.

### Case

A 16-year-old male was transported to our hospital due to abdominal contusion sustained in a traffic accident on October 3, 1989. Abdominal muscle rigidity suggested panperitonitis. Laboratory studies showed a leucocyte count of 15,600/ $\mu$ l, GOT of 477 IU/l, GPT of 261 IU/l, and an LDH of 1,636 IU/l.

Abdominal CT (Fig. 1) revealed collection of a small amount of fluid in the abdominal cavity, an irregular low density area in the medial segment of the liver, and a low density area in contact with the left upper portion of the small intestine. Since these findings suggested liver injury, perfora-

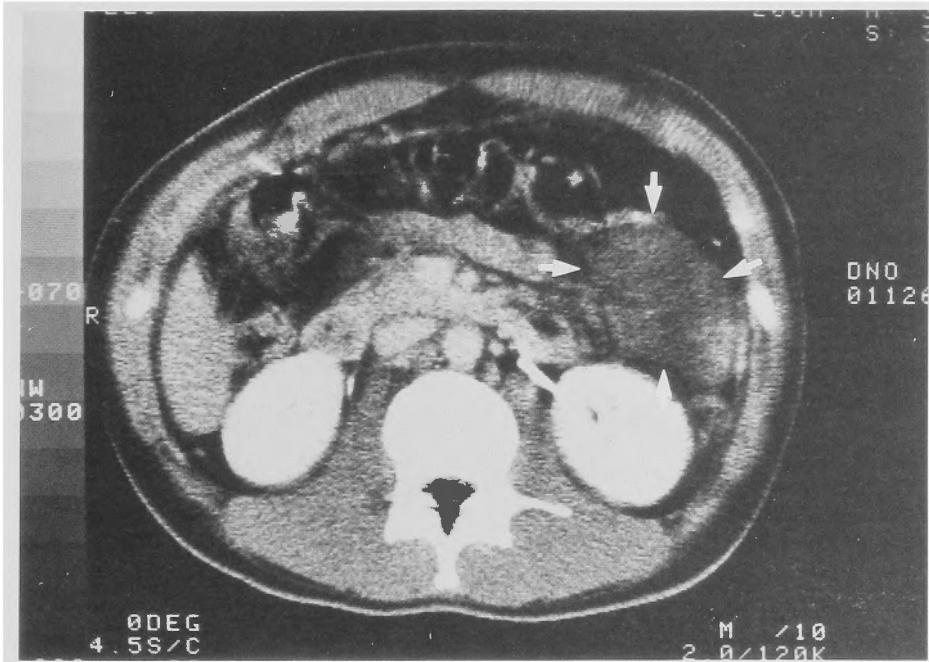
---

Key words: Lymphangioma, Jejunum, Abdominal CT.

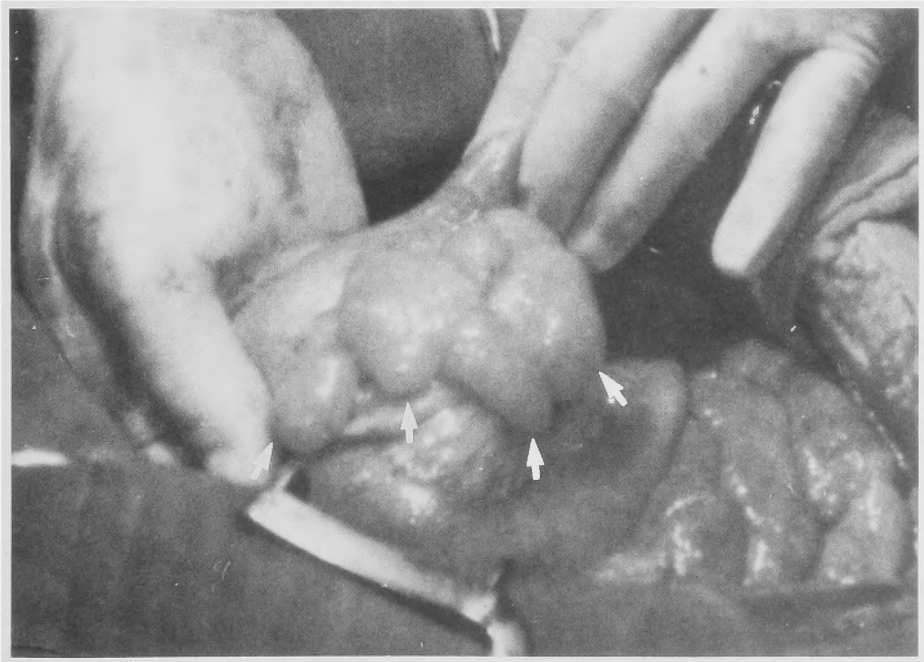
索引語: リンパ管腫, 空腸, 腹部 CT.

Present address: Department of Surgery, Kouga Public Hospital, Minakuchi-cho, Kouga-gun, Shiga-ken, 528, Japan

tion of the small intestine, and panperitonitis, emergency operation was performed on that day. At operation, liver injury and duodenal perforation were observed and repaired by suturing.



**Fig. 1** Abdominal CT. A low density area was observed in the left upper abdomen.



**Fig. 2** At operation. A cystic tumor was observed in the jejunum and adjoining mesentery.

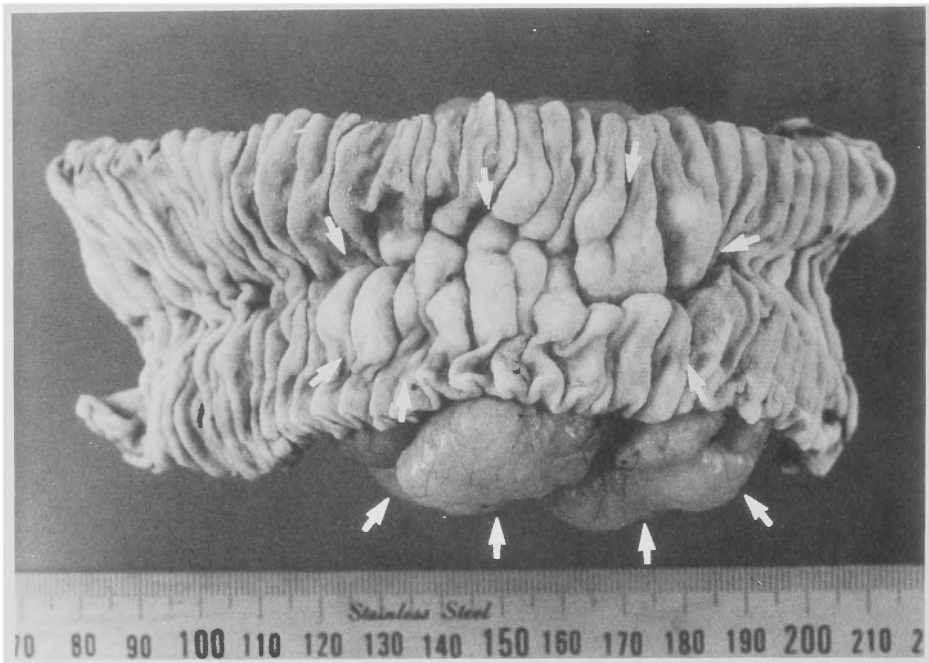


Fig. 3 Resected specimen. The jejunum was opened at the antimesenteric border. The tumor involves the mucosa, serosa, and the mesentrium. The mucosa is elevated like cobble stones.

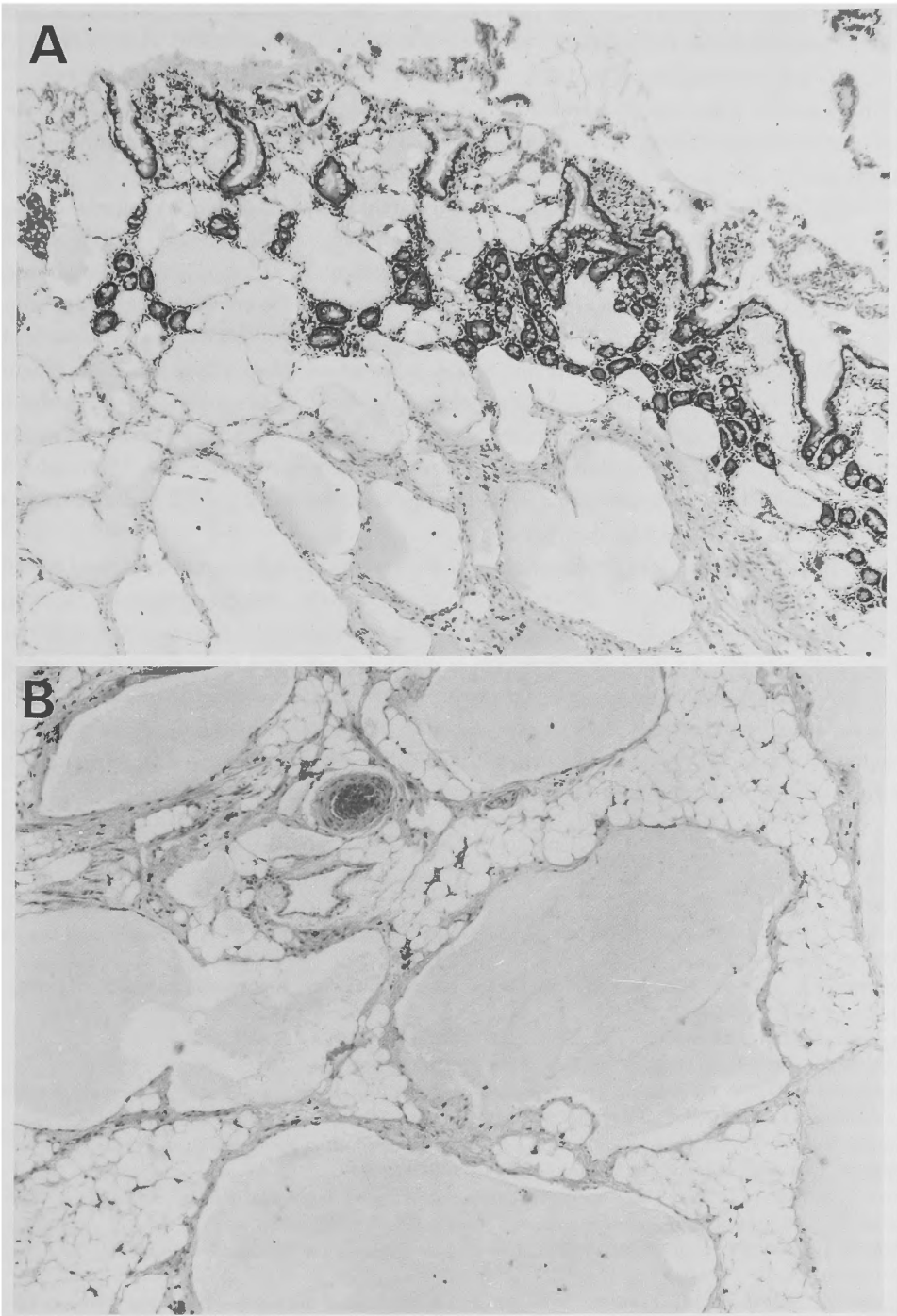
Exploration of the small intestine showed a cystic tumor (5 × 7 cm) in the jejunum and adjoining mesentrium about 30 cm below the ligament of Treitz (Fig. 2). Since no perforation was observed in the small intestine, the low density area on preoperative CT scans was considered to represent this tumor. Segmental resection (about 15 cm) of the small intestine including the tumor was performed.

A resected specimen (Fig. 3) showed a multilobular cystic tumor (5 × 7 cm) extending from the intestinal wall to the mesentrium. The mucosal surface was yellowish-white and elevated like cobble stones.

Pathologic examination (Fig. 4) revealed many endothelium-lined cystic spaces varying in size from the lamina propria mucosae to the serosa of the jejunum and in the adjoining mesentrium. However, there were no findings suggestive of malignancy, and a diagnosis of cavernous lymphangioma of the jejunum and mesentrium was made.

### Discussion

Lymphangiomas, far less common than hemangiomas, are generally considered malformation rather than tumor, and many of them are present at birth. They originate in various parts of the body, frequently in the skin, neck, chest, extremities, axilla, oral cavity, eyes, and the groin<sup>3)</sup>, but are rarely observed in the gastrointestinal tract, especially very rarely in the small intestine. RAINFORD<sup>4)</sup> reported that only 1 of 87 benign tumors of the small intestine was a jejunal lymphangioma in a retrospective analysis of 11,500 autopsies and 4,500 surgical specimens. FLEMING et al<sup>5)</sup> detected 9 lymphatic cysts in the gastrointestinal tract including only 1 in the small intestine by 453,708 roen-



**Fig. 4** Microscopic picture ( $\times 30$ ) shows the tumor composed of many endothelium-lined cystic spaces varying in size, infiltrating from mucosa (A) to adjoining mesenterium (B).

tgenographic examinations in 1,437,767 patients. YAO et al<sup>6)</sup> collected 3 cases of lymphangioma of the small intestine in Japan during the 10-year period between 1969 and 1979, while HARUFUJI et al<sup>1)</sup> collected 10 cases between 1974 and 1984. Since then, only 3 cases have been reported<sup>2)</sup>.

Though several classification schemes have been proposed for lymphatic tumors, they are commonly classified into 3 types: 1) simple lymphangioma, 2) cavernous lymphangioma, and 3) cystic lymphangioma<sup>3)</sup>. The present case was of the cavernous type.

HARUFUJI et al<sup>1)</sup> reported abdominal pain as a frequent symptom of lymphangiomas of the small intestine, but generally, there seem to be no specific symptoms<sup>2)</sup>. This disease is rarely detected by routine examinations because of the low incidence and difficulties in examining the small intestine. Most lymphangiomas have been incidentally detected at operation for other diseases or at autopsy<sup>7,8)</sup>. However, HARUFUJI et al<sup>1)</sup> reported that the preoperative diagnosis of this disease was possible by X-ray examinations such as barium enema and double contrast radiology of the small intestine in 4 of 10 patients. In our patient, the lesion was incidentally detected at operation for injuries to abdominal internal organs sustained in a traffic accident. However, this lesion had been shown as a low density area in the left upper abdomen on preoperative abdominal CT scans. Similarly, SARNO et al<sup>9)</sup> made a diagnosis of lymphangioma in the retroperitoneum based on CT findings. Therefore, CT may be useful for diagnosing this disease.

The primary treatment for lymphangiomas in the gastrointestinal tract is segmental resection of the intestine or local excision<sup>10)</sup>. Lymphangiomas are benign, and no recurrence or malignant transformation has been reported. However, WOOD<sup>11)</sup> reported that when extensive infiltration to the mesentery is present, complete resection is often difficult, and there is possibility of recurrence. There are reports on endoscopic polypectomy for lymphangiomas in the colon<sup>12)</sup>. In the future, endoscopic polypectomy may be also possible in a portion of the small intestine which a fiberscope can reach. However, since growth beyond the cavity as observed in our case has been reported<sup>13)</sup>, caution is needed because polypectomy alone might be inadequate.

#### Reference

- 1) Harufuji J, Ogawa T, Sakasita O, et al: Jejunal lymphangioma: Report of a case, *Stomach and Intestine* 21: 565-568, 1986.
- 2) Shigematu A, Iida M, Hatanaka M: Endoscopic diagnosis of lymphangioma of the small intestine, *Am J Gastroenterol* 83: 1289-1293, 1988.
- 3) Anderson WAD: *Pathology*, St Louis, The C. V. Mosby Co., 1971, 764-765.
- 4) Raiford TS: Tumor of the small intestine, *Arch surg* 25: 122-177, 1932.
- 5) Fleming MP, Carlson HC: Submucosal lymphatic cysts of the gastrointestinal tract. A rare case of submucosal mass lesion. *Am J Roentgenol* 110: 842-845, 1970.
- 6) Yao T, Hiyoshi Y, Tanaka K, et al: Primary benign neoplasms of the jejunum and ileum. Review of the Japanese literature. *Stomach and Intestine* 16: 1049-1056, 1981.
- 7) Liver L, Silverstein J, Tope JW: Benign neoplasms of the small intestine. *Int abst surg* 102: 1, 1956.
- 8) Good CA: Tumors of small intestine. *Amer J Roentg* 89: 685-705, 1963.
- 9) Sarno RC, Carter BL, et al: Cystic lymphangioma: CT diagnosis and thin needle aspiration. *Br J Radiol* 57: 424-426, 1984.
- 10) Nagano K, Yamashiro M, Tamura Y: Cystic lymphangioma of the descending colon. Report of a case. *Stomach and Intestine* 14: 503-511, 1979.
- 11) Wood K: Lymphatic cysts of the mesentery. A review of the literature and a report of two cases. *Brit J Surg* 43: 304-308, 1955.
- 12) Kuroda Y, Katoh H, Ohsato K: Cystic lymphangioma of the colon. Report of a case and review of the

literature. *Dis Col & Rect* 27: 679-682, 1984.

- 13) Sato D, Shiohara Y, Nakasima A, et al: A case report of ileocecal lymphangioma. *Kurume Med J* 28: 141, 1981.

## 和文抄録

### 空腸リンパ管腫の1例

公立甲賀病院外科, 同 放射線科\*

真下 六郎, 山崎 透, 林 一資, 坂本 忠弘  
浅野 元和, 金山 輝次, 井田 健, 坂本 力\*

きわめて稀な空腸リンパ管腫を経験したので報告する。交通事故により腹部内臓器損傷を負った16才男性に対して手術を行った際、偶然に空腸及びそれに続く腸間膜に嚢胞状の腫瘍を認めた。この病巣に対して空腸部分切除を行った。腫瘍は5.0×7.0 cm 大の多房性の嚢胞性腫瘍で、組織病理学的に Cavernous lymphangioma と診断された。文献的に検討を行ったが以

下のとうりである。本症はわれわれが調べたかぎりでは本邦においては、1974年から現在までの16年間に13例が報告されているにすぎない。本症は他の疾患に対する手術、又は剖検により偶然に発見されるのが大部分であるが注腸造影、小腸二重造影或いは腹部 CT にて診断されることもある。治療は一般に腫瘍を含めた腸部分切除又は腫瘍切除が行われている