

Title	Effective Treatment by Orthosis of Dislocation of the Patella Associated with Down's Syndrom : A Report of Case
Author(s)	MATSUSUE, YOSHITAKA; UEO, TOYOJI; YAMAMURO, TAKAO
Citation	日本外科宝函 (1991), 60(3): 189-194
Issue Date	1991-05-01
URL	http://hdl.handle.net/2433/203789
Right	
Type	Departmental Bulletin Paper
Textversion	publisher

Effective Treatment by Orthosis of Dislocation of the Patella Associated with Down's Syndrom A Report of Case

YOSHITAKA MATSUSUE,* TOYOJI UENO,** TAKAO YAMAMURO,***

*Assistant professor, Department of Orthopedic Surgery, Kyoto University

**Associate professor, Department of Orthopedic Surgery, Kyoto University

***Professor, Department of Orthopedic Surgery, Kyoto University

Received for Publication, Feb. 1, 1991

Abstract

The authors reported a case of recurrent dislocation of the patella associated with Down's syndrome. As for treatment, it is important to consider the levels of intelligence and daily activity, severe obesity, and certain internal medical conditions associated with this disease. Primary orthotic treatment is recommended for subluxation or reducible dislocation of the patella.

Introduction

Down's syndrome is well recognised by the features of cardiovascular anomalies, mental retardation, increased susceptibility to infection, and increased joint laxity, and also has many associated orthopedic disorders. Among these, subluxation or luxation of the patella is common, but detailed reports about the conservative treatment of this disorder are rare. The authors report a case of dislocation of the patella associated with Down's syndrome, which was treated by orthosis and with good result.

Case report

A 17 year-old male was noticed to be limping, and complained of pain in his left knee. He was referred to our out-patient clinic on October 14, 1986 by his school doctor, with a diagnosis of dislocation of the patella associated with Down's syndrome. He showed the characteristic appearance of Down's syndrome. Two joint laxities were detected by the five criteria of Carter-Willkinson. The alignment of both knees was found to be about 10 degrees valgus position, and the range of motion was from 0 to 130 degrees. Apprehension test was positive in both knees. The left patella showed complete lateral dislocation at 50 degrees of flexion, but did not dilocate when pushed medially with a thumb.

The roentgenographs of the patella in axial projections taken at the first medical examination

Key words: Down's syndrome, Dislocation, Patella, Brace

索引語: ダウン症候群, 脱臼, 膝蓋骨, 装具

Present address: Department of Orthopaedic Surgery, Faculty of Medicine, Kyoto University, 54 Kawahara-cho, Shogoin, Sakyo-ku, Kyoto, 606, Japan

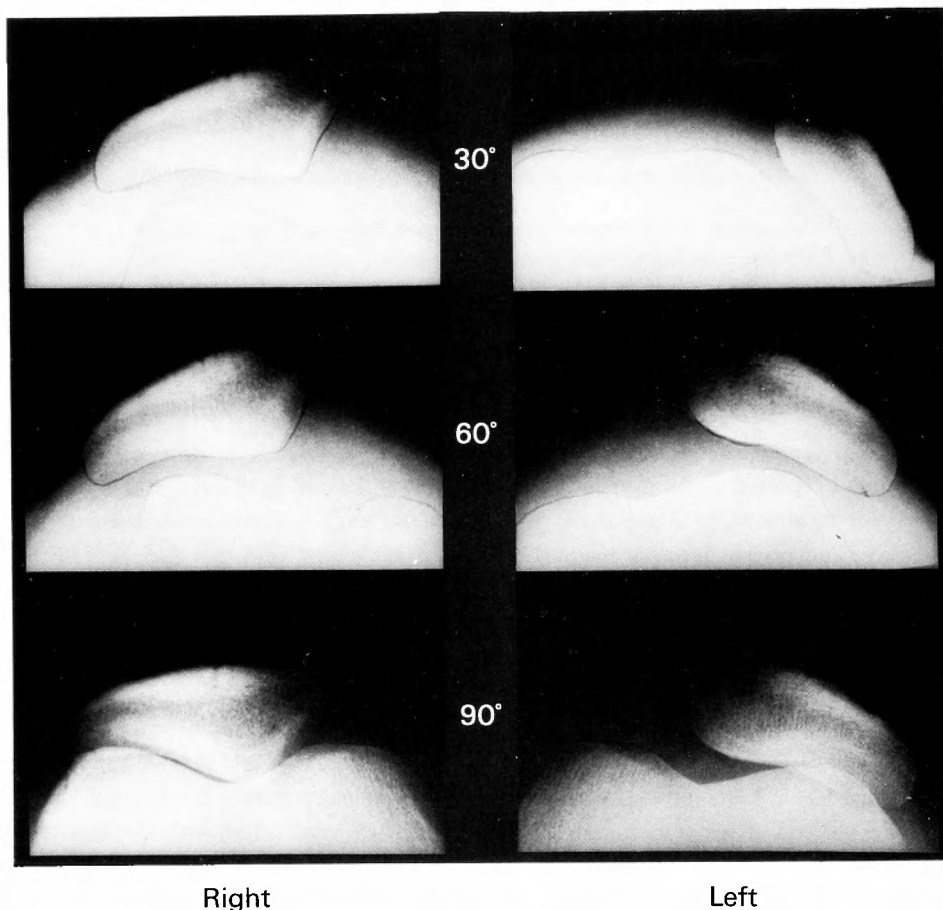


Fig. 1. Roentgenogram in axial projection of the patella taken at first medical examination.

The right patella subluxates; The left patella shows complete dislocation at 30 degrees of flexion and subluxation at 90 degrees.

showed that the right patella subluxated at 30 and 60 degrees of flexion, and the left patella dislocated completely at 30 degrees, while still subluxating at 90 degrees of flexion (Fig. 1). Plumbo's orthosis (5) was applied to both knees, and the patellae were then held in normal position (Fig. 2). The patient wore the orthosis at all time except at night. The roentgenographs in axial projection after 3 years showed that the left patella subluxated at 30 degrees and lay in normal position at 90 degree of flexion. The right patella lay in normal position at every angle (Fig. 3). Since that time, he has had no pain in his left knee, and has been able to do his work in school. When the patellar tilting angle and lateral displacement ratio were measured according to MERCHANT's method (4), the position of the right patella was markedly improved at 30 and 60 degree of flexion and that of the left patella was also improved distinctly at every degree of flexion (Fig. 4).

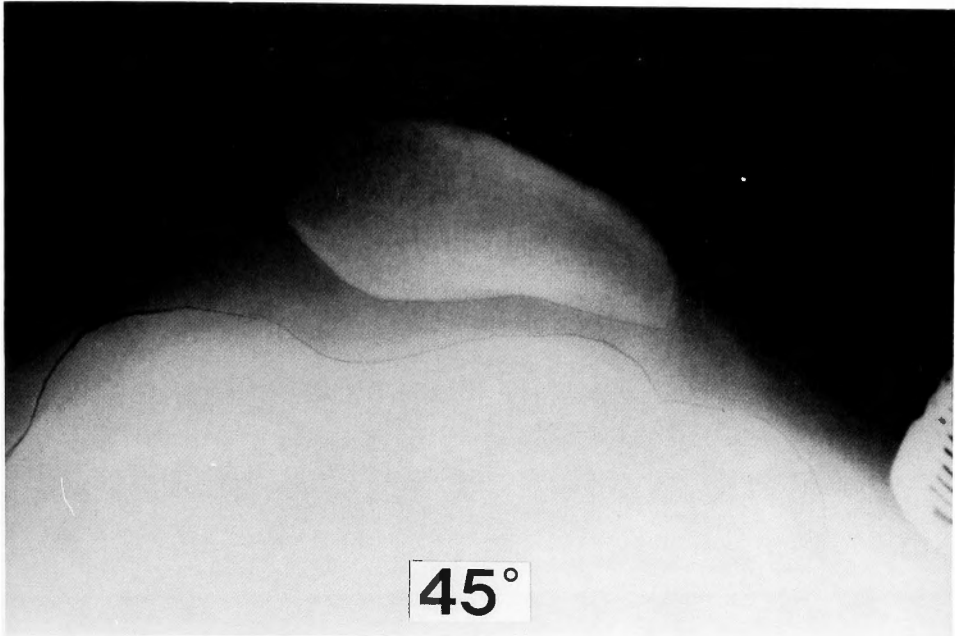


Fig. 2. The patella held in normal position by application of Palumbo's orthosis.

Discussion

Down's syndrome is associated with several kinds of orthopaedic disorders. **DIAMOND** et al (1981), in reviewing the orthopaedic pathology among institutionalised children with Down's syndrome, found that dislocation of the patella was present in 5 percent, and subluxation in 21 percent of them. According to the **DUGDALE**'s study (1986), the frequency of dislocation of the patella was 8.3 percent among institutionalised children, and 4 percent among non-institutionalised children, almost the same number as that obtained by the **DIAMOND**'s study. There has been no detailed report concerning the conservative treatment of recurrent dislocation of the patella associated with Down's syndrome.

Pes planus, dislocation of the patella, subluxation of atlanto-axial joint, and dislocation of the hip joint are often noted in association with Down's syndrome, probably due to generalised muscle hypotonia and increased joint laxity. However, no significant joint laxity was noticed in this case. **LIVINGSTONE** and **HIRST** (1986) found that, of the 39 school-age children with Down's syndrome included in his study, only two could be regarded as showing unequivocally abnormal generalised joint laxity; 15 of the 39 children had no evidence of joint laxity at all.

Special problems particular to Down's syndrome must be considered in choosing a method of treatment. **WATANABE** et al. (1986) mentioned that the indication for surgery should be carefully considered, because the results of surgery are poor in patients with low IQ's or in very obese patients. Therefore, particular notice must be taken of the levels of intelligence and daily activity, severe obesity, and cardio-respiratory condition. If such conditions are severe, it is obvious that the treatment, especially if surgical, may be difficult to perform.

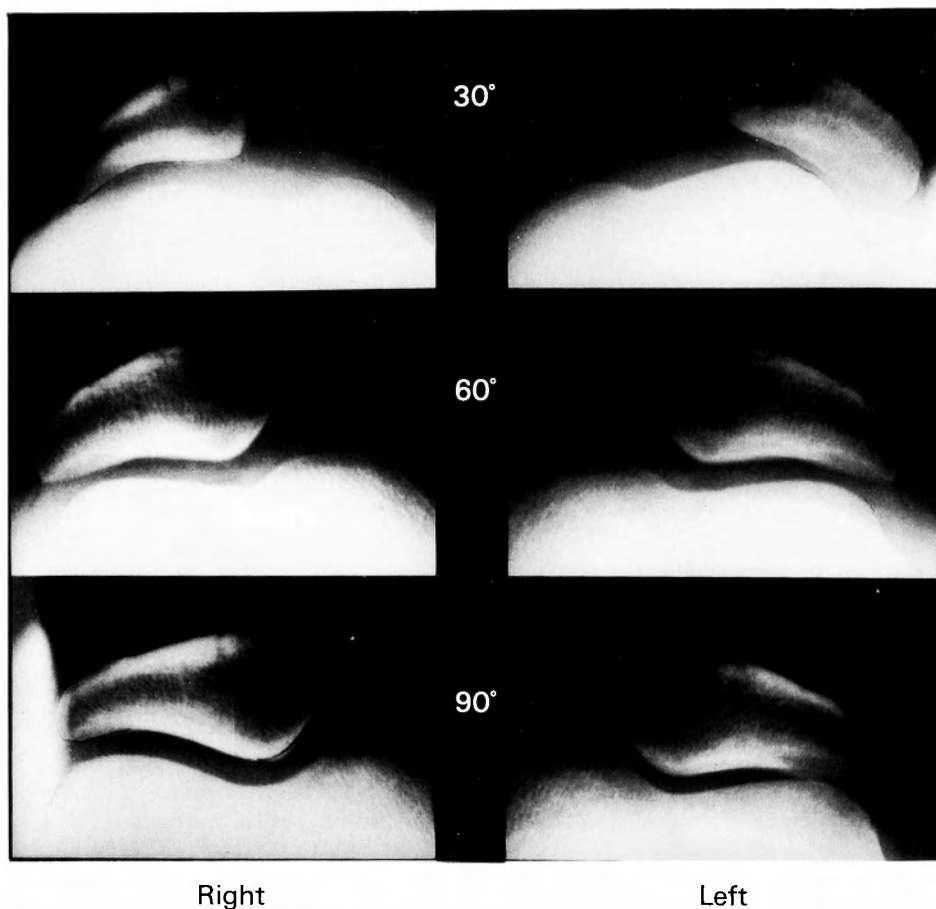


Fig. 3. Roentgenogram in axial projection after three years of orthotic treatment. The right patella held in almost position. The left patella remains slightly subluxated, but the position of the patellae are much improved.

As for conservative treatment, DUGDALE and RENSHAW (1986) found, through the clinical experience of three cases treated by orthosis, that it had little effect in cases of permanent dislocation of the patella. On the other hand, MENDEZ et al. (1988) pointed out that non-surgical treatment either maintained or improved the ambulatory status in 67 percent of the 8 conservatively treated knees with fair or good previous ambulation, whereas 80 percent of the knees with poor previous ambulation did not improve. There has been no detailed report concerning serial roentgenographical observations. Furthermore, patients with Down's syndrome cooperate with orthotic treatment in most cases, so the authors advocate that such treatment should be tried primarily if dislocation of the patella were noticed in an early stage.

If orthotic treatment is not effective, surgical treatment may be considered. However, DUGDALE and RENSHAW (1986) reported that surgical treatment had a satisfactory result in only four out of eight knees operated on, with an average follow-up of 16.8 years. Moreover, almost all pa-

	Angle of flexion	Right		Left	
		At first exam.	At follow-up	At first exam.	At follow-up
Tilting angle	30°	33°	21°	62°	43°
	60°	37°	19°	40°	28°
	90°	11°	11°	23°	13°
Lateral displacement ratio	30°	62	38	168	62
	60°	53	28	68	42
	90°	17	17	36	14

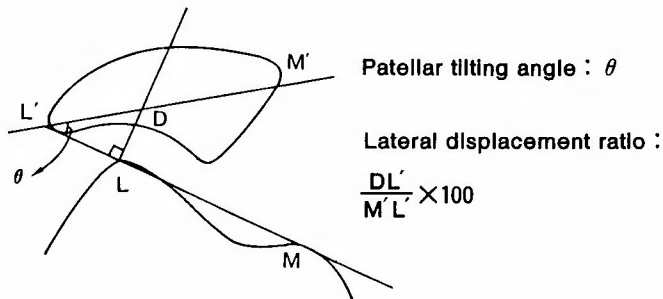


Fig. 4. Serial change of the patellae by Merchant's method. Patellar tilting angle and lateral displacement ratio, both much improved.

tients with patellofemoral instability adapted to the problem and were able to walk, as he also pointed out. On the other hand, MENDEZ et al. (1988) found that operative treatment resulted in good ambulatory ability in 86 percent of the knees with fair or poor preoperative ambulatory status, but did not effectively correct deformities that subsequently resulted in degenerative arthritis. He also found reducible dislocation to be the best indication for surgery, because permanent dislocation occurs in conjunction with advancement of osteoarthritic change.

References

- 1) Diamond LS, Lynne D, Sigman B: Orthopedic disorders in patients with Down's syndrome. *Orthop Clin North America* 12(1): 57-71, 1981.
- 2) Dugdale TW, Renshaw TS: Instability of the patellofemoral joint in Down's syndrome. *J Bone Joint Surg* 68-A(3): 405-12, 1986.
- 3) Livingstone B, Hirst P: Orthopedic disorders in school children with Down's syndrome with special reference to the incidence of joint laxity. *Clin Orthop* 207: 74-6, 1986.
- 4) Mendez AA, Keret D, MacEwen GD: Treatment of patellofemoral instability in Down's syndrome. *Clin Orthop* 234: 148-58, 1988.
- 5) Merchant AC, Mercer RL, Jacobsen RH, Cool CR: Roentgenographic analysis of patellofemoral congruence. *J Bone Joint Surg* 56-A(7): 1329-6, 1974.
- 6) Palumbo PM: Dynamic patellar brace. A new orthosis in the management of patellofemoral disorders. A preliminary report. *Am J Sports Med* 9(1): 45-9, 1981.
- 7) Watanabe R, Akashi K, Morii S, Onoda T, Yasui K: A case of bilateral dislocation associated with Down's syndrome. *Knee* 12: 7-12, 1986.

和文抄録

ダウン症候群に合併した膝蓋骨脱臼に対する
有用な装具療法

松末 吉隆, 上尾 豊二, 山室 隆夫

ダウン症候群に合併した反復性脱臼に対して Palumbo 装具を装着し, 良好な結果を得た一症例を報告する. この疾患の治療に関して, 知能水準, 日常の活動性, 極度の肥満や他の内科的合併症を考慮することが

重要である. 膝蓋骨亜脱臼や整復可能な脱臼に対して, 早期に発見をしましてまず一次的に装具療法を行うことをすすめる.