

Title	<Clinical Studies>Cementation for the Giant Cell Tumor of Bone
Author(s)	MITSUNAGA, EIJI; SHIBATA, TAIHOH
Citation	日本外科宝函 (1993), 62(2): 116-124
Issue Date	1993-03-01
URL	<a href="http://hdl.handle.net/2433/203669">http://hdl.handle.net/2433/203669</a>
Right	
Type	Departmental Bulletin Paper
Textversion	publisher

---

臨 床

---

## Cementation for the Giant Cell Tumor of Bone

EIJI MITSUNAGA and TAIHOH SHIBATA

Department of Orthopaedic Surgery, Ehime University School of Medicine Ehime Japan

Received for Publication, Dec. 21, 1992

### Introduction

Giant cell tumor of bone (GCT) is a benign bone tumor pathologically. However, its local recurrence rate ranges from 40% to 60% when simple curettage and bone graft are performed, owing to its local aggressiveness<sup>4)</sup>. Due to an excessive fear of local recurrence, from the very onset of the detection of the GCT, resection arthrodesis, megaloprosthesis, osteoarticular allograft and alloarthroplasty, and, moreover, amputation may be indicated as in the case of a malignant bone tumor. Since GCT often occurs around the joint, loss of joint function will be inevitable with wide or radical procedures. As the aim in the management of GCT is to achieve good local control and to preserve joint function, several clinical investigations have been done<sup>6,9,10)</sup>. We have adopted the most reliable method of treatment, namely marginal extracapsular excision (using high-speed burr after simple curettage) followed by plugging with polymethylmethacrylate (PMMA)<sup>13)</sup>. This study reports our experience with eleven patients treated by marginal extracapsular curettage and cementation.

### Clinical materials and methods

We have adopted cementation following marginal extracapsular excision in eleven of fifteen cases from July 1986. Four cases indicated without cementation were as follows: a resection arthrodesis for the case aroused in the proximal femur, radiographically determined as grade III, a megaloprosthesis replacement after a wide excision for the case of GCT at the distal femur, a marginal excision and bone graft for the case occurred in the fifth lumbar vertebrae and its associated transverse process and a marginal extracapsular excision and bone graft for the case of GCT at the first cuneiform.

Of eleven cases, where cementation with extracapsular excision was performed, eight lesions occurred at the distal femur, two lesions at the proximal tibia and one lesion at the proximal humerus. There were six males and five females, and their ages ranged from 21 to 59 years of age with an average of 33 (Table 1). The second case was a recurrent one with simple curettage and bone graft.

---

Key words: Giant cell tumor of bone, Cementation, Polymethylmethacrylate, Effectiveness.

索引語: 骨巨細胞腫, セメント充填, ポリメタクリル酸メチル, 有用性.

Present address: Shigenobu-cho, Onsen-gun, Ehime 791-02 JAPAN.

Table 1 Patient list

Case	Age	Sex	Anatomic site	Histological Grade	Radiological Grade	S.S.S.	Follow up Period	Recurrence	Complication	Functional Evaluation
1. K. M.	21	F	dist. Femur	II	II	S2	72 mos	—	—	Excellent
2. T. TS.*	26	M	dist. Femur	II	III	S2	71 mos	—	—	Excellent
3. H. M.	59	F	dist. Femur	II	II	S2	69 mos	—	—	Fair
4. T. TN.	52	F	dist. Femur	I	I	S1	67 mos	—	—	Excellent
5. T. K.	33	M	dist. Femur	I	III**	S3	65 mos	—	—	good
6. N. I.	48	F	dist. Femur	II	II	S2	36 mos	—	fracture	Excellent
7. S. T.	28	M	dist. Femur	II	II	S2	35 mos	—	—	good
8. A. K.	22	M	prox. Humerus	II	III**	S3	23 mos	—	—	Excellent
9. K. S.	42	M	prox. Tibia	II	II	S2	11 mos	—	—	good
10. M. T.	47	F	prox. Tibia	II	II	S2	10 mos	—	—	Excellent
11. T. N.	41	M	dist. Femur	II	II	S2	8 mos	—	—	good

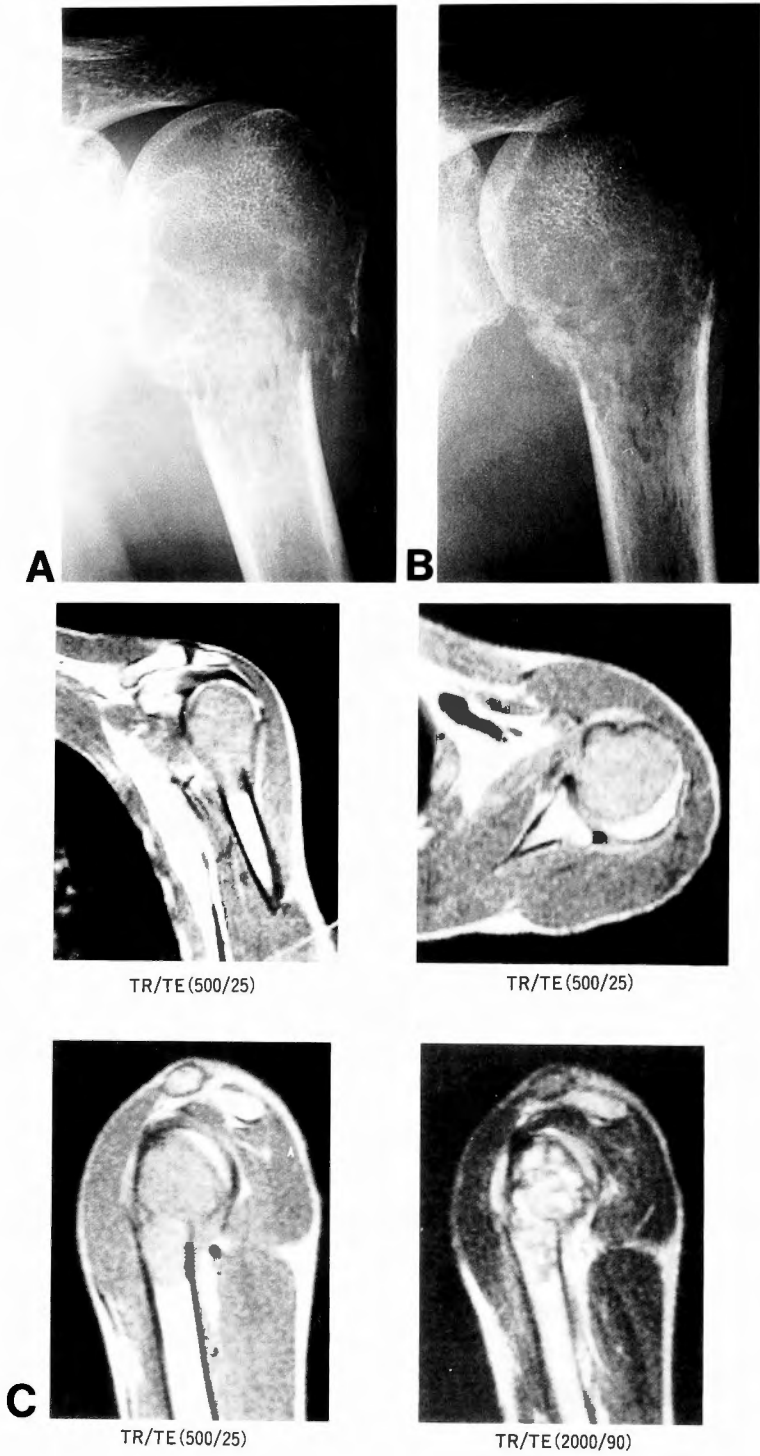
\*: recurrent case after curettage with bone graft

\*\* : associated with a pathologic fracture preoperatively

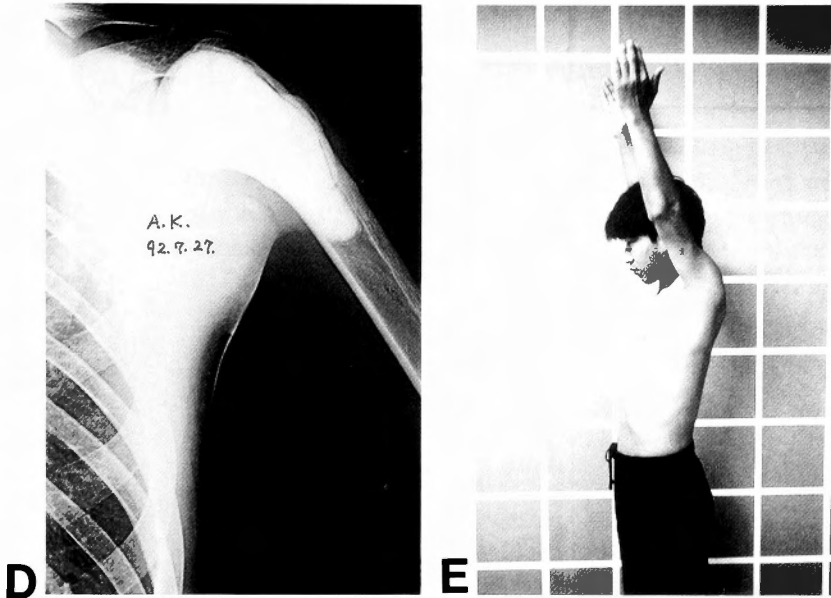
Table 2 Functional results according to a modified functional evaluation system

	Score Max=35	Motion	Pain	Stability	Deformity	Strength	Functional ability	Emotional acceptance
1.	35	5	5	5	5	5	5	5
2.	35	5	5	5	5	5	5	5
3.	23	5	3	1	1	5	3	5
4.	33	5	3	5	5	5	5	5
5.	31	5	3	5	5	5	3	5
6.	35	5	5	5	5	5	5	5
7.	31	5	3	5	5	5	5	3
8.	33	5	3	5	5	5	5	5
9.	31	5	5	5	5	5	3	3
10.	35	5	5	5	5	5	5	5
11.	31	5	3	5	5	5	3	5

Ave. 31.9



(Fig. 1 A-C)



**Fig. 1** Case 8. 22 year old male. GCT at the proximal humerus was associated with a pathologic fracture (A). However, a bony shell was considered to be preserved until the operation was performed (B). On MR imaging study, an extraosseous extension could not be determined (C). X-ray taken at 23 months after the operation reveals 2 mm radiolucent zone around the plugged cement (D). According to a modified functional evaluation system, this case was rated as excellent (E).

Although the fifth and the eighth case were associated with pathologic fractures at their initial visits to our hospital, bony shells were preserved until the operations were performed, and an extraosseous extension could not be determined by an MR imaging study (Fig. 1). Radiologically, according to *Campanacci's* classification<sup>1)</sup> in which one lesion was graded as grade I, three lesions were graded as grade III and seven lesions were graded as grade II. According to the surgical staging system<sup>4)</sup> one case was in s1, eight in s2 and two in s3. The mean follow-up period was 40.6 months with a range of 8–72 months.

Once the diagnosis of giant cell tumor was made, usually from a needle biopsy specimen, we evaluated the lesions according to *Campanacci's* classification and *Enneking's* surgical staging system. Besides *Campanacci's* grade III and *Enneking's* stage 3, we adopted marginal extracapsular curettage with cementation as the first treatment of choice. Even when the lesion was associated with a pathologic fracture, cementation was indicated if the bony shell was preserved. Marginal extracapsular curettage was achieved through a rectangular window placed into the overlying cortex, and intralesional excision of the tumor was performed using a curette followed by resection of a margin of normal bone using a high-speed burr. It was essential not to penetrate the joint cartilage and to use a high-speed burr in all directions in order not to leave a residual tumor. After the cavity was irrigated sufficiently with a saline solution and dried, it was hand-packed with PMMA. An intraoperative X-ray was taken to confirm whether penetration of PMMA into the joint or the extraosseous region had occurred. Postoperatively, a bulky compressive dressing was applied, and a continuous passive motion was started on the second day after surgery. A partial weight bearing was permitted one or two weeks after surgery.

## Results

We evaluated our results according to a modified *Enneking's* functional evaluation system<sup>5,15)</sup>. This system consists of seven factors, motion, pain, stability, deformity, strength, functional ability and emotional acceptance. Each factor was rated as follows; 5 points as excellent, 3 points as good, 1 point as fair and 0 points as poor. In our series, 6 were rated as excellent, 4 were rated as good and 1 was rated as fair. The score ranged from 23 to 35 with an average of 31.9 (Table 2). There was no local recurrence and no infection. Although one patient suffered from a pathologic fracture at the

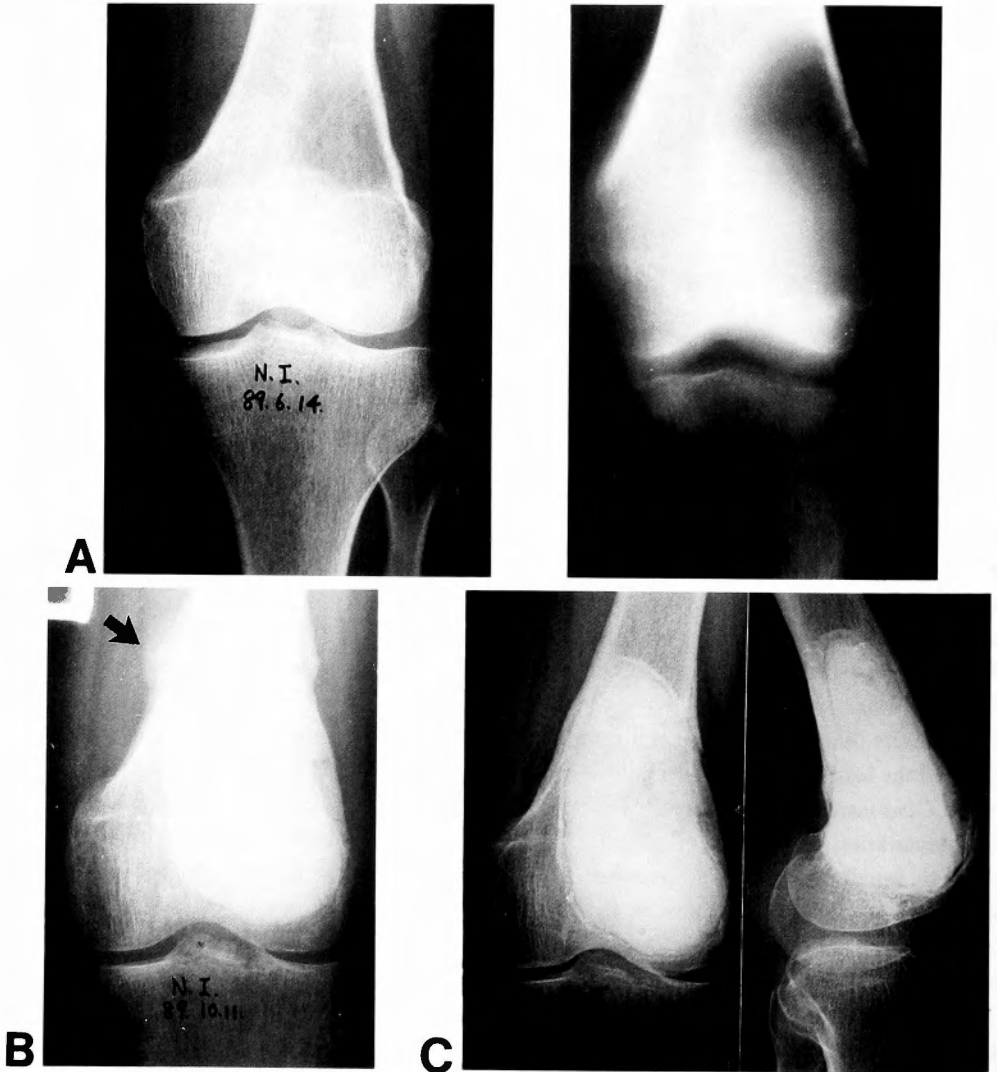


Fig. 2 Case 6. 48 year old female. GCT at the distal femur (A). Two months after the operation, this patient suffered from a pathologic fracture. A callus formation was visible on x-ray examination (arrow) (B). X-ray taken 36 months after the operation (C). According to a modified functional evaluation system, this case was rated as excellent.

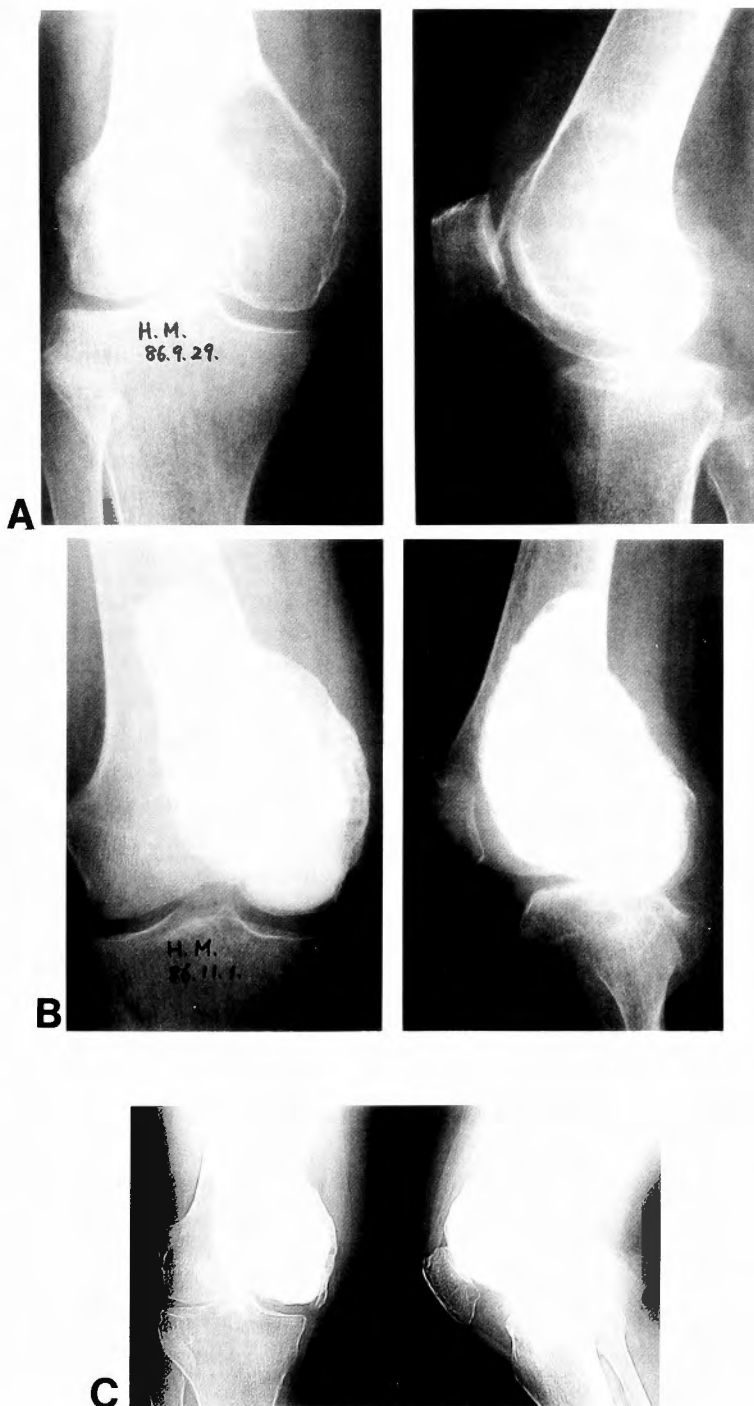

Fig. 3 Case 3. 59 year old female. GCT at the distal femur (A). X-ray taken immediately after the operation (B) and 69 months after the operation (C). A degenerative joint change was present, but did not progress after the operation.

upper part of the cementation, the fracture healed by conservative treatment (Fig. 2). In case 3, a degenerative joint change was present but did not progress after cementation (Fig. 3).

### Discussions

Due to the greater tendency of GCT to occur around the joint and due to its local aggressiveness, the aim of the treatment of GCT is to achieve good local control and preserve joint function. A number of alternative methods have been developed as an adjuvant management to achieve local control; for example, cryosurgery (liquid nitrogen), phenol/alcohol application, PMMA and laser have been tried. Since Vidal's first report on cementation for GCT, several authors<sup>10,16</sup> have used PMMA as fillers in the treatment of GCT. However, this technique had not gained wide-spread acceptance, partly because the physical properties of PMMA were believed to be only temporary substitutes for normal bone and not real, permanent ones. In 1985, at the third International Limb Salvage (ISOLS) Conference in Florida, functional results of the cementation procedure for GCT over two years were reported for 240 cases at several institutes<sup>2,3,7</sup> and were superior to those of wide en block excision. The local recurrence rate of curettage filling with PMMA was reported to range from 4.8% to 29.4%. In our small series, there was no local recurrence.

There are two major advantages of filling with PMMA into the curettaged cavity. One of them is to stabilize immediately the reconstructed defect including the subchondral region. The other is to have the possibility of increasing the surgical margin owing to PMMA's thermal or cytotoxic effects. Leeson<sup>9</sup> demonstrated experimentally that PMMA-related thermal necrosis could extend the surgical margin by 1-2 mm. Rock<sup>12</sup> stated that the monomer released by PMMA was cytotoxic which further increased the local necrosis, and the free radicals which additionally were released upon polymerization were toxic to lipid component of the cell. On the other hand, there are also disadvantages to using PMMA. Thermal necrosis results in increasing the risk of a pathologic fracture, particularly in large lesions. Moreover, one of our major concerns is to accelerate the degeneration of the articular cartilage through the damage to subchondral bone. However, fortunately in practice, there are few patients showing the evidence of osteoarthritis in large series with the longest follow-up periods<sup>11</sup>. In spite of our small series and short term follow-up, the progression of articular cartilage degeneration has not been evident.

Marginal extracapsular curettage with cementation for the treatment of GCT results in good local control, a low incidence of complications and satisfactory joint function. We recommend marginal extracapsular curettage with cementation as the treatment of choice for GCT, particularly for the cases in stage 1 and stage 2.

In summary, we reported eleven cases of giant cell tumors of bone which we treated by marginal extracapsular curettage and cementation. There was no local recurrence and no infection. Functional results were evaluated according to a modified Enneking's functional evaluation system where six were rated as excellent, four were rated as good and one was rated as fair. A postoperative pathologic fracture occurred in one case and, fortunately, healed by conservative treatment. In conclusion, we recommend this method of treatment as the first treatment of choice for these cases with stage 1 and stage 2 giant cell tumor of bone.



## References

- 1) Campanacci M, Giunti A and Olmi R: Giant cell tumours of bone. A study of 209 cases with long-term follow up in 130. *Ital. J. Orthop and Traumat.* 1: 249-277, 1975.
- 2) Camargo FP and Camargo OP: Surgical treatment of benign cavity bone lesions using methylmetacrylate cement and polyethylene prosthesis: Experience with 175 cases. in limb salvage in musculoskeletal oncology, pp 519-527, 1987.
- 3) Conrad EU, Enneking WF and Springfield DS: Giant-cell tumor treated with curettage and cementation, in limb salvage in musculoskeletal oncology, pp 516-519, 1987.
- 4) Enneking WF: A system of staging musculoskeletal neoplasms *Clin. Orthop.* 204: 9-24, 1986.
- 5) Enneking WF: A system for the functional evaluation of the surgical management of musculoskeletal tumors, in limb salvage in musculoskeletal oncology, pp 5-16, London, Churchill Livingstone, 1987.
- 6) Jacobs PA and Clemency RE: The closed cryosurgical treatment of giant cell tumor. *Clin. Orthop* 192: 149-158, 1985.
- 7) Johnston J: Treatment of giant cell bone tumors by aggressive curettage and packing with bone cement, in limb salvage in musculoskeletal oncology, pp 512-516, London, Churchill Livingstone, 1987.
- 8) Lesson MC, Lippitt SB and Makley JT: Thermal aspects of the use of polymethylmethacrylate in large metaphyseal defects in bone: A clinical review and laboratory study, in new developments for limb salvage in musculoskeletal tumors, pp 277-288, Springer-Verlag, Berlin, 1989.
- 9) Marcove RC, Weis LD, Vaghaiwalla MR and Pearson R: Cryosurgery in the treatment of giant cell tumors of bone.: A report of 52 consecutive cases. *Clin. Orthop.* 134: 275-289, 1978.
- 10) Persson BM and Wouters HW: Curettage and Acrylic cementation in surgery of giant cell tumors of bone. *Clin. Orthop.* 120: 125-133, 1976.
- 11) Persson BM, Rydholm A, Berlin O and Gunterberg B: Curettage and acrylic cementation in surgical treatment of giant-cell bone tumors, in limb salvage in musculoskeletal oncology, pp 476, Churchill Livingstone, London, 1987.
- 12) Rock M: Adjuvant management of benign tumors; basic concepts of phenol and cement use. *Chir. Organi Mov.*, LXXV, Suppl. N. 1.: 195-197, 1990.
- 13) Shibata T, et al: Rationale and effectiveness of bone cement plugging for giant-cell tumor of bone (in Japanese). *Cent. Jpn. J. Orthop. Traumat.* 31: 177-179, 1988.
- 14) Surg HW, et al: Giant-cell tumor of bone: analysis of two hundred and eight cases in chinese patients. *J Bone and Joint Surg* 64-A: 755-761, 1982.
- 15) Tomita K and Tuchiya H: Functional evaluation of limb salvage surgery in osteosarcomas. *M.B. Orthop.* 27: 85-90, 1990 (in Japanese).
- 16) Willert HG, Enderle A: Temporary bone cement plug: An alternative treatment of large cystic tumorous lesion near the joint. In Kotz R: The proceedings: 2nd International workshop on the design and application of tumor prostheses for bone and joint reconstruction. Vienna, Egerman Druckereigesellschaft: 69-72, 1983.

## 和文抄録

## 骨巨細胞腫に対する CEMENTATION の経験

愛媛大学医学部 整形外科

光長 栄治, 柴田 大法

骨巨細胞腫は、病理学的には良性であるが、その局所における aggressive さに加え、まれに転移をおこすこともあり、その生物学的態度は必ずしも良性とはいえない。また、関節近傍に発生することから、治療法の選択に迷うことも少なくない。我々は、1986年から主として stage 1, 2 の GCT に対して CEMENTATION を施行してきたが、今回その術後成績を評価しその有用性について検討した。対象は、11例の GCT で、男 6例、女 5例であり、発生部位は大腿骨遠位 8例、脛

骨近位 2例、上腕骨近位が 1例であった。術後経過観察期間は 8ヶ月から 72ヶ月、平均 42ヶ月であった。術後機能評価を Enneking の modified functional evaluation system を用いて行った。excellent 6例、good 4例、fair 1例であり、また、合併症としては、術後に 1例骨折がみられたが、保存療法で治癒した。少数のシリーズであり、経過観察期間も長期ではないが、CEMENTATION は stage 1 および stage 2 の GCT に対する第一選択の治療法であると評価できた。