

| | |
|-------------|---|
| Title | <Case Report>Complete Obstruction of the Inferior Vena Cava due to Chronic Relapsing Pancreatitis : A Case Report |
| Author(s) | OHNO, TETSUYA; TAKABAYASHI, ARIMICHI; MAKI, ATSUHIKO; USUI, YUJI; TAKEUCHI, KATSUMI; KOHNO, SHIGENE |
| Citation | 日本外科宝函 (1994), 63(6): 215-220 |
| Issue Date | 1994-11-01 |
| URL | http://hdl.handle.net/2433/203645 |
| Right | |
| Type | Departmental Bulletin Paper |
| Textversion | publisher |

Complete Obstruction of the Inferior Vena Cava due to Chronic Relapsing Pancreatitis: A Case Report

TETSUYA OHNO, ARIMICHI TAKABAYASHI, ATSUHIKO MAKI
YUJI USUI, KATSUMI TAKEUCHI AND SHIGENE KOHNO*

Kitano Hospital, Tazuke Kohfukai Medical Research Institute Department of Surgery and Radiology*;
13-3 Kamiyama-cho, Kita-ku, Osaka, 530, Japan

Received for Publication, August. 16., 1994

Abstract

A woman aged 62 with long history of chronic relapsing pancreatitis presented with swelling and ulcer in the lower limbs and occasional gastrointestinal bleeding. The radiological imaging showed complete obstruction of Inferior Vena Cava (IVC) at the level of the pancreas and well developed collateral vessels. Portal vein and splenic vein were also obstructed and superior mesenteric venous blood drained into the liver via coronary vein. She was originally found to have pancreas head tumor, which was not resectable. A palliative operation was performed, but histological examination of pancreatic specimen suggested only chronic inflammation and no evidence of malignancy. She was diagnosed as tumor-forming type chronic pancreatitis.

Although SPV or SMV-PV obstruction has been recognized as a complication of chronic pancreatitis, IVC obstruction can occur by the same mechanism. This is the only case but one ever reported.

Not only splenoportography but IVC-graphy will contribute to more precise understanding of patient's condition with chronic pancreatitis.

Case report

A 59 year old previously healthy woman was hospitalized in February of 1990, complaining of occasional vomiting. She had no symptoms suggesting chronic pancreatitis and no habitus of alcohol nor drug abuse, but on physical examination, a large ill-defined abdominal mass was palpable at the right side of the abdomen. Results of laboratory test were as followed: serum amylase 65 IU/L, urinary amylase 130 IU/L, elastase-1,600 mg/dl (normal < 400 mg/dl). Upper gastrointestinal series gave the stricture of the 3rd portion of the duodenum. A subsequent computed axis tomographic (CAT) scan with contrast medium showed large enhanced lesion at the pancreas head. Spleno-portal vein was intact and no evidence of extrapancreatic tumor could be demonstrated. At laparotomy in May of 1990, She was noted to have a tumor of 7 cm in diameter at the head of pancreas with severe swelling of regional lymph nodes, part of which involved transverse mesocolon.

Key words: Chronic relapsing pancreatitis, Splenic venous obstruction, Portal venous obstruction, IVC obstruction, Gastrointestinal bleeding

索引用語: 慢性膵炎, 脾静脈閉塞, 門脈閉塞, 下大静脈閉塞, 消化管出血

Present address: Grand demeure Kitashirakawa 403 Higashikubota-cho 25 Kitashirakawa Sakyo-ku Kyoto 606.

Laboratory findings during the period of gastrointestinal bleeding

| | Transfusion (CRC) (ml) | S-Amy (IU/L) | U-Amy (IU/L) | Elastase I (ng/dl) | BUN (mg/dl) | Cr. (mg/dl) | Ca (mEq/L) | LDH (WU) | GOT (KU) | GPT (KU) |
|------------------------|------------------------------|-----------------|-----------------|-----------------------|----------------|----------------|---------------|-------------|-------------|-------------|
| | | 50~220 | 60~840 | 100~400 | 8.0~20.0 | 0.4~1.1 | 4.3~5.5 | 50~400 | 8~40 | 5~30 |
| 1st. (1991 7/16) | 1200 | 559 | | | 41.6 | 1.3 | 3.8 | 320 | 10 | 7 |
| 2nd. (1991 10/15) | 1000 | 234 | 560 | 820 | 42.7 | 1.1 | 4.1 | 241 | 11 | 10 |
| 3rd. (1992 4/18) | 1000 | 319 | 504 | 1100 | 25.8 | 1.4 | 4.4 | 241 | 12 | 5 |
| 4th. (1993 1/26) | 1000 | 236 | | 280 | 50.6 | 0.93 | 3.8 | 222 | 13 | 13 |

Table 1

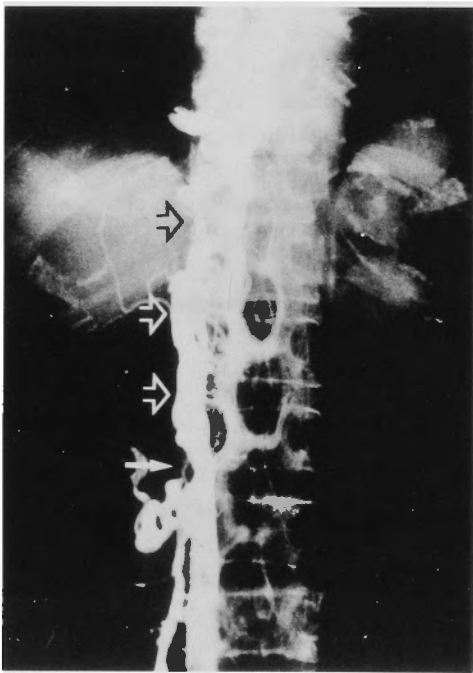


Fig. 1 left

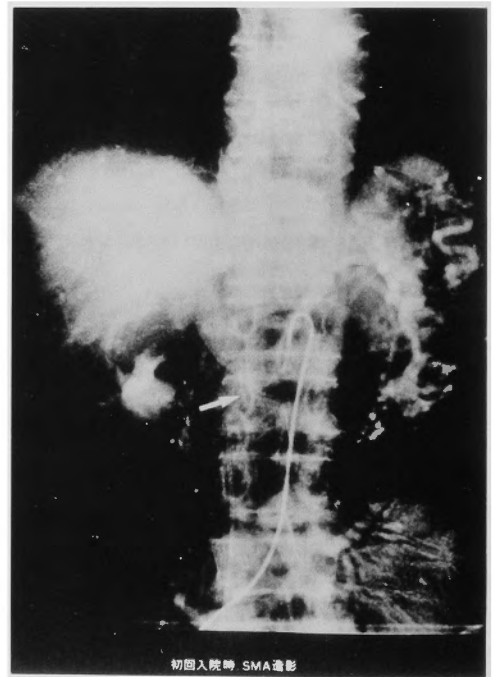


Fig. 1 right

Fig. 1 IVC-ography (left) and portal phase in superior mesenteric arteriography. (right)

- a) IVC was completely obstructed at the level of the 2nd. lumbar vertebra. (arrow) Collateral vessels were well developed and venous blood flowed back to SVC via azygos vein. (open arrow)
- b) Both portal and splenic vein were also obstructed at the same vertebral level (arrow) and coronary vein as collateral was well developed.

We diagnosed it as unresectable pancreas head tumor according to operative findings and performed a palliative operation, in which cholecystojejunostomy and gastrojejunostomy were made by the Roux-en-Y procedure. Intra-operative biopsy specimen on frozen section from pancreas and lymph nodes, however, revealed no malignant change. At the post-operative microscopic examination, also, no malignant cells and only non specific chronic inflammation with fibrosis were recognized

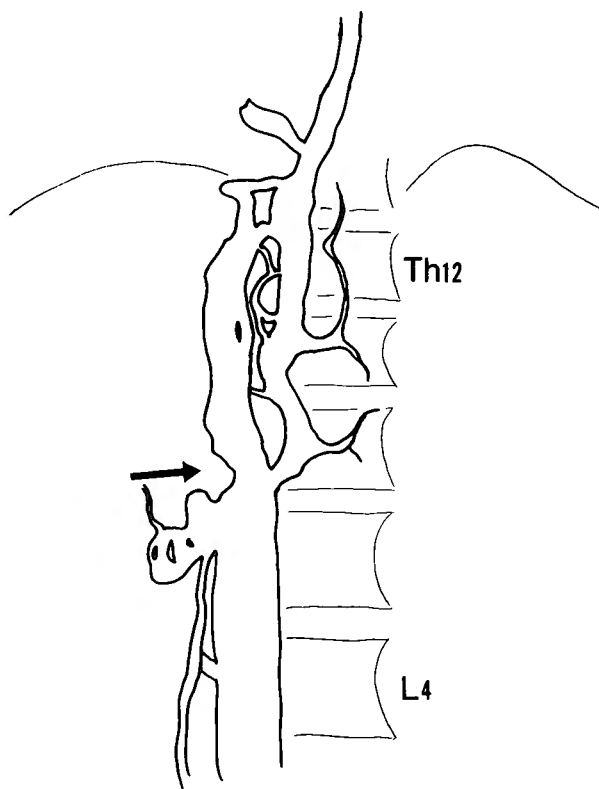


Fig. 1

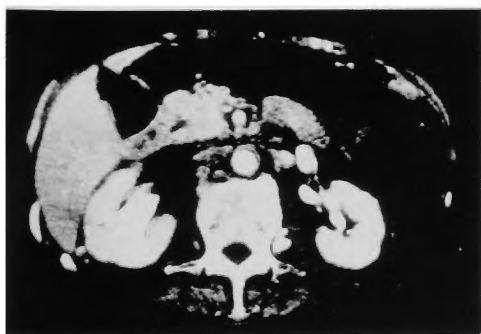

Fig. 2 left

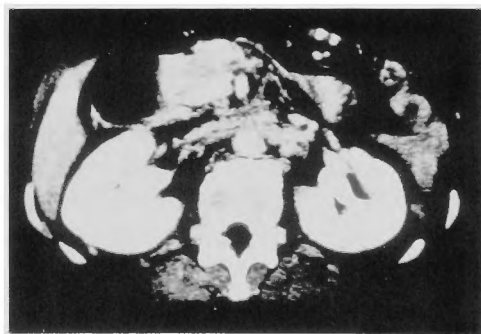


Fig. 2 right

Fig. 2 Computed axis tomographic (CAT) scan with contrast medium showed large enhanced mass lesion at the pancreas head in February of 1990. (left) But this lesion disappeared in January of 1993. (right)

from biopsy specimen and the tumor was diagnosed finally as tumor-forming type chronic pancreatitis.

After the operation the patient made an uneventful recovery. We have been observing her on outpatient basis. During the following three years, the patient suffered 4 times of episodes of massive hematemesis and melena, and was admitted on emergency. Each time with relapsing symptoms of pancreatitis, Serum level of pancreatic enzymes tended to elevate as shown on Table 1. Angiographic imaging study revealed no evidence of A-V malformation in the gastrointestinal tract. At upper gastrointestinal endoscopic examination, neither gastroesophageal varices nor peptic ulcer could be found, but anastomotic site of gastrojejunostomy showed extremely reddened and congestive mucous membrane and was very liable to bleeding. Submucosal venous dilatations were also present at jejunal side of anastomosis. Slight contact with endoscope easily caused bleeding and we presumed that this site was the bleeding point. Each episode of gastrointestinal bleeding needed transfusion of 5 or 6 packs of concentrated red cell but conservative therapy such as fasting for at least five days, and H₂-blocker infusion (400 mg/day of cimetidine) was sufficient.

In September of 1992, she complained about swelling and ulcer of the lower limb. We performed angiographic examination for visceral organs during the last admission and its findings are showed in figure 1. Both portal and splenic vein were completely obstructed at the level of 2nd lumbar vertebra, where corresponding to the site of the pancreas and superior mesenteric venous blood drained into the liver via coronary vein. No varices formation could be detected on this angiographic series. On IVC-graphy, IVC was completely obstructed at the same level of vertebra and collateral vesseles via azygos vein were well developed. Lower limb ulcer was improved by rest and deterioration of swelling has not been observed at present.

Endoscopic retrograde cholangiopancreatography demonstrated slightly dilated main pancreatic duct and its branches, and wall irregularity, consistent with chronic pancreatitis. No enhanced mass lesion was detected on CAT scan in January of 1993. She has had no further problemes in the 6 months of follow up after the last admission.

Discussion

Visceral veno-occlusive change as a complication of chronic pancreatitis may be associated with serious life threatening symptoms. Splenoportal venous abnormality was first described by Rignault et al. in 1968¹⁾. They began using splenoportography in patients with pancreatic disorders as a diagnostic aid and unsuspectedly found a relatively great number of cases with this vascular abnormalities.

In the same year, Leger et al. also found that 54% of patients with pancreatitis had abnormal splenoportagrams and 24% had complete obstruction of splenic vein²⁾.

In 1971, G. F. Longstreth et al. reported 5 patients with extrahepatic portal hypertension caused by chronic pancreatitis and revealed partial or total portal system obstruction in all cases³⁾.

Little and Moossa reported 16 cases of splenic vein occlusion in 92 patients with acute or chronic pancreatitis⁴⁾. Recently, Bernades et al. described that the incidence of splenoportal venous obstruction was 13.2% in their prospective study of 266 patients who met the criteria of chronic pancreatitis⁵⁾.

On the other hand, analogous occlusion of the superior mesenteric and/or portal veins (SMV-PV) in patients with proved chronic pancreatitis without cancer was reported by A.L. Warshaw et

Incidence of Visceral veno-occlusive change due to chronic pancreatitis

| | | number of reported cases | | | |
|--------------------|------|--------------------------|----|----|-----|
| | | sum | SV | PV | IVC |
| Rignaut et al. | 1968 | | 19 | 1 | 0 |
| Leger et al. | 1968 | 126 | 69 | | 0 |
| Longstreth et al. | 1971 | | 5 | | 0 |
| Little, Moossa | 1981 | 92 | 16 | | 0 |
| A.L.Warshaw et al. | 1987 | | | 14 | 0 |
| C.Peillon et al. | 1991 | | | | 1 |
| Bernades et al. | 1992 | 226 | 22 | 13 | 0 |
| Our case | 1993 | | | | 1 |

SV: Splenic vein, PV: Portal and/or superior mesenteric vein, sum: number of studied cases

al.⁶⁾

In our case, not only splenoportal vein (SPV) but IVC has been completely obstructed. It is suggested that the medication for chronic pancreatitis in this case has been somehow insufficient on outpatient basis. The incidence of pancreatitis-associated IVC change is unknown. Complete obstruction of IVC due to chronic relapsing pancreatitis has been reported for the first time in 1991 by C. Peillon et al.⁷⁾ We believe that this case is the second one and very rare, and during the natural course of chronic pancreatitis, IVC could be obstructed by the same mechanism for splenoportal venous obstruction.

The cause of SMA-PV and/or SPV obstruction has been described as fibrosis, acute inflammation (acute exacerbation of chronic pancreatitis) which may be responsible for intimal injury and venous thrombosis, and a pseudocyst which may compress veins^{3,5,6,8)}. In the case reported by C. Peillon et. al. IVC obstruction was secondary to the pancreatic pseudocyst. In our case, no pseudocyst was recognized. We conclude that long-termed inflammation due to chronic relapsing pancreatitis and probable repeated acute exacerbation has extended even to IVC and caused its complete obstruction. These visceral veno-occlusive changes as a complication of chronic relapsing pancreatitis result in local portal or visceral venous hypertension and may be associated with serious life threatening symptoms such as massive gastrointestinal bleeding.

References

- 1) Rignault D, Mine J, Moire D: Splenoportographic changes in chronic pancreatitis. *Surgery* 1968; 63: 571-575.
- 2) Leger L, Lenriot JP, Lemaigre G: L'hypertension et la stase portales segmentaires dans les pancreatites chronique; A propos de 126 cas examines par splenoportographie et spleno-manometrie. *J Chir* 1968; 95: 599-608.
- 3) Longdstreth GF, Newcommer AD, Green PA: Extrahepatic portal hypertension caused by chronic pancreatitis. *Ann Intern Med* 1971; 75: 903-908.
- 4) Little AG, Moossa AR: Gastrointestinal hemorrhage from left-sided portal hypertension. *Am J Surg* 1981; 141: 153.
- 5) Bernades P, Baetz A, Levy P et al.: Splenic and Portal venous obstruction in chronic pancreatitis. *Dig dis Sci* 1992; 37 No.3, 340-346.
- 6) Warshaw AL, Gongliang J, Ottinger LW: Recognition and clinical implication of mesenteric and portal vein obstruction in chronic pancreatitis. *Arch Surg* 1987; 122: 410-415.
- 7) Peillon C, Manouvrier JL, Testart J: Inferior Vena Cava thrombosis secondary to chronic pancreatitis with

pseudocyst. Am J Gastroenterol 1991; 86: 1854-1856.

8) Moossa AR, Gadd M.A Isolated splenic vein thrombosis. World J Surg 9: 384-390, 1985

和文抄録

慢性膵炎による下大静脈の完全閉塞をみた一例

北野病院 田附興風会医学研究所 外科, 放射線科*

大野 哲哉, 高林 有道, 薄井 裕治

牧 淳彦, 竹内 勝美, 光野 重根*

切除不能な膵頭部癌の疑いで胃空腸吻合, 胆嚢空腸吻合を施工し, 病理組織診断で腫瘤形成性慢性膵炎と判明した症例が, いわゆる chronic relapsing pancreatitis の経過をとり, 慢性膵炎の憎悪にともない吐

下血をくりかえし, 更に, 下肢の腫張と潰瘍を来した. 血管造影にて, 下大静脈の完全閉塞が認められ, 非常に稀な症例と考えられた.