

Title	<Original Articles>Posterior Proctomucosectomy and Ileal Pullthrough Reconstruction : A New Restorative Procedure after Total Proctocolectomy
Author(s)	MAETANI, SHUNZO; ONODERA, HISASHI; PARK, TAE BUN; IKEUCHI, DAISUKE; FURUYAMA, HIROAKI; UMEYAMA, SHIN; YONEZAWA, KEI; MURAO, NAOKO; MANABE, TADAO; IMAMURA, MASAYUKI
Citation	日本外科宝函 (1994), 63(5): 163-172
Issue Date	1994-09-01
URL	<a href="http://hdl.handle.net/2433/203643">http://hdl.handle.net/2433/203643</a>
Right	
Type	Departmental Bulletin Paper
Textversion	publisher

---

原 著

---

## Posterior Proctomucosectomy and Ileal Pullthrough Reconstruction: A New Restorative Procedure after Total Proctocolectomy

SHUNZO MAETANI, HISASHI ONODERA, TAE BUN PARK, DAISUKE IKEUCHI,  
HIROAKI FURUYAMA, SHIN UMEYAMA, KEI YONEZAWA, NAOKO MURAO,  
TADAO MANABE, and MASAYUKI IMAMURA

First Department of Surgery, Faculty of Medicine, and Research Center for Biological Engineering, Kyoto University

Received for Publication, August 4., 1994

### Summary

We reported a new method of restorative proctocolectomy using posterior approach and pull-through reconstruction. This method obviated transanal manipulation, a major factor causing damage to the internal sphincter, thus preventing fecal incontinence due to sphincter dysfunction. Also, temporary ileostomy was not necessary because the spout of an S-pouch was pulled down below the anal verge and its distal free end acted as a diverting stoma while the more proximal, healing zone (future anastomotic line) was kept from fecal contamination. This method was applied to a 32-year-old woman with familial polyposis coli and a 50-year-old woman with ulcerative colitis. Their bowel movements steadily decreased to three times and five times a day, respectively. There was no fecal leakage or perianal excoriation. The advantages as well as disadvantages of this method compared with the conventional techniques were discussed.

### Introduction

Although anastomosis of the ileal pouch to the anal canal has become the procedure of choice after total proctocolectomy for benign lesions, many problems have yet to be settled, such as technical complexities, fecal leakage, need of temporary ileostomy and its complications<sup>1-7)</sup>. In an attempt to solve these problems, we have developed a new method using posterior dissection and pull-through reconstruction without endoanal anastomosis and covering colostomy. Although thus far this method has been tried in only two cases, the results have been excellent. Therefore, our operative method as well as its background is described in this paper.

---

Key words: Restorative proctocolectomy, Posterior proctomucosectomy, Ileoanal pull-through method, Familial polyposis coli, Ulcerative colitis

索引用語: 括約筋温存式結腸直腸切除, 経後方直腸粘膜切除, 回腸肛門貫通術式, 家族性結腸腺腫症, 潰瘍性大腸炎.

Present address: Research Center for Biological Engineering, Kyoto University, Shogoin Kawahara-cho 53, Sakyo-ku, Kyoto 606, Japan.

### Operative method

With the patient placed in a lithotomy position the abdomen is entered through a mid-line incision. Proctocolectomy is performed in the usual manner. The rectum is transected below the peritoneal reflection.

An ileal S-pouch is constructed using the Parks method<sup>4)</sup>. However, more extensive mobilization of the terminal ileum is necessary so that the ileal end extends 10 cm below the pubic symphysis. The mobilized ileum is folded into three limbs each measuring 12 to 15 cm in length while the distal limb has additional 5 cm of free end (spout). The middle limb is opened on its antimesenteric border while both lateral limbs are longitudinally incised along their medial sides so that the mesenteric attachments of all limbs lie on the same side of the pouch. The S-pouch is completed by two-layer continuous sutures of 3-0 polyglactin joining the adjacent cut-edges as well as both outermost edges (Fig. 1). Special care should be taken not to leave a septum between the spout and pouch which may prevent evacuation of the pouch. After the pouch is brought to the pelvic cavity and the remaining intestinal loops are returned to their proper positions, the abdomen is closed and the patient is turned to a prone jackknife position.

A midline incision is made extending from 4 cm above the sacrococcegeal junction to 2 cm above the anal verge. The coccyx and the lowermost sacral segment are exposed. After their lateral edges are freed from muscular and ligamentous attachment, the bones are resected en bloc by dividing the sacral segment obliquely with a chisel. A longitudinal incision is then made in the underlying endopelvic fascia and the pelvic cavity is entered. The rectal stump is easily seen. Otherwise, it can be identified by inserting the index finger through the anus (Fig. 2). About 5 mm below its stapled end a circular incision is made in the muscular coat of the rectum without entering the lumen, exposing the underlying submucosal layer. This incision is joined by a vertical incision along the posterior midline of the rectal stump extending down to the upper border of the puborec-

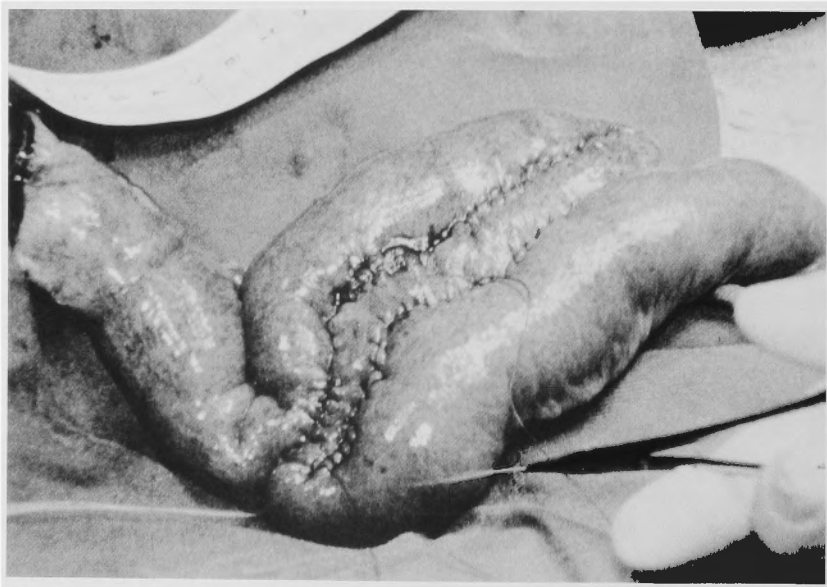
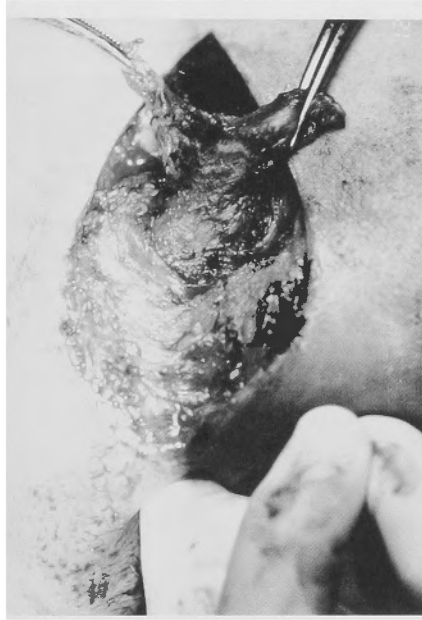
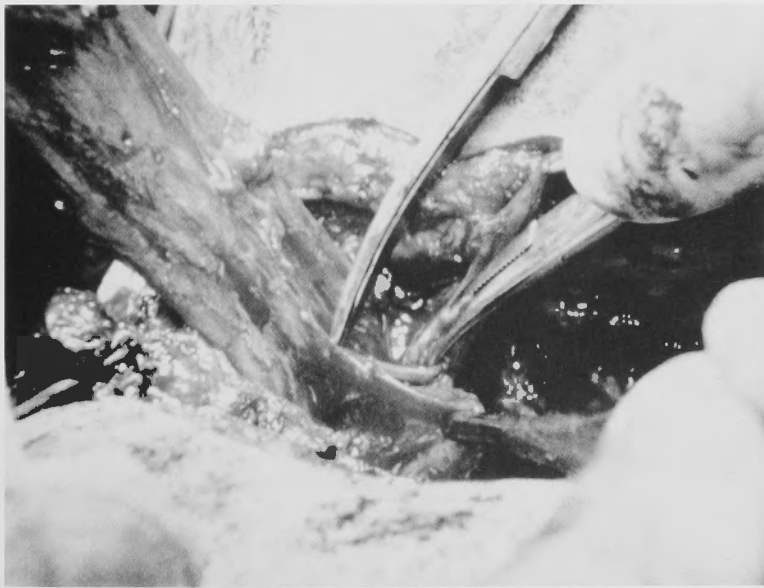
Fig. 1 Creation of an S-pouch.

talis muscle. Starting from these T-shaped incisions, the mucosa is dissected away from the muscular coat and from the internal sphincter using Metzenbaum scissors and bipolar electrocautery (Fig. 3). Even though the plane of dissection can be controlled under direct vision as well as by the



**Fig. 2** Posterior approach of the rectal stump which is defined by the index finger in the rectal lumen while its proximal cut-end is grasped by two forceps.



**Fig. 3** Dissection of the mucosa from the muscularis propria and the internal sphincter while the mucosal tube is pulled posteroinferiorly.

finger in the rectal lumen, the mucosa may be often perforated during this tedious procedure. However, mucosal injuries are harmless unless epithelial islets are left behind. The dissection is completed when the upper border of the columns of Morgani is reached in its entire circumferences. This is confirmed when the mucosal tube is pulled down and turned inside out (Fig. 4). The redundant end of the mucosal tube is then resected.

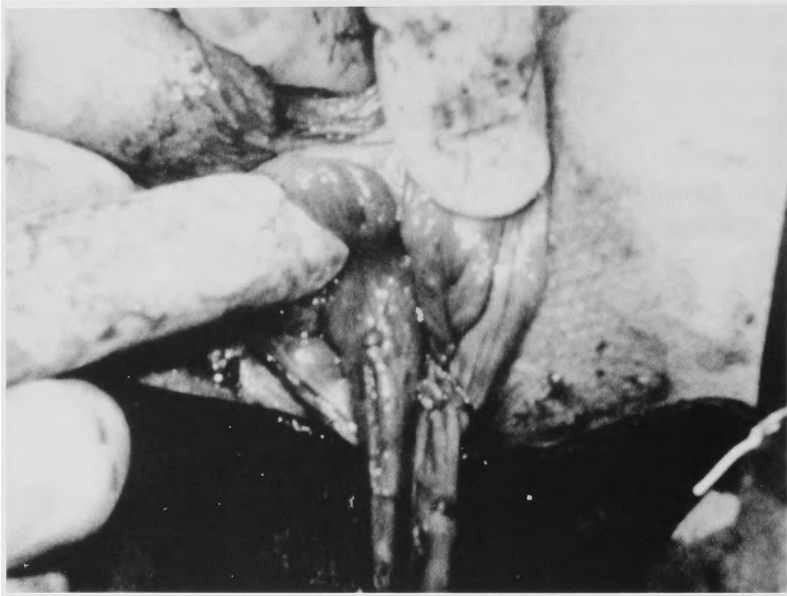

Fig. 4 The mucosal tube is pulled down through the anus and turned inside out, showing the columns of Morgani.

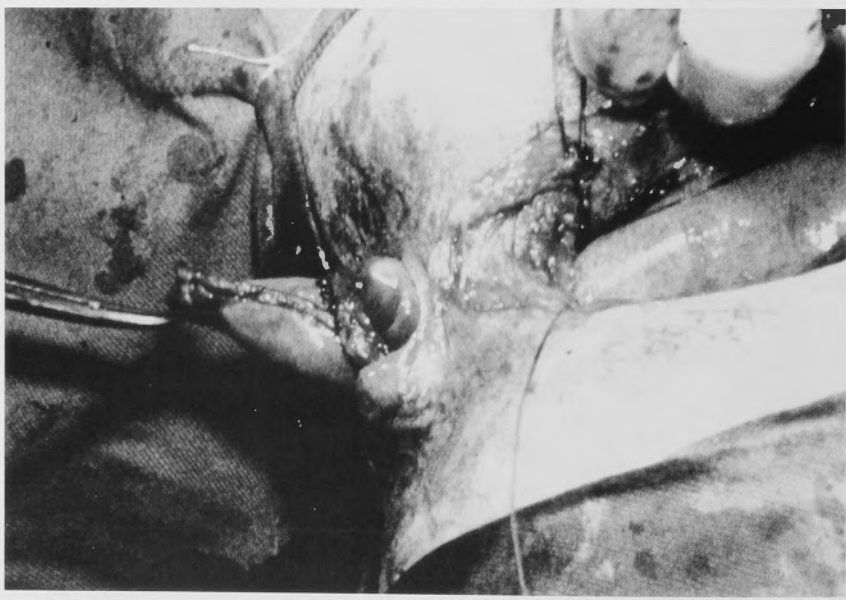
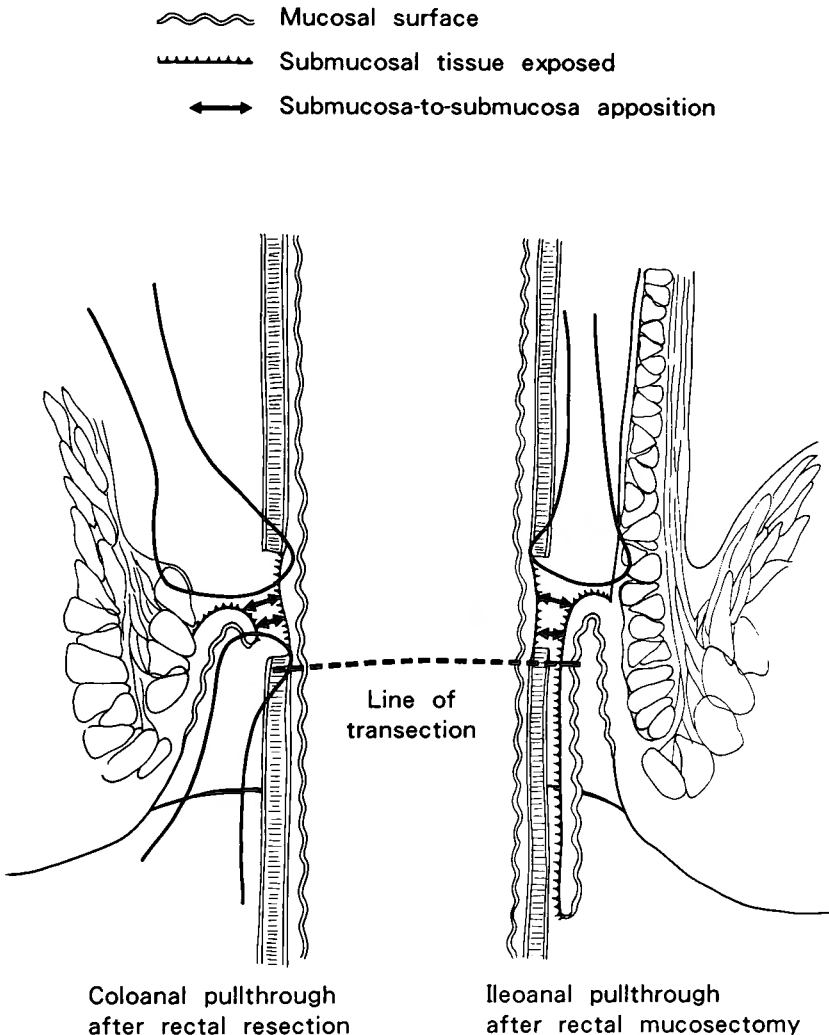


Fig. 5 The ileal spout is pulled out through the anal mucosal tube which is turned inside out.

Through this mucosal tube turned inside out, the ileal spout is tentatively pulled out as far as possible and the anastomotic level of the spout is determined, which corresponds to the site of mucosal reflection, i.e., the lower border of the mucosal tube and should be within 3 cm from the base of the spout. After the spout is pulled back, a circular incision is made in the seromuscular coat of the spout at the anastomotic level, allowing the underlying submucosa to bulge while meticulous care is taken not to enter the ileal lumen. The submucosal ring is completed by creating a tunnel through the mesenteric attachment. Starting from the most anterior point (or the deepest point), 3-0 polyglactin sutures are placed through the internal sphincter immediately above the anal



**Fig. 6** Schematic drawing of our pull-through method. The submucosa of the pull-through intestine is brought into direct contact with its counterpart above the line of future transection. The ileal pullthrough method (right) is compared with the colonic pull-through (left). In both methods, the anal mucosal cuff is reflected so as to facilitate submucosa-to-submucosa approximation as well as to prevent upward migration of anal mucosal cells.

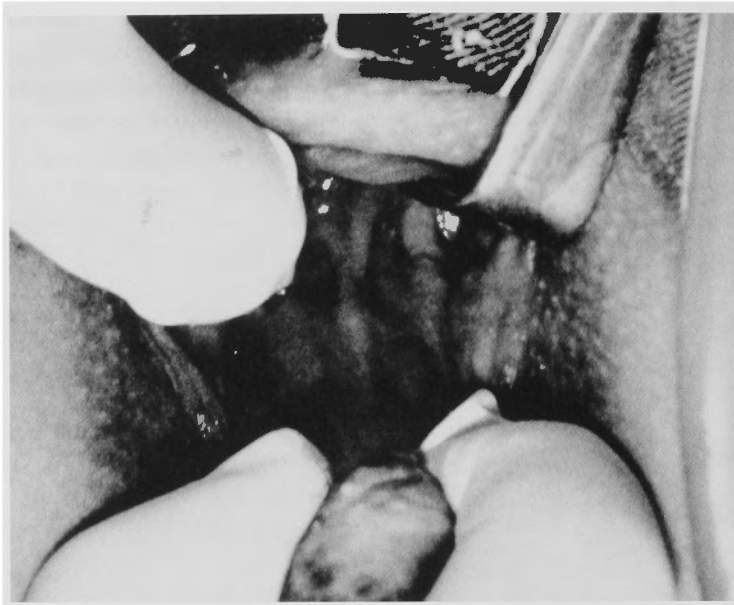

Fig. 7 Complete healing occurs between the ileal spout and the anal mucosal cuff which has been turned inside out.

mucosal reflection and are then passed through the corresponding point of the proximal seromuscular edge of the spout. After a total of five sutures are placed in the anterior (or deeper) half, the spout is again delivered gently through the anal canal (Fig. 5) and the sutures are tied from anteriorly to posteriorly. In the similar manner, the posterior (or superficial) half of the anastomosis is carried out. After completion of the anastomosis, the submucosal ring of the ileum is brought into direct contact with the back (submucosal side) of the anal mucosal cuff as well as with the internal sphincter (Fig. 6). As will be discussed later, this submucosal contact provides the most favorable condition for anastomotic healing.

After two closed suction drains are placed around the spout, the posterior incision is closed in layers. To decompress the pouch and prevent soiling of the anastomosis with ileal contents, a 24-Fr Foley catheter is inserted into the pouch through a small opening in the stapled end of the spout and the opening is tightly closed with a purse-string suture.

Total parenteral nutrition is given during the first two postoperative weeks, and special care is taken to prevent hemoconcentration or hypovolemia which may compromise perfusion of the ileal spout.

In two to three weeks later, healing occurs between the anal mucosal cuff and the spout (Fig. 7) so that free end of the spout is divided together with its mesentery immediately distal to the anal mucosal reflection. Bleeding from the cutend is controlled by sutures or electrocautery.

### Case reports

The first patient treated was a 32-year house-wife with familial polyposis coli and Dukes B cancer in the ascending colon. On January 23, 1992, she underwent restorative proctocolectomy, followed by ileal stump resection three weeks later. Postoperatively, the ileal pouch had to be in-

tubated and decompressed every two days because of fecal retention. On February 23, 1992, using the same posterior approach, the septum separating the pouch and the spout was divided. There after, the postoperative course was smooth. Her average bowel movements have decreased steadily with time, being 10 in April, 6 in July, 4 in August and 3 in October with little day-to-day variations. She does not experience fecal soiling or perianal irritation and wears no pad during day or at night. She has gained 5 kg of body weight since the operation, and is now enjoying good health.

The second patient was a 50-year-old house-wife with 7-year history of ulcerative colitis treated with prednisolone and salazosulfapyridine. The operation was performed on December 17, 1992. After the patient was turned to a prone jackknife position, It was found that the end of the ileal spout did not extend beyond the anal verge. An attempt to pull down the pouch resulted in tearing of a mesenteric vein, necessitating relaparotomy and anastomosis of the mesenteric vein to the ovarian vein. Since the inflammatory contraction was found to involve the anal canal and did not allow the spout to freely pass through it, ileoanal submucosa-to-submucosa apposition was made near the end of the spout which was left within the anal canal. Twelve days after the first operation there was purulent discharge from the intrapelvic drain so that temporary ileostomy was created. It was closed on September 21st, 1993 when inflammatory changes of the anal canal subsided. Nine months there-after, her bowel movements decreased to 5 times a day with no leakage or skin excoriation. She also is in good health.

### Discussion

There have been increasing reports that stretching of the sphincter which is unavoidable during transanal manipulation is an important factor contributing to fecal incontinence due to damage to the internal sphincter<sup>9-13</sup>). The incidence of incontinence is lower with transabdominal dissection compared with transanal mucosectomy<sup>9</sup>) as is so with the use of a stapler<sup>9,10,12-15</sup>) compared with endoanal hand-sewn anastomosis. The excellent fecal control in our cases might be ascribed to the avoidance of transanal manipulation. However, our method has additional advantages over the abdominal and transanal approaches. It is our impression that abdominal resection of the rectum becomes increasingly difficult as the line of resection is more close to the dentate line, requiring remote dissection under limited visual control. Moreover, the actual line of resection tends to deviate from the predetermined level. Such an error is also caused by the use of a stapler.

The posterior approach offers generous exposure permitting precise dissection under good visual control. If necessary, the dissection can be guided by the finger in the rectum. Moreover, the injuries of the levator muscles and extrinsic nerves are minimal since the extrarectal tissues are divided along the midline. Thus far, we have performed posterior dissection in 137 patients including those with low rectal cancer (93), anal cancer (5), recurrent rectal cancer (25), carcinoid tumor (3), villous adenoma (6), radiation proctitis (3) and solitary ulcer syndrome (2). Of these, 31 patients had rectal reconstruction which was always performed without covering colostomy. None of them developed fecal fistula and three had wound infection which healed with conservative management. An only problem commonly encountered was pain in the coccegeal region, which occasionally lasted over a month, but always disappeared except in patients with recurrent cancer.

As for reconstruction, our pull-through technique differs from the conventional methods<sup>16-20</sup>) in that we perform submucosa-to-submucosa approximation. The important role of the submucosa in intestinal anastomosis was first pointed out by HALSTEDT<sup>21</sup>) who claimed that the submucosa endow-



ed the bowel wall with mechanical power strong enough to hold sutures. On the contrary, our concept is that the submucosa, composed of loose connective tissue, is physically weak; however, with its rich vasculature, it exhibits most active fibrovascular proliferation during intestinal healing<sup>22</sup>). It is with this property that the submucosa contributes to secure anastomosis. On the other hand, the role of the mucosa is tricky. In intestinal anastomosis bearing his name, GAMBEE tried to make the mucosal defect as small as possible because he believed such a defect may result in anastomotic failure<sup>23</sup>). This concept was also challenged by our experiment in which end-to-end anastomoses were created in dogs, the posterior half of the cut-end being inverted whereas the anterior half was everted so that difference in healing between serosa-to-serosal and mucosa-to-mucosal anastomoses was studied in otherwise equal conditions. Air inflation tests during the first postoperative week almost always showed that the mucosa-to-mucosal side leaked first although wider mucosal defects were seen on the inverted side<sup>22</sup>). These results have led us to the concept that while the submucosal tissue serves as "a secure adhesive" for anastomotic union, the mucosal surface acts as a barrier. Moreover, mucosal islets remaining in the rectal cuff can induce infection<sup>24</sup>). We postulate that a potential nidus of cuff abscess is also formed by upward migration of anal mucosal cells, misguided by the muscular cuff and failing to join their ileal counterparts. This is another reason why we everted the mucosal tube so that the anal mucosal cut-end makes a "U-turn" (Fig. 2). Thus, while the ileal submucosa is brought into direct contact with the anal submucosa and denuded internal sphincter, the mucosa is prevented from intervening between these tissues. We have used the same technique for coloanal anastomosis<sup>25</sup>).

In addition, our method offers the following desiderata for anastomotic healing: 1) Since the side-wall of the ileum is used for anastomosis, as compared to its cut-end, healing occurs in a broader and more vascularized area, 2) for the same reason, there is no anastomotic leakage unless the ileal spout undergoes necrosis, perforation or retraction, and 3) the anastomotic area is not exposed to intestinal contents and remains relatively clean because the free end of the spout acts as a diverting stoma, making a temporary ileostomy unnecessary.

Our method has some drawbacks. Either a long spout<sup>7</sup>) or a septum between the S-pouch and spout causes fecal retention requiring intubation. However, it is our belief that as compared with direct pouch-anal anastomosis, interposition of an adequate length of the spout is advantageous for closing mechanism of the anal canal. Since a longer segment of the ileum must be mobilized for pull-through reconstruction compared with pouch-anal anastomosis, its vascular supply is more likely to be compromised, leading to necrosis of the spout. In case of coloanal pull-through, such a complication occurs in 0 to 22%<sup>16-20</sup>). Four of our 11 patients also required reoperations due to necrosis and/or retraction of the colonic stump (unpublished data). For the ileal stump, this complication is less likely because of richer vascularization and smaller caliber. To prevent this complication, the entire length of the mesentery of the spout must be preserved. Another problem found in our second case was difficulty to pull down the ileal spout below the anal verge while preserving its vascular supply. Moreover, it is difficult to determine the precise length of ileal mobilization unless it is pulled down through the anal canal. At this point, additional mobilization may be necessary, requiring relaparotomy after repositioning the patient. Also, in patients with a long history of proctitis, a rigid anal canal may not admit the ileal spout. It is likely that these drawbacks add to uncertainty of the operative results which otherwise are difficult to predict. Therefore, whenever this pull-through method is thought to be unsuitable or difficult to perform, it should be changed to either stapled anastomosis or hand-sewn anastomosis by shortening or removing the ileal spout. These alternative pro-

cedures can be performed equally well or even better through the posterior approach.

A part of this work was presented at the 39th Congress of the Japanese Society of Gastroenterological Surgery on February 20th, 1992 in Kobe and at the International Symposium on Ileal Pouch-Anal Anastomosis in September 18th, 1992 in Versailles.

#### References

- 1) Vasilevsky CA, Rothenberger DA, Goldberg SM: The S ileal pouch-anal anastomosis. *World J Surg* 11: 742-50, 1987.
- 2) Nicholls RJ: Restorative proctectomy with various types of reservoir. *World J Surg* 11: 751-62, 1987.
- 3) Liljeqvist L, Lindquist K, Ljungdahl I: Alterations in ileoanal pouch technique, 1980 to 1987: Complications and functional outcome. *Dis Colon Rectum* 31: 929-38, 1988.
- 4) Fleshman JW, Cohen Z, McLeod R, et al: The ileal reservoir and ileoanal anastomotic procedure: Factors affecting technical and functional outcome. *Dis Colon Rectum* 31: 10-6, 1988.
- 5) McMullen K, Hicks TC, Ray JE, et al: Complications associated with ileal pouch-anal anastomosis. *World J Surg* 15: 763-7, 1991.
- 6) Poppen B, Svenberg T, Bark T, et al: Colectomy-proctomucosectomy with S-pouch: Operative procedures, complications, and functional outcome in 69 consecutive patients. *Dis Colon Rectum* 35: 40-7, 1992.
- 7) Parks AG, Nicholls RJ, Belliveau P: Proctomucosectomy with ileal reservoir and anal anastomosis. *Br J Surg* 67: 533-8, 1980.
- 8) Utsunomiya J, Yamamura T, Kusunoki M, et al: J-pouchchange of a method over years. *Ergebnisse der Gastroenterologie* 1988 24: 249-51, 1989.
- 9) Keighley MRB: Abdominal mucosectomy reduces the incidence of soiling and sphincter damage after restorative proctocolectomy and J-pouch. *Dis Colon Rectum* 30: 386-90, 1987.
- 10) Johnston D, Holdsworth PJ, Nasmyth DG, et al: Preservation of the entire anal canal in conservative proctocolectomy for ulcerative colitis: A pilot study comparing end-to-end ileo-anal anastomosis without mucosal resection with mucosal proctectomy and end-to-end anastomosis. *Br J Surg* 74: 940-4, 1987.
- 11) Horgan PG, O'Connell PR, Shinkwin CA, et al: Effect of anterior resection on anal sphincter function. *Br J Surg* 76: 783-6, 1988.
- 12) Lavery IC, Tuckson WB, Easley KA, et al: Internal anal sphincter function after total abdominal colectomy and stapled anastomosis without mucosal proctectomy. *Dis Colon Rectum* 32: 950-3, 1989.
- 13) Wexner SD, James K, Jagleman DG: The double-stapled ileal reservoir and ileoanal anastomosis: A prospective review of sphincter function and clinical outcome. *Dis Colon Rectum* 34: 487-94, 1991.
- 14) Heald RJ, Allen DR: Stapled ileoanal anastomosis: a technique to avoid mucosal proctectomy in the ileal pouch operation. *Br J Surg* 73: 571-2, 1986.
- 15) Kmiot Wa, Keighley MRB: Totally stapled abdominal restorative proctocolectomy. *Br J Surgery* 76: 961-4, 1989.
- 16) Babcock WW: Experiences with resection of the colon and the elimination of colostomy. *Am J Surg* 46: 186-203, 1939.
- 17) Bacon HE: Evolution of sphincter muscle preservation and re-establishment of continuity in the operative treatment of rectal cancer and sigmoid cancer. *Surg Gynecol Obstet* 81: 113-27, 1945.
- 18) Cutait DE, Figliani FJ: A new method of colorectal anastomosis. *Dis Colon Rectum* 4: 335-42, 1961.
- 19) Turnbull RB Jr, Cuthbertson A: Abdominorectal pull-through resection for cancer and for Hirschsprung's disease: Delayed posterior colorectal anastomosis. *Cleveland Clin Q* 28: 109-15, 1961.
- 20) Goligher JC, Duthie HC, De Dombal FT, et al: Abdomino-anal pull-through excision for tumours of the mid-third of the rectum. *Brit J Surg* 52: 323-5, 1965.
- 21) Halsted WS: Circular suture of the intestine: An experimental study. *Am J Med Sc* 94: 436-61, 1887.
- 22) Maetani S, Kashiwara S, Kuramoto S: Submucosal apposition with vertical mattress suture in intestinal anastomosis. *Chir Gastroent* 9: 363-69, 1975.
- 23) Gambee LP: A single-layer open intestinal anastomosis applicable to the small as well as the large intestine. *West J Surg Obstet Gynecol* 59: 1-5, 1951.
- 24) Linquist K, Nisell K, Liljeqvist L: Cuff abscess and ileoanal anastomotic separation in pelvic pouch surgery.

Dis Colon Rectum 30: 355-9, 1987.

- 25) Maetani S, Nishikawa T, Inoue H, et al: Abdominosacral ultra-low rectal resection with pull-through reconstruction and a possible mechanism of continence: Report of a case. Coloproctology 15: 100-3, 1993.

和文抄録

## 後方からの直腸粘膜切除と回腸貫通術式： 新しい大腸全摘再建法

京大大学生体医療工学研究センター

前谷 俊三

京都大学医学部第一外科

小野寺 久, 朴 泰範, 池内 大介  
古山 裕章, 梅山 信, 米沢 圭  
村尾 直子, 真辺 忠夫, 今村 正之

後方からの直腸到達法と貫通術式による新しい大腸全摘再建法を報告した。本法は内肛門括約筋損傷の主因である経肛門操作を必要とせず、括約筋障害による便失禁を予防できる。またS型貯留嚢の下方遊離断端が肛門外に引き出されて人工肛門の役割を果たし、口側の回腸肛門癒合帯（将来の吻合線）の便汚染を防ぐ

ために、一時的回腸瘻造設も不必要である。本法を32歳の家族性結腸腺腫症の女性と50歳の潰瘍性大腸炎の女性に施行した。術後便回数は着実に減少し、各々1日3回と5回となった。また肛門からの便漏れや皮膚びらんも認めなかった。本法の利点や欠点を他の方法と比較検討した。