

Title	<Original Articles>Wrap-Around Neuroorrhaphy : An Improved Method of Repair for Disparate Nerve Stumps
Author(s)	NISHIJIMA, NAOKI; KAKINOKI, RYOSUKE; SUGIMOTO, MASAYUKI; FUJIO, KEIJI; NAKAMURA, TAKASHI
Citation	日本外科宝函 (1995), 64(2): 74-82
Issue Date	1995-03-01
URL	http://hdl.handle.net/2433/203585
Right	
Type	Departmental Bulletin Paper
Textversion	publisher

Wrap-Around Neurorrhaphy: An Improved Method of Repair for Disparate Nerve Stumps

NAOKI NISHIJIMA, RYOSUKE KAKINOKI, MASAYUKI SUGIMOTO,
KEIJI FUJIO and TAKASHI NAKAMURA

Department of Orthopaedic Surgery, Faculty of Medicine, Kyoto University, Kyoto 606, Japan

Received for Publication, Jan. 13., 1995

Abstract

We report a new method of nerve Reconstruction, wrap-around neurorrhaphy, in which the funicular suture site is wrapped with the epineurium of the larger stump. The specific applications of this procedure in brachial plexus reconstruction are described and the clinical results presented.

The method was applied in intercostal nerve transfer to the musculocutaneous nerve in 21 patients and in 12 patients with axillary nerve injury who underwent reconstruction with autografts using wrap-around neurorrhaphy. Rigid fixation of the neurorrhaphy site could be obtained using this method, and the clinical results were satisfactory.

Introduction

Recently, intercostal nerve transfer to the musculocutaneous nerve has become widely accepted for functional restoration of the biceps in brachial plexus injuries, most notably for total root avulsion injuries^{6,7)}. Intercostal nerve transfer is now also indicated for upper root avulsion injuries⁴⁾. Following the restoration of shoulder function, however, tension at the site of neurorrhaphy may develop, and regenerating axons which traverse the suture line can be damaged as tension increases. A discrepancy between the diameters of the proximal and distal stumps in nerve reconstruction, such as that encountered in intercostal nerve transfer, also creates technical difficulties.

We report a new method of nerve reconstruction, wrap-around neurorrhaphy, in which the funicular suture site is wrapped with the epineurium of the larger stump. This permits "packing" of the funiculi and reduces tension at the suture line. In addition, we describe the specific applications of this procedure in brachial plexus reconstruction, citing clinical results.

Methods

The important technical aspects of the method include:

- 1) The epineurium of the stump, with which the neurorrhaphy site is later wrapped, is incised

Key word: wrap-around neurorrhaphy, funicular suture, intercostal nerve transfer, axillary nerve injury, brachial plexus injury

索引用語: 神経外膜を利用した神経再建術, 神経周膜縫合, 肋間神経移行術, 腋窩神経損傷, 腕神経叢損傷

Present Address: Department of Orthopaedic Surgery, Faculty of Medicine, Kyoto University, 54 Shogoin Kawahara-cho, Sakyo-ku, Kyoto 606, Japan.

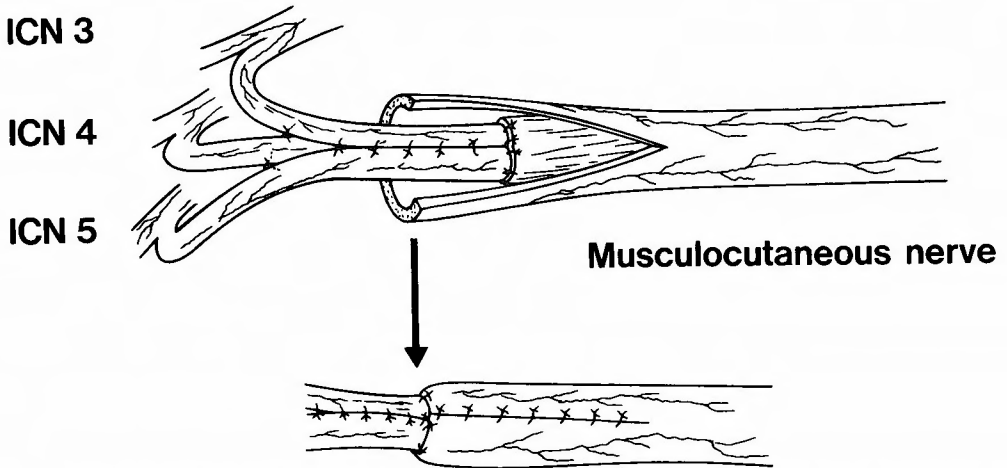


Fig. 1 Intercostal nerve transfer to the musculocutaneous nerve. ICN 3, 3rd intercostal nerve; ICN 4, 4th intercostal nerve; ICN 5, 5th intercostal nerve. The triple cable of three ventral branches of intercostal nerves is approximately the same size as the exposed funiculi of the musculocutaneous nerve.

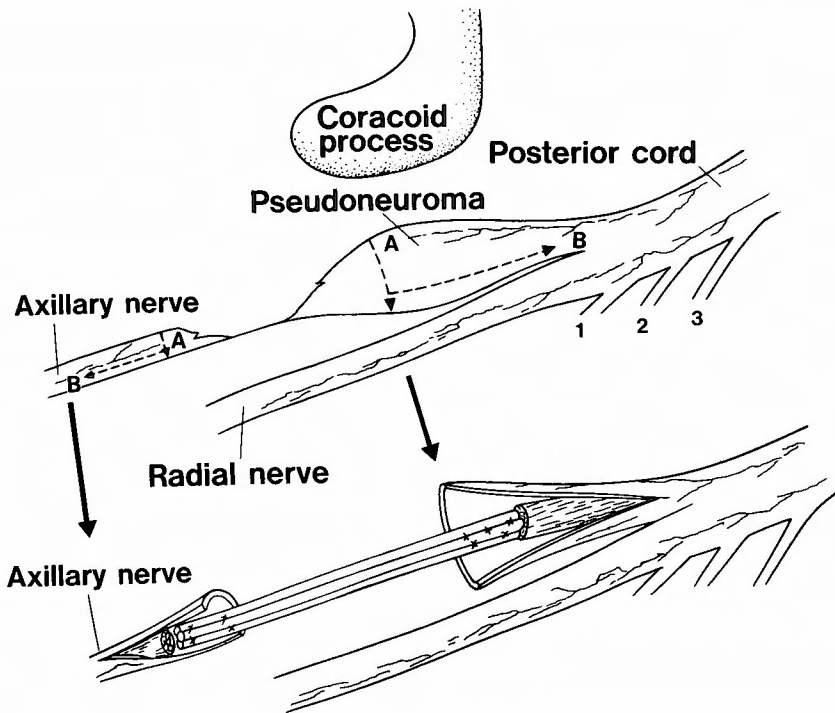


Fig. 2 Reconstruction of an axillary nerve which has ruptured under the coracoid process due to traction injuries. The proximal stump of the axillary nerve forms a pseudoneuroma. The gap between the stumps is usually less than 3–4 cm. Reconstruction of the nerve requires cable grafting, using three sural nerves. The tip of the neuroma is resected along the A-line. The epineurium of the proximal stump is incised longitudinally along the B-line in a proximal direction until normal funiculi are observed. The same procedure is performed on the distal stump.

longitudinally until normal funiculi are identified.

2) Several stay sutures are placed along the distal margin of the opened epineurium.

3) A triple cable is formed, from the ventral branches of the intercostal nerves in the case of intercostal nerve transfer (Fig. 1), or from the sural nerve bundles in the case of nerve reconstructions with autografts, using interrupted sutures for bundling (Fig. 2). Each recipient perineurium is individually adapted to the donor with 10-0 nylon thread (diameter; $25\ \mu\text{m}$).

4) The opened epineurium is closed with 8-0 nylon thread (diameter; $35\ \mu\text{m}$) and wrapped around the neurorrhaphy site.

5) The epineuria of the recipient and donor are firmly sutured to each other with side-to-side sutures with 8-0 nylon thread in order to minimize tension at the funicular suture site (Fig. 3). Care must be taken not to disturb the circulation of the epineurial vessels.

Clinical Applications

1) Intercostal nerve transfer to the musculocutaneous nerve.

Between 1989 and 1992, we performed intercostal nerve transfer using wrap-around neurorrhaphy for the reconstruction of elbow flexors in 21 patients, all injured in traffic accidents, of whom 19 regained powerful active elbow flexion (Table 1) and could abduct and flex the involved shoulder passively without biceps weakness (Fig. 4). Of the two patients whose data are excluded from this report, one had partial spinal cord injuries and the other underwent intercostal nerve transfer 8 months after injury. The elbow flexion strength was evaluated by determining the maximum weight which could be lifted at the middle third of the forearm for 30 seconds (Fig. 5). The elbow flexion contracture might have been partly due to the long-term fixation by the plaster cast after the surgery and partly due to lack of the strength of the triceps. The shoulder was reconstructed with multiple mus-

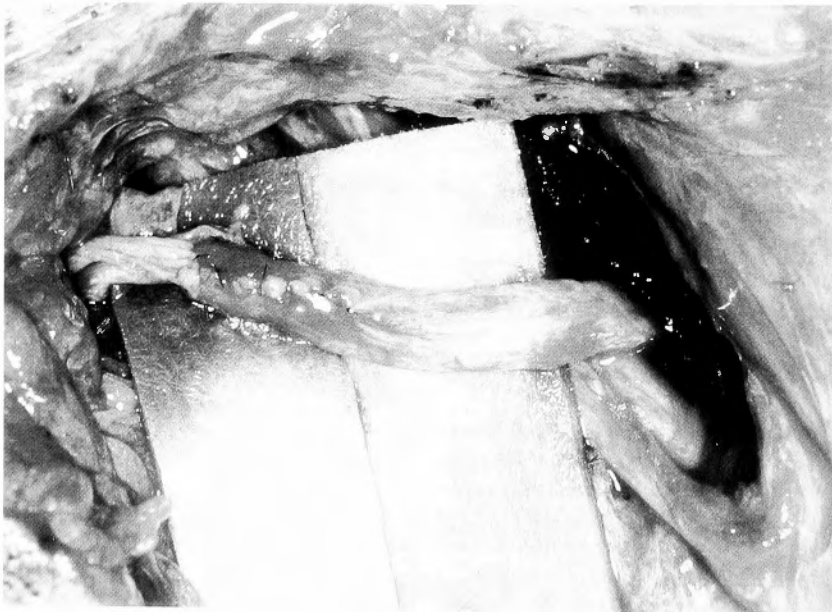


Fig. 3 Three ventral branches of intercostal nerves are transferred to the musculocutaneous nerve.

Table 1 Intercostal nerve transfer to the musculocutaneous nerve

Case	Sex, age (yrs.)	Affected side	Type of root avulsion	Duration from injury to surgery (mos.)	Post-operative examination		
					Duration after operation (yrs. + mos.)	Active range of motion (elbow)	Elbow flexion strength (30 sec.)
1	M, 19	L	total	4 M	4 Y+ 9 M	25°-135°	7 kg
2	M, 21	R	total	3 M	4 Y+ 9 M	20°-130°	7 kg
3	M, 19	R	5678	4 M	4 Y+ 6 M	15°-120°	6 kg
4	M, 22	L	567	2 M	4 Y+ 7 M	15°-130°	13 kg
5	M, 22	L	567	3 M	4 Y+ 5 M	10°-120°	10 kg
6	M, 17	R	total	3 M	3 Y+11 M	25°-120°	8 kg
7	M, 22	R	5678	2 M	3 Y+10 M	15°-140°	10 kg
8	M, 21	R	56	4 M	3 Y+ 9 M	10°-130°	9 kg
9	M, 21	L	5678	2 M	3 Y+ 8 M	20°-135°	10 kg
10	M, 21	R	56	2 M	3 Y+ 8 M	0°-140°	15 kg
11	M, 20	R	total	5 M	3 Y+ 8 M	25°-110°	4 kg
12	M, 21	R	56	2 M	2 Y+10 M	0°-140°	15 kg
13	M, 17	L	total	3 M	2 Y+ 9 M	20°-130°	10 kg
14	M, 17	L	total	3 M	2 Y+ 7 M	20°-130°	12 kg
15	M, 22	R	total	2 M	2 Y+ 4 M	20°-135°	10 kg
16	M, 24	L	5678	3 M	2 Y+ 3 M	10°-120°	8 kg
17	F, 42	R	total	3 M	2 Y+ 3 M	40°-120°	4 kg
18	M, 25	L	5678	4 M	2 Y+ 2 M	10°-130°	8 kg
19	M, 22	L	567	3 M	2 Y+ 1 M	15°-130°	5 kg

Table 2 Reconstruction of the axillary nerve with rupture under the coracoid process

Case	Sex, age (yrs.)	Affected side	Duration from injury to surgery (mos.)	Length of graft (cm)	Post-operative examination		
					Duration after operation (yrs. + mos.)	Active range of motion (shoulder) flex./ext. (degree)	Shoulder abduction strength (kg) (30 sec.) affected/opposite side
1	M 17	R	3 M	3.0 cm	5 Y+ 2 M	180/60	18/25
2	M 23	R	4 M	3.0 cm	4 Y+ 9 M	180/60	20/25
3	M 28	R	4 M	3.5 cm	4 Y+ 4 M	180/50	10/30
4	M 25	L	4 M	3.0 cm	4 Y+ 2 M	180/60	20/25
5	M 20	R	3 M	3.0 cm	3 Y+ 8 M	180/60	20/25
6	M 24	R	4 M	4.5 cm	3 Y+ 3 M	180/60	18/30
7	M 20	L	3 M	3.0 cm	2 Y+11 M	180/60	20/25
8	M 17	L	5 M	3.5 cm	2 Y+ 8 M	180/65	10/25
9	M 21	L	5 M	3.0 cm	2 Y+ 5 M	180/60	15/30
10	M 22	R	4 M	3.5 cm	2 Y+ 5 M	180/60	15/25
11	M 23	R	4 M	6.0 cm	2 Y+ 1 M	160/40	6/25
12	M 56	R	5 M	3.5 cm	2 Y+ 1 M	130/35	10/30




Fig. 4 Case 7: C5, 6, 7, 8 roots avulsion. In the reconstruction of the elbow flexors, intercostal nerves are transferred to the musculocutaneous nerve using this method. The involved shoulder can be flexed passively without biceps weakness. To elevate the shoulder, multiple muscle transfers are applied. For wrist and finger function, tendon transfers are done.

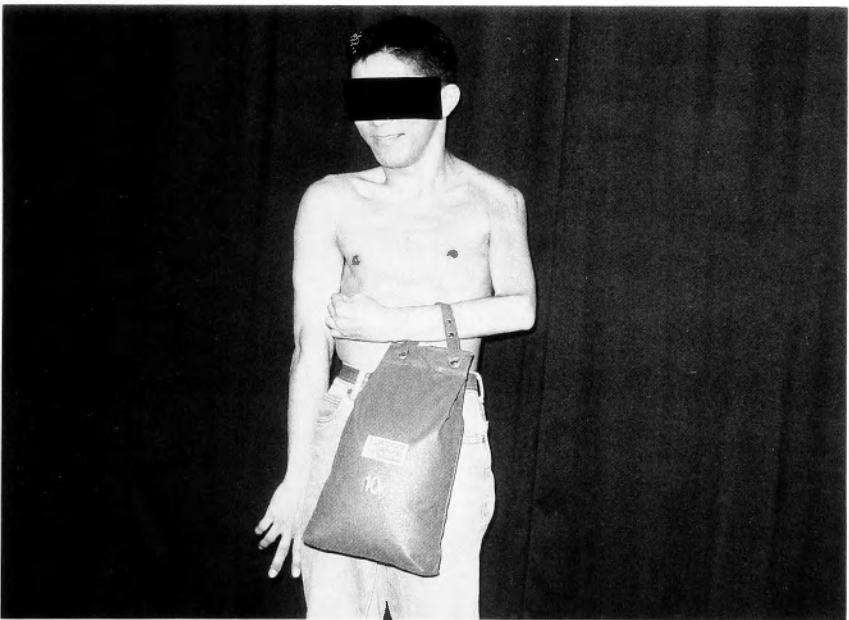

Fig. 5 Elbow flexion strength is evaluated by determining the maximum weight which can be comfortably lifted at the middle third of the forearm for 30 seconds.

cle transfer or joint desis. Only patients with follow-up periods of at least 2 years were included in this study.

2) Reconstruction of axillary nerve with rupture under the coracoid process due to traction injury⁵⁾.

Between 1989 and 1992, Reconstruction of the axillary nerve with autografts using wrap-around neurorrhaphy was performed in 12 patients with axillary nerve traction injury sustained in traffic (11 cases) or other accidents (one case at working on ship). In 6 of these patients, the injury was combined with suprascapular nerve injuries, and in one with the musculocutaneous nerve injuries, these accompanying nerve injuries were treated with neurolysis alone, with satisfactory results. The shoulder abduction strength was evaluated by determining the maximum weight (kg) which could be comfortably lifted at the middle third of the upper arm in 90° abduction position for 30 seconds (Fig. 6). All of the 12 patients regained almost full active range of motion in the shoulder (Table 2).

Three other patients with similar injury were excluded from this report because of the large size of the defect (over 7 cm) and because the distal end could not be wrapped with the epineurium due to the division of the axillary nerve into the deltoid and the teres minor.

Discussion

Methods of microscopic neurorrhaphy include epineurial repair, funicular repair without resection of the epineurium, and funicular repair with resection of the epineurium, although the most effective method of nerve repair remains controversial^{2,3)}. Age, wound condition, site of injury, and specific nerve involvement are important considerations in the selection of the most suitable method

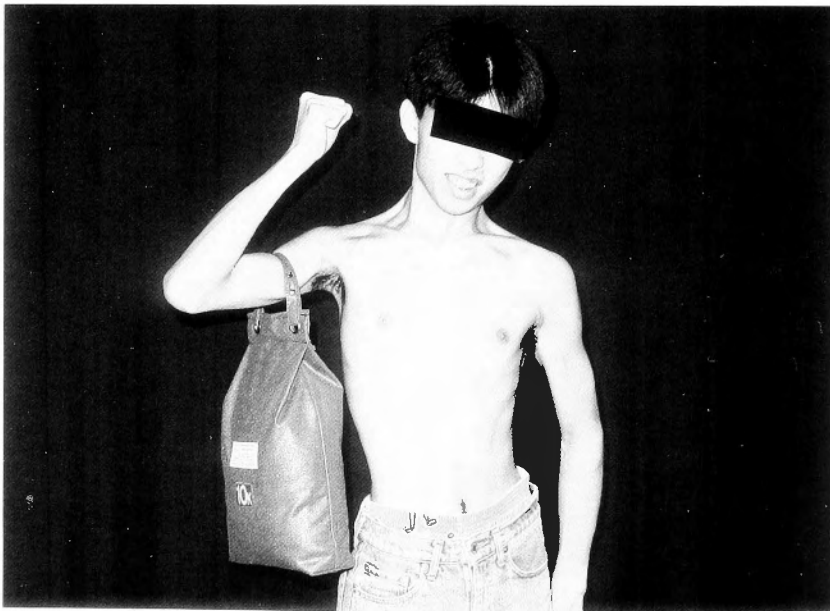


Fig. 6 Case 8: Reconstruction of the axillary nerve with autografts using wrap-around neurorrhaphy. Shoulder abduction strength is evaluated by determining the maximum weight (kg), which can be comfortably lifted at the middle third of the upper arm in 90° abduction position for 30 seconds.

of nerve repair in individual patients.

Wrapping of the epineurium around the neurorrhaphy site prevents misdirection by providing packing around the stumps. The wrapped epineurium allows the nerve to stretch without strain of the funiculi, strengthens the suture site as collagen proliferates, and permits the site of neurorrhaphy to regain excursion with joint motion. To obtain direct union between the funicular structures of the stumps, it is essential to prevent tension on the neurorrhaphy site. If tension is not prevented, connective tissue proliferation will inevitably ensue^{1,8)}.

Wrap-around neurorrhaphy is considered to be most highly indicated in clinical intercostal nerve transfer to the musculocutaneous nerve in root avulsion and clinical reconstruction with a cable of sural nerves, especially in nerve repair requiring extensive excursion with joint motion.

Acknowledgement

We are grateful to Dr. David P. Green for his instructions.

References

- 1) Bora FW, Richardson S, Black J: The biomechanical responses to tension in a peripheral nerve. *J Hand Surg* 5: 21-25, 1980.
- 2) Ito T, Hirotsu H, Yamamoto K: Peripheral nerve repairs by the funicular suture technique. *Acta Orthop Scand* 47: 283-289, 1976.
- 3) Millesi H, Meissl G, Berger A: Further experience with interfascicular grafting of the median, ulnar and radial nerves. *J Bone Joint Surg [Am]* 58: 209-218, 1976.
- 4) Nagano A, Tsuyama N, Ochiai N, et al: Direct nerve crossing with the intercostal nerve to treat avulsion injuries of the brachial plexus. *J Hand Surg* 14-A: 980-985, 1989.
- 5) Petrucci FS, Morelli A, Raimondi PL: Axillary nerve injuries—21 cases treated by nerve graft and neurolysis—. *J Hand Surg* 7: 271-278, 1982.
- 6) Seddon HJ: Nerve grafting. *J Bone Joint Surg* 45-B: 447-461, 1963.
- 7) Tsuyama N, Hara T, Nagano A: Intercostal nerve crossing as a treatment of irreparably damaged whole brachial plexus. In: Nobel J, ed. *Recent developments in orthopaedic surgery*. Manchester: University Press, 169-174, 1987.
- 8) Wilgis EFS, Murphy R: The significance of longitudinal excursion in peripheral nerves. *Hand Clinics* 2: 761-766, 1987.

和文抄録

神経外膜を利用した神経再建方法 —神経断端の大きさが異なる場合の神経修復—

京都大学医学部 整形外科

西島 直城, 柿木 良介, 杉本 正幸,
藤尾 圭司, 中村孝志

神経再建にあたって、その縫合方法には神経外膜縫合、神経周膜縫合、神経外膜・周膜縫合などがある。実際には神経の種類・部位・状態などによって、その縫合方法を変えているのが現状である。

神経外膜を温存・利用して、神経再建した場所を包みこむ神経再建の方法 (wrap-around neurorrhaphy) を記述し、その適用と臨床結果を発表した。この神経再建方法は、神経周膜縫合部位の緊張を防止し、神経束の整然とした包み込み (packing)、そして強固な神経連結を目的とする。神経断端の大きさが著しく異なる時の神経縫合、あるいは関節可動域が大きくて縫合部

位に緊張が推定される時の神経縫合には、この方法(大きい方の神経外膜で縫合部位を包む方法)の良い適用がある。

この方法で神経を再建し、術後2年以上経過している臨床症例の結果をまとめた。症例は、肋間神経移行術(互いの神経断端の大きさが著しく異なる例として)の21症例と、腋窩神経再建術(関節可動域が大きい場所での神経再建例として)の12症例である。

神経外膜を利用して、神経縫合した場所を包みこむ神経再建方法は、このような症例にきわめて良好な適用がある。