

|             |  |
|-------------|--|
| Title       | <Case Report>Splenectomy for en bloc Node Dissection in Gastric Cancer : A Possible Cause of Portal Vein Thrombosis  |
| Author(s)   | KOGIRE, MASAFUMI; NISHIDA, OSAMU; KOBAYASHI, HISATO; SHIMOGOU, TSUKASA; IZUMI, FUYUKI; SUGIYAMA, AKIO; IDA, JUN; MORI, AKIRA; TAMURA, JUN; KOUMOTO, MITSUAKI; BABA, NOBUO; OGAWA, HIROKI; SAKANASHI, SHIRO |
| Citation    | 日本外科宝函 (1996), 65(2): 49-53  |
| Issue Date  | 1996-05-01   |
| URL         | <a href="http://hdl.handle.net/2433/203559">http://hdl.handle.net/2433/203559</a>  |
| Right       |  |
| Type        | Departmental Bulletin Paper  |
| Textversion | publisher  |

---

症 例

---

Splenectomy for *en bloc* Node Dissection in Gastric Cancer:  
A Possible Cause of Portal Vein Thrombosis

MASAFUMI KOGIRE, OSAMU NISHIDA\*, HISATO KOBAYASHI\*\*, TSUKASA SHIMOGOU,  
FUYUKI IZUMI, AKIO SUGIYAMA, JUN IDA, AKIRA MORI, JUN TAMURA,  
MITSUAKI KOUMOTO, NOBUO BABA, HIROKI OGAWA and SHIRO SAKANASHI

Department of Surgery, \*Internal Medicine and \*\*Radiology, Otsu Red Cross Hospital, Otsu, Shiga, Japan  
Received for publication, Feb. 6, 1996

**Abstract**

A 48-year-old woman underwent total gastrectomy, splenectomy, and distal pancreatectomy with *en bloc* regional lymph node dissection for gastric carcinoma. Dull pain in the right upper quadrant and the back developed postoperatively. Contrast-enhanced computed tomography and ultrasonography disclosed portal vein thrombosis (PVT). Heparin and urokinase were given in conjunction with antibiotics. This treatment resulted in clinical improvement, but failed to achieve complete thrombolysis. Cavernous transformation of the portal system was confirmed. Although PVT after splenectomy has been reported mainly in patients with hematological disorders, our case suggests that splenectomy for *en bloc* node dissection in gastric carcinoma is a possible cause of PVT.

**Introduction**

Portal vein thrombosis (PVT) is an uncommon condition, usually associated with infection, cirrhosis or neoplastic diseases such as pancreatic cancer and hepatocellular carcinoma (1). This phenomenon can appear postoperatively, mainly after splenectomy for hematological disorders, in which the spleen was moderately to markedly enlarged (2-4). Although splenectomy is often combined with total gastrectomy for complete lymph node dissection in patients with gastric carcinoma (5), PVT is rarely documented in such patients. We report a case of PVT which occurred after splenectomy for *en bloc* node dissection in gastric carcinoma.

**Case Report**

A 48-year-old woman was referred to our department for surgical treatment of gastric cancer

---

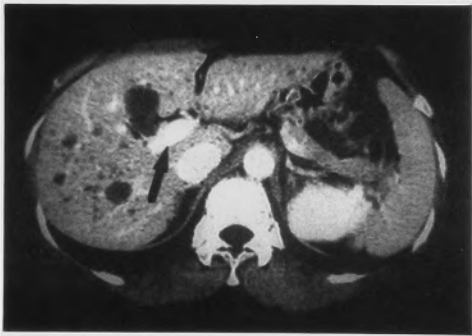Present Address: Department of Surgery & Surgical Basic Science, Graduate School of Medicine Kyoto University, 54-Shougoin Kawara-cho, Sakyo-ku, Kyoto 606-01, Japan

索引用語: 門脈, 血栓, 脾摘術, 胃癌

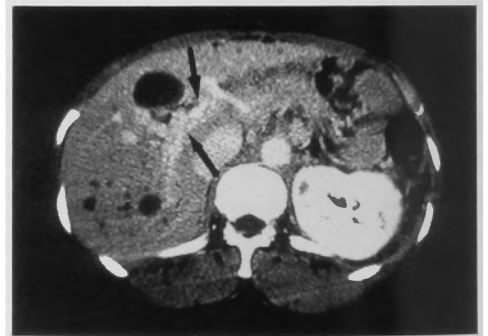
Key words: Portal vein, thrombosis, splenectomy, gastric cancer

locating in the upper third of the stomach. On physical examination, the liver and spleen were not felt. Except for a slightly elevated serum CA19-9 level, hematological and biochemical findings were normal including the bleeding time (1 minute), prothrombin time (10.0 seconds), activated partial thromboplastin time (28.3 seconds), and plasma fibrinogen level (185 mg/dl). Because hypermenorrhoea due to myoma uteri developed 4 days before surgery, the hemoglobin level, which was 12.0 g/dl on admission, decreased to 7.6 g/dl just before surgery. Preoperative computed tomography (CT) showed a patent portal vein, slightly enlarged spleen and scattered small liver cysts (Fig. 1a).

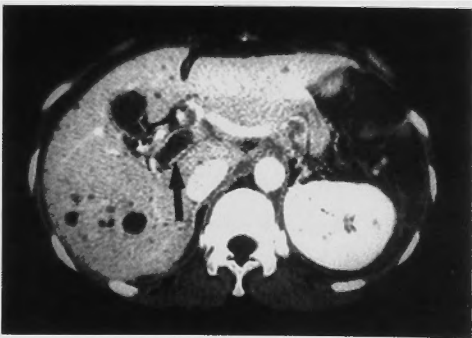She underwent total gastrectomy, splenectomy, and distal pancreatectomy with en bloc regional lymph node dissection. A so-called D2 lymph node dissection was performed according to the General Rules for the Gastric Cancer Study (6). The lymph nodes in the hepatoduodenal ligament were not removed. The splenic vein was doubly ligated. The spleen weighed 150 g. Although intraoperative blood loss was small (258 ml), 4 units of packed red cells were transfused because of pre-existing anemia. Gastric cancer was considered pT2pN0pM0, Stage IB, according to the TNM classification (7). The postoperative course was uneventful until the 18th postoperative day, when dull pain in the right upper quadrant and the back developed and was accompanied by leukocytosis and the elevation of serum alkaline phosphatase and C-reactive protein. Contrast-enhanced CT (Fig. 1b) and ultrasonography disclosed thrombus in the portal, splenic and superior mesenteric veins. Because the diagnosis of PVT was established, heparin (20000 U/day) and urokinase (60000 or 120000 U/day for 7 days) was given intravenously in conjunction with intravenous antibiotics. This treatment resulted in clinical improvement, but failed to achieve complete thrombolysis.



(a)



(c)



(b)

**Fig. 1** a. Preoperative enhanced CT scan. Patent portal vein (arrow), slightly enlarged spleen and scattered small liver cysts are observed.  
b. Postoperative enhanced CT scan. Thrombus in the portal vein is outlined by contrast material (arrow).  
c. Enhanced CT scan obtained at 11-month follow-up. Periorbital varices are observed (arrows).

Mesenteric arteriography performed 12 days after initiation of the treatment showed cavernous transformation of the portal system (Fig. 2). Plasma disappearance rate of indocyanine green (K-ICG), an index of hepatic blood flow (8), was 0.150 (normal range: 0.168–0.206), suggesting that hepatic blood flow had decreased minimally. The patient remained asymptomatic thereafter. Systemic heparinization was gradually replaced by anticoagulation with sodium warfarin, and she was discharged 66 days after surgery. At 2-year follow-up, the patient was well without evidence of esophageal varices or gastrointestinal bleeding. The most recent contrast-enhanced CT showed a thrombosed portal vein and periportal varices (Fig. 1c).

### Discussion

PVT after splenectomy results from the extension of thrombus from the splenic vein to the portal vein (4). Because stasis of blood in the stump of the splenic vein is considered to be a pathogenic factor, PVT after splenectomy is most common in patients with hematological disorders, who frequently have moderate to marked splenomegaly with the dilated splenic vein and are in a hypercoagulable state (9). In contrast, PVT after removal of a normal spleen from patients without hematological disorders has rarely been reported. *Rattner et al.* (4) reviewed the records of more than 1000 patients who underwent splenectomy, and found seven patients with PVT. In only one of the seven

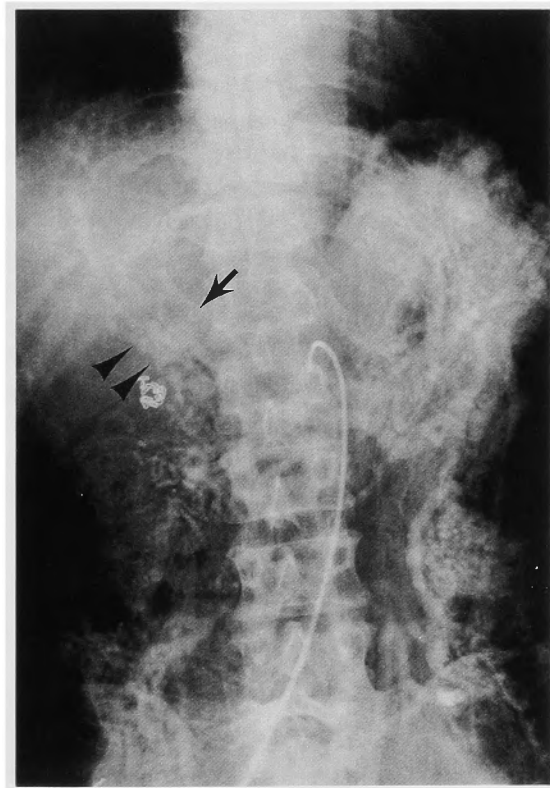


Fig. 2 Venous phase of superior mesenteric arteriography. Thrombus in the portal vein (arrow) and periportal varices (arrowheads) are noted.

patients, the spleen weighed less than 200 g. Although the spleen in our case, weighing 150 g, was slightly enlarged for a Japanese woman, our patient presented no evidence of hematological disorders, intraperitoneal infection or cirrhosis, possible causes of PVT. Because splenomegaly was minimal and the splenic vein was not dilated at surgery, it seems improbable in our patient that the stump of the splenic vein formed a large cul de sac where clot could form. Thus, the exact mechanism whereby PVT developed in our patient remains unclear. Rapid progression of anemia before surgery and blood transfusion during surgery might be involved in the pathogenesis of PVT. Because patients with PVT who later developed overt myeloproliferative disorders have been reported (9), an alternative speculation could be that our patient had a myeloproliferative disorder in a latent form.

Symptoms due to PVT are unremarkable unless an acute, fully occlusive thrombus in the portal or superior mesenteric vein develops mesenteric ischemia. Laboratory data are thought to be non-specific (1, 4); however, leukocytosis and the elevation of serum alkaline phosphatase seen in the case presented here were also noted by others (10), and may be the clues to suspect PVT. Contrast-enhanced CT and ultrasonography can detect PVT with ease (3, 4) as in our case. Therefore, a high index of suspicion has paramount importance in the early diagnosis of PVT.

Once the diagnosis of PVT is established, urgent treatment with thrombolytic agents followed by long-term anticoagulation in conjunction with antibiotics can prevent the lethal complications of bowel infarction and variceal bleeding (3, 4). Resolution of thrombus has been documented in many cases (3, 4, 10). In some cases (3, 4), however, thrombus has persisted for months, inducing cavernous transformation of the portal system as seen in our patient. It is currently unclear whether cavernous transformation can ameliorate portal hypertension, preventing the occurrence of esophageal varices. More aggressive treatment with a combination of surgical thrombectomy and regional thrombolysis using tissue plasminogen activator has recently been proposed (11), and may improve the outcome in selected cases such as those with signs of bowel infarction.

In Western countries, most splenectomies are performed in patients with risk factors for PVT, such as hematological disorders and cirrhosis, which may account for the paucity of reports on PVT after splenectomy in patients without such risk factors. However, splenectomy combined with total gastrectomy and distal pancreatectomy has recently been advocated as the surgery of choice in some cases of advanced gastric carcinoma for en bloc lymph node dissection in Western countries (5, 12), as has been performed in Japan (13), where gastric carcinoma is one of the most common forms of carcinoma. Our case suggests that splenectomy for en bloc node dissection in gastric carcinoma is a possible cause of PVT. Patients who have unexplained abdominal complaints or leukocytosis after splenectomy should undergo contrast-enhanced CT and/or ultrasonography to seek out PVT.

#### References

- 1) Cohen J, Edelman RR, Chopra S: Portal vein thrombosis: a review. *Am J Med* 92: 173-182, 1992.
- 2) Gordon DH, Schaffner D, Bennett JM, et al: Postsplenectomy thrombocytosis. Its association with mesenteric, portal, and/or renal vein thrombosis in patients with myeloproliferative disorders. *Arch Surg* 113: 713-715, 1978.
- 3) Petit P, Bret PM, Atri M, et al: Splenic vein thrombosis after splenectomy: frequency and role of imaging. *Radiology* 190: 65-68, 1994.
- 4) Rattner DW, Ellman L, Warshaw AL: Portal vein thrombosis after elective splenectomy. An underappreciated, potentially lethal syndrome. *Arch Surg* 128: 565-570, 1993.
- 5) Rosin RD: Tumors of the stomach. *In* Maingot's abdominal operations edited by Schwartz SI and Ellis H. Con-

necticut, Appleton & Lange 1990, pp 679-700.

- 6) Japanese Research Society for Gastric Cancer: The General Rules for the Gastric Cancer Study. 12th edition. Tokyo, Kanehara 1993.
- 7) UICC International Union Against Cancer: TNM classification of malignant tumors. Fourth edition. Berlin, Heidelberg, New York, London, Paris, Tokyo, Springer-Verlag 1987.
- 8) Caesar J, Shaldon S, Chiandussi L, et al: The use of indocyanine green in the measurement of hepatic blood flow and as a test of hepatic function. Clin Sci 21: 43-57, 1961.
- 9) Valla D, Casadevall N, Huisse MG, et al: Etiology of portal vein thrombosis in adults. A prospective evaluation of primary myeloproliferative disorders. Gastroenterology 94: 1063-1069, 1988.
- 10) Verbanck JJ, Rutgeerts LJ, Haerens MH, et al: Partial splenoportal and superior mesenteric venous thrombosis. Early sonographic diagnosis and successful conservative management. Gastroenterology 86: 949-952, 1984.
- 11) Demertzis S, Ringe B, Gulba D, et al: Treatment of portal vein thrombosis by thrombectomy and regional thrombolysis. Surgery 115: 389-393, 1994.
- 12) Pacelli F, Doglietto GB, Bellantone R, et al: Extensive versus limited lymph node dissection for gastric cancer: a comparative study of 320 patients. Br J Surg 80: 1153-1156, 1993.
- 13) Maruyama K, Gunven P, Okabayashi K, et al: Lymph node metastases of gastric cancer. Ann Surg 210: 596-602, 1989.

和文抄録

## 胃癌手術（脾摘術合併胃全摘術）後の門脈血栓症の1例

大津赤十字病院 外科, \*内科, \*\*放射線科

小切 匡史, 下郷 司, 泉 冬樹, 杉山 昌生, 井田 純  
 森 章, 田村 淳, 高本 充章, 馬場 信雄  
 小川 博暉, 坂梨 四郎, 西田 修\*, 小林 久人\*\*

門脈血栓症は肝硬変や肝癌の患者で時に認められる病態であるが、術後の門脈血栓症は稀であり、そのほとんどが脾腫に対する脾摘術後に発生している。我々は胃癌根治術に伴う脾摘術後に門脈血栓をきたした症例を経験したので報告する。症例は48才の女性で、胃体上部後壁を中心とする5型胃癌に対し、胃全摘術、脾摘術、脾尾側切除術を行なった。病変は組織学的には低分化腺癌、深達度 ss, No, Po, Ho の stage Ib で、摘出した脾重量は 150 g であった。なお、術前の上血凝固系検査には異常を認めなかった。術後18日目より右上腹部から背部の鈍痛が出現し、白血球数、CRP、血清アルカリフォスファターゼ値も上昇してきた。術後19日目の造影 CT で、門脈、上腸間膜静脈がほとんど造影されず、門脈から上腸間膜静脈におよぶ血栓形成が考えられた。抗生剤の投与とともにただちにヘパリンの持続静注とウロキナーゼ投与を併用したとこ

ろ、臨床症状や検査所見は軽快した。ただし、血栓は完全に消失せず、その後の腹部血管造影では側副血行路としての肝十二指腸間膜内の静脈拡張、いわゆる cavernous transformation が認められた。ヘパリン、ウロキナーゼの投与からワーファリン内服に切り替え、患者は術後66日目に退院した。現在、術後2年経過したが、食道静脈瘤の出現や消化管出血などの門脈血栓、門脈圧亢進に起因すると思われる症状は認めていない。

我々の症例は、進行胃癌根治術の際にしばしば合わせ行われる脾摘術後にも門脈血栓症の出現する可能性があることを示唆しており、そのような手術を受けた患者が術後原因不明の腹部症状や白血球増加を来した時には門脈血栓症も疑い精査を進める必要があると考えられる。