

Title	<Case Report>A Patient with a Traumatic Right Diaphragmatic Hernia Occuring 4 Years After Sustaining Injury : Statistical Observations of a Delayed Diaphragmatic Hernia Caused by Uncomplicated Injury in Japan
Author(s)	MAEKAWA, TAKEO; YABUKI, KIYOTAKA; SATOU, KOICHI; MISHIMA, GOROU; TAMASAKI, YOSHIHISA; WATABE, SUGURU; SHIROTA, SHIGERU
Citation	日本外科宝函 (1997), 66(4): 116-125
Issue Date	1997-12-01
URL	<a href="http://hdl.handle.net/2433/202879">http://hdl.handle.net/2433/202879</a>
Right	
Type	Departmental Bulletin Paper
Textversion	publisher

# A Patient with a Traumatic Right Diaphragmatic Hernia Occuring 4 Years After Sustaining Injury—Statistical Observations of a Delayed Diaphragmatic Hernia Caused by Uncomplicated Injury in Japan

TAKEO MAEKAWA, KIYOTAKA YABUKI, KOICHI SATOU, GOROU MISHIMA,  
YOSHIHISA TAMASAKI, SUGURU WATABE, SHIGERU SHIROTA

Department of Surgery of Juntendo University, Izunagaoka Hospital, Shizuoka Japan

Received for Publication, Oct. 17, 1997

## Abstract

We describe our experience with a patient in whom a traumatic right diaphragmatic hernia developed 4 years after sustaining injury and review cases of delayed diaphragmatic injury reported in Japan. The patient was a 28-year-old man who sustained a severe contusion of the right epigastric region and fractured a right rib in a traffic accident in September 1992. In August 1996, the patient presented with shortness of breath on effort or after meals. A chest roentgenogram revealed intestinal gas in the right side of the thoracic cavity. A right diaphragmatic hernia was diagnosed on the basis of a gastrointestinal series, and the patient was operated on. The hernial orifice extended anteriorly from the central tendon in an 11:00 direction and measured 11×6 cm. The small intestine, right side of the colon, and liver were herniated. A total of 297 cases of blunt traumatic diaphragmatic hernia were reported in Japan between 1981 and 1996, including 47 cases (left side, 32 cases; right side, 15 cases) of delayed diaphragmatic hernia, defined as occurring one month or more after injury. Diaphragmatic hernia should be considered as a possible diagnosis in patients with abnormal shadows in the thoracic region who have recently sustained injury or who have a past history of injury.

## Introduction

Diaphragmatic injury is often caused by blunt injury sustained during traffic or occupational accidents. The incidence of left diaphragmatic hernia is lower than that of right diaphragmatic hernia and the majority of cases are caused by injury. Rarely, however, diaphragmatic injury may occur some time after sustaining injury. In this report we describe our experience with a patient who presented with shortness of breath on effort 4 years after sustaining injury and was found to have a diaphragmatic hernia. *In this Report, we discussed the mechanisms of a delayed diaphragmatic hernia and reviewed the similar cases reported in the literature.*

---

Present address: Department of Surgery of Juntendo University, Izunagaoka Hospital 1129 Nagaoka, Izunagaoka-cho, Tagata-gun, Shizuoka 410-2211 Japan

索引用語: 鈍的外傷, 右横隔膜ヘルニア, 遅発性ヘルニア

Key words Blunt trauma, Right diaphragmatic hernia, Delayed hernia

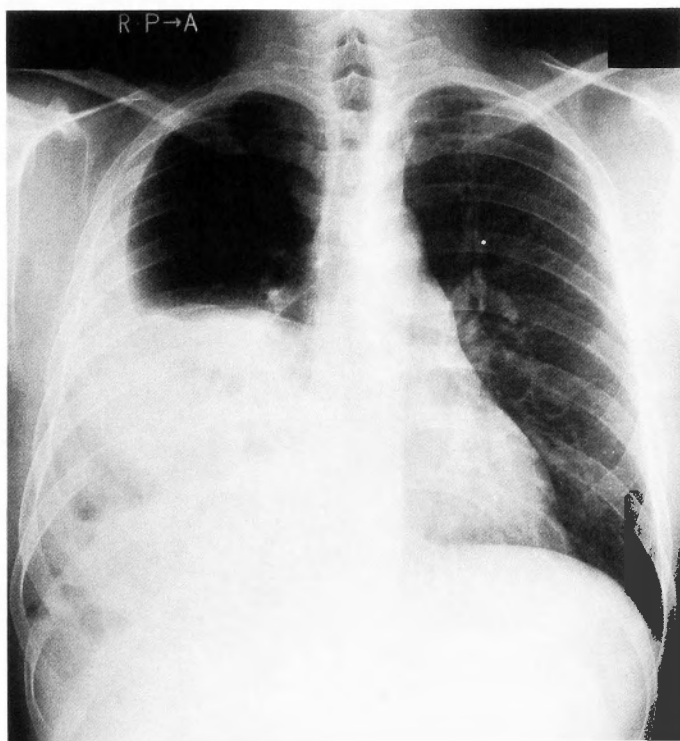
## Case Report

The patient was a 28-year-old man who complained of shortness of breath on effort. In 1992 the patients sustained a severe contusion of the right side of the epigastric region in a traffic accident. He was admitted to a certain hospital and was treated for a right rib fracture, right femur fracture, and right ulnar fracture.

Shortness of breath on effort or after meals appeared from May 1996. Symptoms gradually worsened, and the patient was examined at the department of Surgery of our hospital on August 26, 1996. A plain chest roentgenogram revealed evidence suggesting a right diaphragmatic hernia, and the patient was admitted.

On admission the patient was 164 cm tall and weighted 62 kg. The blood pressure was 130/80 mmHg; the pulse rate was 78/min and regular. The respiratory rate was 18 breaths/min. There was no evidence of anemia on examination of the palpebral conjunctivae or sclera. Auscultation of the chest revealed weak respiratory sounds at the right lower field of the lung as well as intestinal noise. There was no tenderness or muscle guarding of the abdomen.

On admission, a plain chest roentgenogram showed an overall whitish hue of a right middle and lower fields of the lung, associated with evidence of gas accumulation. There was no deviation of the cardiac shadow. The right diaphragmatic angle was indistinct (Fig. 1). An upper gastrointestinal series disclosed herniation of the major portion of the small intestine into the right side of the thoracic

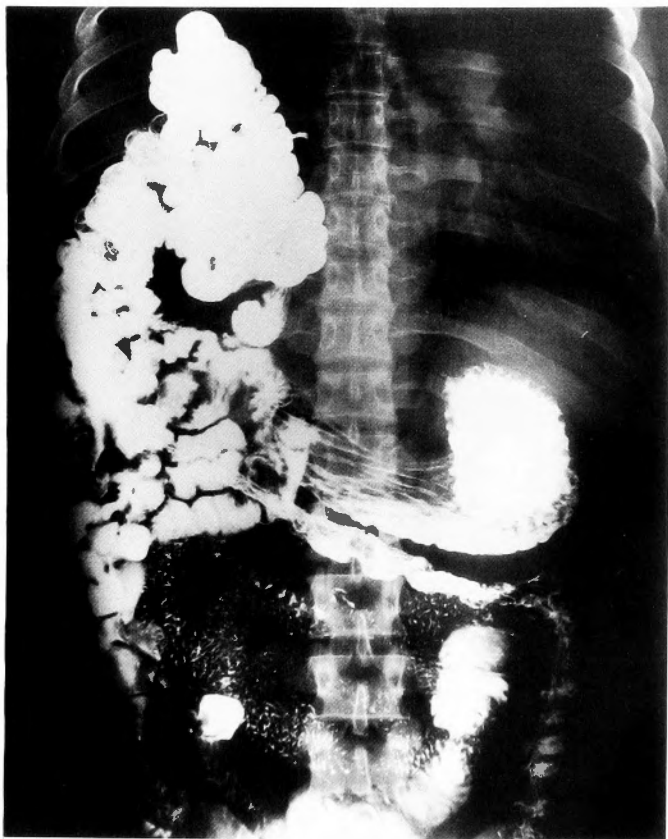


**Fig. 1** Findings on plain chest X-ray film: The right middle and lower lung fields were whitish overall and contained evidence of gas.

cavity (Fig. 2). On barium enema examination, the right side of the colon extending from the cecum to the hepatic flexure had herniated into the right side of the thoracic cavity (Fig. 3).

A computed tomographic scan of the chest showed in the right side of the thoracic cavity a heterogeneous shadow associated with gas extending from the peritoneal cavity. A homogenous, fan-like high density area was seen at the right side of the thoracic aorta in the thoracic cavity. This was the gastrointestinal tract herniated into the thoracic cavity and the right lobe of the liver (Fig. 4).

Laparotomy was performed via a subcostal incision in the epigastric region. The diaphragmatic rupture was located in the 11:00 direction, anteriorly from the central tendon of the right diaphragm. A rupture running parallel to the muscle fibers and measuring  $11 \times 6$  cm was seen (Fig. 5). The small intestine, right colon, and atrophied right lobe of the liver had herniated from the rupture into the thoracic cavity. The herniated intestine and liver showed minimal adhesion with the surrounding tissue. After redressment, the diaphragmatic rupture was directly closed with knotted sutures. In addition, the right colon was fixed to the retroperitoneum and redressed. Postoperatively, the patient complained of abdominal fullness but was discharged from the hospital on day 28.



**Fig. 2** Findings on upper gastrointestinal series: Most of the small intestine and the right side of the colon protruded into the right side of the thoracic cavity.

## Discussion

Recent increases in traffic and occupational accidents have led to an increased incidence of purely traumatic diaphragmatic hernias. In 1981 Kasahara et al.<sup>1)</sup> reported that among 420 patients with diaphragmatic hernia, there were 245 cases of diaphragmatic hernia caused by trauma in Japan. In this report we compiled cases of traumatic diaphragmatic hernia reported in Japan between 1981 and 1996, *with interested of number of cases, scauses, site of hernia and terms after injury.*

There were a total of 193 males (mean age, 45.1 years) and 53 females (mean age, 44.0 years), with a distinct preponderance in males. Most cases occurred in persons who were socially active (Table 1).

When classified according to cause 80.8% of cases were caused by traffic injuries, 9.6% by falls, 6.1% by crush injuries, and 3.5% by contusions. Up to 1981, 36.4% of cases were caused by accidents, but recently there has been a trend toward an increased number of cases due to traffic accidents (Table 2).

A total of 179 cases (74.6%) of diaphragmatic hernia occurred on the left side and 60 cases (25.0%) on the right. Most cases thus occurred on the left side (Table 3). Childress et al.<sup>2)</sup> attri-

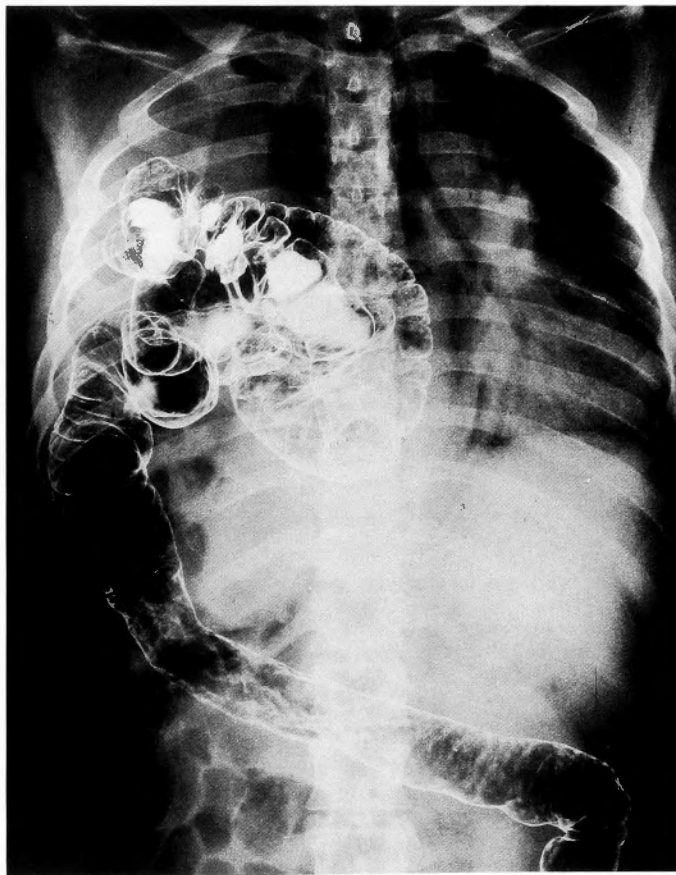
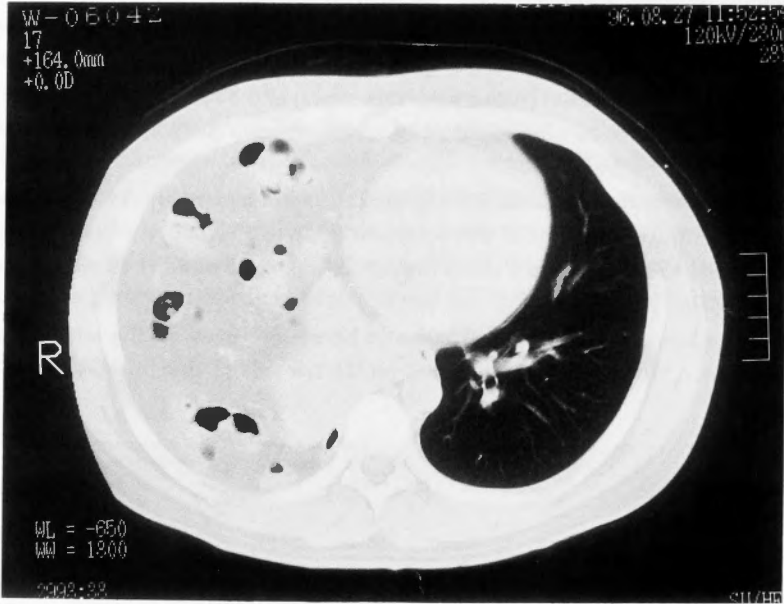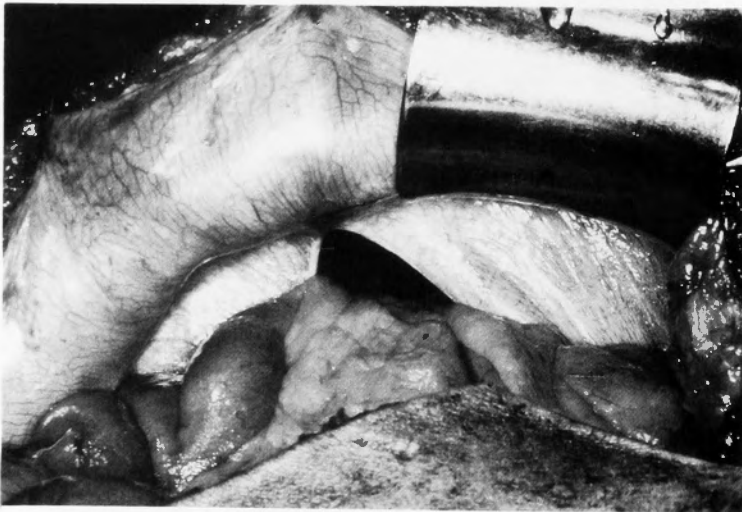


Fig. 3 Findings on barium enema: The right side of the colon protruded into the right side of the thoracic cavity.

buted the low incidence of hernia on the right side to the fact that the right diaphragm is protected by the liver: increased intraperitoneal pressure produced by abdominal trauma is buffered by the liver and right kidney. Lucido et al.<sup>3)</sup> reported that during embryonic development the posterolateral part of the diaphragm undergoes tissue fusion and is therefore more fragile than the right side, in-



**Fig. 4** Findings on abdominal computed tomographic scan. A irregular shadow associated with gas was seen at the right side of the thoracic cavity. In addition, a uniform, fan-like high-density area was seen at the right side of the thoracic aorta.



**Fig. 5** Intraoperative photograph: A tear, measuring  $11 \times 6$  cm, was located anteriorly from the center of the right diaphragmatic ligament. The small intestine, right side of the colon, and right lobe of the liver prolapsed through the hernial orifice.

creasing susceptibility to the effects of injury.

Several mechanisms have been proposed for the occurrence of the tears of the diaphragmatic hernia. Yoshimura et al.<sup>4)</sup> reported that dynamically and morphologically the diaphragm is divided into two rings covered by a left and a right membrane. Important factors leading to herniation therefore include the direction and site of external stress as well as anatomic considerations responsible for the fragility of the diaphragm. In other words, the diaphragm is ruptured around the tendon along

Table 1  
**Cases of diaphragmatic hernia caused by blunt injury in Japan (1981~1996 years)**

	No of patients	Mean age
Men	193	54.1
Women	53	44.0
Unknown	(51)	

Table 2  
**Causes of injury in blunt trauma**

	No of patients	%
Traffic injuries	160	80.8
Falls	19	9.6
Crush injuries	12	6.1
Contusions	7	3.5
Unknown	(99)	

Table 3  
**Side of diaphragm injured by blunt trauma**

Side	No of patients	%
Left	179	74.6
Right	60	25.0
Both	1	4.2
Unknown	(57)	

the muscle and tendon fibers in a direction parallel to that of the external force. Tsukioka et al.<sup>5)</sup> reported that exposure to external trauma results in an internal force to resist such trauma, which leads to rupture of the diaphragm and severing of tissue. However, Sadamitsu<sup>6)</sup> and other investigators<sup>7,8)</sup> have described patients in whom the muscle fibers of the diaphragm were ruptured at the sternal part of the diaphragm or at the attachment of the retroperitoneum rather than at the middle of the tendon. When the diaphragm is exposed to trauma from an oblique direction, not only is the thorax distorted or stressed by the external force from a lateral or anteroposterior direction, but also the components of the thorax, including the ribs, diaphragm, and muscle of the abdominal wall, are sprained. The force is transmitted along the ribs primarily around the diaphragmatic arch. The muscle fibers at the attachment of the diaphragm are lacerated. This is also considered one mechanism of diaphragmatic hernia.

In Japan epidemiologic studies of diaphragmatic hernia caused by trauma have been performed by Kasahara et al.<sup>1)</sup>, Sadamitsu et al.<sup>6)</sup>, and Yoneyama et al.<sup>9)</sup>. To our knowledge, there have been

Table 4

**Sex and mean age of patients with delayed diaphragmatic hernia (1981~1996 years)**

	No of patients	Mean age
Left side	32	48.6
Men	24	
Women	8	
Right side	15	47.6
Men	11	
Women	4	

Table 5

**Incidence of prolapsed organs in delayed diaphragmatic hernia**

Viscera	Left (32 pts)		Right (15 pts)	
	No of patients		No of patients	
Stomach	22	68.8 %	1	6.7 %
Duodenum			1	6.7 %
Small intestine	10	31.3 %	7	46.7 %
Colon	18	56.3 %	6	40.0 %
Spleen	7	21.9 %		
Liver	2	6.3 %	11	73.3 %
Gall bladder			4	26.7 %
Greater omentum	13	40.6 %	2	13.3 %

(Including 2 or more prolapsed organs)





gastrointestinal fluorograms. However, some patients who have diaphragmatic hernia are asymptomatic<sup>12)</sup>. During the period of occlusion and strangulation, symptoms of gastrointestinal obstruction occur after the intermittent period, and many cases are detected at this time. In our case, diaphragmatic hernia was discovered on examination of a chest film taken when the patient came to the hospital because of shortness of breath on effort. Surgeons often encounter conditions associated with trauma. There has been a particularly marked increase in the frequency of traffic accidents and uncomplicated abdominal trauma. The possibility of diaphragmatic hernia should be considered in patients with an abnormal shadow on chest films who have recently sustained trauma as well as those who have a history of trauma. Interview of such patients at to the detailed history and course of their symptoms may facilitate the early discovery of this condition.

### Concluding Remarks

We have described our experience with a patient with a right diaphragmatic hernia who presented with shortness of breath on effort 4 years after blunt trauma. Forty-seven case of delayed diaphragmatic hernia reported in Japan between 1981 and 1996 were reviewed along with a discussion of the related literature.

### References

- 1) H. Kasahara, S. Tanaka, M. Nishino et al: A case of traumatic diaphragmatic hernia associated with hiatus hernia of esophagus. *Surgical treatment* 23: 484-488, 1961 (in Japanese).
- 2) Childress ME, Grimes OF: Immediate and Remote sequelae in traumatic diaphragmatic hernia, *Surg Gynecol, Obstet* 113: 573-584, 1961.
- 3) Lucido JL, Wall CA: Ruptur of the diaphragm due to blunt trauma. *Arch Surg* 86: 989-999, 1963.
- 4) Yoshimura K, Shindo T, Hurukawa T: Diaphragmatic injury, *J JTOM*, 24: 391-409, 1976 (in Japanese).
- 5) Tsukioka K, Tokuhawa T, Koizumi H et al: Traumatic diaphragmatic hernia. *The Japanese Journal of Thoracic Surgery*, 42: 286-291, 1989 (in Japanese).
- 6) Sadamitsu D, Sawada Y, Sagimoto H et al: Right-sided traumatic diaphragmatic hernia following blunt trauma. *J. Jpn. Surg. Soc.* 85: 182-187, 1983 (in Japanese).
- 7) Ogawa M, Takahashi H, Kitano M et al: A study of two cases traumatic diaphragmatic hernia with associated atypical lesions. *J. Jpn. Soc. Clin Surg* 46: 215-220, 1995 (in Japanese).
- 8) Mashiko K, Murakami M, Yasudo K et al: Diaphragmatic injuries. Clinical diagnosis and surgical treatment for traumatic diaphragmatic hernia. *J. Jpn. Soc. Clin Surg* 42: 641-646, 1982 (in Japanese).
- 9) Yoneyama K, Yakoyama S, Kiso I: Traumatic hernia of the diaphragma: Report of 3 cases and clinical study of the cases reported in Japan. *Clinical surgery (Rin Ge)*. 29: 105-112, 1974 (in Japanese).
- 10) Hirai Y, Watanabe H, Shimizu K et al: A case of traumatic diaphragmatic hernia due to original trauma suffered 43 years previously. *J. Jpn. Soc. Clin Surg* 52: 2220-2221, 1991 (in Japanese).
- 11) Sanada M, Matsumoto K, Ishikawa R et al: Traumatic diaphragmatic injury: *J. Jpn. Soc. Clin Surg* 45: 1446-1452, 1984 (in Japanese).
- 12) Inada T, Kohashi H, Tsumura M et al: A case of traumatic diaphragmatic hernia presenting a distinct thoracic abdominal shadow after a long course of disease: *J Jpn Respiratory Soc* 28: 1611-1615, 1990 (in Japanese).

## 和文抄録

受傷後4年を経過して発症した外傷性右横隔膜ヘルニアの1例  
—本邦鈍的外傷性横隔膜ヘルニアの統計的観察—

順天堂大学伊豆長岡病院 外科

前川 武男, 矢吹 清隆, 佐藤 浩一  
三島 吾朗, 玉崎 良久, 渡辺 英  
城田 繁

受傷後4年を経過して発症した外傷性右横隔膜ヘルニアの1例と本邦の鈍的外傷性横隔膜ヘルニアの報告例の統計的観察について検討した。

【症例】28歳, 男性。1992年9月交通事故により右肋骨骨折を伴う右上腹部の鈍的外傷を受けた。1996年8月労作時や食後の息切れが出現した。胸部 X-P 写真および消化管造影検査で右横隔膜ヘルニアと診断し手術を施行した。破裂部位は右横隔膜の臍中心の前方11

時方向で, 筋線維方向に11×6cmの破裂部位を認めた。脱出臓器は小腸, 右結腸および肝右葉であった。また, 1981年から1996年までに本邦で鈍的外傷による横隔膜ヘルニアの報告例は297例であった。そのうち受傷後1ヶ月以降に発症した遅発性横隔膜ヘルニアは47例(右32例, 左15例)であった。受傷直後はもとより外傷の既往があり, 胸部異常陰影のある患者には本疾患を念頭におくことが大切である。