

Title	Tomographic comparison of cone-rod and rod-cone retinal dystrophies.
Author(s)	Inui, Emiko; Oishi, Akio; Oishi, Maho; Ogino, Ken; Makiyama, Yukiko; Gotoh, Norimoto; Kurimoto, Masafumi; Yoshimura, Nagahisa
Citation	Graefe's archive for clinical and experimental ophthalmology = Albrecht von Graefes Archiv für klinische und experimentelle Ophthalmologie (2014), 252(7): 1065-1069
Issue Date	2014-01-18
URL	http://hdl.handle.net/2433/200215
Right	The final publication is available at Springer via http://dx.doi.org/10.1007/s00417-014-2570-1 .
Type	Journal Article
Textversion	author

Tomographic Comparison of Cone-Rod and Rod-Cone Retinal Dystrophies

Emiko Inui, MD; Akio Oishi, MD, PhD; Maho Oishi, MD; Ken Ogino, MD; Yukiko

Makiyama, MD; Norimoto Gotoh, MD, PhD; Masafumi Kurimoto, MD, PhD;

Nagahisa Yoshimura, MD, PhD

Department of Ophthalmology and Visual Sciences, Kyoto University Graduate

School of Medicine, Kyoto, Japan

Corresponding Author: Akio Oishi, MD

54, Shougoin Kawahara-cho

Sakyo-ku, Kyoto 606-8507, Japan

Tel: (81)-75-751-3248

Fax: (81)-75-752-0933

E-mail: aquio@kuhp.kyoto-u.ac.jp

Conflicts of Interest: Nagahisa Yoshimura receives financial support from Topcon, Nidek and Canon. He is also a paid consultant of Nidek.

Abstract

Purpose: To investigate the relationship between impairment of cone/rod photoreceptors and changes in optical coherence tomography (OCT) findings.

Methods: We retrospectively reviewed the clinical records of 35 patients with cone-rod dystrophy (CRD) and 35 visual acuity-matched patients with retinitis pigmentosa (RP). The presence or absence of the external limiting membrane (ELM), inner segment ellipsoid (ISe), interdigitation zone (IZ), and foveal cavitation (hyporeflective space in the outer retina) were determined using OCT image evaluation.

Results: There were no statistical differences in the number of CRD and RP patients with an intact ELM and ISe. None of the CRD patients had an intact IZ, but 20% of RP patients did ($P = 0.011$). In addition, foveal cavitation tended to be observed more frequently in CRD patients than (25.7%) than in RP patients (5.7%) despite the difference was not significant after the correction of multiple comparison.

Conclusions: Eyes with CRD and RP had significant differences in foveal morphology, even when visual acuity was matched. This result supports the notion that absence of an IZ and the presence of foveal cavitation is related to cone-dominant photoreceptor impairment.

Keywords: cone-rod dystrophy; retinitis pigmentosa; optical coherence
tomography

Introduction

Major advances in ophthalmologic imaging devices, including optical coherence tomography (OCT) [1], have allowed visualization of the diseased retina and pathologic processes underlying various ocular conditions. The OCT device provides detailed images, which allow layer-by-layer analysis of macular microstructures. This has proven extremely useful in evaluating various retinal diseases [2].

Common retinal features on OCT images include 3 highly reflective bands in the outer retina, which are used as markers of photoreceptor integrity. These linear structures represent the external limiting membrane (ELM), the inner segment ellipsoid (ISe), and the interdigitation zone (IZ) [3, 4] and are disrupted or absent in many central retinal functional disorders [5]. However, how to interpret OCT findings is still under debate [3]. For example, the ISe was previously called the inner segment/outer segment junction (IS/OS) and the IZ line was previously called the cone outer segment tips (COST) or outer segment-retinal pigment epithelium (RPE) interdigitation [4]. Thus, it is certain that image abnormalities reflect anatomical changes in photoreceptors, but how

these OCT characteristics correlate with photoreceptor anatomy remains unclear.

Retinitis pigmentosa (RP) and cone-rod dystrophy (CRD) belong to a set of hereditary diseases that affect photoreceptors. Retinitis pigmentosa is characterized by primary impairment of rod photoreceptors [6], but CRD is characterized by primary impairment of cone photoreceptors [7, 8]. In later stages of both diseases, both rods and cones degenerate, resulting in both central and peripheral visual dysfunction.

As expected by the pathology of the diseases, disruption or disappearance of the ELM, ISe, and/or IZ have been reported in eyes with these diseases e.g. in RP [9-12], cone dystrophy [13-17], and CRD [18]. In addition, a recent study suggested that the IZ line is useful in differentiating between different types of photoreceptor degenerations because cone photoreceptors are primarily impaired in CRD [19]. However, it is not known if changes of IZ line is specific to CRD because IZ appearance on OCT is sensitive to any kind of photoreceptor damage [20]. A previous study compared ISe status in eyes with CRD and eyes with RP. It was concluded that eyes with CRD are missing the foveal ISe more frequently [18]. Unfortunately, this result may have resulted from

differences in central retinal function between CRD and RP patients, so it is not clear if this difference is reflective of different disease processes.

In the present study, we use OCT to examine visual acuity-matched eyes with either CRD or RP. Specifically, differences in ELM, ISe, and IZ line status were investigated in hopes of determining if anatomical differences in rod-cone and cone-rod macular impairment exist.

Methods

All study procedures adhered to the tenets of the Declaration of Helsinki and the study protocol was reviewed and approved by the Institutional Review Board (IRB)/Ethics Committee of the Kyoto University Graduate School of Medicine. The IRB waived the need for written informed consent.

Patient Characteristics

We retrospectively reviewed the clinical records of consecutive CRD patients. All patients underwent comprehensive ophthalmic examinations, including visual acuity measurement, kinetic and static visual field testing, full-field electroretinography (ERG, recordings obtained following the 2008

recommendations of the International Society for Clinical Electrophysiology of Vision [21]), fundus photography, OCT, and slit-lamp biomicroscopy. The CRD diagnosis was made based on the presence of progressive visual acuity loss, photophobia, and reduced or extinguished photopic and flicker ERG amplitude. A family history of CRD or atrophic foveal changes, confirmed with fundus examination or OCT, supported the diagnosis. All included CRD patients had been examined using the Spectralis® spectral domain OCT (Heidelberg Engineering, Heidelberg, Germany). No patient had media opacities severe enough to interfere with OCT imaging.

To compare findings in CRD eyes with those of RP eyes, we included a group of visual acuity-matched RP patients who had been seen at our clinic. The diagnosis of rod-cone dystrophy was also made based on clinical presentation and patient symptoms including progressive visual acuity or visual field loss, night blindness, characteristic fundus appearance (e.g., bony spicule pigmentation), and reduced or extinguished scotopic ERG amplitude. To exclusively compare cone-rod and rod-cone dystrophies, patients with macular dystrophy and normal photopic and scotopic ERGs, despite fundoscopic macular degeneration, were excluded.

One RP patient was included for every CRD patient and when 2 or more visual acuity-matched RP patients were found, the one closest in age to the corresponding CRD patient was chosen. Data from the right eye of each patient was used, unless media opacity prevented good quality OCT images from being obtained.

Clinical Characteristics

The inheritance pattern of each patient was determined based on family history. Visual acuity was measured with Landolt C charts and converted to the logarithm of the minimum angle of resolution (logMAR) equivalent for analyses. Central retinal sensitivity was measured with the Humphrey field analyzer (Carl Zeiss Meditec, Tokyo, Japan) using the Swedish Interactive Threshold Algorithm Standard 10-2 program.

Optical coherence tomography had been performed on all patients. Horizontal scans centered on the fovea were reviewed by 2 independent examiners (EI, AO) for the presence/absence of foveal ELM, ISe, and IZ lines. Examiners were masked to all other parameters and clinical measurements during evaluation. When interpretation discrepancies occurred, a third examiner

(KO) arbitrated. Central retinal thickness, defined as the distance between the inner surface of the internal limiting membrane and the outer border of the RPE, was manually measured.

Statistical Analyses

Statistical SPSS software (version 19, IBM Japan, Tokyo, Japan) was used to perform all statistical analyses. Data are presented as mean \pm standard deviation, unless otherwise specified. Comparisons between groups were performed using unpaired t-tests or chi-square tests, as appropriate. Statistical significance was defined as $P < 0.05$. When multiple comparisons were performed, the Holm's correction was applied and the significance level adjusted. This method modifies rejection criteria to control the overall probability of a type 1 error. First, P-values for each comparison were ordered. We then applied the rejection criteria $P \geq 0.05$ for the largest P-value, $P \geq 0.025$ ($0.050/2$) for the second largest P-value and so on.

Results

A total of 35 patients with CRD and 35 patients with RP were included in

analyses. Patient characteristics are summarized in Table 1. Because subjects were visual acuity-matched, no significant difference in visual acuity existed between the CRD and RP groups. Even though all efforts were made to also age-match the groups, RP patients (60.2 ± 10.7 years) were significantly older than CRD patients (51.7 ± 14.6 years, $P = 0.010$). The amplitude of ERG waveforms was also more severely impaired in RP patients than in CRD patients. Genetic screening had been previously performed in some CRD patients and revealed mutations of the *ABCA4* gene in 5 patients, the *GUCY2D* gene in 3 patients, the *CRX* gene in 1 patient, and the *CEP290* gene in 1 patient. In the RP group, 1 patient had mutations of the *EYS* gene and 1 patient had a mutation in the *RHO* gene.

Outer retinal status, determined on OCT images, is shown for each patient group in Table 2. The central retina was significantly thinner in CRD patients than in RP patients. In addition, CRD patients tended to be missing the ELM and ISe more frequently than RP patients, but this difference was not statistically significant. Interestingly, none of the CRD patients had an intact IZ line, but 20% of the RP patients did ($P = 0.011$). In addition, some CRD patients had a hyporeflective space beneath the fovea, which appeared similar to

subretinal fluid (Figure). This anomaly was previously named, “foveal cavitation” [22], and was present more often in CRD patients (25.7%) than in RP patients (5.7%, $P = 0.045$ but adjusted significant level should be 0.017). Though relatively large, this difference was not statistically significant after multiple testing corrections were applied.

Finally, the clinical characteristics between CRD patients with and without foveal cavitation were compared (Table 3). Interestingly, CRD patients with foveal cavitation tended to be younger than those without it and were more likely to have an intact ELM or ISe.

Discussion

In the present study, we showed that the IZ line on OCT images may be present in eyes with RP, but is generally not present in eyes with CRD.

Additionally, approximately 25% of patients with CRD have foveal cavitation.

These results support the idea that the IZ line reflects cone photoreceptor integrity and that foveal cavitation indicates cone-dominant photoreceptor loss.

The IZ line is vulnerable to damage and is disrupted in virtually every kind of macular diseases [5] [20]. Disruption of the IZ line has been reported both in

RP [12] and in CRD [19], but the difference between these retinal dystrophies is not known. The results of the current study showed that the IZ line is visible in some patients with RP, but not in any patients with CRD, even though patients had similar visual acuity. Considering that both diseases affect both cone and rod photoreceptors, and that the difference between them is cone-dominant or rod-dominant impairment, more frequent absence of the IZ line in eyes with CRD is likely attributable to predominantly cone impairment. This finding indicates that the cone photoreceptor outer segment/RPE interdigitation site is disrupted relatively early in the course of the CRD.

Yokochi et al. [18] previously compared macular structures in eyes with RP and CRD. They found that the ISe (or IS/OS) is absent in the fovea of patients with CRD. In contrast, we did not find a difference in ELM or ISe status between eyes with CRD and eyes with RP. This discrepancy may have been caused by differences in the 2 study populations. Mean logMAR visual acuity of RP patients in Yokochi et al.'s study [18] was -0.03, indicating a relatively early disease stage. Average logMAR visual acuity in our study was 0.84 in RP patients, indicating a much later disease stage. Therefore, it is likely that our patients had more severe damage to foveal structures than those in the previous

study. Additionally, the present study showed only minimal difference in foveal ELM and ISe status between RP and CRD patients. This result indicates that these structures may be less vulnerable to damage than the IZ line.

Focal loss of outer foveal reflectivity on OCT images, or foveal cavitation, has been reported in eyes with Stargardt disease, congenital achromatopsia, and cone dysfunction syndromes [16, 17, 23-25]. Subsequent reports have demonstrated that foveal cavitation is not specific to Stargardt disease or achromatopsia, and that it can be found in eyes with foveal cone impairment [22]. In the present study, 25.7% of CRD patients had this OCT finding, but it was only found in 5.7% of RP patients. This difference was not statistically significant after Holm's correction was applied. Considering that the CRD and RP groups were visual acuity-matched and had statistically the same ISe status, foveal cavitation may specifically reflect predominant cone loss with relative rod preservation. The previous study suggested that structural support or tension is needed to have subretinal fluid remain unabsorbed [22]. Rod outer segments, which are longer than cone outer segments, might function as such a structural support. The loss of cone outer segments results in space without cellular material, which would likely appear as a hyporeflective space on OCT images. This hypothesis is

consistent with the relatively high frequency in which foveal cavitation occurs in patients with congenital achromatopsia, Stargardt disease, and cone dysfunction syndrome [16, 17, 22-25]. With impairment of both rod and cone photoreceptors, the retina would be uniformly thinned rather than having cavitation. Further exploration of the foveal cavitation phenomenon in other conditions is needed to better understand its origins and what it anatomically represents.

Interestingly, patients who had foveal cavitation were younger and had better preservation of both the ELM and ISe. These results might indicate that foveal cavitation only occurs temporarily and is unique to a specific disease stage. It likely appears when cone photoreceptors are damaged and outer segment loss has occurred. As the ISe and, subsequently, the ELM become obscured, further photoreceptor impairment occurs and foveal cavitation disappears. Longitudinal studies are needed to determine the time course and disease stage at which cavitation appears and disappears.

Our study had several limitations. Although we made all attempts to visual acuity-match and age-match RP patients to CRD patients, CRD patients were, on average, younger than RP patients. This age discrepancy reflects the differences in disease course. Visual acuity is relatively preserved in patients

with RP until the later stages of the disease. Additionally, cone and rod responses, as measured with ERG, were significantly better preserved in eyes with CRD than in eyes with RP. Therefore, RP patients with the same visual acuity as CRD patients would be in later disease stages than corresponding CRD patients. If both visual acuity- and age-matched comparisons were possible, study results may have differed.

Another study limitation is inclusion bias. We only included patients who were diagnosed with these diseases, which may have excluded patients with less distinctive disease presentation. Thus, our results are only applicable to patients with relatively typical RP and CRD cases and not the entire disease cohort.

In conclusion, we showed that ELM and ISe status are not different between RP and CRD patients when visual acuity is matched. Patients with CRD almost never have an intact IZ line and sometimes show foveal cavitation on OCT images at a relatively early disease stage. These findings may improve our understanding of how photoreceptor degenerations are represented on OCT images.

Acknowledgments

This study was supported, in part, by the Japan Ministry of Health, Labor and Welfare (No. 12103069). The funding organization had no role in the design or conduct of this research.

References

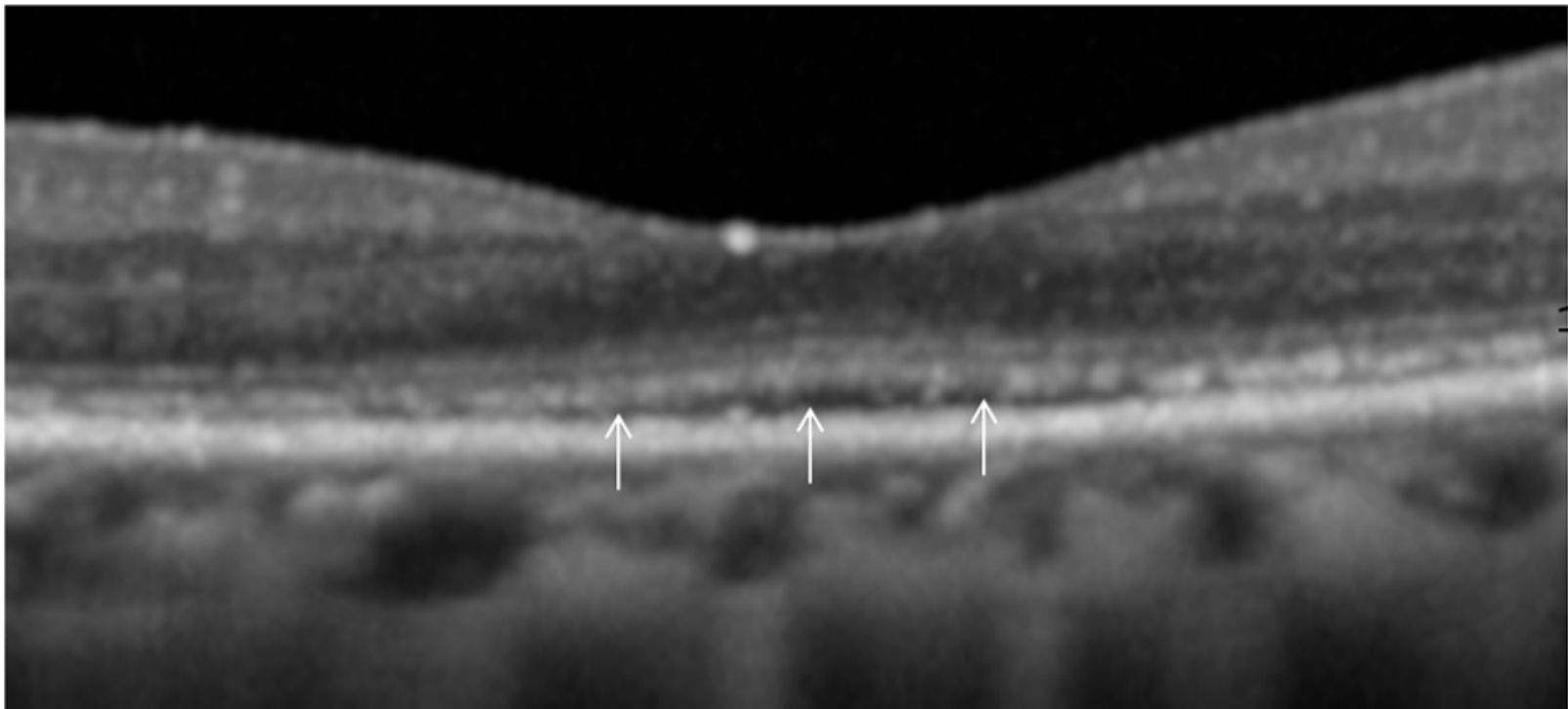
1. Drexler W (2007) Cellular and functional optical coherence tomography of the human retina: the Cogan lecture. *Invest Ophthalmol Vis Sci* 48: 5339-5351
2. Adhi M, Duker JS (2013) Optical coherence tomography--current and future applications. *Curr Opin Ophthalmol* 24: 213-221
3. Spaide RF (2012) Questioning optical coherence tomography. *Ophthalmology* 119: 2203-2204 e2201
4. Spaide RF, Curcio CA (2011) Anatomical correlates to the bands seen in the outer retina by optical coherence tomography: literature review and model. *Retina* 31: 1609-1619
5. Wong IY, Lu LP, Koizumi H, Lai WW (2012) The inner segment/outer segment junction: what have we learnt so far? *Curr Opin Ophthalmol* 23: 210-218
6. Hartong DT, Berson EL, Dryja TP (2006) Retinitis pigmentosa. *Lancet* 368: 1795-1809
7. Michaelides M, Hunt DM, Moore AT (2004) The cone dysfunction syndromes. *Br J Ophthalmol* 88: 291-297
8. Hamel CP (2007) Cone rod dystrophies. *Orphanet J Rare Dis* 2: 1-7
9. Mitamura Y, Mitamura-Aizawa S, Nagasawa T, Katome T, Eguchi H, Naito T (2012) Diagnostic imaging in patients with retinitis pigmentosa. *J Med Invest* 59: 1-11
10. Oishi A, Nakamura H, Tatsumi I, Sasahara M, Kojima H, Kurimoto M, Otani A, Yoshimura N (2009) Optical coherence tomographic pattern and focal electroretinogram in patients with retinitis pigmentosa. *Eye* 23: 299-303
11. Oishi A, Otani A, Sasahara M, Kojima H, Nakamura H, Kurimoto M, Yoshimura N (2009) Photoreceptor integrity and visual acuity in cystoid macular oedema associated with retinitis pigmentosa. *Eye* 23: 1411-1416
12. Hagiwara A, Mitamura Y, Kumagai K, Baba T, Yamamoto S (2013) Photoreceptor impairment on optical coherence tomographic images in patients with retinitis pigmentosa. *Br J Ophthalmol* 97: 237-238
13. Cho SC, Woo SJ, Park KH, Hwang JM (2013) Morphologic characteristics of the outer retina in cone dystrophy on spectral-domain optical coherence tomography. *Korean J Ophthalmol* 27: 19-27

14. Zahlava J, Lestak J, Karel I (2013) Optical coherence tomography in progressive cone dystrophy. *Biomed Pap Med Fac Univ Palacky Olomouc Czech Repub*, Epub ahead of print, doi: 10.5507/bp.2013.017.
15. Hood DC, Zhang X, Ramachandran R, Talamini CL, Raza A, Greenberg JP, Sherman J, Tsang SH, Birch DG (2011) The inner segment/outer segment border seen on optical coherence tomography is less intense in patients with diminished cone function. *Invest Ophthalmol Vis Sci* 52: 9703-9709
16. Sergouniotis PI, Holder GE, Robson AG, Michaelides M, Webster AR, Moore AT (2012) High-resolution optical coherence tomography imaging in KCNV2 retinopathy. *Br J Ophthalmol* 96: 213-217
17. Vincent A, Wright T, Garcia-Sanchez Y, Kisilak M, Campbell M, Westall C, Heon E (2013) Phenotypic characteristics including in vivo cone photoreceptor mosaic in KCNV2-related "cone dystrophy with supernormal rod electroretinogram". *Invest Ophthalmol Vis Sci* 54: 898-908
18. Yokochi M, Li D, Horiguchi M, Kishi S (2012) Inverse pattern of photoreceptor abnormalities in retinitis pigmentosa and cone-rod dystrophy. *Doc Ophthalmol* 125: 211-218
19. Lima LH, Sallum JM, Spaide RF (2013) Outer Retina Analysis by Optical Coherence Tomography in Cone-Rod Dystrophy Patients. *Retina* 33: 1877-1880
20. Shimozono M, Oishi A, Hata M, Matsuki T, Ito S, Ishida K, Kurimoto Y (2012) The significance of cone outer segment tips as a prognostic factor in epiretinal membrane surgery. *Am J Ophthalmol* 153: 698-704, 704 e691
21. Marmor MF, Fulton AB, Holder GE, Miyake Y, Brigell M, Bach M (2009) ISCEV Standard for full-field clinical electroretinography (2008 update). *Doc Ophthalmol* 118: 69-77
22. Leng T, Marmor MF, Kellner U, Thompson DA, Renner AB, Moore W, Sowden JC (2012) Foveal cavitation as an optical coherence tomography finding in central cone dysfunction. *Retina* 32: 1411-1419
23. Thomas MG, McLean RJ, Kohl S, Sheth V, Gottlob I (2012) Early signs of longitudinal progressive cone photoreceptor degeneration in achromatopsia. *Br J Ophthalmol* 96: 1232-1236
24. Barthelmes D, Sutter FK, Kurz-Levin MM, Bosch MM, Helbig H, Niemeyer

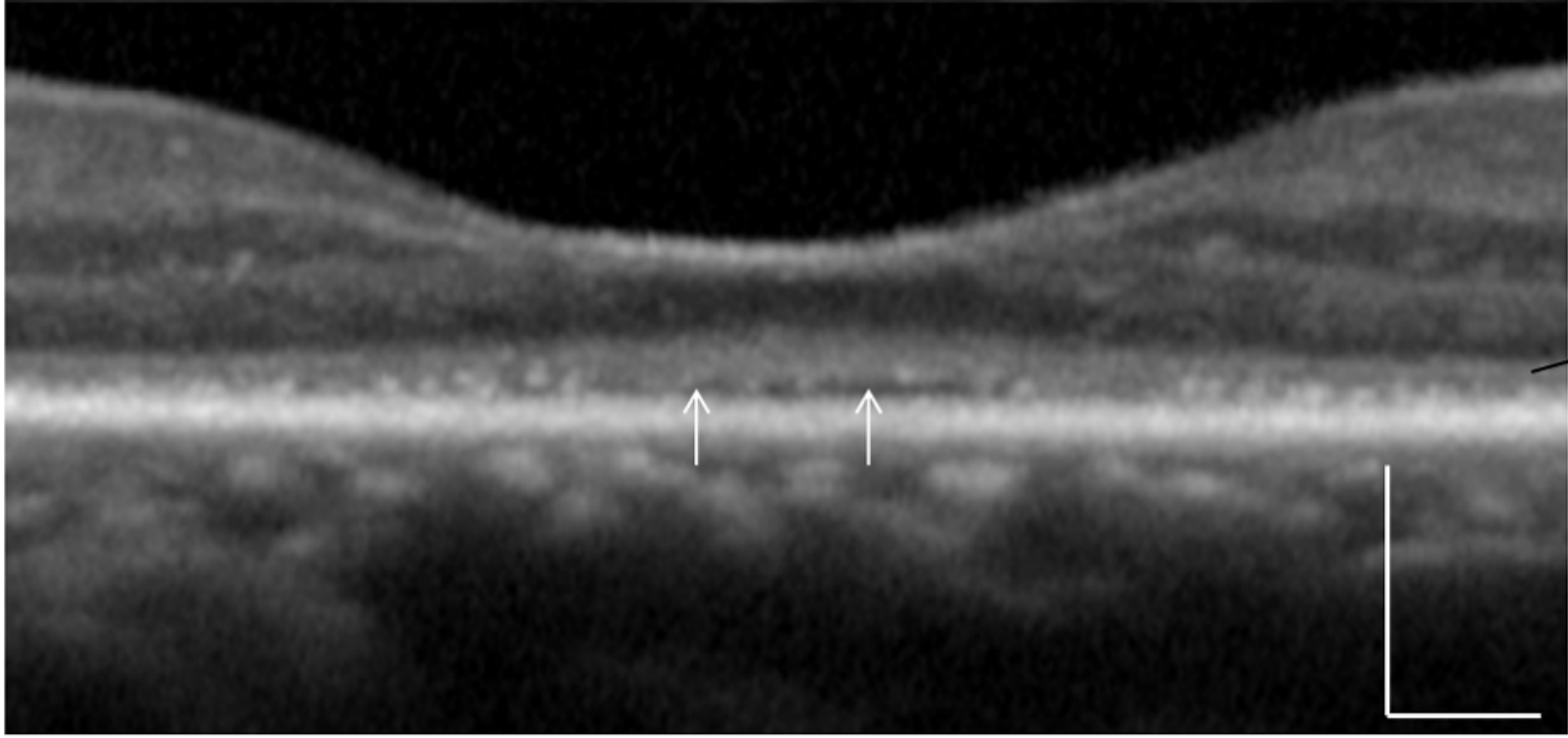
- G, Fleischhauer JC (2006) Quantitative analysis of OCT characteristics in patients with achromatopsia and blue-cone monochromatism. *Invest Ophthalmol Vis Sci* 47: 1161-1166
25. Thiadens AA, Somervuo V, van den Born LI, Roosing S, van Schooneveld MJ, Kuijpers RW, van Moll-Ramirez N, Cremers FP, Hoyng CB, Klaver CC (2010) Progressive loss of cones in achromatopsia: an imaging study using spectral-domain optical coherence tomography. *Invest Ophthalmol Vis Sci* 51: 5952-5957

Figure Legend

Figure. Representative OCT images of foveal cavitation in patients with cone-rod dystrophy. A hyporeflective space between the inner segment ellipsoid line and the retinal pigment epithelium (arrows) is apparent. ELM = external limiting membrane, ISe = inner segment ellipsoid. Scale bar indicates 200 μm .



ELM
ISe



ELM

Table 1. Clinical characteristics of visual acuity matched patients with cone-rod dystrophy (CRD) and retinitis pigmentosa (RP).

	CRD (n = 35)	RP (n = 35)	P-value
Age (years)	51.7 ± 14.6	60.2 ± 10.7	0.010*
Sex (M/F)	20/15	15/20	0.339
logMAR visual acuity	0.84 ± 0.54	0.84 ± 0.54	1.000
Dark adapted 0.01 (μV)	52.2 ± 30.1	0.0	<0.001*
Dark adapted 3.0 a-wave (μV)	102.1 ± 52.3	0.0	<0.001*
Dark adapted 3.0 b-wave (μV)	136.5 ± 61.8	0.0	<0.001*
Light adapted 3.0 (μV)	44.5 ± 29.1	3.4 ± 9.1	<0.001*
Light adapted 3.0 flicker (μV)	39.8 ± 24.4	2.6 ± 6.6	<0.001*

*indicates statistical significance.

Table 2. Comparison of outer retinal optical coherence tomography (OCT) status between visual acuity matched patients with cone-rod dystrophy (CRD) and retinitis pigmentosa (RP).

OCT Parameter	CRD (n = 35)	RP (n = 35)	P-value
ELM present	16 (45.7%)	19 (54.2%)	0.633
ISe present	10 (28.6%)	13 (37.1%)	0.611
IZ present	0 (0%)	7 (20%)	0.011*
Central Retinal Thickness (μm)	115.9 \pm 47.4	158.7 \pm 86.9	0.003*
Foveal cavitation present	9 (25.7%)	2 (5.7%)	0.045*

*indicates statistical significance, ELM = external limiting membrane, ISe = inner segment ellipsoid, IZ = interdigitation zone, CRT = central retinal thickness

Table 3. Comparison of cone-rod dystrophy patients with and without foveal cavitation. Foveal cavitation was represented on optical coherence tomography as hyporeflective spaces beneath the fovea (Figure).

	Foveal cavitation present	Foveal cavitation absent	P-value
n (patients)	9	26	---
Age (years)	44.0 ± 13.9	54.4 ± 14.1	0.072
logMAR visual acuity	0.7 ± 0.6	0.9 ± 0.5	0.414
Central retinal thickness (µm)	133.5 ± 25.0	110.5 ± 51.6	0.099
ELM present/absent (%)	9 (100%)	7 (26.9%)	<0.001*
ISe present/absent (%)	6 (66.7%)	4 (15.4%)	0.007*

*indicates statistical significance, ELM = external limiting membrane, ISe = inner segment ellipsoid