

Title	Hepatoprotective effect by pretreatment with olprinone in a swine partial hepatectomy model.
Author(s)	Iguchi, Kohta; Hatano, Etsuro; Yamanaka, Kenya; Sato, Motohiko; Yamamoto, Gen; Kasai, Yosuke; Okamoto, Tatsuya; Okuno, Masayuki; Taura, Kojiro; Fukumoto, Kyoko; Ueno, Kazuyuki; Uemoto, Shinji
Citation	Liver transplantation (2014), 20(7): 838-849
Issue Date	2014-07
URL	http://hdl.handle.net/2433/199896
Right	This is the peer reviewed version of the following article: Iguchi, K., Hatano, E., Yamanaka, K., Sato, M., Yamamoto, G., Kasai, Y., Okamoto, T., Okuno, M., Taura, K., Fukumoto, K., Ueno, K. and Uemoto, S. (2014), Hepatoprotective effect by pretreatment with olprinone in a swine partial hepatectomy model. Liver Transpl, 20: 838–849, which has been published in final form at http://dx.doi.org/10.1002/lt.23884 . This article may be used for non-commercial purposes in accordance with Wiley Terms and Conditions for Self-Archiving.
Type	Journal Article
Textversion	author

Modification of Portal Venous Pressure by Olprinone in a Swine Partial

Hepatectomy Model: Translational Research from Rats to Humans

Kohta Iguchi,¹ Etsuro Hatano,¹ Kenya Yamanaka,¹ Motohiko Sato,¹ Gen Yamamoto,¹

Yosuke Kasai,¹ Tatsuya Okamoto,¹ Masayuki Okuno,¹ Kojiro Taura,¹

Kyoko Fukumoto,² Kazuyuki Ueno,² and Shinji Uemoto¹

¹Department of Surgery, Graduate School of Medicine, Kyoto University, Kyoto, Japan

²Department of Pharmaceutical Sciences, Niigata University of Pharmacy and Applied
Life Science, Niigata, Japan

Running title: Efficacy of olprinone in a swine hepatectomy model

Key words: phosphodiesterase inhibitor, posthepatectomy liver failure, small-for-size
syndrome, shear stress, eNOS

Abbreviations: CVP, central venous pressure; eNOS, endothelial nitric oxide synthase; Hx, hepatectomy; ICGk, plasma disappearance rate of indocyanine green; iv, intravenous administration; OLP, olprinone; PDE, phosphodiesterase; PHLF, posthepatectomy liver failure; POD, postoperative days; PT, prothrombin activity; PVP, portal venous pressure; SFSS, small-for-size syndrome; T-bil, total bilirubin.

Financial support: Translational Research Grant from Translational Research Center, Kyoto University Hospital

Conflict of interest: The authors declare that they have no conflicts of interest.

Address correspondence to: Etsuro Hatano, MD, PhD

Department of Surgery, Graduate School of Medicine, Kyoto University

54 Kawaharacho, Shogoin, Sakyo-ku, Kyoto 606-8507, Japan

Telephone: 81-75-751-4323, Fax: 81-75-751-4348, E-mail: etsu@kuhp.kyoto-u.ac.jp

Excessive portal flow to a small remnant liver or small-for-size graft is a primary factor in causing small-for-size syndrome. We demonstrated that a phosphodiesterase III inhibitor, olprinone (OLP) showed a hepatoprotective effect by modifying portal venous pressure (PVP) in a rat extended hepatectomy model and small-for-size liver transplantation model. To identify the appropriate dose and duration of treatment for clinical application, we conducted the experiments, using a swine partial hepatectomy model. Twenty microminipigs were divided into 4 groups that received the following treatments: group A, control group; group B, 0.3 $\mu\text{g}/\text{kg}/\text{minute}$ (min), pre- and postoperative administration; group C, 0.1 $\mu\text{g}/\text{kg}/\text{min}$, preoperative administration; group D, 0.3 $\mu\text{g}/\text{kg}/\text{min}$, preoperative administration. The pigs underwent 70% partial hepatectomy. Hemodynamic changes, including changes in PVP, were examined. Liver biopsy was performed 1 and 3 hours (h) after hepatectomy. Blood samples were collected until postoperative day 7. Compared with group A, PVP elevation, periportal edema and sinusoidal hemorrhage were attenuated after left Glisson's ligation in groups C and D. Pretreatment with OLP in groups C and D preserved the microstructure of sinusoids and improved prothrombin activity 1 and 3 h after hepatectomy. They showed better recovery of remnant liver volume and plasma disappearance rate of indocyanine green on postoperative day 7. In contrast, group B showed exacerbation of liver damage.

Measurement of serum OLP concentration showed that 10 ng/ml of OLP was appropriate for a hepatoprotective effect. In conclusion, Pretreatment with OLP showed hepatoprotective effects in a swine partial hepatectomy model. OLP may have a potential to ameliorate patients' outcomes after hepatectomy or liver transplantation.

Because of the improvement in the preoperative assessment of liver function and surgical techniques, liver surgery has become a safer treatment of choice and its indications have been expanded.¹ Extended hepatectomies can be performed for the treatment of advanced liver cancers. Furthermore, living donor liver transplantation has been a treatment for end-stage liver disease because of the critical shortage of cadaveric organs. However, a small remnant liver or small-for-size partial graft frequently causes posthepatectomy liver failure (PHLF) or small-for-size syndrome (SFSS), which are lethal complications.²

To prevent PHLF or SFSS, portal venous pressure (PVP) modification is one of the key strategies,³ including portocaval shunt or splenic artery ligation.^{4,5} Clavien et al. reviewed strategies for safer liver resections and transplantations, focusing on preoperative evaluation, manipulation of liver volume, and hepatoprotective strategies (surgical approach and pharmacological approach).⁶ Among pharmacological approaches, several drugs have been reported to show hepatoprotective effects in rodent models.⁷⁻⁹ In particular, some drugs associated with reduction of PVP provided significant hepatoprotective effects.¹⁰⁻¹² However, few drugs have been tested in large animal models.⁶ Pigs are non-primate mammals that closely resemble humans in terms of anatomy, physiology, and genetics,^{13,14} and are an ideal animal model for a

preclinical study.

Olprinone (OLP) is a selective phosphodiesterase (PDE) III inhibitor. Elevation of intracellular cyclic adenosine monophosphate mediates positive inotropic effects and vasodilating properties.¹⁵ OLP has been used for the treatment of acute heart failure in cardiac surgery.¹⁶ PDE III is abundant in the liver,¹⁵ and we have demonstrated the hepatoprotective effects of OLP in 3 rat models: 90% partial hepatectomy model; 30% partial liver transplantation model; and sinusoidal obstruction syndrome model.¹⁷⁻¹⁹ In the 90% partial hepatectomy model, OLP was found to upregulate endothelial nitric oxide synthase (eNOS), attenuate the elevation of PVP after Glisson's ligation, and preserve the microstructure of the hepatic sinusoid, resulting in improved survival rate after hepatectomy.¹⁸ In the rat model, OLP was administered intraperitoneally at 0.6 $\mu\text{g}/\text{kg}/\text{min}$ for 48 h before hepatectomy. However, we have no knowledge of the appropriate dose and duration of OLP treatment for humans.

In the present study, we pursued hepatoprotective properties of OLP and tried to demonstrate its possible beneficial effect in a swine 70 % partial hepatectomy model with the aim of future clinical application.

MATERIALS AND METHODS

Animals and experimental design

Twenty female specific pathogen-free microminipigs (age, 1.5–2 years; weight, 20–23 kg) were obtained from Fuji Micra (Shizuoka, Japan). They were randomly assigned to 4 groups according to the dose and duration of OLP treatment (purchased from Eizai Pharmaceutical Co., Ltd, Japan) (Figure 1). Pigs in group A were administered saline (control group). Pigs in group B were administered OLP at 0.3 $\mu\text{g}/\text{kg}/\text{min}$ from 3 h before hepatectomy to 24 h after hepatectomy (pre- and postoperative administration group). Pigs in groups C and D were administered OLP for 3 h until hepatectomy started (preoperative administration groups). Group C received a low dose of OLP (0.1 $\mu\text{g}/\text{kg}/\text{min}$) and group D received a high dose (0.3 $\mu\text{g}/\text{kg}/\text{min}$). OLP was administered at 2 ml/h from a central venous catheter cannulated in the right external jugular vein using a Baxter infusion pump (Model J2C1075J; Baxter, Deerfield, IL, USA). All animal experiments were conducted by the animal research committee of Kyoto University, and all animals were cared for in accordance with Guide for the Care and Use of Laboratory Animals from the National Institutes of Health.

Anesthesia

After an overnight fast, pigs were sedated with xylazine HCl (0.3 mg/kg), midazolam (0.2 mg/kg), and atropine sulfate (0.025 mg/kg) intramuscularly, and intratracheal intubation was performed. The pigs underwent general anesthesia with a mixture of oxygen/air (FiO₂ 0.4) and sevoflurane (1–1.5%). A heating mat was used for prevention of hypothermia. The infusion was performed at 20 ml/kg/h for all groups, from the induction of anesthesia until 3 h after hepatectomy. Muscle relaxation was sustained using vecuronium bromide. For control of surgical site infection, 0.5 g of cefazolin was prophylactically administered every 3 h from just before laparotomy.

Operative procedures

Midline laparotomy was performed. After dissecting the suspensory ligaments around the left lateral lobe, the hepatoduodenal ligament was skeletonized for detecting the left hepatic artery and portal vein. After 3 h of OLP administration, the left hepatic artery and the left portal vein were ligated, and hepatectomy was performed. The left lateral and the medial lobe were resected (defined as 70% hepatectomy).^{20,21} Parenchymal transection was performed using a monopolar electrical scalpel after addition of transfixation ligatures with a 1-0 braid absorbable suture on the line just proximal to a scheduled resection line. Small vessels in the hepatic parenchyma were ligated with 4-0

braid absorbable sutures and cut. We unified a resection line of the medial lobe as a line that was 5 cm distant from the suprahepatic inferior vena cava. Every manipulation was carried out under aseptic conditions.

Postoperative management

Pigs received a 500 ml infusion of lactate Ringer's solution on postoperative days (PODs) 1 and 2. They were also administered 10 mg of famotidine intravenously for prophylaxis of peptic ulcer, 0.5 g of cefazolin for control of surgical site infection, and 0.1 mg of buprenorphine for pain control. Water intake was permitted from POD 1, and dry food was started from POD 3. Pigs were generally anesthetized at POD 7 and were then sacrificed.

Hemodynamic analyses

The right carotid artery and the right jugular vein were cannulated for monitoring arterial blood and central venous pressures (CVP), respectively. The central venous catheter was tunneled subcutaneously to exit behind the ear for postoperative access. The jejunal branch of the superior mesenteric vein was cannulated with a PE-50 catheter for monitoring PVP. The catheters were connected through blood pressure transducers

(MLT1050, PowerLab System, ADInstruments, Pty, Ltd, Australia) and a quad bridge amplifier (ML118, PowerLab System, ADInstruments) to a 4-channel data-recording unit (ML500 PowerLab/800, PowerLab System, ADInstruments). All data were analyzed using the PowerLab software system.

Serum total bilirubin level and prothrombin activity

The International Study Group of Liver Surgery (ISGLS) defined posthepatectomy liver failure using the values of serum total bilirubin level (T-bil) and prothrombin activity (PT).²² For measuring T-bil and PT, blood samples were collected from the central venous catheter at the following time points: preoperatively; 1, 3, 6, and 24 h after hepatectomy; and POD 2, 3, 5, and 7. Serum and plasma were collected after centrifugation of blood samples for 10 min at 3500 and 3100 rpm, respectively. These samples were stored at -80°C for later analysis.

Liver histology and immunohistochemistry

Liver biopsy was performed at 3 time points during surgery: just before hepatectomy and 1 and 3 h after hepatectomy (Figure 1). Biopsy samples were fixed with 10% formaldehyde, embedded in paraffin wax, and sectioned at 4 μm . The slides were

stained with hematoxylin and eosin.

Platelet/endothelial cell adhesion molecule (CD31) is frequently used to evaluate the microstructure of hepatic sinusoids.²³ For immunostaining for CD31, tissue samples were directly embedded in OCT compound (Sakura Finetek, Tokyo, Japan) and sectioned at 4 μm . The sections were fixed with 4% paraformaldehyde for 10 min at 4°C. To block endogenous peroxidase activity, the sections were treated with 0.3% H_2O_2 in methanol for 10 min. After blocking with DakoCytomation Protein Block Serum-free X0909 (Dako, Tokyo, Japan) for 30 min, the sections were incubated with a primary antibody recognizing porcine CD31 (MCA1746G; Serotec, Oxford, UK) at 1:100 dilution overnight at 4°C. The sections were incubated with a labeled polymer in an EnVision + System HRP kit (Dako) at room temperature for 1 h. After incubation, the sections were examined using a Liquid DAB Substrate Chromogen System (Dako) and counterstained with hematoxylin. A decrease in the staining suggests a loss of the sinusoidal cells. The area of immunohistochemical staining was quantified morphometrically with ImageJ (National Institutes of Health). The total area of the endothelial cells was calculated from 10 randomly selected images per high-power field (magnification, $\times 200$); the images were captured using a KEYENCE BZ-9000 (Japan).

For immunostaining for eNOS, paraffin sections were subjected to antigen

retrieval in citrate buffer (10 mmol/l, pH 6.0) in a pressure cooker. After blocking, the sections were incubated with a primary antibody recognizing eNOS (PAB12680; Abnova, Taipei, Taiwan) at 1:50 dilution overnight at 4°C. Subsequently, the sections were incubated with a labeled polymer in an EnVision + System HRP kit (Dako) at room temperature for 1 h. After incubation, the sections were examined using a Liquid DAB Substrate Chromogen System (Dako) and counterstained with hematoxylin.

Electron microscopy

We evaluated the microstructure of hepatic sinusoids using transmission electron microscopy. The biopsy samples were cut into small pieces (approximately 1 mm³) and fixed with 2% glutaraldehyde overnight at 4°C. Thin sections were stained with saturated uranyl acetate and lead citrate and observed using a Hitachi H-7650 electron microscope.

Western Blot Analysis

We performed western blot analysis in order to compare eNOS expression levels between groups. Liver tissue samples were homogenized in a lysis buffer containing 10 mmol/l Tris-HCl (pH 7.4), 150 mmol/l NaCl, 1% Nonidet P-40, and protease inhibitor.

For immunoblotting, the protein (20 µg) was subjected to 10% sodium dodecyl sulfate-polyacrylamide gel electrophoresis. After electrophoresis, the protein was transferred onto Immobilon-NC transfer membranes (Millipore Corporation, Billerica, MA, USA). These membranes were blocked with 5% skim milk in TBS-Tween and incubated with a primary antibody recognizing eNOS (#9572, Cell Signaling Technology, Inc. (CST), Danvers, MA, USA) or actin (sc-1615, Santa Cruz Biotechnology, Inc., Santa Cruz, CA) at a 1:1000 dilution overnight at 4°C. Furthermore, the membranes were washed and reacted with horseradish peroxidase - conjugated antibodies (Santa Cruz Biotechnology). Chemiluminescence was detected with ECL reagent (GE Healthcare UK Ltd., Buckinghamshire, UK) and visualized with the Ez-Capture II camera (ATTO, Tokyo, Japan). The intensity of the bands was quantified with ImageJ.

Postoperative outcomes at POD 7

To assess the degree of liver hypertrophy, we calculated the liver volume increase ratio at POD 7 using the following formula:

$$\text{(remnant liver volume at POD 7)} / \text{(resected liver volume} \times 3/7\text{)}.$$

This formula was used because 70% partial hepatectomy was performed in this study.^{20,21} The liver volume was measured in a wet condition.

In addition, to assess the degree of functional recovery of the liver, we calculated the ratio of plasma disappearance rate of indocyanine green (ICGk), which was calculated using the following formula:

$$(\text{ICGk at POD 7})/(\text{ICGk before surgery})$$

ICGk was measured using pulse dye densitometry (DDG 3000 analyzer; Nihon Kohden Industry, Tokyo, Japan). Details of this measurement are described elsewhere.²⁴ In brief, after the pig was anesthetized and the circulation got stable, ICG (0.4 mg/kg) was injected through a central venous catheter and a photodetector was attached to the tail of the pig. Photometrical signals from each pulse were used to calculate ICGk.

Serum OLP concentration

We evaluated serum OLP concentration 6 times: before hepatectomy (control); just before hepatectomy (after 3 h administration of OLP); and 1, 3, 24, and 48 h after hepatectomy. OLP concentration was determined by ultra-fast liquid chromatography using milrinone as an internal standard. In brief, OLP was extracted with ethyl acetate, and the organic layer was evaporated to dryness. To 1.0 ml of pig serum, 30 μ l of 30 μ g/ml internal standard, 1 ml of 0.1 mol/l phosphate buffer (pH 7.0), and 5 ml of ethyl acetate were added. The residue was reconstituted using 200 μ l of the mobile phase. Then, 50 μ l of this solution was injected

into an ultra-fast liquid chromatography system equipped with a reversed-phase column (Shim-pack XR-ODS; inside diameter, 3.0 mm; length, 100 mm; Shimadzu, Kyoto, Japan) and a spectrofluorometric detector with excitation/emission wavelength set at 335/400 nm. The mobile phase consisting of a mixture of 10 mmol/l phosphate buffer solution at pH 7.0 and acetonitrile (88:12 [vol/vol]) was used at a flow rate of 0.5 ml/min. The retention times of OLP and the internal standard were 8.0 and 5.5 min, respectively.

Statistical analyses

The Student *t* test was used to detect differences in the continuous variables. The OLP treatment groups (groups B, C, and D) were compared with the control group (group A), and a *P* value <0.05 indicated statistical significance. All tests were two-sided. All analyses were performed using JMP software version 8 (SAS Institute Inc., Cary, NC).

RESULTS

Characteristics of the pigs in each group

All pigs survived until POD 7 except 2 pigs in group B, who died from major bile leakage at POD 3 and from gastric dilation at POD 3, respectively. Thus, 18 pigs were analyzed in this study. The characteristics of the pigs in each group are shown in Table

1. There were no significant differences with regard to body weight, resected liver volume, resected liver volume per body weight ratio, or estimated remnant liver volume.

OLP attenuated the elevation of PVP after left portal vein ligation

The results of the hemodynamic analyses, including PVP, arterial blood pressure, CVP, and portal to central venous pressure (PVP-CVP) gradients are shown in Figure 2.

PVP at 10 min after left portal vein ligation was significantly lower in the OLP treatment groups (groups B, C, and D) than in the control group (group A) (Figure 2A).

OLP attenuated the elevation of PVP in the acute phase. No significant differences were observed in arterial blood pressure except in group D at 0 min after hepatectomy.

Hypotension due to continuous OLP administration was not observed (Figure 2B). No

significant differences were observed in CVP in all the timings (Figure 2C). PVP-CVP

gradient at 10 min after left portal vein ligation was significantly lower in the OLP

treatment groups than in the control group (Figure 2D). In groups C and D, it was also

lower than in group A at 0 min after hepatectomy.

OLP pretreatment attenuated the elevation of serum total bilirubin level and

prothrombin activity

The results of T-bil and PT analyses are shown in Figure 2E and 2F. Serum T-bil level tended to be lower in groups C and D than in group A. In contrast, serum T-bil level was higher in group B, especially at 6 h after hepatectomy (statistically significant). PT was lower in groups C and D than in group A, especially at 1 and 3 h after hepatectomy, and at POD 5 (statistically significant). However, at the acute phase, PT tended to be higher in group B than in group A. These results indicated that OLP treatment before hepatectomy showed beneficial effects, but OLP treatment after hepatectomy aggravated posthepatectomy liver injury.

OLP pretreatment inhibited periportal edema and sinusoidal hemorrhage

Representative photographs of hematoxylin and eosin staining are shown in Figure 3. In group A, periportal edema was observed 1 h after hepatectomy (Figure 3A). Within the swollen hepatocytes, sinusoidal hemorrhage was observed 3 h after hepatectomy (Figure 3B). These findings were similar to part of the pathological presentations in patients with SFSS.^{25,26} In group B, the area of the sinusoidal hemorrhage spread around the portal vein (Figure 3C, 3D). In contrast, in groups C and D, periportal edema was rarely seen, and the structure around the portal vein was normal at both 1 and 3 h after

hepatectomy (Figure 3E-H). These findings suggest that OLP treatment before hepatectomy alleviated the hepatocyte damage caused by the elevation of PVP, but OLP treatment after hepatectomy resulted in exacerbation of liver damage.

OLP pretreatment preserved endothelial cells in hepatic sinusoids

The results of CD31 immunostaining are shown in Figure 4. The area of CD31 expression before hepatectomy was 0.193. One hour after hepatectomy, it was 0.092, 0.095, 0.13, and 0.14 in groups A, B, C, and D, respectively. Three hours after hepatectomy, it was 0.071, 0.067, 0.10, and 0.12, respectively. At both 1 and 3 h, sinusoidal endothelial cells were better preserved in groups C and D than in group A, with statistical significance. However, there was no significant difference between groups C and D. In contrast, no difference was observed between groups A and B.

Furthermore, we morphologically examined endothelial cell injury using transmission electron microscopy (Figure 5). In groups C and D, sinusoidal endothelial cells were well preserved (Figure 5F-I). A thin layer of fenestrated endothelium was covered with the space of Disse, which was filled with microvilli. In contrast, in group A, the sinusoidal wall was disrupted and microvilli extending from parenchymal cell surface were damaged (Figure 5B, 5C). In group B, the endothelial cells detached, and

microvilli were lost from cell surface at 3 h after hepatectomy (Figure 5D, 5E).

OLP pretreatment improved the outcomes at POD 7

The liver volume increase ratios are shown in Figure 6. The mean values in groups A, B, C, and D were 2.95, 2.35, 3.63, and 3.47, respectively. Group C showed a significantly better outcome than did group A ($P = 0.04$).

The ICGk ratios are also shown in Figure 6. The mean values in groups A, B, C, and D were 1.01, 1.05, 1.28, and 1.21, respectively. Groups C and D tended to show better ICGk recovery than did group A.

On the contrary, the mean values of Ki-67 labeling indices in groups A, B, C, and D were 33.1, 33.0, 12.6 and 16.7%, respectively (Supplementary Figure 1). Ki-67 was still more highly activated in groups A and B than in the OLP pretreatment groups (groups C and D). In a rat partial hepatectomy model, Ki-67 expression reached a peak at 36 h after surgery, and decreased gradually thereafter.²⁷ In a swine 70% partial hepatectomy model, other indices of proliferative markers, such as thymidine kinase activity or mitotic index, reached a peak at POD3.²⁸ Based on these data, we considered that the high activity of Ki-67 at POD7 in groups A and B indicated delayed recovery compared to groups C and D.

OLP pretreatment upregulated eNOS

We have demonstrated that hepatoprotective effects were brought about through eNOS upregulation in a rat model.¹⁸ We also examined whether eNOS was upregulated in the pig model by OLP pretreatment using liver biopsy specimens just before hepatectomy. Western blot analysis revealed that the levels of eNOS expression tended to be higher in the OLP treatment groups (groups B, C, and D) than in the control group (group A) (Figure 7A). The groups receiving a high dose of OLP (groups B and D) showed higher levels of eNOS expression than the group receiving a low dose (group C).

Representative photographs of immunostaining for eNOS are shown in Figure 7B-E. Both hepatocytes and endothelial cells showed higher eNOS expression in OLP treatment groups than in group A. This result suggested that we were able to reproduce the hepatoprotective effects observed in the rat liver in our pig model.

Measurement of serum OLP concentration for assessing the appropriate dose and treatment duration

Serum OLP concentrations are shown in Figure 8. For observing the pharmacological effects of OLP, the most important time point was just before hepatectomy, when the

liver was about to be exposed to surgical stress. The mean values of the OLP concentration just before hepatectomy were 9.7 and 32.8 ng/ml in groups C and D, respectively. These results suggest that a serum OLP concentration of approximately 10 ng/ml was sufficient to obtain hepatoprotective effects.

In contrast, in group B, the OLP concentration increased gradually to 47.1 ng/ml at 24 h after hepatectomy, until OLP administration was stopped. We observed increasing necrosis of periportal hepatocytes at 1 and 3 h after hepatectomy (Figure 3), when serum OLP concentrations were 26.8 and 43.4 ng/ml, respectively. This result indicated that if a serum OLP concentration >20 ng/ml was maintained after hepatectomy, posthepatectomy liver injury would be exacerbated.

DISCUSSION

We conducted the present experiments in a swine partial hepatectomy model to evaluate the hepatoprotective effects of OLP, a PDE inhibitor. PDE inhibitors have been reported to show beneficial effects on ischemia reperfusion injury of various organs, including the heart,^{29,30} liver,^{31,32} kidney,³³ and brain.³⁴ Inhibition of PDE leads to increased levels of intracellular cyclic adenosine monophosphate, followed by activation of PI3K-Akt or PKA-p38MAPK cascades, resulting in activation of eNOS; these mechanisms are

thought to be important for the beneficial properties of these drugs. In particular, we focused on PVP and eNOS upregulation found in a previous rat partial hepatectomy model,¹⁸ and examined this efficacy in a pig model to enable translation from rats to humans.

In case of extended hepatectomy or small-for-size liver transplantation, portal hyperperfusion has been considered a primary factor causing PHLF or SFSS.^{2,6} A small remnant liver or graft is exposed to increased portal flow, and the endothelia of the sinusoids are damaged, resulting in disrupted hepatic microcirculation and necrosis of hepatocytes.^{3,23,35,36} Man et al. reported that the transient portal hypertension resulted in progressive and irreversible liver damage in a rat SFSS model.³⁵ In the present study, OLP pretreatment attenuated the elevation of PVP in the acute phase and preserved hepatic microstructure, leading to better recovery at POD 7 in a swine partial hepatectomy model.

For the clinical application of OLP, the appropriate dose and treatment duration of OLP must be established. With regard to the pharmacokinetics of OLP in humans, the half-life ($t_{1/2}$) is 1 h and continuous administration for $3 \times t_{1/2}$ (3 h) is estimated to result in 88% of the plateau level of serum concentration.³⁷ Without hepatic metabolism, OLP is excreted in an unchanged form in urine. For treatment of heart failure, OLP has

been administered at 0.1–0.3 $\mu\text{g}/\text{kg}/\text{min}$, and the therapeutic serum concentration is 20 ng/ml. The main effects of OLP are dose-dependent, that is, a vasodilating property at a low dose and a positive inotropic property at a high dose.³⁸ For liver surgery, OLP concentration has to be kept sufficiently high when the liver is exposed to shear stress or ischemic reperfusion. We demonstrated that a serum OLP concentration of approximately 10 ng/ml is appropriate for obtaining a hepatoprotective effect in the pig model.

In contrast, OLP treatment after hepatectomy, which resulted in a serum OLP concentration >20 ng/ml, resulted in detrimental effects. These effects were not observed in a pig without hepatectomy, receiving continuous OLP for 48 hours with the serum concentration >20 ng/ml. (data not shown) One possible reason is that OLP increased hepatic tissue blood flow, resulting in augmented shear stress to the small remnant liver.³⁵ Iribe et al. reported that OLP administration at 0.3 $\mu\text{g}/\text{kg}/\text{min}$ for 2 h resulted in an increase in cardiac output as well as hepatic blood flow in humans.³⁹ The result of the serum OLP concentration indicated that excessive OLP caused the harmful effect because of the increase in hepatic tissue blood flow after hepatectomy. This hypothesis might be supported by our experience that rats receiving OLP after hepatectomy showed poor prognosis. With regard to the other doses, pigs receiving

pre- and postoperative OLP at 0.1 or 0.05 $\mu\text{g}/\text{kg}/\text{min}$ were examined. However, they did not show better recovery at POD7 (data not shown). We considered that this was partly because serum OLP concentration after hepatectomy might have become higher than expected in the dehydrated pigs. All the results considered, when OLP is used in hepatectomy or donor hepatectomy, it should be administered only until the hepatectomy is finished or a partial graft is obtained.

Large animal research is expected to play an important role in bridging the knowledge gap between rats and humans. In general, there is a substantial difference between animal species in pharmacokinetics, mainly due to cytochrome P450 (CYP450) activity. However, a similarity in the primary structure of a CYP3 enzyme, which is responsible for the metabolism of the majority of drugs in CYP450 family, has been observed in pigs and humans.⁴⁰ Therefore, pigs are expected to become an appropriate animal model for translational research, particularly for new drug discovery.¹⁴ Now we are conducting a phase I clinical trial (UMIN00004975), and trying to examine the safety and efficacy of OLP in humans based on the findings in this pig model.

In summary, we conducted translational research, using a swine partial hepatectomy model, to elucidate the appropriate dose and treatment duration of OLP in

humans. We consider that OLP may have the therapeutic potential to overcome PHLF and SFSS.

ACKNOWLEDGEMENTS

We thank Dr Rei Takahashi, Department of Pharmacotherapeutics, Faculty of Pharmaceutical Sciences, Doshisha Women's College of Liberal Arts, for advice on pathological assessment. We also thank Ms. Keiko Okamoto-Furuta and Mr. Haruyasu Kohda, Division of Electron Microscopic Study, Center for Anatomical Studies, Graduate School of Medicine, Kyoto University, for preparing electron microscopic specimens.

REFERENCES

1. Cescon M, Vetrone G, Grazi GL, Ramacciato G, Ercolani G, Ravaioli M, et al. Trends in Perioperative Outcome After Hepatic Resection Analysis of 1500 Consecutive Unselected Cases Over 20 Years. *Annals of Surgery*. 2009;249(6):995-1002.
2. Dahm F, Georgiev P, Clavien PA. Small-for-size syndrome after partial liver transplantation: Definition, mechanisms of disease and clinical implications. *American Journal of Transplantation*. 2005;5(11):2605-10.
3. Ogura Y, Hori T, El Moghazy WM, Yoshizawa A, Oike F, Mori A, et al. Portal Pressure < 15 mm Hg Is a Key for Successful Adult Living Donor Liver Transplantation Utilizing Smaller Grafts than Before. *Liver Transplantation*. 2010;16(6):718-28.
4. Boillot O, Delafosse B, Mechet I, Boucaud C, Pouyet M. Small-for-size partial liver graft in an adult recipient; a new transplant technique. *Lancet*. 2002;359(9304):406-7.
5. Troisi R, Cammu G, Militerno G, De Baerdemaeker L, Decruyenaere J, Hoste E, et al. Modulation of portal graft inflow: A necessity in adult living-donor liver transplantation? *Annals of Surgery*. 2003;237(3):429-36.

6. Clavien P, Petrowsky H, DeOliveira ML, Graf R. Medical progress: Strategies for safer liver surgery and partial liver transplantation. *New England Journal of Medicine*. 2007;356(15):1545-59.
7. Cai SR, Motoyama K, Shen KJ, Kennedy SC, Flye MW, Ponder KP. Lovastatin decreases mortality and improves liver functions in fulminant hepatic failure from 90% partial hepatectomy in rats. *Journal of Hepatology*. 2000;32(1):67-77.
8. Bustos M, Beraza N, Lasarte JJ, Baixeras E, Alzuguren P, Bordet T, et al. Protection against liver damage by cardiotrophin-1: A hepatocyte survival factor up-regulated in the regenerating liver in rats. *Gastroenterology*. 2003;125(1):192-201.
9. Palmes D, Skawran S, Stratmann U, Armann B, Minin E, Herbst H, et al. Amelioration of microcirculatory damage by an endothelin A receptor antagonist in a rat model of reversible acute liver failure. *Journal of Hepatology*. 2005;42(3):350-7.
10. Zhao Y, Man K, Lo CM, Ng KT, Li XL, Sun CK, et al. Attenuation of small-for-size liver graft injury by FTY720: Significance of cell survival Akt signaling pathway. *American Journal of Transplantation*. 2004;4(9):1399-407.
11. Man K, Lee TK, Liang TB, Lo CM, Fung PCW, Tsui SH, et al. FK 409 ameliorates small-for-size liver graft injury by attenuation of portal hypertension and down-regulation of Egr-1 pathway. *Annals of Surgery*. 2004;240(1):159-68.

12. Xu X, Man K, Zheng SS, Liang TB, Lee TK, Ng KT, et al. Attenuation of acute phase shear stress by somatostatin improves small-for-size liver graft survival. *Liver Transplantation*. 2006;12(4):621-7.
13. Bendixen E, Danielsen M, Larsen K, Bendixen C. Advances in porcine genomics and proteomics-a toolbox for developing the pig as a model organism for molecular biomedical research. *Briefings in Functional Genomics*. 2010;9(3):208-19.
14. Zuber R, Anzenbacherova E, Anzenbacher P. Cytochromes P450 and experimental models of drug metabolism. *Journal of Cellular and Molecular Medicine*. 2002;6(2):189-98.
15. Bender AT, Beavo JA. Cyclic nucleotide phosphodiesterases: Molecular regulation to clinical use. *Pharmacological Reviews*. 2006;58(3):488-520.
16. Mizushige K, Ueda T, Yukiiri K, Suzuki H. Olprinone: A phosphodiesterase III inhibitor with positive inotropic and vasodilator effects. *Cardiovascular Drug Reviews*. 2002;20(3):163-74.
17. Narita M, Hatano E, Ikai I, Miyagawa-Hayashino A, Yanagida A, Nagata H, et al. A Phosphodiesterase III Inhibitor Protects Rat Liver From Sinusoidal Obstruction Syndrome Through Heme Oxygenase-1 Induction. *Annals of Surgery*. 2009;249(5):806-13.

18. Yamanaka K, Hatano E, Narita M, Kitamura K, Yanagida A, Asechi H, et al. Olprinone Attenuates Excessive Shear Stress Through Up-Regulation of Endothelial Nitric Oxide Synthase in a Rat Excessive Hepatectomy Model. *Liver Transplantation*. 2011;17(1):60-9.
19. Yamanaka K, Hatano E, Iguchi K, Yamamoto G, Sato M, Toriguchi K, et al. Effect of olprinone on liver microstructure in rat partial liver transplantation. *Journal of surgical research*. 2013;183(1):391-6.
20. Court FG, Wemyss-Holden SA, Morrison CP, Teague BD, Laws PF, Kew J, et al. Segmental nature of the porcine liver and its potential as a model for experimental partial hepatectomy. *British Journal of Surgery*. 2003;90(4):440-4.
21. Iida T, Yagi S, Taniguchi K, Hori T, Uemoto S. Improvement of morphological changes after 70% hepatectomy with portocaval shunt: Preclinical study in porcine model. *Journal of Surgical Research*. 2007;143(2):238-46.
22. Rahbari NN, Garden OJ, Padbury R, Brooke-Smith M, Crawford M, Adam R, et al. Posthepatectomy liver failure: A definition and grading by the International Study Group of Liver Surgery (ISGLS). *Surgery*. 2011;149(5):713-24.
23. Fondevila C, Hessheimer AJ, Taura P, Sanchez O, Calatayud D, de Riva N, et al. Portal Hyperperfusion: Mechanism of Injury and Stimulus for Regeneration in

Porcine Small-for-Size Transplantation. *Liver Transplantation*. 2010;16(3):364-74.

24. Ohwada S, Kawate S, Hamada K, Yamada T, Sunose Y, Tsutsumi H, et al. Perioperative real-time monitoring of indocyanine green clearance by pulse spectrophotometry predicts remnant liver functional reserve in resection of hepatocellular carcinoma. *British Journal of Surgery*. 2006;93(3):339-46.

25. Kelly DM, Demetris AJ, Fung JJ, Marcos A, Zhu Y, Subbotin V, et al. Porcine partial liver transplantation: A novel model of the "small-for-size" liver graft. *Liver Transplantation*. 2004;10(2):253-63.

26. Demetris AJ, Kelly DM, Egtesad B, Fontes P, Marsh JW, Tom K, et al. Pathophysiologic observations and histopathologic recognition of the portal hyperperfusion or small-for-size syndrome. *American Journal of Surgical Pathology*. 2006;30(8):986-93.

27. Gerlach C, Sakkab DY, Scholzen T, Dassler R, Alison MR, Gerdes J. Ki-67 expression during rat liver regeneration after partial hepatectomy. *Hepatology*. 1997;26(3):573-8.

28. Kahn D, Hickman R, Terblanche J, Vonsommoggy S. PARTIAL-HEPATECTOMY AND LIVER-REGENERATION IN PIGS - THE RESPONSE TO DIFFERENT RESECTION SIZES. *Journal of Surgical Research*.

1988;45(2):176-80.

29. Sanada S, Kitakaze M, Papst PJ, Asanuma H, Node K, Takashima S, et al. Cardioprotective effect afforded by transient exposure to phosphodiesterase III inhibitors - The role of protein kinase A and p38 mitogen-activated protein kinase. *Circulation*. 2001;104(6):705-10.
30. Nomura Y, Horimoto H, Mieno S, Nakahara K, Okawa H, Yoshida M, et al. Repetitive preischemic infusion of phosphodiesterase III inhibitor olprinone elicits cardioprotective effects in the failing heart after myocardial infarction. *Molecular and Cellular Biochemistry*. 2003;248(1-2):179-84.
31. Kobayashi T, Sugawara Y, Ohkubo T, Imamura H, Makuuchi M. Effects of amrinone on hepatic ischemia-reperfusion injury in rats. *Journal of Hepatology*. 2002;37(1):31-8.
32. Kume M, Banafsche R, Yamamoto Y, Yamaoka Y, Nobiling R, Gebhard M-M, et al. Dynamic changes of post-ischemic hepatic microcirculation improved by a pre-treatment of phosphodiesterase-3 inhibitor, milrinone. *Journal of Surgical Research*. 2006;136(2):209-18.
33. Mizutani A, Murakami K, Okajima K, Kira S, Mizutani S, Kudo K, et al. Olprinone reduces ischemia/reperfusion-induced acute renal injury in rats through

enhancement of cAMP. *Shock*. 2005;24(3):281-7.

34. Genovese T, Mazzon E, Paterniti I, Esposito E, Cuzzocrea S. Neuroprotective effects of olprinone after cerebral ischemia/reperfusion injury in rats. *Neuroscience Letters*. 2011;503(2):93-9.

35. Man K, Lo CM, Ng IOL, Wong YC, Qin LF, Fan ST, et al. Liver transplantation in rats using small-for-size grafts - A study of hemodynamic and morphological changes. *Archives of Surgery*. 2001;136(3):280-5.

36. Man K, Fan ST, Lo CM, Liu CL, Fung PCW, Liang TB, et al. Graft injury in relation to graft size in right lobe live donor liver transplantation - A study of hepatic sinusoidal injury in correlation with portal hemodynamics and intragraft gene expression. *Annals of Surgery*. 2003;237(2):256-64.

37. Kakihana Y. Phosphodiesterase III inhibitor. *Anesthesia 21 Century*. 2008;10(2-31):32-40.

38. Adachi H, Kamata S, Kodama K, Nagakura T. Vasorelaxant effect of a phosphodiesterase 3 inhibitor, olprinone, on isolated human radial artery. *European Journal of Pharmacology*. 2000;396(1):43-7.

39. Iribe G, Yamada H, Matsunaga A, Yoshimura N. Effects of the phosphodiesterase III inhibitors olprinone, milrinone, and amrinone on

hepatosplanchnic oxygen metabolism. *Critical Care Medicine*. 2000;28(3):743-8.

40. Monshouwer M, van't Klooster GAE, Nijmeijer SM, Witkamp RF, van Miert A.

Characterization of cytochrome P450 isoenzymes in primary cultures of pig hepatocytes.

Toxicology in Vitro. 1998;12(6):715-23.

FIGURE LEGENDS

Figure 1. Details of the 4 groups according to the dose of OLP, treatment time, and timings of liver biopsy

Figure 2. Results of the hemodynamic (A–D) and biochemical studies (E, F): (A) portal venous pressure; (B) systolic arterial blood pressure; (C) central venous pressure; (D) PVP to CVP gradient; (E) serum total bilirubin level; and (F) prothrombin time. * $P < 0.05$, vs. group A.

Figure 3. Representative photographs of hematoxylin and eosin staining ($\times 100$). In group A, swollen hepatocytes were observed 1 h after hepatectomy in the periportal area (A), and sinusoidal hemorrhage spread within periportal connective tissues 3 h after hepatectomy (B). In group B, these findings were more marked. Necrosis of hepatocytes was observed 1 h after hepatectomy (C and C' ($\times 200$)), and sinusoidal hemorrhage was more severe (D and D' ($\times 200$)). In contrast, in groups C and D, these findings were rarely observed, and the structure around the portal vein was preserved both 1 h (E, G) and 3 h (F, H) after hepatectomy.

Figure 4. Representative photographs of immunostaining for CD31 ($\times 100$). (A) Control pigs before surgery; (B, C) group A 1 and 3 h after hepatectomy; (D, E) group B 1 and 3 h after hepatectomy; (F, G) group C 1 and 3 h after hepatectomy; (H, I) group D 1 and 3 h after hepatectomy. (J) The relative CD31 expression was quantified morphometrically. The data are expressed as the mean and standard deviation. $*P < 0.05$ vs. group A).

Figure 5. Micrographs of hepatic sinusoids on transmission electron microscopy ($\times 4000$). (A) Control pigs before surgery; (B, C) group A 1 and 3 h after hepatectomy; (D, E) group B 1 and 3 h after hepatectomy; (F, G) group C 1 and 3 h after hepatectomy; (H, I) group D 1 and 3 h after hepatectomy. Asterisks indicate the space of Disse, and arrows indicate endothelial cells.

Figure 6. The results of the (A) liver volume increase ratio at POD 7, and (B) ICGk ratio at POD 7. The liver volume increase ratio at POD 7 was calculated using the following formula: (remnant liver volume at POD 7)/(resected liver volume $\times 3/7$). This formula was based on an approximate value considering that the procedure used in this study was 70% partial hepatectomy.^{20,21} The ICGk ratio was calculated using the following formula: (ICGk at POD 7)/(ICGk before surgery). The data are expressed as

the mean and standard deviation. * $P < 0.05$ vs. group A.

Figure 7. (A) Western blot analysis of hepatic eNOS just before hepatectomy. The relative eNOS levels were quantified by densitometry. The data are expressed as the mean and standard deviation. (B-E) Representative photographs of immunostaining for eNOS just before hepatectomy ($\times 200$). (B) Group A; (C) group B; (D) group C; (E) group D. Staining of eNOS in hepatocytes and endothelial cells was more prominent in OLP treatment groups than in group A. Arrows indicate endothelial cells.

Figure 8. Serum OLP concentration. Data are expressed as the mean and standard deviation.

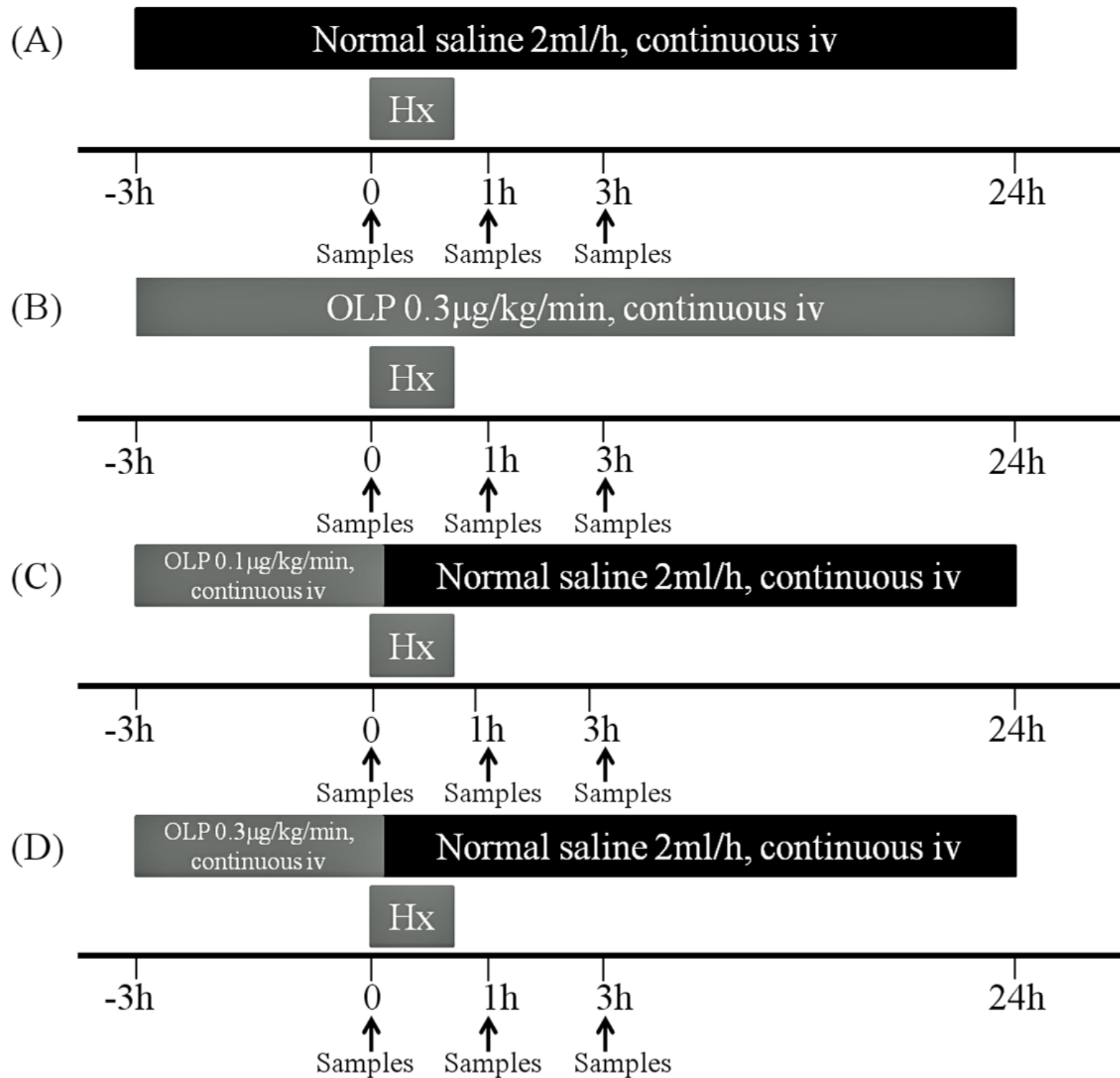


Figure 1

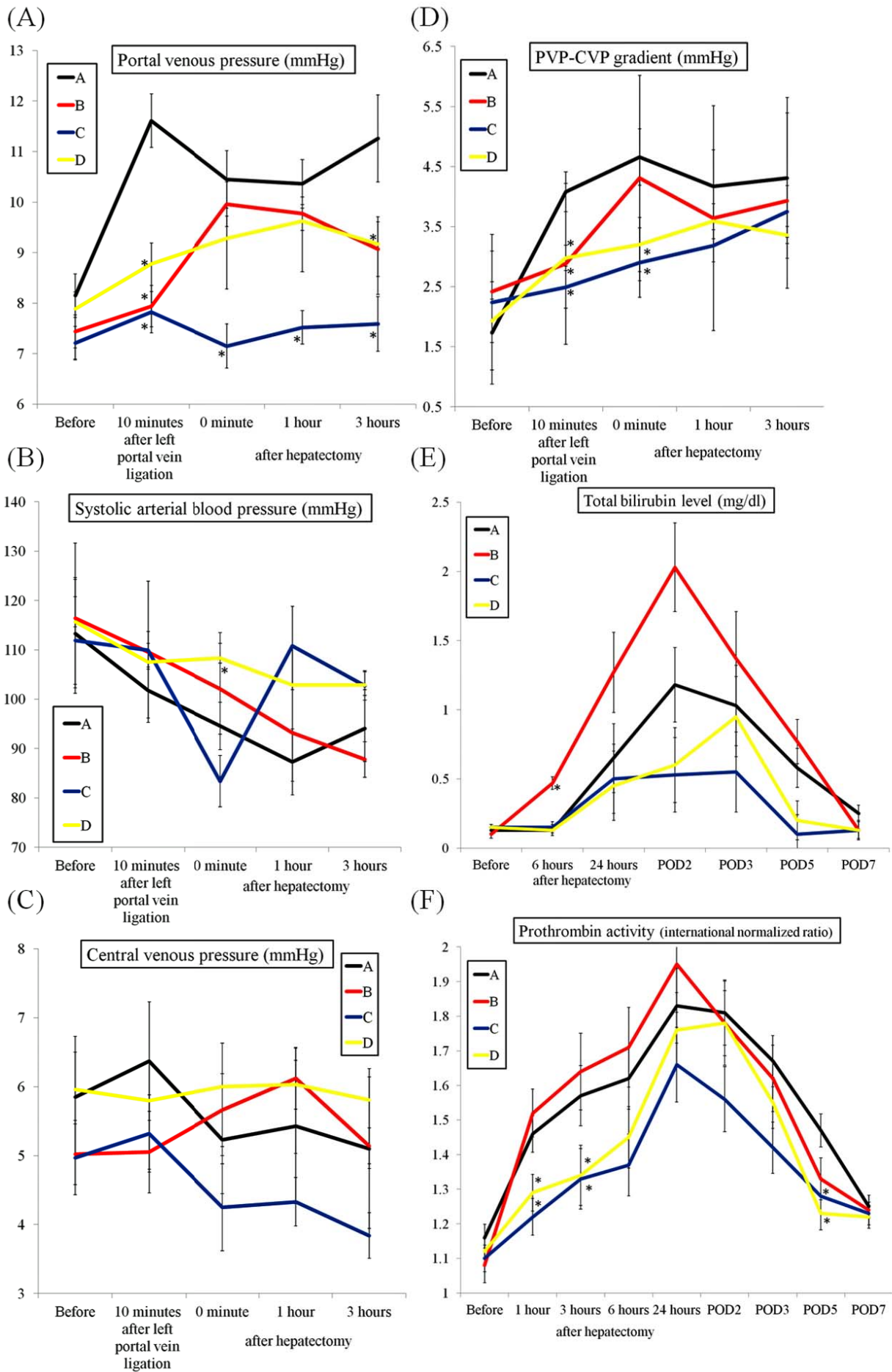


Figure 2

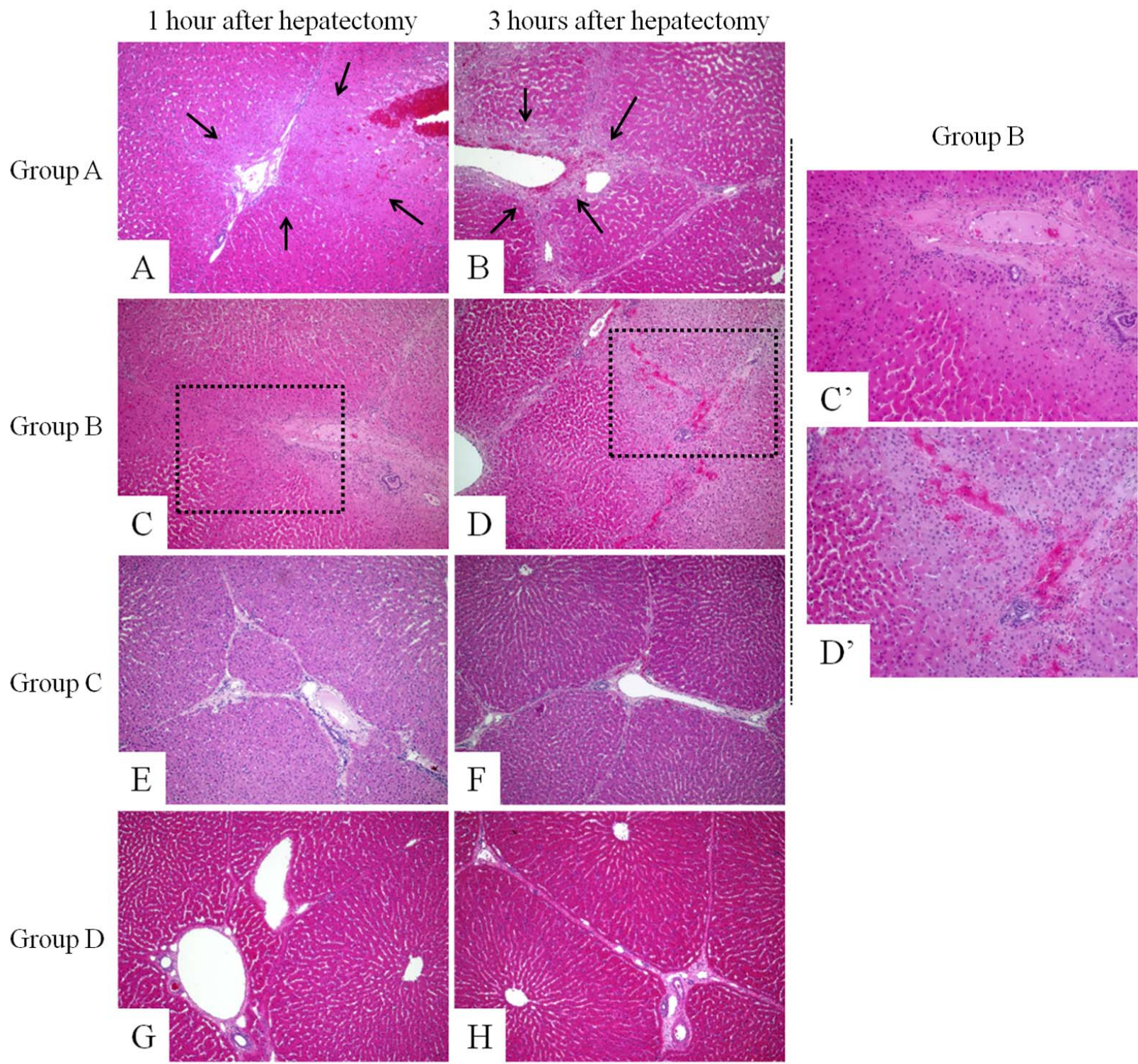


Figure 3

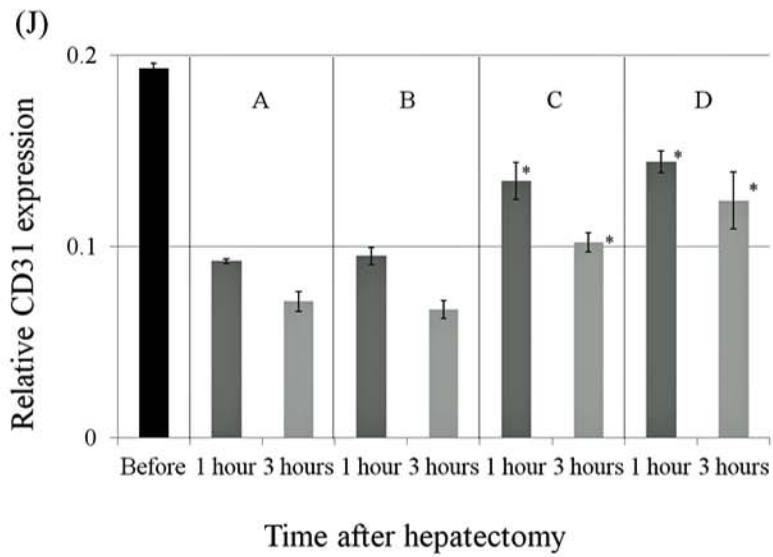
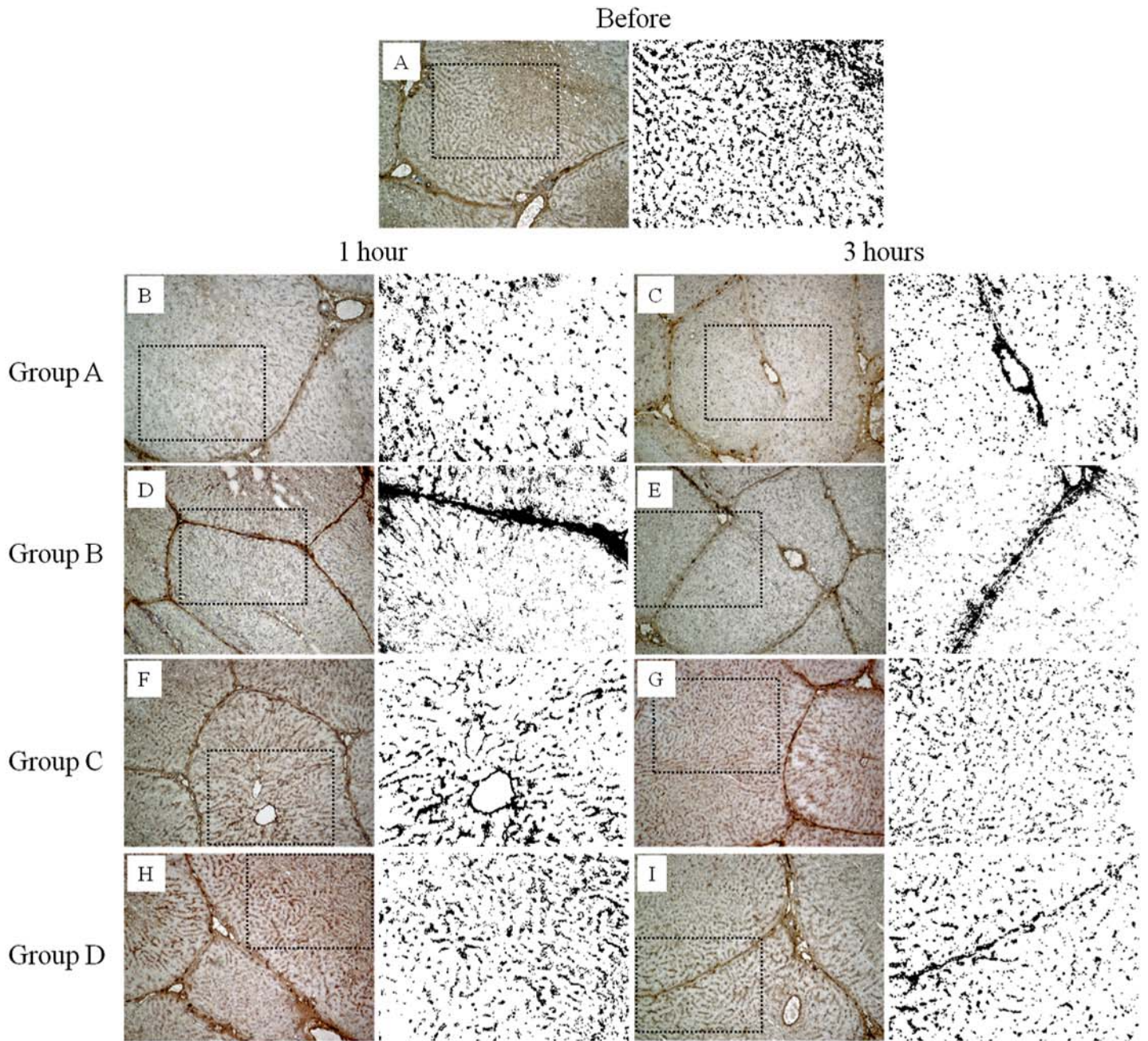
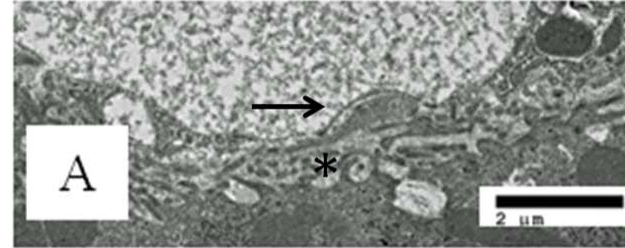


Figure 4

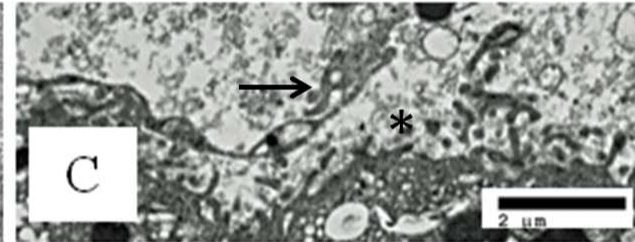
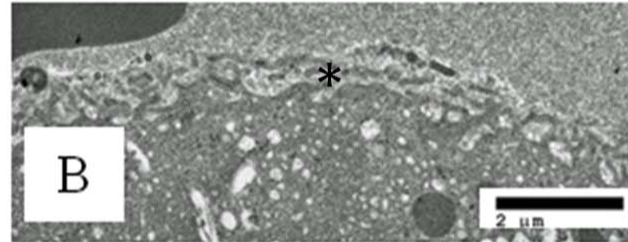
Before



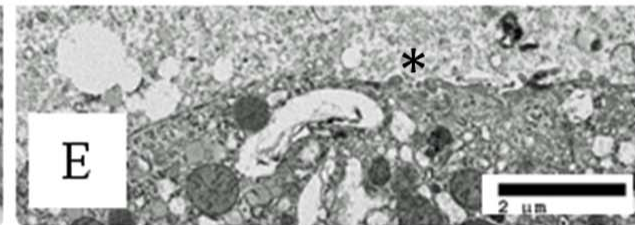
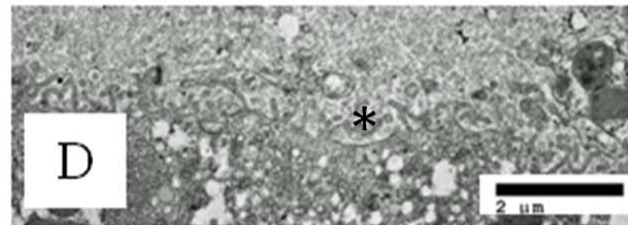
1 hour

3 hours

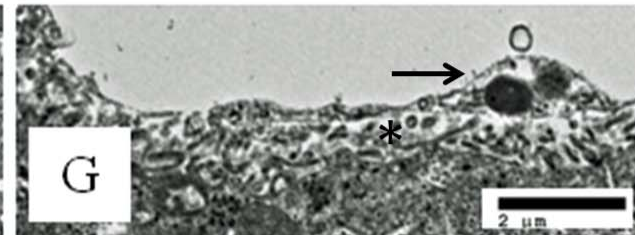
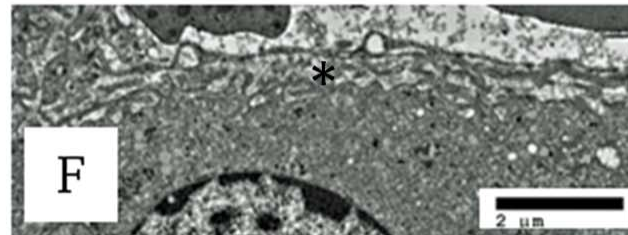
Group A



Group B



Group C



Group D

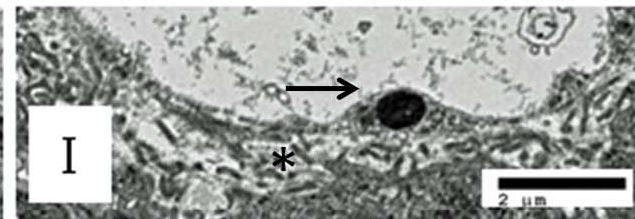
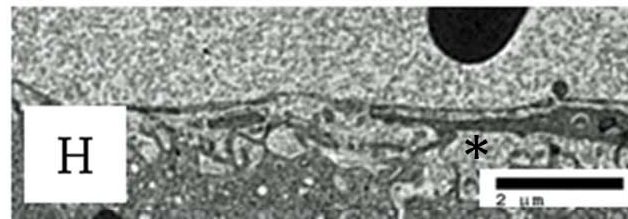


Figure 5

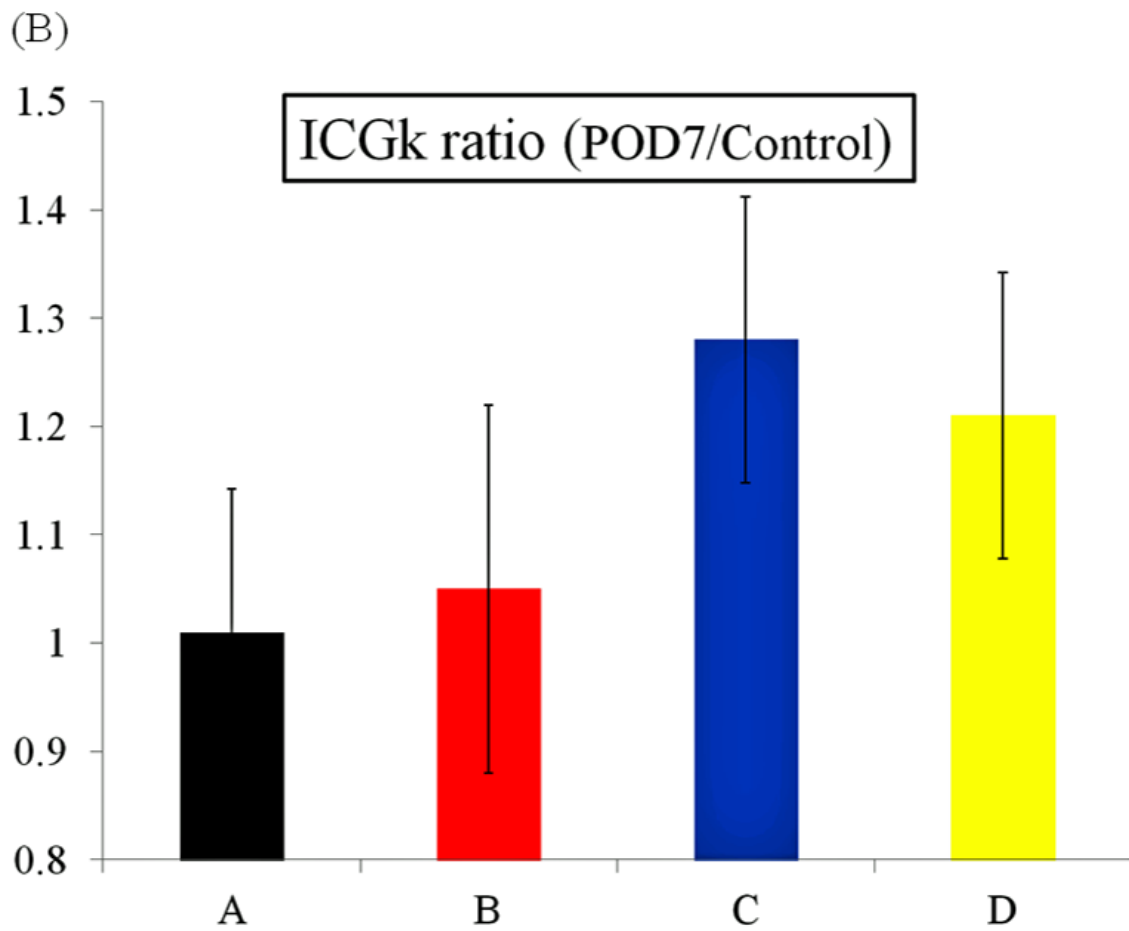
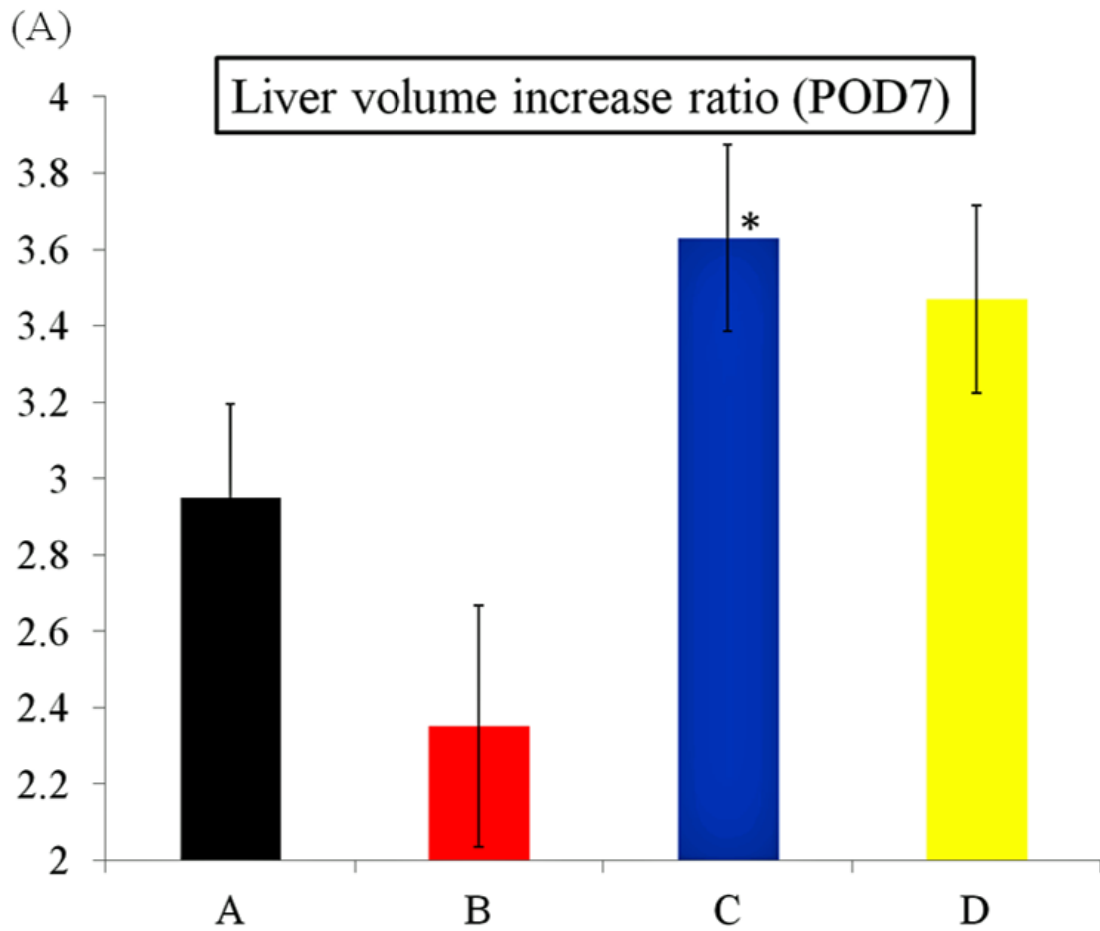


Figure 6

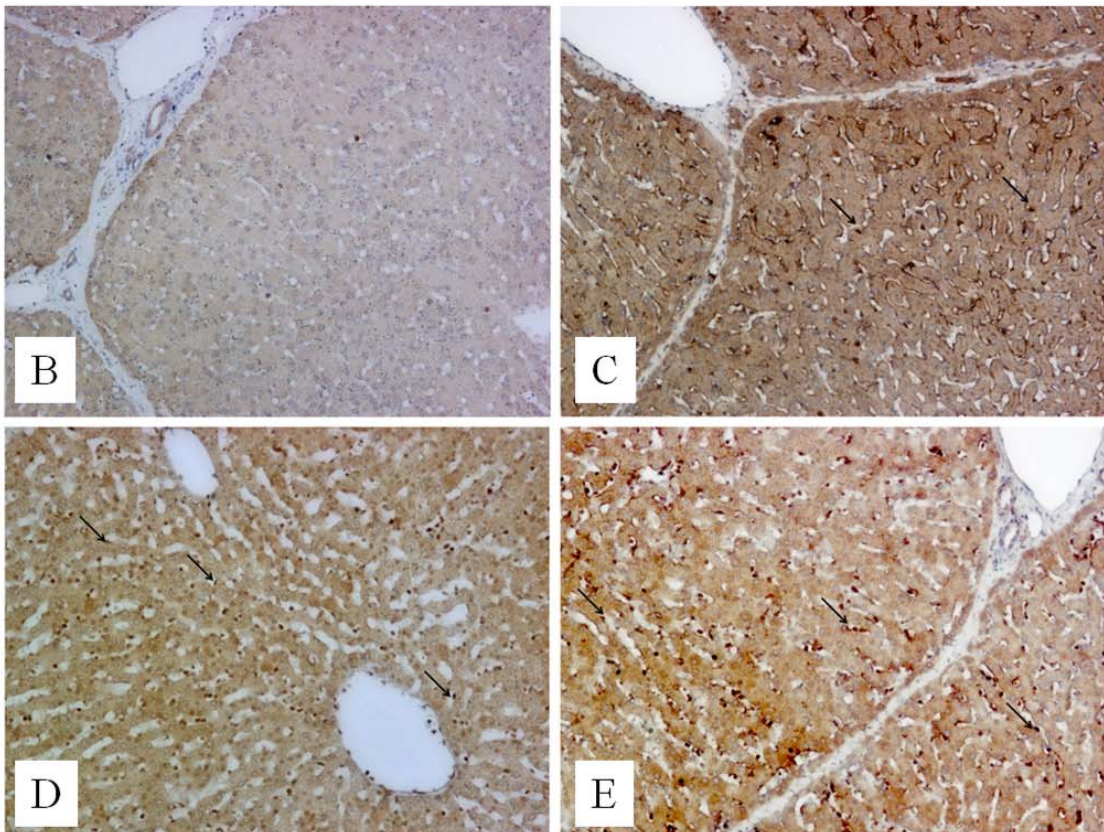
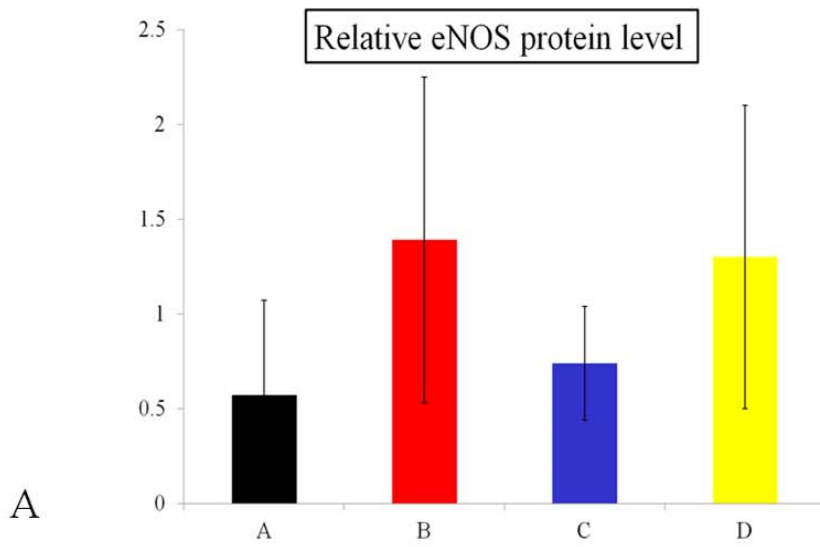
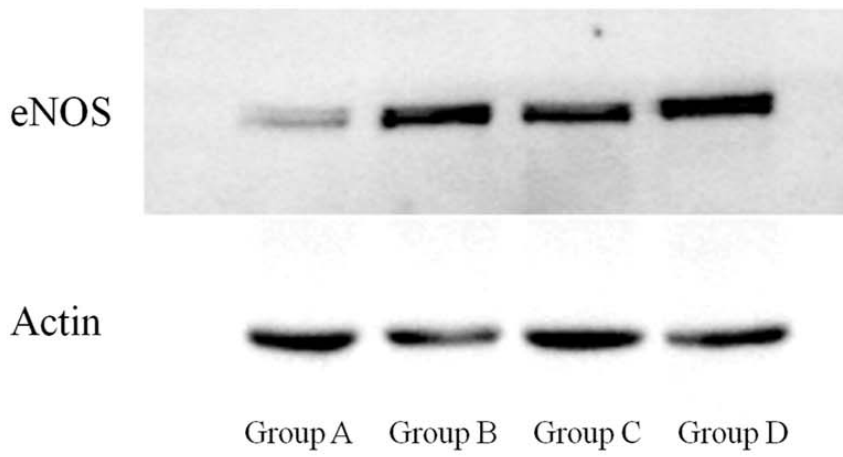


Figure 7

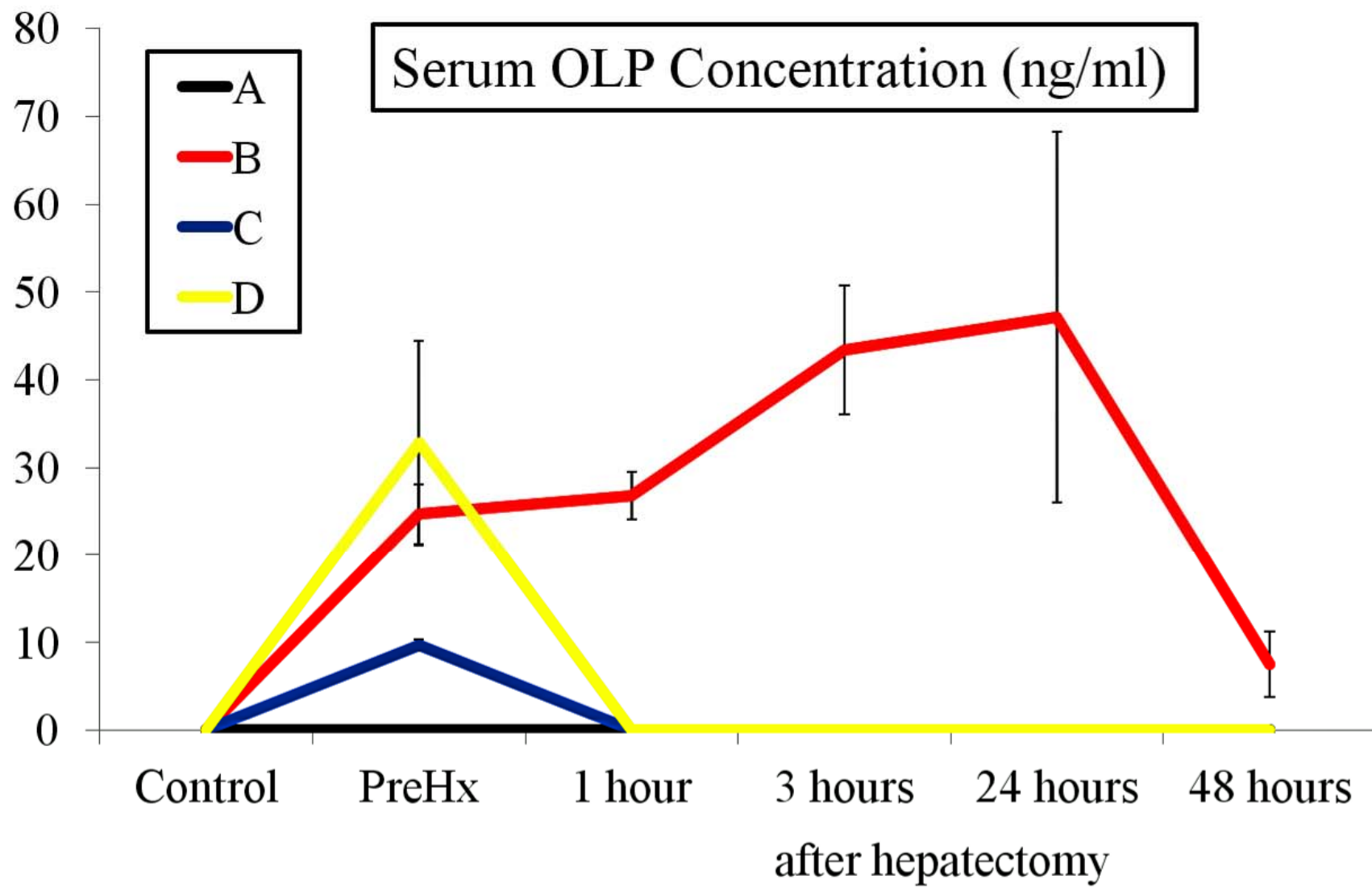


Figure 8

TABLE 1 Characteristics of the pigs in each group

Characteristic	A (n = 5)	B (n = 3)	C (n = 5)	D (n = 5)
Body weight (kg)	21.4	21.5	20.9	22.2
Resected liver volume (kg)	0.21	0.23	0.21	0.21
Resected liver volume/body weight	0.010	0.011	0.010	0.010
Estimated remnant liver volume (kg) ^a	0.09	0.11	0.09	0.09

Values are means.

^aEstimated remnant liver volume was calculated by multiplying 3/7 by the resected liver volume, which was based on an approximate value considering that the procedure used in this study was 70% partial hepatectomy.^{20,21}

