

Title	BMP2 gene mutation in pulmonary arteriovenous malformation and pulmonary hypertension: a case report.
Author(s)	Handa, Tomohiro; Okano, Yoshiaki; Nakanishi, Norifumi; Morisaki, Takayuki; Morisaki, Hiroko; Mishima, Michiaki
Citation	Respiratory investigation (2014), 52(3): 195-198
Issue Date	2014-05
URL	<a href="http://hdl.handle.net/2433/188945">http://hdl.handle.net/2433/188945</a>
Right	© 2013 The Japanese Respiratory Society. Published by Elsevier Japan KK
Type	Journal Article
Textversion	author

***BMPR2* gene mutation in pulmonary arteriovenous malformation and pulmonary hypertension: a case report**

**Author names and affiliations:**

Tomohiro Handa, MD, PhD<sup>a</sup> (hanta@kuhp.kyoto-u.ac.jp), Yoshiaki Okano, MD, PhD<sup>b</sup>

(yokano2@kuhp.kyoto-u.ac.jp), Norifumi Nakanishi, MD, PhD<sup>c</sup>

(nnakanis@hsp.ncvc.go.jp), Takayuki Morisaki, MD, PhD<sup>d</sup> (morisaki@ri.ncvc.go.jp),

Hiroko Morisaki, MD, PhD<sup>d</sup> (hirokom@ri.ncvc.go.jp), Michiaki Mishima, MD, PhD<sup>a</sup>

(mishima@kuhp.kyoto-u.ac.jp)

<sup>a</sup> Department of Respiratory Medicine, Graduate School of Medicine, Kyoto University,

Kyoto, Japan

<sup>b</sup> Department of Internal Medicine, Hanwa Daini Senboku Hospital, Sakai, Japan

<sup>c</sup> Division of Pulmonary Circulation, Department of Cardiovascular Medicine, National

Cerebral and Cardiovascular Center, Suita, Japan

<sup>d</sup> Department of Bioscience and Genetics, National Cerebral and Cardiovascular Center

Research Institute, Suita, Japan

**Short title:** Pulmonary hypertension in PAVM

**Correspondence to:** Tomohiro Handa MD, PhD

Assistant Professor, Department of Rehabilitation Medicine/Respiratory Medicine,

Kyoto University Hospital, 54 Shogoin Kawahara-cho, Sakyo, Kyoto 606-8507, Japan

Telephone number: +81 75 751 3830; Fax number: +81 75 751 4643

E-mail address: [hanta@kuhp.kyoto-u.ac.jp](mailto:hanta@kuhp.kyoto-u.ac.jp)

## **Abstract**

The transforming growth factor- $\beta$  superfamily signaling pathway is thought to be involved in the pathogenesis of pulmonary arteriovenous malformation (PAVM).

However, the association between *bone morphogenetic protein receptor type 2* (*BMPR2*) gene mutations and PAVM remains unclear. We present a case of concurrent PAVM and pulmonary arterial hypertension (PAH), with a deletion mutation in exon 6 and exon 7 of the *BMPR2* gene. Drug treatment for PAH improved the patient's hemodynamics and exercise capacity, but worsened oxygenation. This case suggests that *BMPR2* gene mutation may be associated with the complex presentation of PAVM combined with PAH.

**Keywords:** ambrisentan, *bone morphogenetic protein receptor type 2*, pulmonary arterial hypertension, pulmonary arteriovenous malformation, sildenafil

## **Abbreviation list**

*ACVRL1 = activin A receptor type 2-like 1*

BMP = bone morphogenetic protein

*BMPR2 = bone morphogenetic protein receptor type 2*

CI = cardiac index

CO = cardiac output

*MADH4 = decapentaplegic homologue 4*

ENG = endoglin

HHT = hereditary hemorrhagic telangiectasia

HRCT = high resolution computed tomography

*MADH4 = decapentaplegic homologue 4*

PAH = pulmonary arterial hypertension

PAP = pulmonary artery pressure

PAVM = pulmonary arteriovenous malformation

PCWP = pulmonary capillary wedge pressure

PVR = pulmonary vascular resistance

RHC = right heart catheterization

TGF- $\beta$  = transforming growth factor- $\beta$

## 1. Introduction

Hereditary pulmonary arterial hypertension (PAH) and hereditary hemorrhagic telangiectasia (HHT) are associated with mutations in the transforming growth factor- $\beta$  (TGF- $\beta$ ) and bone morphogenetic protein (BMP) pathways and have a major impact on lung vasculature [1, 2]. Pulmonary arteriovenous malformation (PAVM) is a complication of HHT, occurring in 20–40% of patients. Conversely, approximately 80–95% of PAVM cases are associated with HHT [3]. The most frequent cause of hereditary PAH is *bone morphogenetic protein receptor type 2 (BMPR2)* gene mutation. However, its association with HHT or PAVM remains unclear. We present a case of concurrent PAVM and PAH, with a novel deletion mutation in exon 6 and exon 7 of the *BMPR2* gene.

## 2. Case report

A 33-year-old woman was referred to a clinic due to cough, where she was found to have a chest CT abnormality. At presentation in our hospital, she had no chest symptoms. Physical examination revealed a body temperature of 36.5°C, blood pressure

of 116/78 mmHg, and pulse rate of 80 beats/min with a regular rhythm. Heart and lung auscultation revealed no abnormalities, and there was no pretibial edema. There was no sign of mucocutaneous telangiectases on the fingers, lips, or oral cavity. Additionally, there was no previous history of drug abuse. Moreover, there was no family history of HHT, recurrent nasal hemorrhage, or abnormal chest shadow. Laboratory tests showed mild polycythemia, and autoantibody screening for collagen vascular diseases was negative. Electrocardiography and arterial blood gas at rest revealed no abnormalities. Pulmonary function tests showed decreased diffusing capacity (supplementary Table S1). Chest HRCT revealed meandering vasculature in bilateral lung fields (Fig. 1A). A 3-dimensional reconstruction image showed a saccular aneurysm with an afferent artery and efferent vein, suggesting the presence of PAVM (Fig. 1B). Tc MAA scintigraphy and the 100% oxygen inhalation method showed a mild increase in the arteriovenous shunt ratio (8.4% and 5.1%, respectively), and contrast echocardiography revealed microbubble flow from the pulmonary vein to the left atrium, such that LA enhancement was delayed from RA enhancement by more than 3 cardiac cycles. Based on these findings, the patient was diagnosed with multiple PAVMs. Abdominal CT and



brain MRI showed no AVM in other organs, and portal hypertension was ruled out by abdominal echocardiogram. According to the International Clinical Diagnostic Criteria for HHT, a diagnosis of HHT was unlikely [4].

Right heart catheterization (RHC) revealed concurrent pulmonary arterial hypertension as follows: pulmonary artery pressure (PAP) 55/29 (41) mmHg, pulmonary capillary wedge pressure (PCWP) 14 mmHg, cardiac output (CO) 3.81 L/min, cardiac index (CI) 2.75 L/min/m<sup>2</sup>, pulmonary vascular resistance (PVR) 7.1 Wood. A series of examinations showed no evidence of left-sided heart failure, pulmonary embolism, obstructive or restrictive pulmonary disease, portal hypertension, or connective tissue disease. Mutation analysis of entire coding exons and adjacent introns of the *BMP2*, *endoglin (ENG)*, *activin A receptor type 2-like 1 (ACVRL1)*, and *decapentaplegic homologue 4 (MADH4)* genes was performed by bidirectional direct DNA sequencing after PCR amplification of genomic DNA. Analysis of large-scale gene rearrangements in *BMP2*, *ENG*, and *ACVRL1* was performed using multiplex ligation-dependent probe amplification. This genetic study was approved by the ethics committees of the National Cerebral and Cardiovascular Center Research Institute

(approval number M20-01-3, November 17, 2011). No *ACVRL1* or *ENG* mutation was identified. However, a heterogeneous germline deletion mutation of exon 6 and exon 7 of the *BMP2* gene was identified, which was further confirmed by real-time quantitative PCR using TaqMan probes.

Because the patient was asymptomatic, she was followed-up without any specific treatment. The patient experienced mild dyspnea after she delivered a child 16 months after the diagnosis of PAVM and PAH. Follow up RHC showed worsening of PH (PAP 81/41 (56) mmHg, PCWP 14 mmHg, CO 3.59 L/min, CI 2.60 L/min/m<sup>2</sup>, PVR 10.9 Wood), although the shunt ratio was unchanged (Fig. 2). PAH-specific treatment with sildenafil (60 mg/day) and ambrisentan (5–10 mg/day) improved hemodynamics, exercise capacity, and symptoms, although oxygenation at rest and during exercise deteriorated, accompanied by mild elevation of the shunt ratio (Fig. 2). At present, the combination drug treatment is being continued with careful follow-up of the patient's oxygenation.

### **3. Discussion**

We presented a case of PAVM combined with PAH, with a *BMPR2* gene mutation. The diagnosis of PAVM was made based on compatible findings of chest HRCT and contrast echocardiography along with an increased shunt ratio. There was no other comorbidity likely to cause PAVM, suggesting that PAVM was associated with the *BMPR2* gene mutation. Aside from PAVM, this patient had no features suggestive of HHT. However, because of the relatively young age of the patient, it is possible that HHT will develop in the future. Because the clinical phenotype of HHT becomes easier to identify with age, the age of onset in a Japanese cohort was reported to be >30 years in 27% of patients and >40 years in 8% of patients [5].

Although PAH and HHT have different characteristics with regard to endothelial cell and smooth muscle cell proliferation, they may share common genetic backgrounds [1, 2, 6]. Mutations in the *BMPR2* gene have been associated with 80% of familial PAH and 15–40% of idiopathic PAH cases, whereas about 80% of HHT cases are associated with heterozygous germline mutations of *ENG*, *ACVRL1*, and *MADH4* [1, 3]. Approximately 30 families with both PAH and HHT have been described, and most of them carried *ACVRL1* gene mutations [2, 6, 7, 8]. To date, there has been only one

case report of a patient with a *BMP2* mutation who had concurrent PAH and HHT with PAVM [9]. The present case, along with the previous case, suggests that *BMP2* gene mutation may be associated with the complex presentation of PAVM combined with PAH. Additionally, pre-existing PAH may have caused the PAVM. In previous reports of concurrent PAH and PAVM, the authors speculated that PAH may have caused PAVM by rupture of the hypoplastic vascular septa, an increase in the size of a previously developed arteriovenous fistula, or an enlargement of anatomically normal arteriovenous shunts [10, 11]. Unfortunately, genetic abnormalities were not investigated in these reports.

It remains unknown why gene mutations of common pathways cause different phenotypes, and why the two phenotypes co-exist in a subset of cases. It is speculated that differential distribution of the receptors and alternative ligand-receptor responses may play a role [1, 12]. BMP9 acts through ACVRL1 and SMAD1, 5, 8, and the signal is balanced by BMP2 and ActR2A [12]. *BMP2* gene mutation does not usually lead to overt HHT, because ActR2A compensates. It is speculated that in patients with HHT and *BMP2* gene mutation, this compensation may be incomplete [9]. In our patient,

the entire genomic deletion of exon 6 and exon 7 of the *BMPR2* gene, containing 231 bp and 115 bp of the coding sequence, respectively, would result in a frame shift transcript lacking 346 bp of the coding sequence, including the region coding for the kinase domain. The mutated transcript is expected to be degraded by nonsense-mediated mRNA decay, which supposedly leads to haploinsufficiency of the *BMPR2* gene product. This mutation has not been reported in the literature so far, and differs from that reported previously in concurrent HHT and PAH (nonsense mutation in exon 10) [9]. Further investigation is necessary to elucidate mechanisms by which these mutations cause both PAVM and PAH.

In the present case, PAH worsened after the delivery of a child. After the diagnosis of PAVM and PAH, we instructed the patient regarding the risks of becoming pregnant, such as an enlargement of the PAVM and increased risk of pulmonary hemorrhage and cerebrovascular events [13, 14]. Additionally, PAH during pregnancy is associated with a high risk to the parturient [15]. Because of the risk posed by PAVM and PAH, we believe that pregnancy should be avoided in this situation.

The patient had no hypoxemia during rest, whereas oxygen desaturation was

observed on exercise. This may be due to a small increase in the shunt ratio at rest, and the shunt ratio and ventilation/perfusion mismatch may have increased during exercise because of the increased vascular resistance of the pulmonary arteries. Regarding the medical treatment of patients with PAVM and PAH, some authors do not recommend vasodilator therapy because of a potential increase of arteriovenous shunt volume, while others have demonstrated the effectiveness and safety of endothelin receptor antagonists in this disease [16, 17]. In our case, combination therapy improved exercise capacity and hemodynamics, though oxygenation deteriorated, with a mild increase of the shunt ratio. One possible explanation is that the increased shunt ratio caused by the vasodilator worsened hypoxemia, whereas the drug decreased pulmonary vascular resistance, leading to increased cardiac output and improved exercise capacity. Taking the potential adverse effect on shunt ratio into account, careful follow-up of oxygenation is required when PAH-specific therapy is applied to patients with PAVM and PAH.

In conclusion, PAVM and PAH can occur in association with germline *BMPR2* gene mutations. Screening for *BMPR2* gene mutation should be considered in this

complex disease.

### **Acknowledgement**

We would like to acknowledge the patient, her family, and the nurses involved in her care. We thank Dr. Yoshinobu Konishi, Dr. Kohei Ikezoe, Dr. Kiminobu Tanizawa, Dr. Kensaku Aihara (Department of Respiratory Medicine, Graduate School of Medicine, Kyoto University), Dr. Reiko Hozo (Department of Cardiovascular medicine, Graduate School of Medicine, Kyoto University), Dr. Sonoko Nagai (Kyoto Central Clinic/Clinical Research Center), and Prof. Kazuo Chin (Department of Respiratory Care and Sleep Control Medicine, Graduate School of Medicine, Kyoto University) for their contribution to the clinical assessment. We also thank Dr. Takeshi Kubo (Department of Diagnostic Imaging and Nuclear Medicine Graduate School of Medicine, Kyoto University) for his contribution in the radiological assessment.

### **Funding Sources**

This study was supported by the Respiratory Failure study group and Diffuse Lung Disease study group from the Ministry of Health, Labour and Welfare, Japan (H23-Nanchi-Ippan-023 and 024).

**Conflict of interest**

The authors have no conflicts of interest.



## References

- [1] Upton PD, Morrell NW. TGF-beta and BMPR-II pharmacology--implications for pulmonary vascular diseases. *Curr Opin Pharmacol* 2009;9:274-80.
- [2] Trembath RC, Thomson JR, Machado RD, et al. Clinical and molecular genetic features of pulmonary hypertension in patients with hereditary hemorrhagic telangiectasia. *N Engl J Med* 2001;345:325-34.
- [3] Wong HH, Chan RP, Klatt R, et al. Idiopathic pulmonary arteriovenous malformations: clinical and imaging characteristics. *Eur Respir J* 2011;38:368-75.
- [4] Shovlin CL, Guttmacher AE, Buscarini E, et al. Diagnostic criteria for hereditary hemorrhagic telangiectasia (Rendu-Osler-Weber syndrome). *Am J Med Genet* 2000;91:66-7.
- [5] Shioya T, Kanazawa T. Osler disease: Hereditary Hemorrhagic Telangiectasia. *Kokyu* 1989;8:707-12. [in Japanese]
- [6] Harrison RE, Flanagan JA, Sankelo M, et al. Molecular and functional analysis identifies ALK-1 as the predominant cause of pulmonary hypertension related to hereditary haemorrhagic telangiectasia. *J Med Genet* 2003;40:865-71.

- [7] Abdalla SA, Gallione CJ, Barst RJ, et al. Primary pulmonary hypertension in families with hereditary haemorrhagic telangiectasia. *Eur Respir J* 2004;23:373-7.
- [8] Smoot LB, Obler D, McElhinney DB, et al. Clinical features of pulmonary arterial hypertension in young people with an ALK1 mutation and hereditary haemorrhagic telangiectasia. *Arch Dis Child* 2009;94:506-11.
- [9] Rigelsky CM, Jennings C, Lehtonen R, et al. BMPR2 mutation in a patient with pulmonary arterial hypertension and suspected hereditary hemorrhagic telangiectasia. *Am J Med Genet A* 2008;146A:2551-6.
- [10] Yoshida F, Terasawa A, Hosoe M, et al. Long-term observation of a case of pulmonary arteriovenous fistula with pulmonary hypertension. *Intern Med* 1995;34:574-6.
- [11] Sperling DC, Cheitlin M, Sullivan RW, et al. Pulmonary arteriovenous fistulas with pulmonary hypertension. *Chest* 1977;71:753-7.
- [12] Upton PD, Davies RJ, Trembath RC, et al. Bone morphogenetic protein (BMP) and activin type II receptors balance BMP9 signals mediated by activin receptor-like kinase-1 in human pulmonary artery endothelial cells. *J Biol Chem*

2009;284:15794-804.

[13] Shovlin CL, Winstock AR, Peters AM, et al. Medical complications of pregnancy in hereditary haemorrhagic telangiectasia. *QJM* 1995;88:879-87.

[14] Esplin MS, Varner MW. Progression of pulmonary arteriovenous malformation during pregnancy: case report and review of the literature. *Obstet Gynecol Surv* 1997;52:248-53.

[15] Safdar Z. Pulmonary arterial hypertension in pregnant women. *Ther Adv Respir Dis* 2013;7:51-63.

[16] Bonderman D, Nowotny R, Skoro-Sajer N, et al. Bosentan therapy for pulmonary arterial hypertension associated with hereditary haemorrhagic telangiectasia. *Eur J Clin Invest* 2006;36:71-2.

[17] Chang SA, Jang SY, Ki CS, et al. Successful bosentan therapy for pulmonary arterial hypertension associated with hereditary hemorrhagic telangiectasia. *Heart Vessels* 2011;26:231-4.

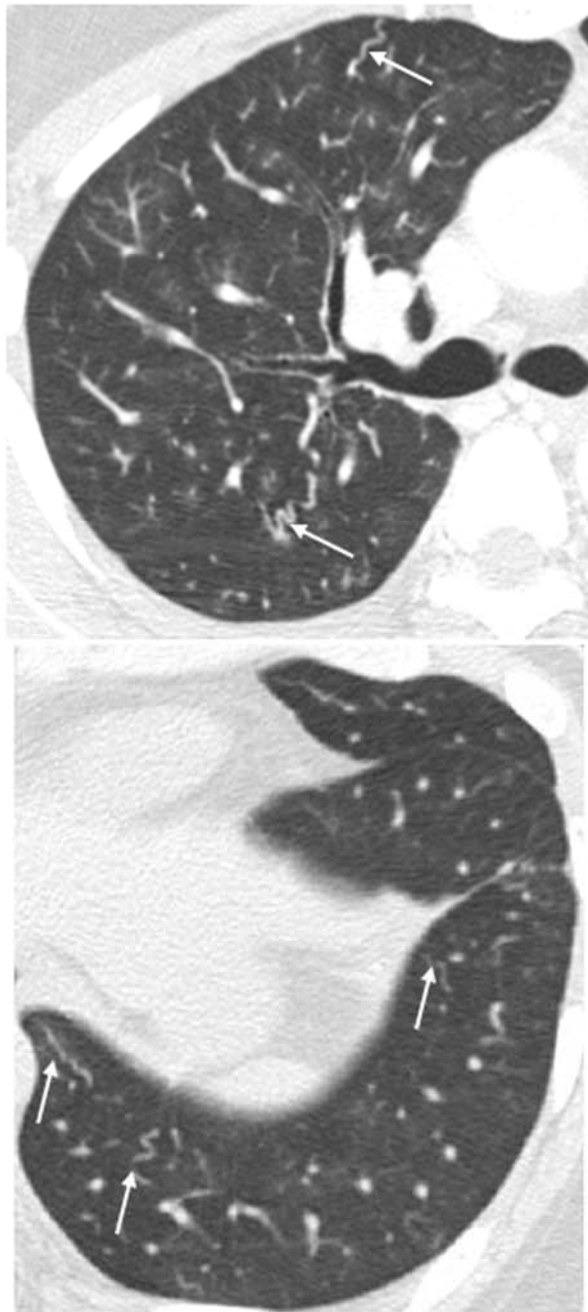
## Figure legends

Figure 1. A. Chest HRCT on admission. Multiple meandering feeding vessels (arrows) are found in bilateral lung fields. B. 3-dimensional reconstruction image of chest CT. A saccular aneurysm (5.8 mm in diameter, arrowhead) with an afferent artery (2.6 mm in diameter) and efferent vein (2.7 mm in diameter) is shown (arrows). PA, pulmonary artery; PV, pulmonary vein; AA, afferent artery; EV, efferent vein.

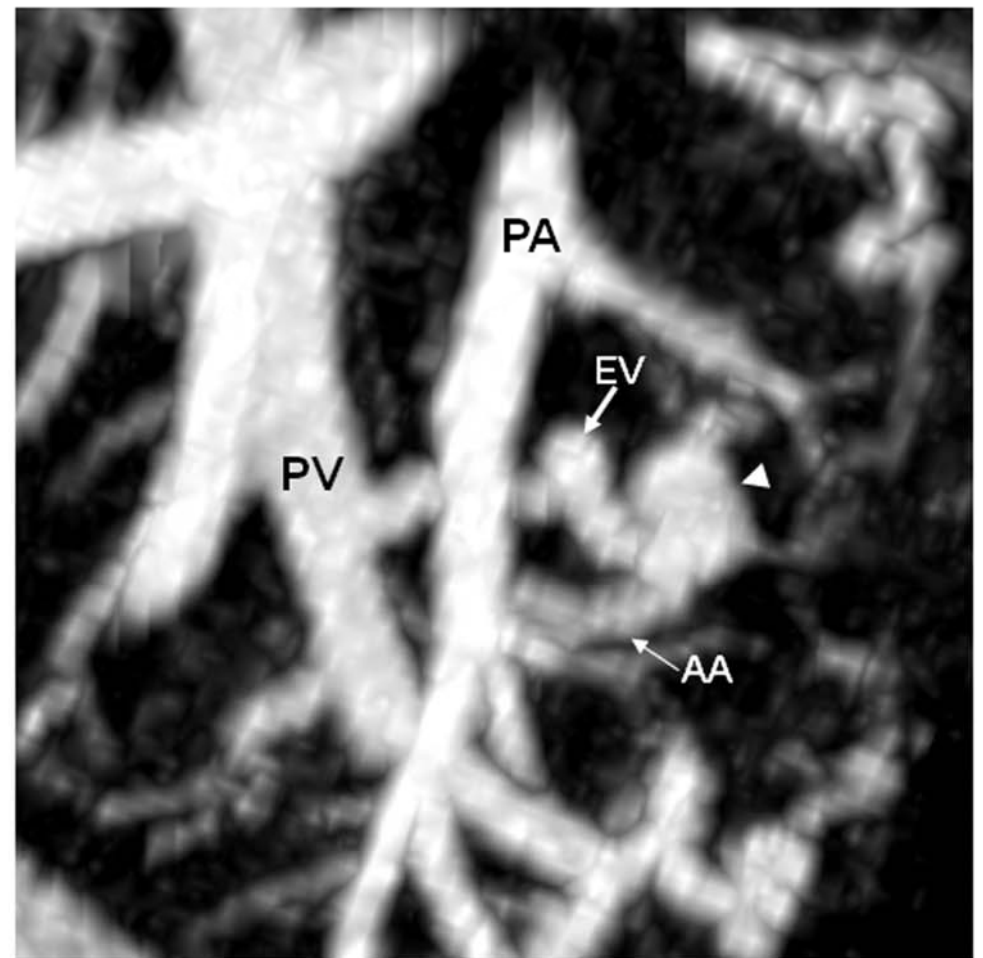
Figure 2. Clinical course of the patient. PH deteriorated after the delivery of a child.

After 5 months of combination treatment for PH, hemodynamics and clinical symptoms improved. \*Period from the start of PAH treatment. NYHA-FC, New York Heart Association Functional Class; sPAP, systolic pulmonary artery pressure estimated by Doppler echocardiogram; PAP, pulmonary artery pressure measured by right heart catheter; CI, cardiac index; PVR, pulmonary venous resistance; BNP, B-type natriuretic peptide; 6MWD, six-minute walk distance; Min SpO<sub>2</sub>, Minimal oxygen saturation during six-minute walk test.

Figure 1

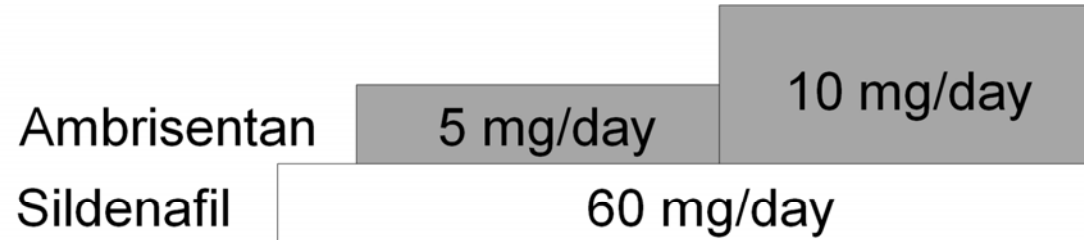


A



B

Figure 2



	At diagnosis	Before treatment	7 days*	40 days*	5 months*
NYHA-FC	I	II	I	I	I
sPAP (mmHg)	42	87	81	57	45
PAP (mmHg)	55/29 (41)	81/41 (56)	-	-	50/19 (34)
CI (L/min/m <sup>2</sup> )	2.75	2.60	-	-	2.88
PVR (Wood)	7.1	10.9	-	-	6.5
BNP (pg/mL)	7.4	7.5	21.5	17.1	7.4
Shunt ratio (%)	8.1	7.8	11.4	8.3	9.5
6MWD (m)	347	390	427	461	466
Min SpO <sub>2</sub> (%)	97	95	87	80	83
A-aDO <sub>2</sub> (torr)	17.9	12.4	17.5	16.8	28.1

↑  
Delivery of a child (16 months after the diagnosis)

Table S1. Laboratory test results on admission

<CBC>		TP (6.3–8.1)	7.2 g/dL
White blood cells	$4.6 \times 10^9/L$	$\gamma$ - globulin (10.6–20.5)	15.2%
Red blood cells	$4.78 \times 10^{12}/L$	<Arterial blood gas (room air)>	
Hemoglobin	15.2 g/dL	pH	7.401
Platelets	$207 \times 10^9/L$	PaO <sub>2</sub>	81.9 mmHg
<Coagulation>		PaCO <sub>2</sub>	40.2 mmHg
PT (sec)	11.6 s	HCO <sub>3</sub> <sup>-</sup>	24.4 mmol/L
PT (act)	100%	BE	0.2 mEq/L
APTT	27.2 s	<Pulmonary function tests>	
Fib	245 mg/dL	% VC	80.1%
D-dimer	0.2 pg/mL	%FEV <sub>1</sub>	75.5%
<Serology>		FEV <sub>1</sub> /FVC	87.9%
CRP	0.0 mg/dL	%DLCO	56.9%
Anti-nuclear antibody	< $\times 40$	%DLCO /VA	80.5%
Anti-CCP antibody	negative		
Anti-centromere antibody	negative		
Anti-Scl-70 antibody	negative		
Anti-RNP antibody	negative		
<Biochemistry>			
LDH (129–241)	184 IU/L		
CPK (35–141)	69 IU/L		

---

abbreviations: APTT, activated partial thromboplastin time; CCP, cyclic citrullinated peptide; RNP, ribonucleoprotein; LDH, lactate dehydrogenase; CPK, creatine phosphokinase; PT, prothrombin time; TP, total protein; VC, vital capacity; FEV, forced expiratory volume; FVC, forced vital capacity; DLCO, diffusing capacity for carbon monoxide.