

Title	Solid testicular mass in a 44-year-old man.
Author(s)	Murakami, Kaoru; Kobayashi, Takashi; Sumiyoshi, Shinji; Okubo, Kazutoshi; Kamba, Tomomi; Yoshimura, Koji; Ogawa, Osamu
Citation	Urology (2013), 82(6): 1204-1206
Issue Date	2013-12
URL	http://hdl.handle.net/2433/179779
Right	© 2013 Elsevier Inc.
Type	Journal Article
Textversion	author

Solid Testicular Mass in a 44-year-old man

1/9

THE CASE

A 44-year-old man presented to our clinic with complaints of a left testicular mass. This mass was noted 6 months earlier by the patient. He reported left scrotal pain for a week prior to the visit but denied scrotal trauma or frank pain. He also denied voiding symptoms, gross hematuria, penile discharge, fever, or weight loss. His urologic history was insignificant while his medical and surgical history was significant only for hypertension. He also denied smoking.

On physical examination, the patient had a firm, round and motile left scrotal mass with mild tenderness. Complete blood cell count and serum biochemistry tests revealed no significant abnormality. Serum lactic dehydrogenase (LDH, 185 IU/l, normal 124–226 IU/l), α -fetoprotein (AFP, 6.9 ng/ml, normal <15 ng/ml), β -subunit of human chorionic gonadotropin (hCG- β , <0.1 ng/ml, normal <0.2 ng/ml) and C-reactive protein (CRP, 0 mg/dl, normal <0.2 mg/dl) were not elevated. A tuberculin skin reaction was slightly positive, suggesting no active tuberculosis infection.

A ultrasonography imaging revealed a heterogeneously hypoechoic and hypovascular lesion 3 cm in diameter within the left testis (Fig. 1) with apparently intact epididymis separated from the tumor. Multiple cystic lesions were also observed to the left side of the prostate while the left kidney was not visualized.

Solid Testicular Mass in a 44-year-old man

2/9

A computed tomography scan also showed a solid, weakly enhanced mass in the left scrotum, and multiple cystic masses on the left seminal vesicle, the highly hypoplastic left kidney and no retroperitoneal lymphadenopathy (Fig. 2).

DIFFERENTIAL DIAGNOSIS

Based on these findings of unilateral renal hypogenesis and ipsilateral seminal vesicle cyst, Zinner syndrome was diagnosed. As it is very rare anatomic anomaly, no case with concomitant disease causing scrotal solid mass has been reported for this syndrome.

As for testicular solid mass, testicular cancer including seminoma and nonseminomatous germ cell tumor should be primarily considered. Non-germ cell tumor comprises Leydig cell, Sertoli cell, and granulosa cell tumors. As the patient is a middle-aged man, lymphoma, spermatocytic seminoma, and a metastatic lesion are also differential. Soft tissue sarcomas are usually presented as a paratesticular mass.

Benign testicular tumors include epidermoid cyst, Leydig cell hyperplasia, gonadal stromal fibroma, hemangioma, leiomyoma, angioleiomyoma and neurofibroma.^{1,2} Epidermoid cysts, most common in benign solid testicular

Solid Testicular Mass in a 44-year-old man

3/9

mass lesions, and fibroma of gonadal stromal origin can occur in patients who are aged 30 to 50 years as a painless testicular mass.^{1,2} Testicular hemangioma and hemorrhage can also be presented as a testicular solid mass in any age of men. Although rare as a testicular mass, sarcoidosis and tuberculosis can also cause masses with a heterogeneous appearance. However, tuberculosis more commonly affects the epididymis.

Although the appearance on ultrasound imaging of our patient with heterogeneous low echogenicity was consistent with any of above-mentioned testicular solid masses, concern for malignant testicular tumor could not ruled out and the patient underwent a left inguinal orchiectomy. Postoperative course was uneventful and the patient discharged hospital on postoperative day 4. The left testicle was sent for pathologic diagnosis.

PATHOLOGY (PRESENTET BY SHINJI SUMIYOSHI, M.D.)

Gross examination of the specimen revealed a firm, well circumscribed, dark brown lesion measuring 5.5 cm in greatest diameter, with heterogeneous, and partly hemorrhagic or spongy appearance on the cut section (Fig. 3A). The mass occupied most of the testicle. Histopathological examination revealed

Solid Testicular Mass in a 44-year-old man

4/9

granulomatous inflammation and fibrosis occupying the testis to epididymis (Fig. 3B-D). Epididymal ducts were cystically dilated containing proteinous material and many macrophages. There was neither necrotic focus nor neoplastic lesion. No pathogenic microorganisms were detected with Grocott or Periodic acid-Schiff stain. Polymerase chain reaction revealed no evidence of any acid-fast bacteria including *Mycobacterium tuberculosis* and *Mycobacterium avium*. These findings were consistent with the diagnosis of granulomatous orchitis.

DISCUSSION

Zinner syndrome is a rare abnormality which was first reported by Zinner in 1914, characterized by unilateral renal agenesis, ipsilateral seminal vesicle cyst, and ejaculatory duct obstruction.³ The suggested etiology includes anomaly of the mesonephric (Wolffian) duct between 4th and 13th gestational weeks.⁴ Most patients are asymptomatic and diagnosed occasionally or due to male infertility, although some patients may present pelvic pain, perineal discomfort, painful ejaculation, or lower urinary tract symptoms such as dysuria or urgency.⁵ Abdominal and pelvic imagings by ultrasound or CT scans are useful for

Solid Testicular Mass in a 44-year-old man

5/9

detecting renal anomaly and seminal vesicle cyst,⁶ while anomaly of the mesonephric duct as well as seminal vesicle cyst may be best evaluated by MRI.⁷ No treatment is required for asymptomatic patients with Zinner syndrome and surveillance is the best option in the absence of clinical symptom. For symptomatic patients who failed conservative treatments, transurethral, laparoscopic, and robotic surgeries should be considered adapting clinical problems.⁸

Granulomatous orchitis, first reported by Grunberg in 1926,⁹ is also a relatively rare disease characterized by chronic inflammation with granulomas in the testicular interstitium or tubules. Most of patients present unilateral scrotal swelling with or without pain. It is often difficult to differentiate it preoperatively from malignant testicular tumor since there are no specific findings on imaging studies including ultrasonography, computed tomography (CT), and magnetic resonance imaging (MRI) to granulomatous orchitis.¹⁰ Additionally, conservative medical treatments are scarcely effective, although some investigators have reported successful treatment of granulomatous orchitis with corticosteroid.¹¹ Moreover, an involved testis is often almost totally replaced with granuloma. Therefore, surgical resection by inguinal orchiectomy is usually a treatment of

Solid Testicular Mass in a 44-year-old man

6/9

choice. Particularly in the present case, removal of involved testis would not affect the patient's fertility since the ipsilateral ejaculatory duct is already obstructed. Although influence of orchiectomy on testicular endocrinological function is unclear, an inguinal orchiectomy should be recommended for patients with granulomatous orchitis as far as the contralateral testis is healthy.

The etiology of granulomatous orchitis still remains obscure and most of the cases are considered as "idiopathic" granulomatous orchitis. To date, spermatic tract obstruction, vascular insufficiency, immunologic reaction to sperm, a specific infection (such as *Mycobacterium tuberculosis* and *Mycobacterium avium*), and trauma have been proposed.¹² The present case may provide an important implication for the etiology of granulomatous orchitis. Although direct relationship with Zinner syndrome in the present case is difficult to prove, ipsilateral spermatic tract occlusion due to ejaculatory duct obstruction might have affected. Indeed, dilatation of vas deferens was evident in the pathological examination on orchiectomy specimen.

In summary, we report, to the best of our knowledge, the first case of granulomatous orchitis in a man with Zinner syndrome. Although coexistence has not been reported due to the rarity of both granulomatous orchitis and Zinner

Solid Testicular Mass in a 44-year-old man

7/9

syndrome, future accumulation of case records is warranted to elucidate real etiology of granulomatous orchitis.

Solid Testicular Mass in a 44-year-old man

8/9

References

1. Park SB, Lee WC, Kim JK *et al.*: Imaging features of benign solid testicular and paratesticular lesions. *Eur Radiol.* 2011, 21: 2226-2234.
2. Frias-Kletecka MC and MacLennan GT: Benign soft tissue tumors of the testis. *J Urol.* 2009, 182: 312-313.
3. Zinner A: Ein fall von intravesikaler Samenblasenzyste. *Wien Med Wochenschr.* 1914, 64: 605.
4. Denes FT, Montellato NI, Lopes RN *et al.*: Seminal vesicle cyst and ipsilateral renal agenesis. *Urology.* 1986, 28: 313-315.
5. Ghonge NP, Aggarwal B and Sahu AK: Zinner syndrome: A unique triad of mesonephric duct abnormalities as an unusual cause of urinary symptoms in late adolescence. *Indian J Urol.* 2010, 26: 444-447.
6. Livingston L and Larsen CR: Seminal vesicle cyst with ipsilateral renal agenesis. *AJR Am J Roentgenol.* 2000, 175: 177-180.
7. Arora SS, Breiman RS, Webb EM *et al.*: CT and MRI of congenital anomalies of the seminal vesicles. *AJR Am J Roentgenol.* 2007, 189: 130-135.
8. Pereira BJ, Sousa L, Azinhais P *et al.*: Zinner's syndrome: an up-to-date review of the literature based on a clinical case. *Andrologia.* 2009, 41: 322-330.
9. Grunberg H: Uber drei ungewonliche Falle von chronischer Orchitis unter dem klinischen Blide eines Hondentumors. *Frankfurt Zeitschr Path.* 1926, 33: 217-227.
10. Dhand S and Casalino DD: Idiopathic granulomatous orchitis. *J Urol.* 2011, 186: 1477-1478.
11. Chilton CP and Smith PJ: Steroid therapy in the treatment of granulomatous orchitis. *Br J Urol.* 1979, 51: 404-405.
12. Wegner HE, Loy V and Dieckmann KP: Granulomatous orchitis--an analysis of clinical presentation, pathological anatomic features and possible etiologic factors. *Eur Urol.* 1994, 26: 56-60.

Solid Testicular Mass in a 44-year-old man

9/9

Figure legends

Figure 1

Ultrasound image of left testicle showed a heterogenously low echogenic tumor within the left testis and normal left epididymis.

Figure 2

Computed tomography revealed multiple cystic lesions on the left seminal vesicle (A, B) and the highly hypoplastic left kidney (C).

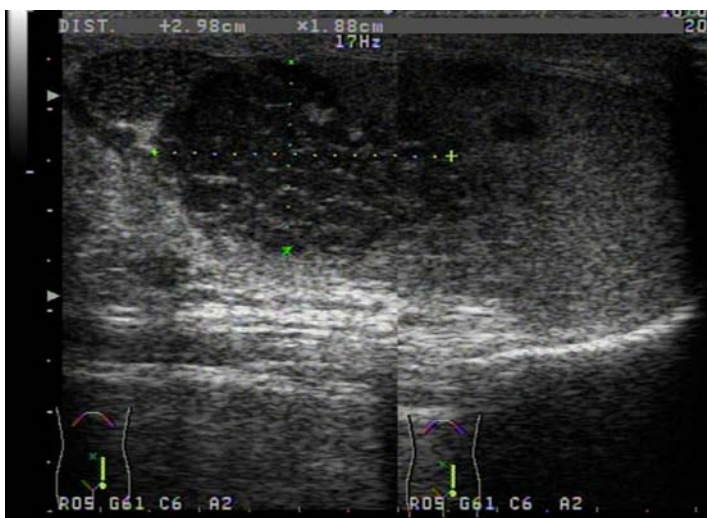
Figure 3

A: Macroscopic appearance of surgical specimen of left inguinal orchiectomy showed a heterogenous cut surface partly occupied with hemorrhagic or spongy lesions. The ipsilateral vas deferens and epididymis were not involved but dilated presumably due to ejaculatory duct obstruction for Zinner syndrome. B-D: Representative microscopic images of hematoxyline and eosin stain characterized by massive stromal infiltration and fibrosis (B) accompanied with granulomatous inflammation with foam cell infiltration (C) and dilatation of epididymal ducts (D). Original magnification x40 (B) and x100 (C, D). Bars represent 250 mm (B) and 100 mm (C, D).

Solid Testicular Mass in a 44-year-old man

10/9

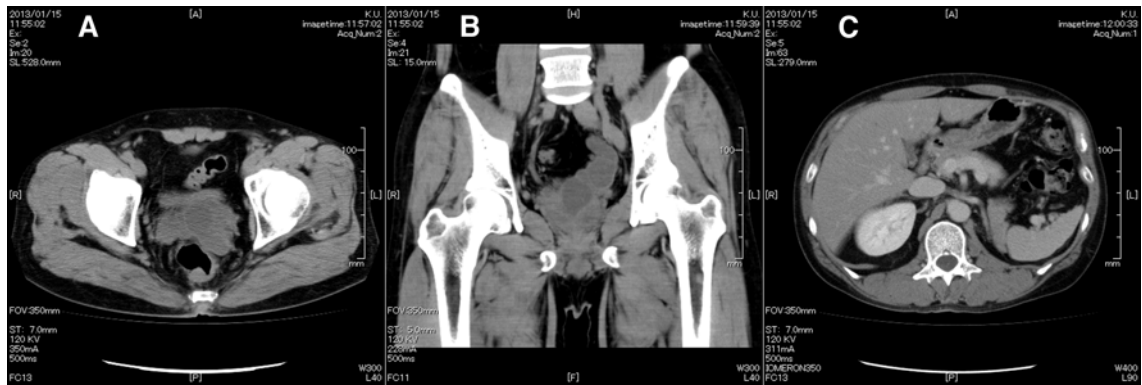
Figure 1



Solid Testicular Mass in a 44-year-old man

11/9

Figure 2



Solid Testicular Mass in a 44-year-old man

12/9

Figure 3

