

Title	Vaginal delivery in the presence of huge vulvar varicosities: a case report with MRI evaluation.
Author(s)	Furuta, Nozomi; Kondoh, Eiji; Yamada, Shigehito; Kawasaki, Kaoru; Ueda, Akihiko; Mogami, Haruta; Konishi, Ikuo
Citation	European Journal of Obstetrics & Gynecology and Reproductive Biology (2013), 167(2): 127-131
Issue Date	2013-04
URL	<a href="http://hdl.handle.net/2433/173408">http://hdl.handle.net/2433/173408</a>
Right	© 2012 Elsevier Ireland Ltd.
Type	Journal Article
Textversion	author

Original

August 25, 2012

**Vaginal delivery in the presence of huge vulvar varicosities: a case report with MRI evaluation**

Nozomi FURUTA, Eiji KONDOH\*, Shigehito YAMADA, Kaoru KAWASAKI,

Akihiko UEDA, Haruta MOGAMI, Ikuo KONISHI

Department of Gynaecology and Obstetrics, Kyoto University, Kyoto, Japan

\*Corresponding author address:

Department of Gynaecology and Obstetrics, Kyoto University

54 Shogoin Kawahara-cho, Sakyo-ku, Kyoto 606-8507, Japan

Tel: +81-75-751-3269

Fax: +81-75-761-3967

E- mail: kondo@kuhp.kyoto-u.ac.jp

**Short title**

Vulvar varicosities and pregnancy

**Condensation**

Women with vulvar varicosities may be allowed to attempt a vaginal delivery regardless of their severity.

**Abstract**

Vulvar varicosities are generally not an indication for a caesarean-section delivery. However, in a rare case of severe vulvar varicosities, it would be a controversial issue whether to perform a caesarean section for fear they might rupture during a vaginal delivery. We present a case of huge vulvar varicosities during pregnancy. MRI revealed obstruction of the internal iliac system by the gravid uterus and subsequent incompetence of a collateral pathway via the round ligament vein that emptied into the ovarian vein. The patient went into labour at 38 weeks, and successfully vaginally delivered a baby. The vulvar varicose veins got compressed by the foetal head from the inside, and markedly diminished in size during crowning and after delivery. Women with vulvar varicosities can be allowed to attempt a vaginal birth regardless of their severity. The use of MRI aids in the overall anatomical understanding of vulvar varicosities in pregnancy. (149 words)

**Keywords:** mode of delivery, MRI, pregnancy, vulvar varicosity.

## **Introduction**

Vulvar varicosities occur in approximately 2% of pregnant women, and usually regress spontaneously after parturition <sup>(1)</sup>. In general, vulvar varicosities are not an indication for a caesarean-section delivery. However, the vulvar varicose veins may cause extensive haemorrhage should they rupture during the course of labour <sup>(2)</sup>. Practically, a caesarean section is sometimes performed in extremely severe cases of vulvar varicosities for fear of their rupture during a vaginal delivery <sup>(3)</sup>. To date, there is no consensus on the mode of delivery in a rare case of extensive vulvar varicosities.

In order to determine the optimal mode of delivery in pregnancies involving vulvar varicosities, it would be important to understand the underlying causes of vulvar varicosity formation in pregnancy and how the varicosities change in the course of vaginal delivery. We present a case of huge vulvar varicosities in pregnancy that succeeded in an uneventful vaginal delivery. An anatomical evaluation of vulvar varicose veins was also conducted using magnetic resonance imaging (MRI). This article sheds light on the anatomical and physiological aspects of vulvar varicosities in pregnancy.

## Case

A 32-year-old woman, gravida 1, para 1, complained of swelling and discomfort in the left labia minora at 16 weeks of gestational age. Examination revealed mild vulvar varicosities. She had neither varicose veins of the legs nor a history of varicose veins in her first pregnancy. The vulvar varicosities grew larger toward the end of the second trimester with each regular prenatal check-up. There were bilateral (mainly left) extensively swollen varicosities of the labia majora and minora and the clitoral hood (Figure 1). Transvaginal ultrasonography showed multiple echo-free serpentine tubular channels on the lateral sides of the uterine cervix (Figure 2). Colour Doppler sonography confirmed venous flow consistent with uterine veins. MRI demonstrated that markedly dilated and meandering veins formed vulvar varicosities, draining into a vein along the round ligament from the labia majora through the inguinal canal, and then to the utero-ovarian veins (Figure 3). The collateral pathway consisted of the round ligament varicosities and the grossly dilated incompetent ovarian vein. The vulvar varicosities did not deteriorate very much during the third trimester, and they did not cause pain or itching. Ultrasound evaluation of lower extremities did not detect deep venous thrombosis.

After an explanation of anatomical evaluation of vulvar varicosities and the possible risk of varicose vein rupture during labour, the patient decided to deliver vaginally.

The patient went into labour at 38-weeks-and-5-days pregnant. During the second stage of labour, vulvar varicosities gradually diminished in size as the foetal head descended (Figure 4). She gave birth to a healthy female infant with a birth weight of 2882 g by spontaneous vaginal delivery. The varicose veins did not rupture, and they resolved soon after delivery. The total blood loss was 290 g.

## Discussion

It is presently unclear whether a vaginal delivery increases the risk of massive blood loss in the event of huge vulvar varicosities. Labour may be allowed and caesarean delivery is performed for obstetric indications. For example, there is no indication for caesarean section other than known obstetric indications in cases of the Klippel-Trenaunay syndrome, which is a congenital vascular disorder that often presents vulvar varicosities<sup>(4-8)</sup>. However, some reports<sup>(2,3,4-6)</sup>, but not all<sup>(7-10)</sup>, have shown that caesarean delivery should be considered in cases of large vulvar varicosities. There is no evidence that either mode of delivery is advantageous in cases of huge vulvar varicosities, and no data are available to quantify the risk of rupture during a vaginal delivery. Moreover, definition of “huge” vulvar varicosities itself has not yet been established. In the current case, the vulvar varicosities were regarded as “huge”, because there was a collateral pathway consisting of the round ligament varicosities and the dilated ovarian vein. The vulvar varicose veins markedly diminished at the end of the second-stage labour as the foetal head descended and compressed vaginal and vulvar varicities from the inside. This finding indicates that extensive vulvovaginal varicosities will, at least theoretically, decrease



in size regardless of their size or extent during labour and delivery. Thus, it would be safe to say that vulvar varicosities rarely rupture during a vaginal delivery. Practically, it would be important to avoid laceration to the vulvar varicosities during delivery. A gentle and slow delivery will minimise the risk of genital trauma and subsequent rupture of vulvar varicosities.

Vulvar varicosities in pregnancy are generally managed expectantly, because most of them disappear after delivery. Ultrasound evaluation of lower extremities should be conducted to rule out deep vein thrombosis. Superficial venous thrombosis is also a risk factor for venous thromboembolism <sup>(11)</sup>. Antithrombotic prophylaxis with use of low-molecular-weight heparin is considered during pregnancy and postpartum period.

The pathogenesis of vulvar varicosities is mainly valvular dysfunction, but the fundamental aetiology remains unclear. Vulvar varicosity is the most common unusual cause of lower limb varicose veins in a non-pregnant state <sup>(12)</sup>, and almost half arise from the incompetent varicose veins at the saphenofemoral junction <sup>(13)</sup>. In our case, the patient had no leg varicosities, but had incompetence of the round ligament veins and the ovarian vein. Vulvar varicosities in pregnancy usually

develop after 12 weeks, and vanish soon after delivery. The incidence rises with increasing parity <sup>(1)</sup>, and several pathophysiologic mechanisms, which are closely associated with pregnancy, is thought to be involved in vulvar varicosities. The possible underlying mechanisms are mechanical compression of the inferior vena cava and pelvic veins by an enlarged gravid uterus, an increase in intravascular volume and hormonal factors <sup>(14)</sup>. McLennan reported that pregnant women had a progressive increase up to 24 cm H<sub>2</sub>O from a normal of below 10 cm H<sub>2</sub>O in femoral pressures <sup>(15)</sup>. The increase starts as early as 12-14 weeks of gestation, while antecubital venous pressures remains unchanged during pregnancy <sup>(15)</sup>. Increased levels of oestrogen and progesterone cause venous distensibility and embrittlement, and a scarcity of valves in the pelvic veins is also related with vulvar varicosities in pregnancy <sup>(14)</sup>. The other risk factors for vulvar varicose veins may include increasing age, occupations involving standing for long periods and genetics <sup>(14)</sup>. Because ovarian vein valves are absent in 15% of women on the left side and in 6% of women on the right <sup>(16)</sup>, the primary pathogenesis of the current case might be the incompetence of the left ovarian vein. Although vulvar varicosities did not appear in her first pregnancy, the ovarian venous valvular dysfunction might have already

occurred due to obstruction of the internal iliac venous system by the gravid uterus, and manifest as the huge vulvar varicosities in the current pregnancy.

The venous drainage of the vulva enters the pelvic cavity through the saphenous hiatus, pudendal canal, obturator canal and inguinal canal. The venous blood drains mainly to the three pathways: (1) the internal iliac vein, (2) the femoral vein, and (3) the ovarian vein (Figure 5). Moreover, there are anastomoses and communicating veins between the three pathways (Figure 3). The internal pudendal and obturator veins are tributaries of the internal iliac vein. The internal pudendal vein traverses through the pudendal canal along the lateral wall of the ischiorectal fossa. The obturator vein enters the pelvis through the obturator canal. The internal pudendal and obturator veins are likely to get compressed by the enlarged gravid uterus, and the mechanical obstruction of the first pathway may be the most probable cause of vulvar varicosities in pregnancy. The superficial external pudendal vein and the deep external pudendal vein join the great saphenous vein around the sapheno-femoral junction. The great saphenous vein passes through the saphenous hiatus, and ends in the femoral vein. The incompetence of the second pathway is the most common cause of vulvar varicosities in non-pregnant women <sup>(13)</sup>. The third

drainage pathway of the vulva is the vein along the round ligament. It runs through the inguinal canal to join the ovarian vein. Round ligament varicosities are rare, and often manifest as an inguinal mass that mimics hernias in pregnancy <sup>(17)</sup>. In the current case, ultrasonography and MRI exhibited dilated uterine veins, and MRI revealed engorged collateral circulation of the round ligament vein into the ovarian vein. Moreover, vulvar varicose veins markedly improved shortly after the vaginal birth. These findings suggest that vulvar varicosities in our case were mainly due to obstruction of the internal iliac venous system by the gravid uterus, leading to the subsequent incompetence of the round ligament vein and the ovarian vein. Varicose veins in the vulva or lower extremities due to ovarian vein incompetence are associated with pelvic congestion syndrome or recurrent varicosities after surgical treatment <sup>(13)</sup>. Although there have been no previous reports on evaluation of vulvar varicosities using MRI during pregnancy, this approach will contribute to the anatomical understanding of vulvar varicosities, leading to better management of the varicose veins and possible future pelvic congestion syndrome.

In conclusion, the patient with huge vulvar varicosities had a successful vaginal birth. Women with vulvar varicosities can be allowed to attempt a vaginal

birth regardless of their severity. The vulvar varicosities are probably due to obstruction of the internal iliac system and subsequent incompetence of the collateral pathway consisting of the round ligament vein and the ovarian vein. The use of MRI aids in the overall anatomical understanding of vulvar varicosities in pregnancy.

## References

- [1] Dodd H, Wright HP. Vulval varicose veins in pregnancy. *Br Med J.* 1959  
28;1:831-2
- [2] Reich WJ, Nechtow MJ. Rupture of a vulvar varix with massive and extensive hemorrhage following a normal delivery. *Am J Obstet Gynecol.* 1951;61:1374-5.
- [3] Adler SS. Extensive varix of vulva and vagina in full term pregnancy; delivery by cesarean section. *Am J Obstet Gynecol.* 1946;51:272-4.
- [4] Watermeyer SR, Davies N, Goodwin RI. The Klippel-Trenaunay syndrome in pregnancy. *BJOG.* 2002;109:1301-2.
- [5] Rebarber A, Roman AS, Roshan D, Blei F. Obstetric management of Klippel-Trenaunay syndrome. *Obstet Gynecol.* 2004;104:1205-8.
- [6] Tanaka R, Fujita Y, Ishibashi Hiasa K, Yumoto Y, Hidaka N, et al. Successful Management of Pregnancy Complicated by Klippel-Trenaunay Syndrome Using MR Angiography-Based Evaluation. *Case Rep Obstet Gynecol.* 2011;2011:723467. Epub 2011 Oct 27.
- [7] Güngör Gündoğan T, Jacquemyn Y. Klippel-trenaunay syndrome and pregnancy. *Obstet Gynecol Int.* 2010;2010:706850. Epub 2010 Dec 19.

- [8] Atis A, Ozdemir G, Tuncer G, Cetincelik U, Goker N, Ozsoy S. Management of a Klippel-Trenaunay syndrome in pregnant women with mega-cisterna magna and splenic and vulvar varices at birth: A case report. *J Obstet Gynaecol Res.* 2012 May 21. doi: 10.1111/j.1447-0756.2012.01867.x. [Epub ahead of print]
- [9] Gearhart PA, Levin PJ, Schimpf MO. Expanding on earlier findings A vulvar varicosity grew larger with each pregnancy. *Am J Obstet Gynecol.* 2011;204:89.e1-2.
- [10] Guida M, Paladini D, Greco E, Di Spiezio Sardo A, Coppola C, Nappi C. Pregnancy-induced symptomatic pelvic and extra-pelvic cavernous hemangiomas. *Clin Exp Obstet Gynecol.* 2009;36:55-7.
- [11] Decousus H, Quéré I, Presles E, Becker F, Barrellier MT, Chanut M, et al. Superficial venous thrombosis and venous thromboembolism: a large, prospective epidemiologic study. *Ann Intern Med.* 2010 16;152(4):218-24.
- [12] Jung SC, Lee W, Chung JW, Jae HJ, Park EA, Jin KN, et al. Unusual causes of varicose veins in the lower extremities: CT venographic and Doppler US findings. *Radiographics.* 2009;29:525-36.
- [13] Hobbs JT. Varicose veins arising from the pelvis due to ovarian vein incompetence. *Int J Clin Pract.* 2005;59:1195-203.

[14] Beebe-Dimmer JL, Pfeifer JR, Engle JS, Schottenfeld D. The epidemiology of chronic venous insufficiency and varicose veins. *Ann Epidemiol.* 2005;15:175-84.

[15] McLennan CE. Antecubital and femoral venous pressure in normal and toxemic pregnancy. *Am J Obstet Gynecol.* 1943;45:568-91.

[16] Ahlberg NE, Bartley O, Chidekel N. Right and left gonadal veins. An anatomical and statistical study. *Acta Radiol Diagn (Stockh).* 1966;4:593-601.

[17] McKenna DA, Carter JT, Poder L, et al. Round ligament varices: sonographic appearance in pregnancy. *Ultrasound Obstet Gynecol.* 2008;31:355-7.



## Figure Legends

Figure 1. Severe vulvar varicosity appearance at 32 weeks of gestation.

Extensively swollen varicosities were seen in the labia majora and minora and the clitoral hood (left), and vaginal varicose veins were also observed at the vaginal entrance (right).

Figure 2. Transvaginal ultrasound images of dilated uterine veins at 32 weeks of gestation.

Multiple echo-free tubular channels were observed on the lateral side of the uterine cervix.

Figure 3. True FISP images of vulvar varicosities at 32 weeks of gestation.

Coronal images (A-F) are arranged from dorsal to ventral, and axial images from caudal to cranial (G-L). Dilated and meandering uterine veins were at either side of the uterine cervix (arrow). Dilated and meandering veins formed vulvar varicosities (arrowhead). The varicosities were drained into a marked dilated vein along the round ligament (double arrow) from the labia majora through the inguinal canal, into

the ovarian vein (double arrowhead). A communicating vein was observed between the ovarian vein and femoral vein pathways (oval).

Figure 4. Serial vulvar varicosity appearance on day of delivery.

Alterations of vulvar varicosities during labour are shown (A, labour on set; B and C, the second stage of labour; D, before delivery of the placenta; E, after repair of episiotomy). Vulvar varicosities gradually diminished in size with the descent of the foetal head, and markedly decreased in size during crowning and after delivery.

Figure 5. Anatomical analysis of vulvar varicosities.

The venous drainage of the vulva enters the pelvic cavity through the saphenous hiatus, pudendal canal, obturator canal and inguinal canal. The venous blood drains mainly to the three pathways: (1) the internal iliac vein that receives the internal pudendal and obturator veins; (2) the superficial external pudendal vein and the deep external pudendal vein into the great saphenous vein that ends in the femoral vein; and (3) the vein along the round ligament into the ovarian vein.

**Disclosure**

The authors report no conflict of interest.

Figure 1

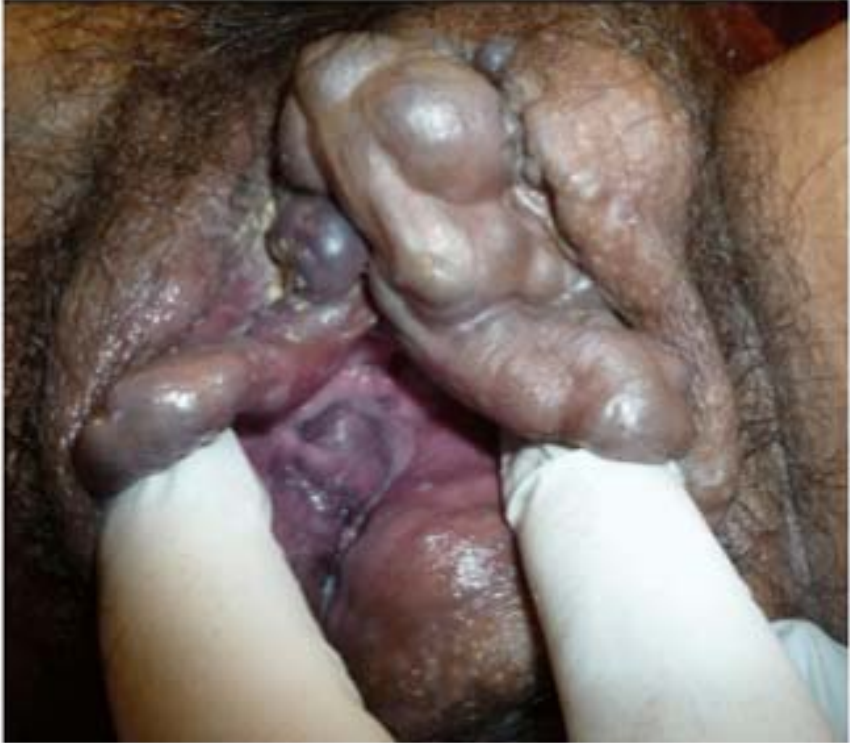
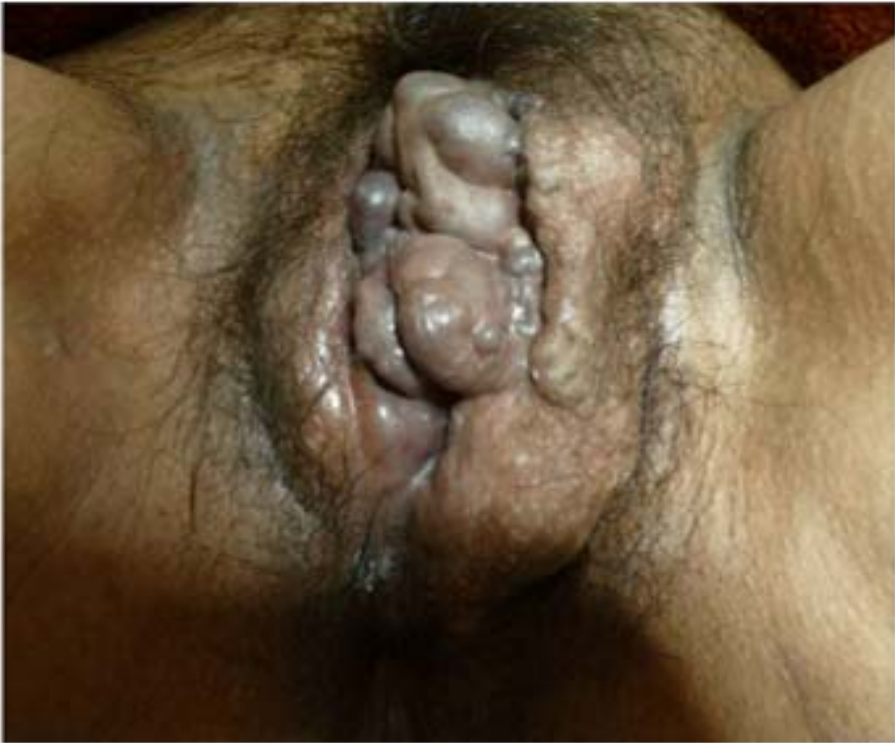
Figure 2

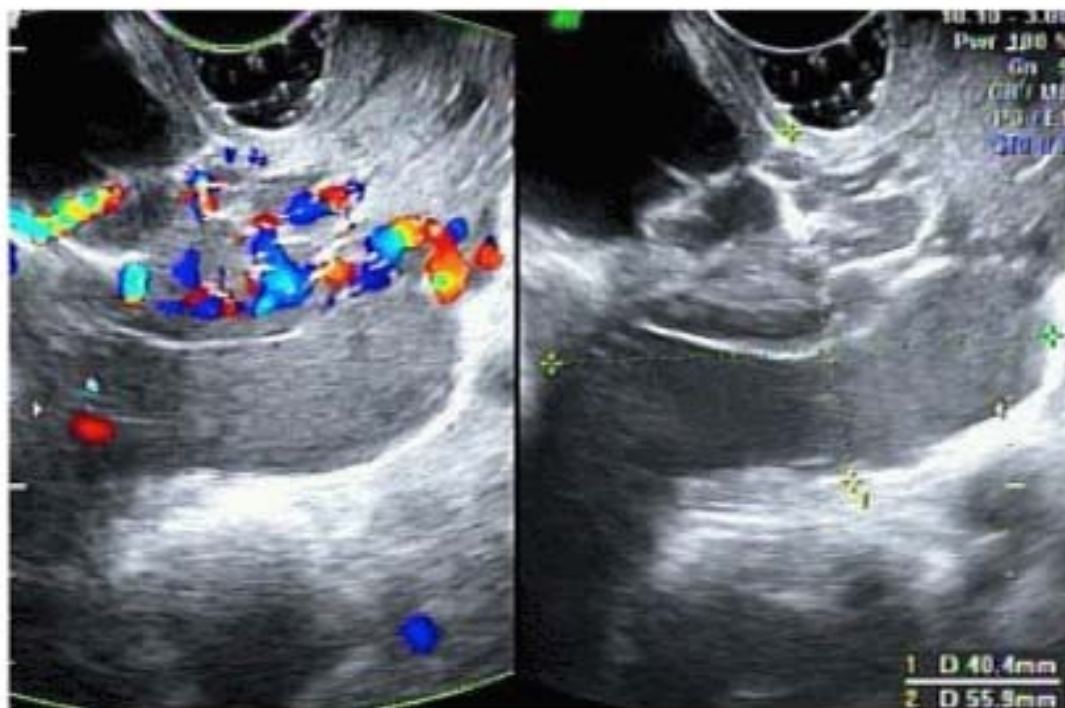
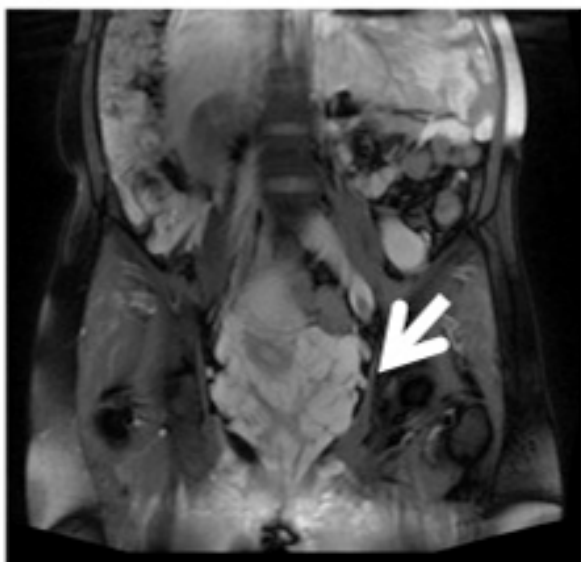
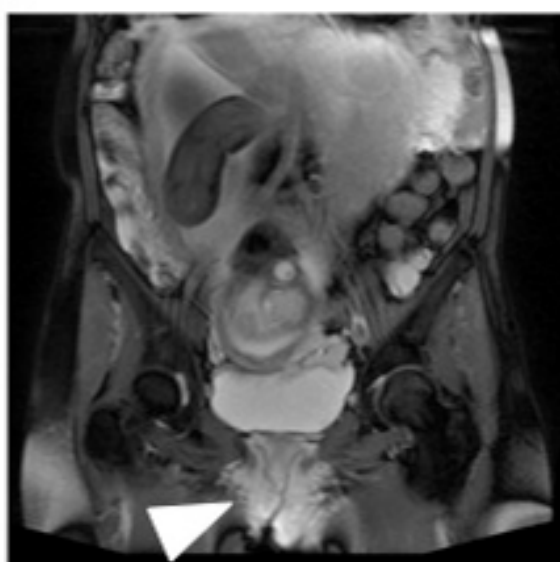


Figure 3

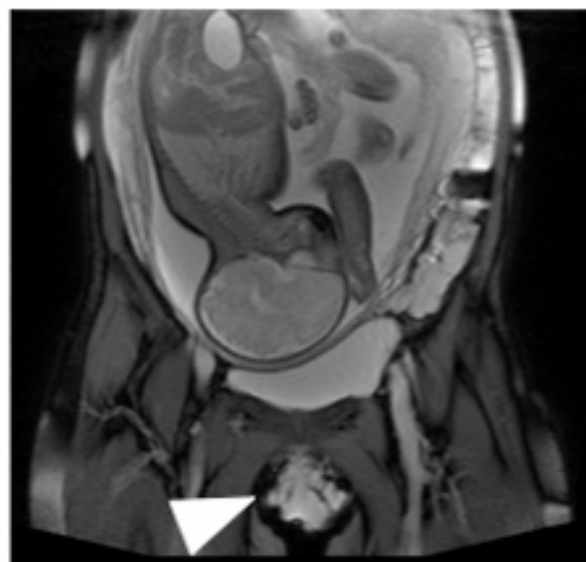
A



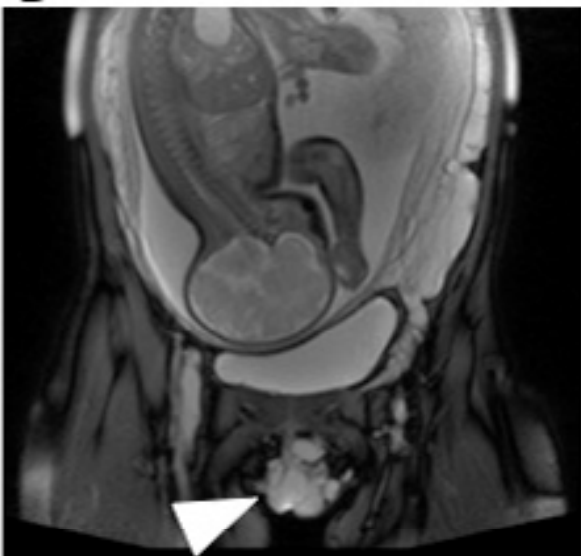B



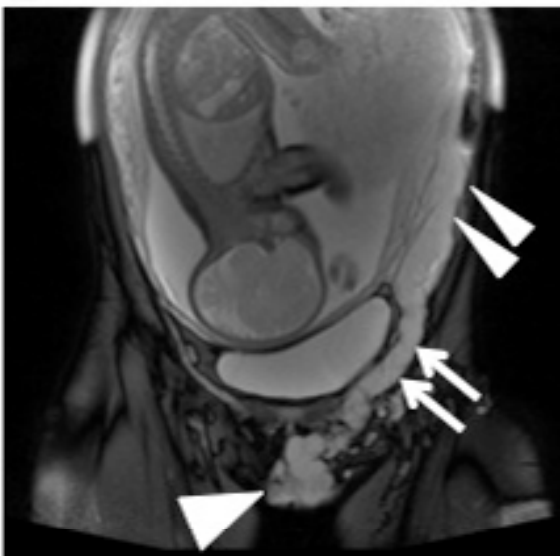
C



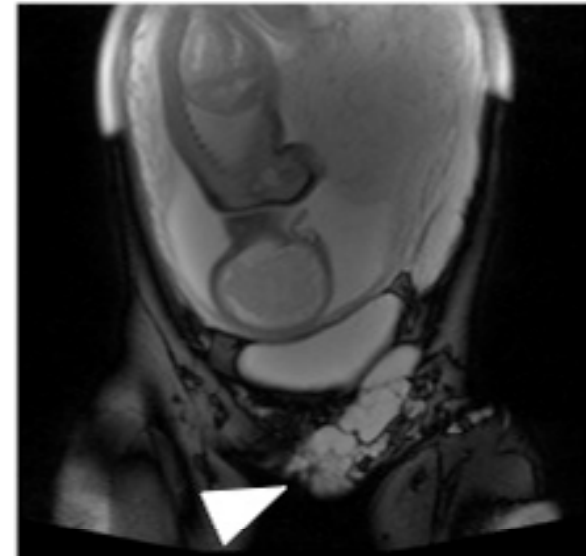
D



E



F



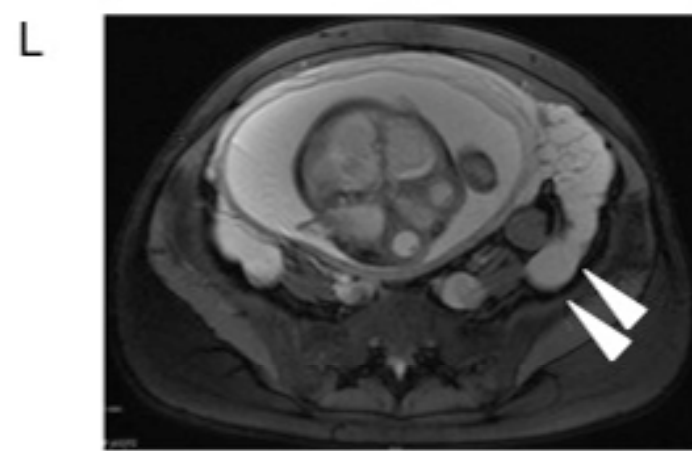
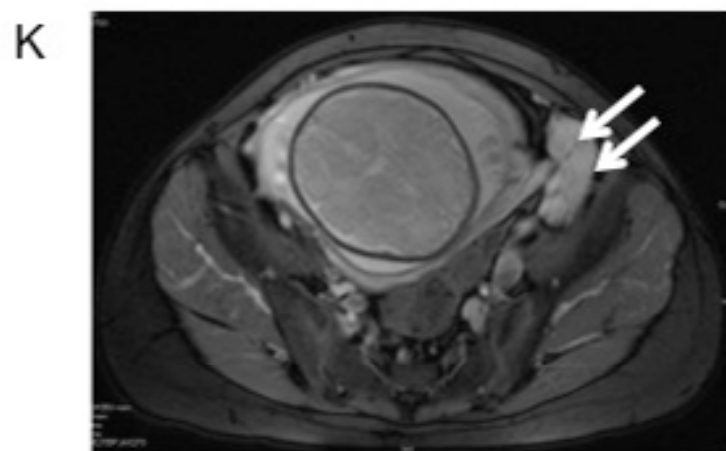
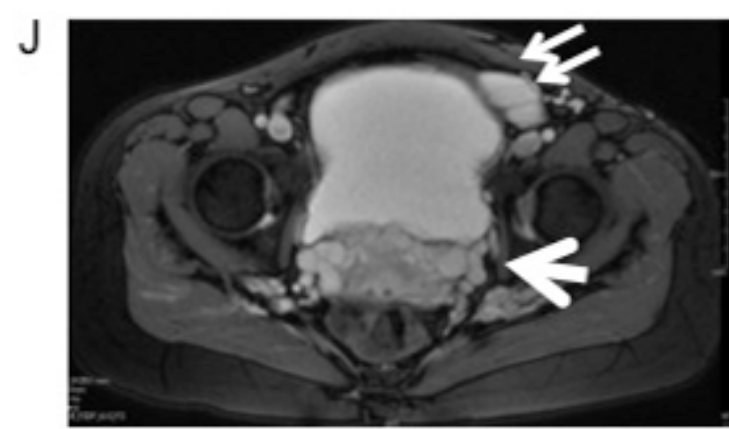
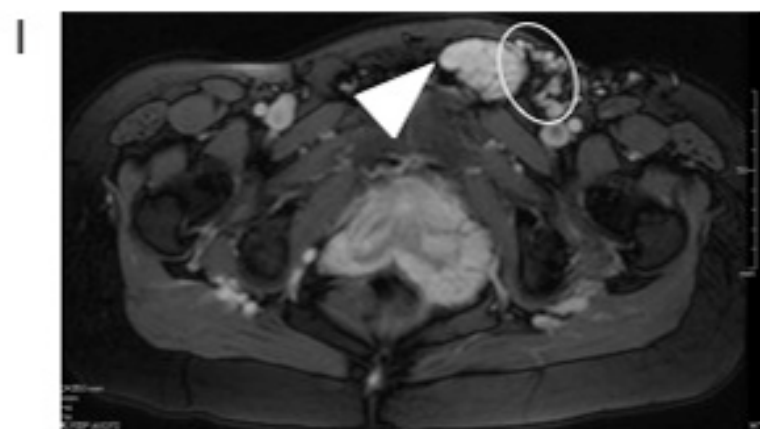
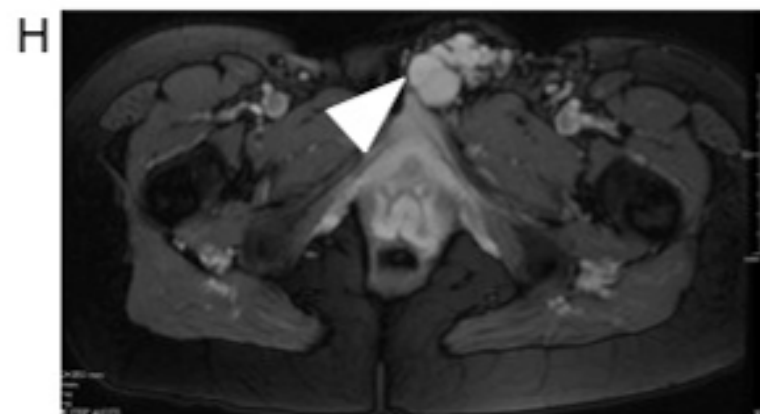
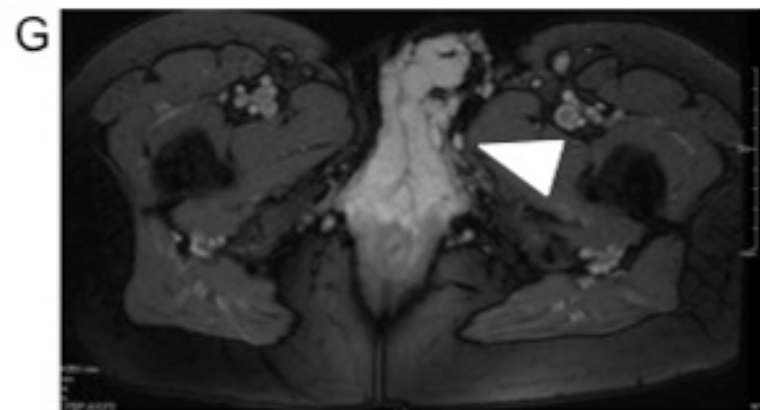


Figure 4

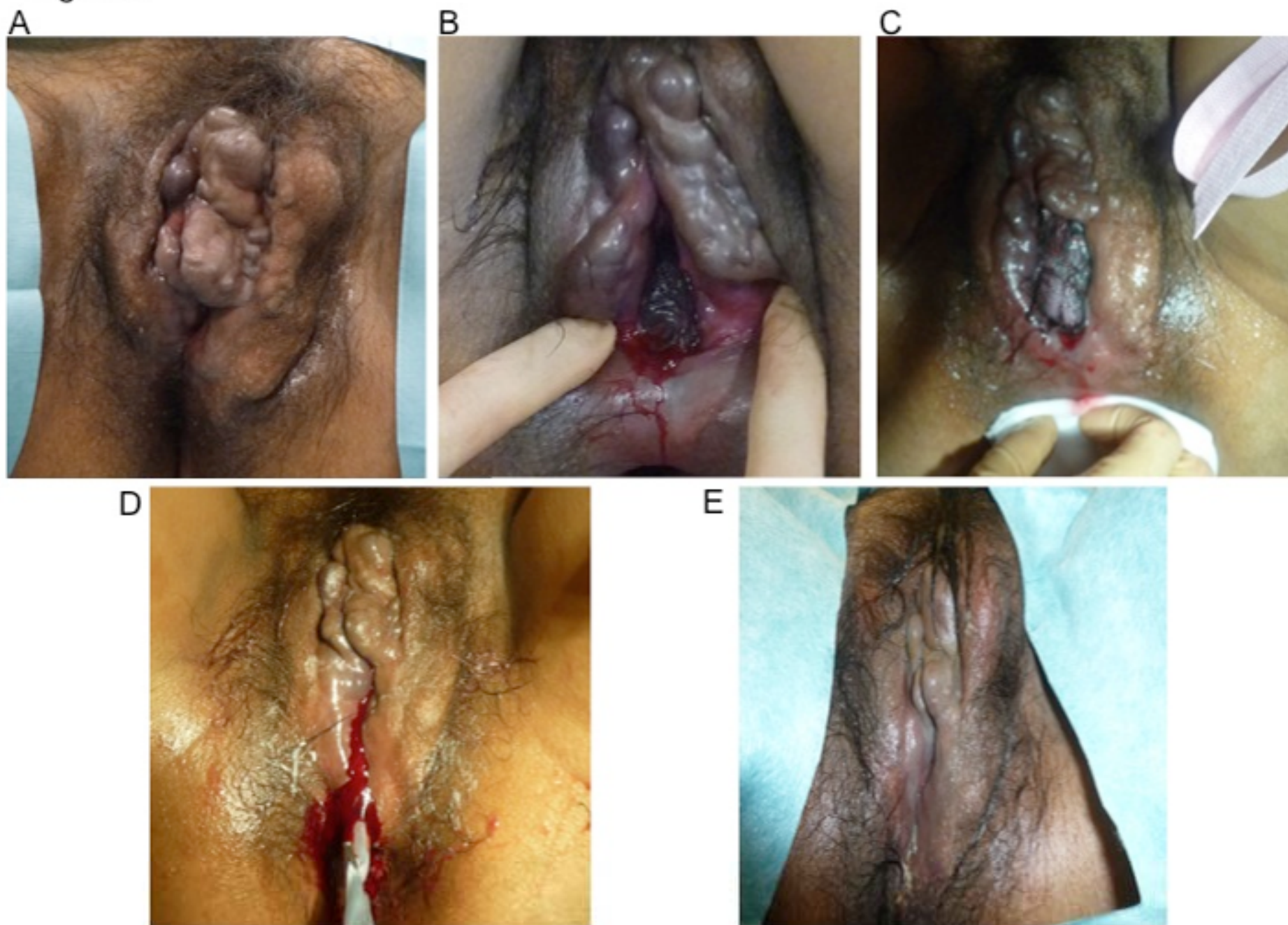



Figure 5

