

Title	Intrathoracic esophagogastric anastomosis using a linear stapler following minimally invasive esophagectomy in the prone position.
Author(s)	Okabe, Hiroshi; Tanaka, Eiji; Tsunoda, Shigeru; Obama, Kazutaka; Sakai, Yoshiharu
Citation	Journal of gastrointestinal surgery : official journal of the Society for Surgery of the Alimentary Tract (2013), 17(2): 397-402
Issue Date	2013-02
URL	http://hdl.handle.net/2433/169700
Right	The final publication is available at www.springerlink.com
Type	Journal Article
Textversion	author

Intrathoracic esophago-gastric anastomosis using a linear stapler following minimally invasive esophagectomy in the prone position

Running head: Linear-stapled intrathoracic esophagogastric anastomosis in prone position

Authors' names: Hiroshi OKABE¹⁾, Eiji TANAKA¹⁾, Shigeru TSUNODA¹⁾, Kazutaka OBAMA¹⁾, Yoshiharu SAKAI¹⁾

Affiliation:

1) Department of Surgery, Kyoto University Graduate School of Medicine
54 Kawahara-cho, Shogoin, Sakyo-ku, Kyoto, 606-8507, Japan

Corresponding Author: Hiroshi OKABE

Mailing address:

Department of Surgery, Graduate School of Medicine Kyoto University
54 Kawahara-cho, Shogoin, Sakyo-ku, Kyoto, 606-8507, Japan

E-mail address: hokabe@kuhp.kyoto-u.ac.jp

Telephone: +81-75-366-7595

Fax: +81-75-366-7642

Sources of funding: None

Keywords: Minimally invasive esophagectomy, Esophageal cancer, Esophago-gastric anastomosis, Prone position

Abstract

Background: Minimally invasive esophagectomy (MIE) in the prone position typically includes thoracoscopic mediastinal dissection and laparoscopic gastric tube construction, followed by esophago-gastric anastomosis in the neck. We introduced an intrathoracic esophago-gastric anastomosis using linear staplers.

Technique: The lower mediastinal dissection and the gastric tube construction are done in the laparoscopic part of the operation. The esophagus is transected at the cranial level of the aortic arch after the completion of the upper mediastinal lymph node dissection in the prone position. The excess length of the gastric tube is sacrificed before making the anastomosis. Side-to-side esophago-gastric anastomosis is performed using a 35 mm endoscopic linear stapler. The entry hole is closed with hand suturing using the posterior and the axillary port.

Results: Twenty-six patients with middle or lower esophageal tumor underwent MIE with an intrathoracic anastomosis. The mean thoracoscopic procedure time was 302min. One patient had an anastomotic leakage, which was successfully managed with drainage. There has been no anastomotic stenosis. Pneumonia was observed in two patients. There was no mortality.

Conclusions: MIE with an intrathoracic linear-stapled anastomosis with the patient in the prone

position is safe and feasible.

Introduction

Esophagectomy is still the mainstay of curative treatments for esophageal cancer. Minimally invasive esophagectomy (MIE) using thoracoscopic and laparoscopic approach has been developed and introduced by several surgeons, because open transthoracic resection of the esophagus is highly invasive and associated with substantial morbidity. Performing this procedure with the patient in the prone position is favored by some groups because the thoracoscopic procedure in the left decubitus position requires retraction of the lung and could lead to postoperative pulmonary complications. Although the benefit of the prone position has not been clarified, some studies have demonstrated a better outcome, such as less blood loss, or fewer pulmonary complications[1-3].

Anastomotic leakage is a serious surgical complications following esophagectomy. Some comparative studies have shown a higher leakage rate in MIE than in open esophagectomy[4,5]. This may be due to the different site of anastomosis in the two procedures. In these studies, MIE procedure included thoracoscopic dissection of the esophagus and laparoscopic construction of a gastric tube, followed by esophago-gastric anastomosis in the neck. More patients underwent intrathoracic anastomoses in open esophagectomy, while most patients in MIE had cervical anastomoses, which are thought to have a higher leakage rate[6]. Therefore, MIE with intrathoracic anastomosis has been gradually increasing in recent years. With a secure method of anastomosis, it

could improve the outcome of MIE, and establish its clinical advantages[7].

A circular stapler is most frequently used method for intrathoracic esophago-gastric anastomosis in open esophagectomy. However, linear stapled anastomosis is an attractive alternative for thoracoscopic reconstruction, because it is easier to manipulate in the limited pleural space than a circular stapler, and postoperative stenosis rarely occurs. Only two case series studies have investigated thoracoscopic linear-stapled anastomosis following esophagectomy[8,9]. Both series were done in the left decubitus position following the Ivor-Lewis resection for lower esophageal cancer, and anastomoses were made at the level of the azygous arch. Therefore, in spite of their favorable outcomes, it is difficult to apply their methods for cases in the prone position, or cases requiring a higher transection of the esophagus.

This report presents a modified technique of linear-stapled esophago-gastric anastomosis that is suitable for the thoracoscopic reconstruction and can be safely performed at the upper mediastinum in the prone position.

Patients and Methods

Patients

A total of 39 patients with esophageal tumor who underwent MIE at at Kyoto University Hospital

between September 2010 and April 2012. Among them, 13 patients with upper esophageal tumor underwent MIE with anastomosis in the neck, and 26 patients (23 males and 3 females) underwent MIE with thoracoscopic linear-stapled esophago-gastric anastomosis. All the 26 patients were included in this retrospective study. The study protocol was approved by our institutional review board. These patients had a median age of 67 years (range, 56-79 years). The tumor was located at the lower or abdominal esophagus in 17 patients, and at the middle esophagus in 9 patients (**Table 1**). The pathological diagnoses included 20 squamous cell carcinomas, four adenocarcinomas, one gastrointestinal stromal tumor, and one malignant melanoma. The preoperative stage was determined by endoscopic findings and computed tomography according to the American Joint Committee on Cancer Staging System[10].

Surgical technique

Laparoscopic procedure

The procedure begins with laparoscopy. The patient is placed in a modified lithotomy position. The first port is placed through the umbilicus, and the laparoscope is inserted to establish a pneumoperitoneum of 8 mmHg. Four operating ports and a Nathanson liver retractor are placed as in laparoscopic gastrectomy[11]. The surgeon stands on the patient's right side. First, the gastrocolic

and the gastrosplenic ligament are divided to reach the left crus of the diaphragm. The left side of the omentum is partially left attached to the stomach so that it can wrap the esophago-gastric anastomosis later. The lesser omentum is opened and the fundus is mobilized to isolate the esophagus. The right crus of the diaphragm is divided to reach the right thoracic cavity and the anterior part of lower mediastinal lymph node dissection is done through the hiatus. A gastric tube is created using serial applications of ENDO GIA™ Universal linear staplers (Covidien), and sero-muscular sutures are placed over the staple edge. A pyloroplasty is not performed. The left gastric artery is divided to dissect lymph nodes around the celiac axis. The posterior part of lower mediastinal lymph node dissection is done to reach the level of the inferior pulmonary vein. Finally, the proximal edge of the gastric tube is anchored to the proximal stomach with sutures.

Thoracoscopic procedure

The port wound is closed, and the patient is placed in the prone position. The first 12 mm port for a scope is placed at the right ninth intercostal space posterior to the posterior axillary line. A pneumothorax of 6 mmHg is established and two working 12 mm ports are placed at the seventh and fifth intercostal space, and another 5 mm port is placed at the third intercostal space at the axilla for the assistant (**Figure 1**). The middle and upper mediastinal lymph node dissection is done, while

both sides of the recurrent laryngeal nerve are isolated and preserved. The thoracic duct is preserved unless direct tumor invasion is recognized. The esophagus is transected at the cranial level of the aortic arch. The proximal edge of tumors located at the middle esophagus is preoperatively marked with an endoscopic clip and the proximal margin is secured under the intraoperative fluoroscope. The resected specimen is pulled up to introduce the gastric tube into the thoracic cavity. The seventh intercostal port wound is extended to 4 cm, and the specimen is extracted. The port site is covered with the Wound Retractor® (Applied Alexis) and a surgical glove to reestablish the pneumothorax. When a tumor is bulky, it is gently pushed back to the abdominal cavity through the hiatus, and removed through the umbilicus after the whole thoracic procedure including esophago-gastric anastomosis is finished and patient is turned back to the supine position.

Esophago-gastric anastomosis

The scope is inserted through the seventh intercostal port for the anastomosis (**Figure 1**, port B). The gastric tube is pulled up to the upper mediastinum and an appropriate point for the anastomosis is marked with a dye (**Figure 2**). For the anastomosis with a linear stapler, the gastric tube needs to overlap with the esophagus for about 5cm. The excess length of the gastric tube is sacrificed using linear staplers (ENDO GIA™ Universal, Covidien) to prevent the redundancy (**Figure 3a**). The edge

is covered with seromuscular sutures. A small hole is made at the anastomotic site on the greater curvature, and the gastric juice is suctioned to prevent contamination. The right half of the esophageal stump is opened with scissors and a lumen is recognized. Full thickness suture is placed on the edge with 3-0 VICRYL® (Ethicon) for the stay suture. The surgeon's left hand operates an endoscopic linear stapler (ENDOPATH® ETS 35mm, Ethicon) through the port at the ninth intercostal space (**Figure 1**, port A), and inserts the anvil side into the gastric tube. The cartridge side is then inserted into the esophagus. Pulling the stay suture facilitates the safe insertion into the true lumen (**Figure 3b** and **4**). The application of the stapler creates a side-to-side anastomosis. Hemostasis is confirmed and the entry hole is closed with hand sutures using 3-0 PDS® (Ethicon). First, two sutures are placed at both edges of the opening, and used as stay sutures brought out through the third intercostal port site and the fourth or fifth intercostal space near the vertebrae (**Figure 5a**). A needle holder is operated through the third or fifth intercostal port to close the entry hole, (**Figure 1**, port C or D). Because the working space is limited at the site of the anastomosis near the thoracic inlet, we prefer interrupted sutures with Roeder's slip knot (**Figure 5b**). The entry hole is completely closed and the suture line is wrapped with the omentum, which is anchored to the gastric tube and the esophagus with a few sutures (**Figure 5c and 5d**). The gastric tube is anchored to the right crus and the right pleural edge by interrupted sutures to reduce the risk of postoperative

hiatal hernias. A 16-French thoracic tube is inserted through the seventh intercostal port wound.

Surgical outcome and postoperative complications

Operative time, blood loss, number of harvested lymph nodes, and postoperative complications were retrieved from the prospective database. Postoperative complications included all major and minor complications and were graded according to the Clavien-Dindo classification[12].

Results

The backgrounds and surgical outcomes of 26 patients are listed in **Table 1**. The mean operative time was 499 min (range, 365 to 645min), and the estimated blood loss was 78 g (range, 13 to 210 g). The mean duration for the thoracic procedure was 302 min. Postoperative complications that required any treatment (grade II or higher complications according to the Clavien-Dindo classification) occurred in seven patients (26.9%). One patient had an anastomotic leakage due to segmental ischemia of the proximal end of the gastric tube, which was successfully managed with insertion of a thoracic drainage tube. The patient also had pneumonia. Aspiration pneumonia occurred in another patient. Other complications included, chylothorax, pericarditis, mediastinal abscess, and hiatal hernia. Reoperations were required for two patients with chylothorax and a

patient with hiatal hernia. There was no mortality. The median postoperative hospital stay was 19 days. No patient experienced anastomotic stenosis during a median follow-up period of seven months. Fifteen patients underwent endoscopic follow-up, revealing reflux esophagitis in one patient. The findings of postoperative endoscopy and an upper gastrointestinal series study in representative cases are shown in **Figure 6**.

Discussion

A secure method of anastomosis is crucial to achieve a better outcome of MIE, because anastomotic complications not only prolong the hospital stay, but also impair the quality of life of patients for a long time. Intrathoracic anastomosis has advantages for reduction of anastomotic leakage; a more proximal part of the gastric tube with a better blood supply can be used for the anastomosis, and the anastomotic site can be wrapped with the omentum. Linear-stapled anastomosis has been reported to decrease the frequency of anastomotic stenosis, another frequent anastomotic complication[13]. Therefore, thoracoscopic linear-stapled anastomosis would be an ideal method of reconstruction following MIE.

Our current report is the first case-series of thoracoscopic linear-stapled anastomosis in the prone position. Although the basic concept is the same as in the left lateral decubitus position, some

technical considerations were required for adaptation to the prone position and for higher transection of the esophagus. First, linear-stapled closure of the entry hole is not feasible in the prone position, because the anterior port is not available. Thus, we use the third intercostal port at the axilla instead for the surgeon's right hand and perform a hand sewn closure. By using this port, a better alignment is obtained even for cases with a high anastomosis at the thoracic inlet. Second, we made a smaller entry hole by opening only the half of the esophageal stump to make this closure easier. Third, we use interrupted sutures with Roeder's slip knot for the closure, because there is still a limitation of the range of motion. Our method, with these modifications, can be applied for esophageal cancer at the middle esophagus, as well as lower or abdominal esophagus, because the esophagus can be transected at a higher location in the thorax. This is a very important advantage of our method, because the dominant type of esophageal cancer in Asian countries is squamous cell carcinoma, which often develops in a higher location.

Although the blood supply of the gastric conduit should be improved in intrathoracic anastomosis, we experienced one anastomotic leakage in the second case. A partial segmental ischemic change of the gastric tube was detected by an endoscopic observation. There is always a redundancy in the gastric tube when it is pulled up into the thoracic cavity because the required length of the gastric tube is not known when it is prepared. Therefore, the excess length of the gastric tube was sacrificed

prior to the anastomosis in all subsequent procedures. We believe that this modification contributes to the higher security of the anastomosis by using the location with a better blood supply. Omental wrapping would also be effective for preventing major leakage. Although the detected ischemic change was significant, the defect was completely covered with the omentum and ultimately healed without stenosis.

Another frequent complication following esophagectomy is pulmonary complications. Some case series studies report that MIE in the prone position could reduce postoperative respiratory problems, because retraction of the lung is not necessary during the thoracoscopic procedure[1]. Intrathoracic anastomosis was performed without the neck dissection and preserved better swallowing function, which is important to prevent aspiration pneumonia. It may contribute to infrequent pulmonary complication rate (7.7%) in this study.

A hiatal hernia is another complication to be discussed. We try to preserve the left pleura in order to prevent postoperative hiatal hernia, so that the intestine cannot protrude into the left thoracic cavity. However, we experienced one case with a hiatal hernia migrating into the right thoracic cavity. We fixed the gastric tube to the right crus and pleural edge for the prevention of the hiatal hernia in all subsequent procedures.

In conclusion, we successfully established intrathoracic esophago-gastric anastomosis following

MIE for esophageal cancer with the patient in the prone position by introducing several technical modifications, even in cases requiring a transection of the esophagus at the upper mediastinum. We believe that our method will contribute to the reduction of anastomotic leakage or stenosis following MIE.

References

- 1 Palanivelu C, Prakash A, Senthilkumar R, Senthilnathan P, Parthasarathi R, Rajan PS, Venkatachlam S: Minimally invasive esophagectomy: Thoracoscopic mobilization of the esophagus and mediastinal lymphadenectomy in prone position--experience of 130 patients. *J Am Coll Surg* 2006;203:7-16.
- 2 Kuwabara S, Katayanagi N: Comparison of three different operative methods of video-assisted thoracoscopic esophagectomy. *Esophagus* 2010;7:23-29.
- 3 Yatabe T, Kitagawa H, Yamashita K, Akimori T, Hanazaki K, Yokoyama M: Better postoperative oxygenation in thoracoscopic esophagectomy in prone positioning. *J Anesth* 2010;24:803-806.
- 4 Safranek PM, Cubitt J, Booth MI, Dehn TC: Review of open and minimal access approaches to oesophagectomy for cancer. *Br J Surg* 2010;97:1845-1853.

- 5 Zingg U, McQuinn A, DiValentino D, Esterman AJ, Bessell JR, Thompson SK, Jamieson GG, Watson DI: Minimally invasive versus open esophagectomy for patients with esophageal cancer. *Ann Thorac Surg* 2009;87:911-919.
- 6 Raz DJ, Tedesco P, Herbella FA, Nipomnick I, Way LW, Patti MG: Side-to-side stapled intra-thoracic esophagogastric anastomosis reduces the incidence of leaks and stenosis. *Dis Esophagus* 2008;21:69-72.
- 7 Luketich JD, Pennathur A, Awais O, Levy RM, Keeley S, Shende M, Christie NA, Weksler B, Landreneau RJ, Abbas G, Schuchert MJ, Nason KS: Outcomes after minimally invasive esophagectomy: Review of over 1000 patients. *Ann Surg* 2012
- 8 Gorenstein LA, Bessler M, Sonett JR: Intrathoracic linear stapled esophagogastric anastomosis: An alternative to the end to end anastomosis. *Ann Thorac Surg* 2011;91:314-316.
- 9 Ben-David K, Sarosi GA, Cendan JC, Hochwald SN: Technique of minimally invasive ivor lewis esophagogastrectomy with intrathoracic stapled side-to-side anastomosis. *J Gastrointest Surg* 2010;14:1613-1618.
- 10 Edge SB, Byrd DR, Compton CC, Fritz AG, Greene FL, Trotti A: *AJCC cancer staging manual*, 7th edition. New York, Springer, 2009.
- 11 Okabe H, Obama K, Kan T, Tanaka E, Itami A, Sakai Y: Medial approach for laparoscopic total

gastrectomy with splenic lymph node dissection. J Am Coll Surg 2010;211:e1-6.

12 Dindo D, Demartines N, Clavien PA: Classification of surgical complications: A new proposal with evaluation in a cohort of 6336 patients and results of a survey. Ann Surg 2004;240:205-213.

13 Orringer MB, Marshall B, Iannettoni MD: Eliminating the cervical esophagogastric anastomotic leak with a side-to-side stapled anastomosis. J Thorac Cardiovasc Surg 2000;119:277-288.

Table 1. Patients' backgrounds and surgical outcomes

Clinical Parameters	N=26
Age	67 (56-79)
Sex (M/F)	23/3
Smoking history (Yes/No)	22/4
Tumor location (Mt/Lt/Ae)	9/16/1
Clinical stage (I/II/III/IV) ¹⁾	9/7/8/1
Operative time (min)	499 (365-645)
Thoracoscopic procedure (min)	302 (230-391)
Blood loss (g)	78 (13-210)
Harvested lymph nodes	54.8 (37-98)
Complications ²⁾	7 (26.9%) ³⁾
Pneumonia	2
Chylothorax	2
Hiatal hernia	1
Anastomotic leakage	1
Pericarditis	1
Mediastinal abscess	1
Mortality	0 (0%)
Length of hospital stay (days)	19 ⁴⁾ (14-107)

Values are shown in mean except for the length of hospital stay, and ranges are also shown in parentheses.

1) According to the American Joint Committee on Cancer Staging System. One case of gastrointestinal stromal tumor was not included.

2) Grade II or higher complications according to the Clavien-Dindo classification are listed.

3) The total does not add up because of overlapping elements.

4) Median value

Figure legends

Figure 1

Port sites for the thoracoscopic procedure. A (9th intercostal space), B (7th intercostal space), and C (5th intercostal space) are for 12 mm ports; D (3rd intercostal space) is for 5mm port.

Figure 2

a. A gastric tube pulled up to the upper mediastinum. The point for the anastomosis (*) is determined so that the gastric tube sits straight. b. The point is marked with ink.

Figure 3

Schematic illustration of the side-to-side esophago-gastric anastomosis.

a. Preparation of the gastric tube. The tip of the gastric tube is sacrificed (dotted line) at 5 cm distal to the marking point for the anastomosis (*). The transection line is covered with seromuscular sutures. b. A 35 mm endoscopic linear stapler is used for the side-to-side anastomosis on the greater curvature.

Figure 4

Intraoperative view of the esophago-gastric anastomosis. A linear stapler is operated with the surgeon's left hand, with the right hand holding the opened edge of the esophagus. Note that the anastomosis is made at the level of the right subclavian artery.

Figure 5

Closure of the entry hole. a. Two stay sutures on the both edges of the opening. b. Interrupted sutures using the Roeder's slipping knot. c. Completion of the closure. d. Anastomotic site is wrapped with the omentum.

Figure 6

a. and b. Endoscopic views of the anastomosis in representative cases at 3 months after surgery. A circular, rather than a triangular, wide anastomosis is seen. No mucosal break suggesting reflux disease is observed. c. A gastrografin swallow study at 6 days after surgery. The contrast passes smoothly through the wide anastomosis (black arrows). The white arrow head shows clips, which were placed during operation to show the upper level of lymph node dissection along the right recurrent laryngeal nerve.

Fig. 1

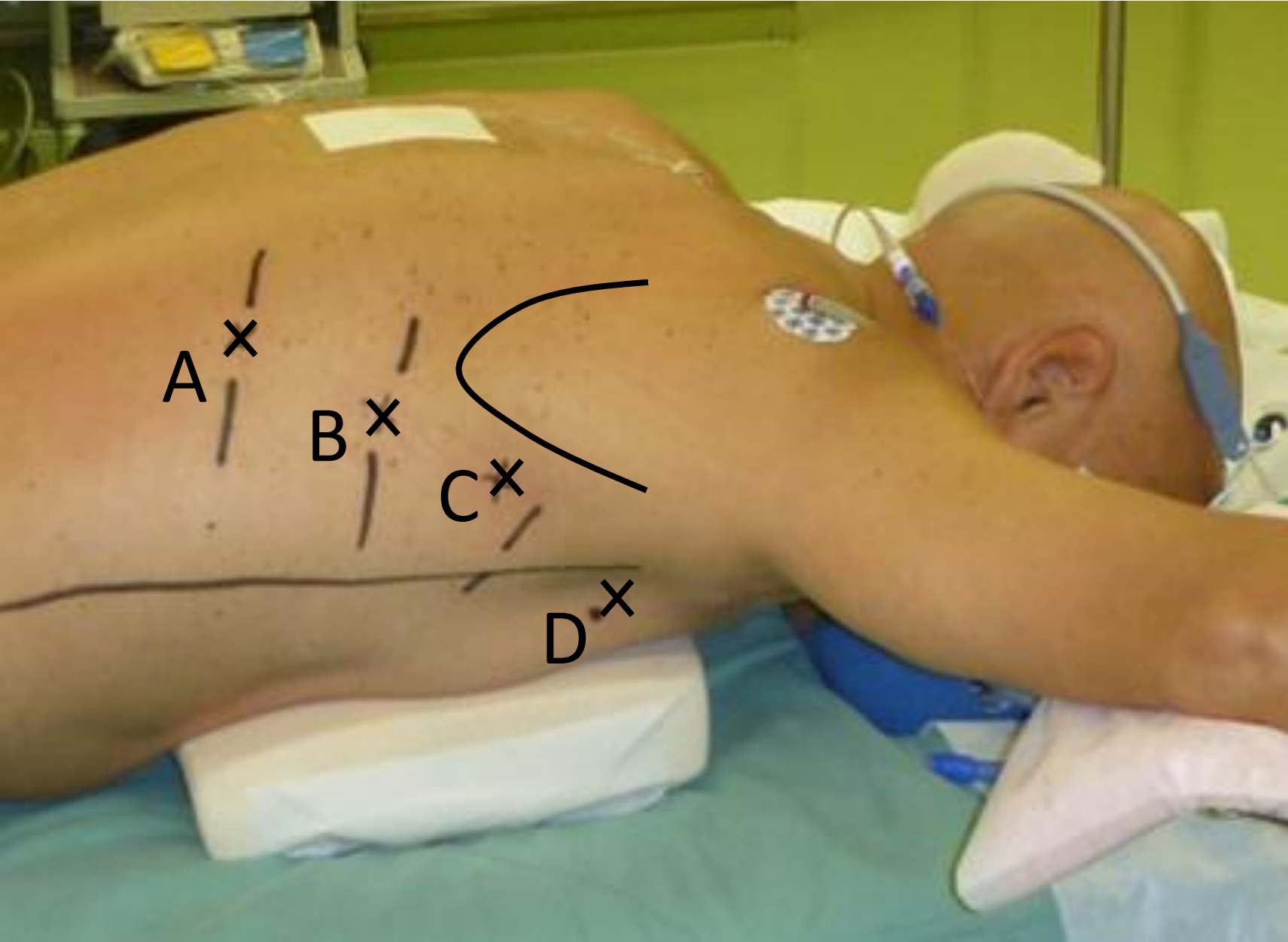


Fig. 2

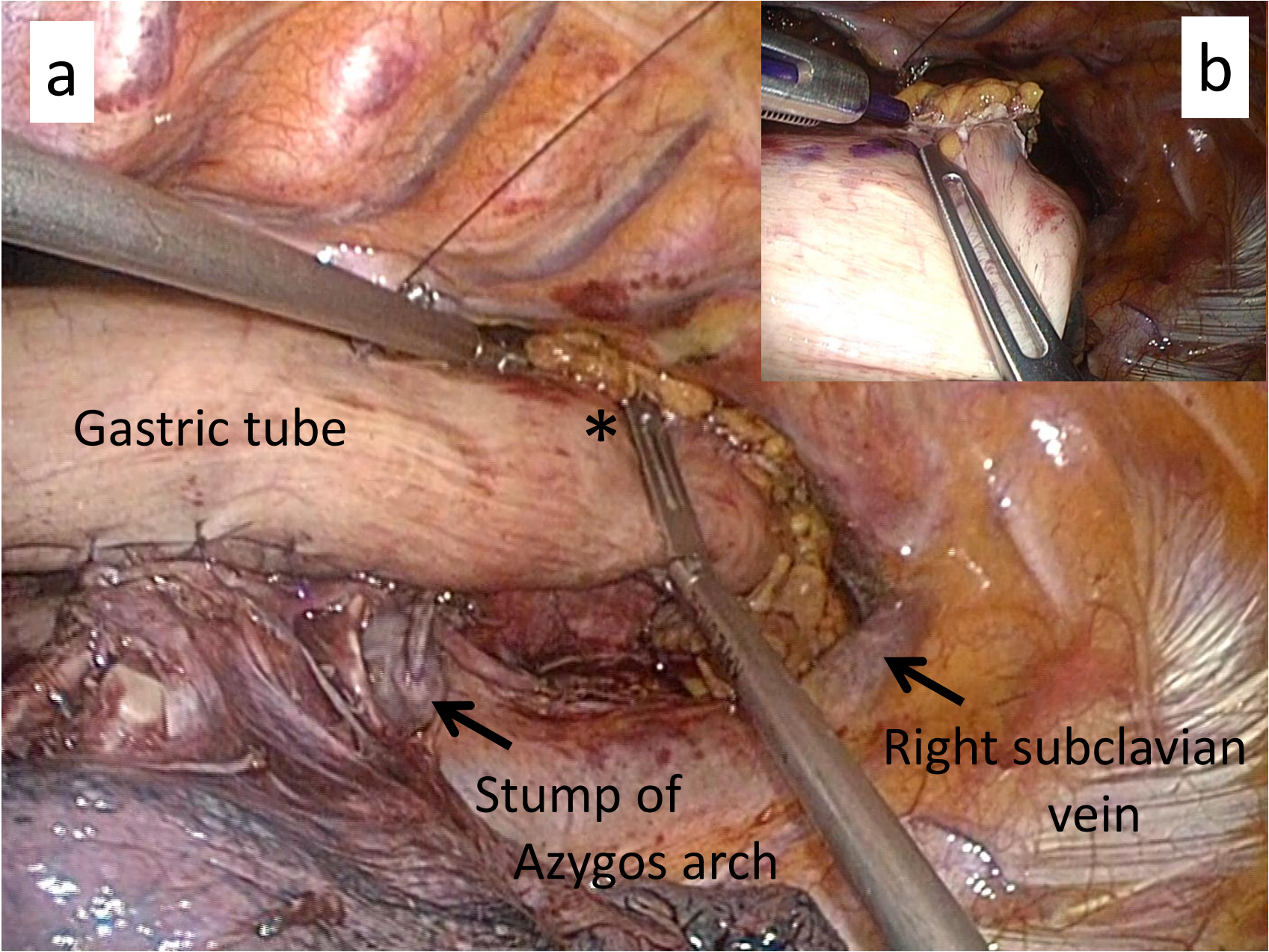
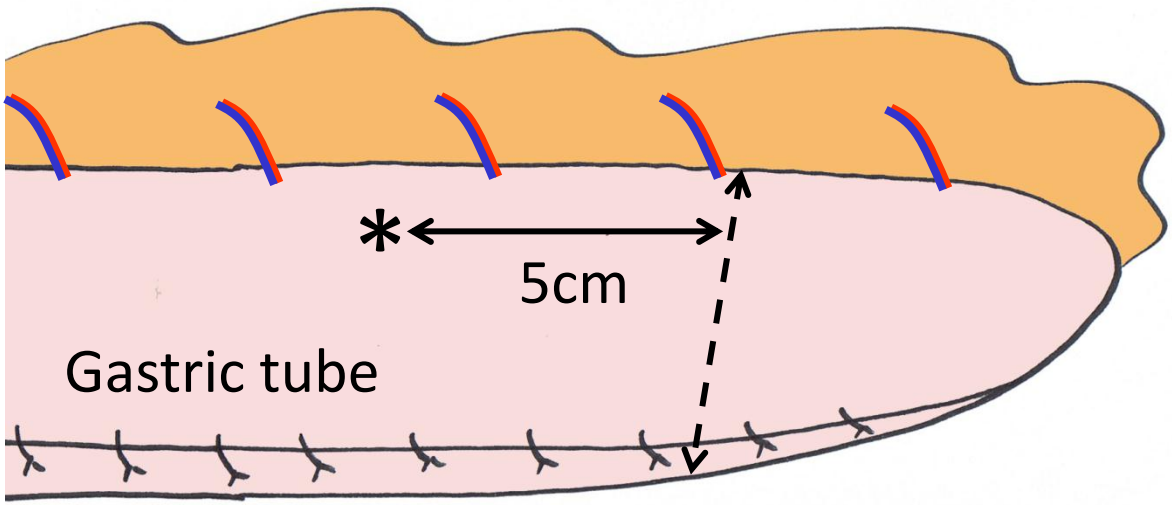


Fig. 3

a



b

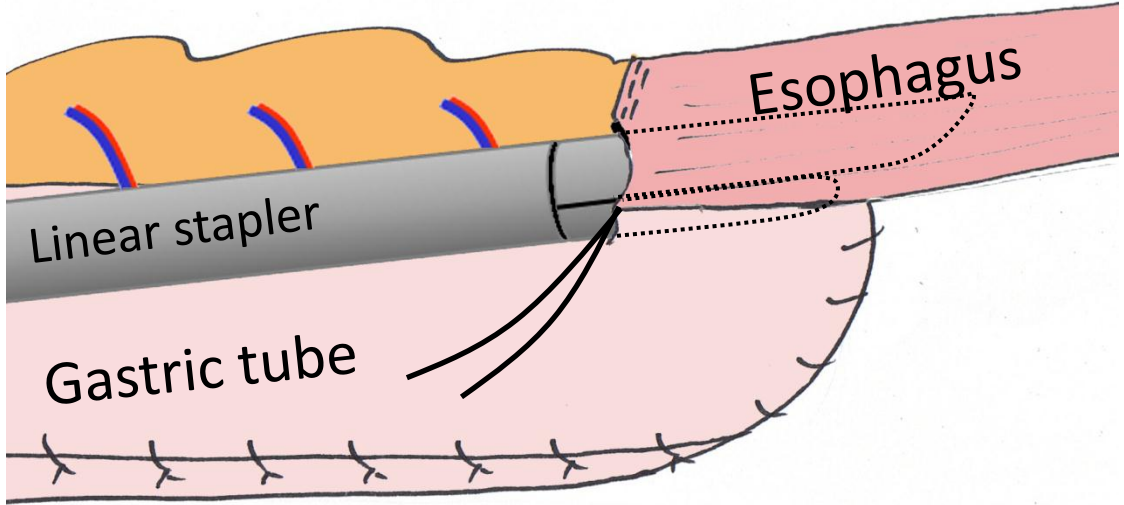


Fig. 4

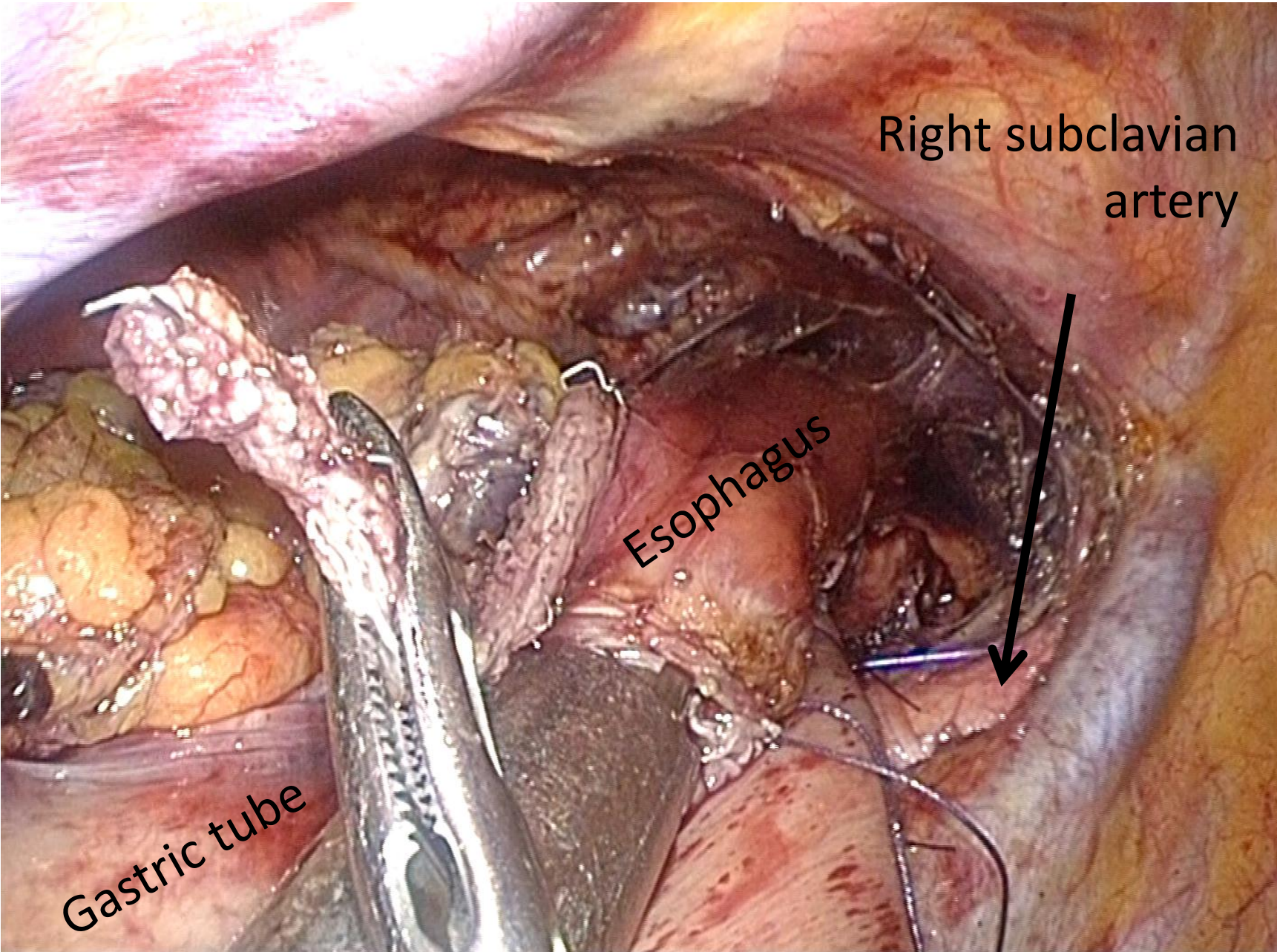


Fig. 5

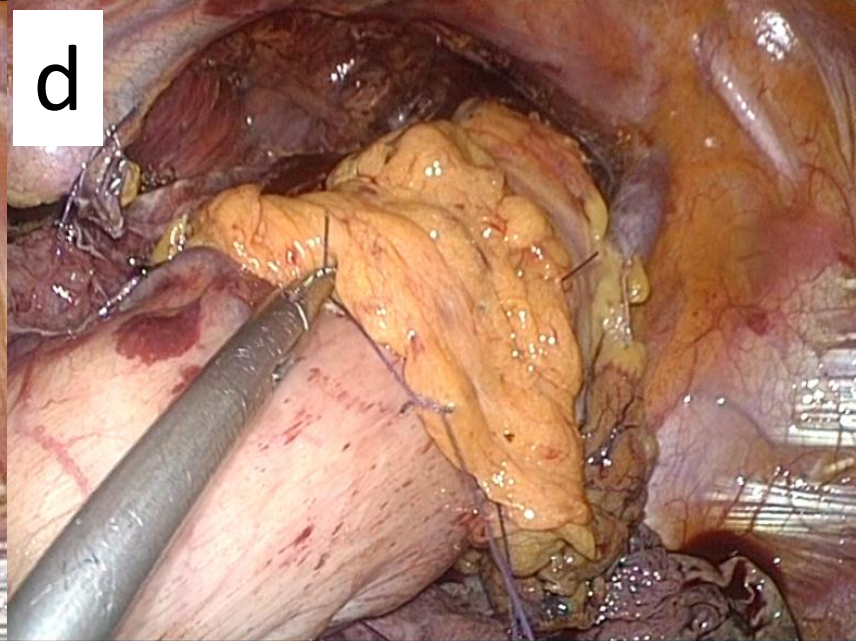
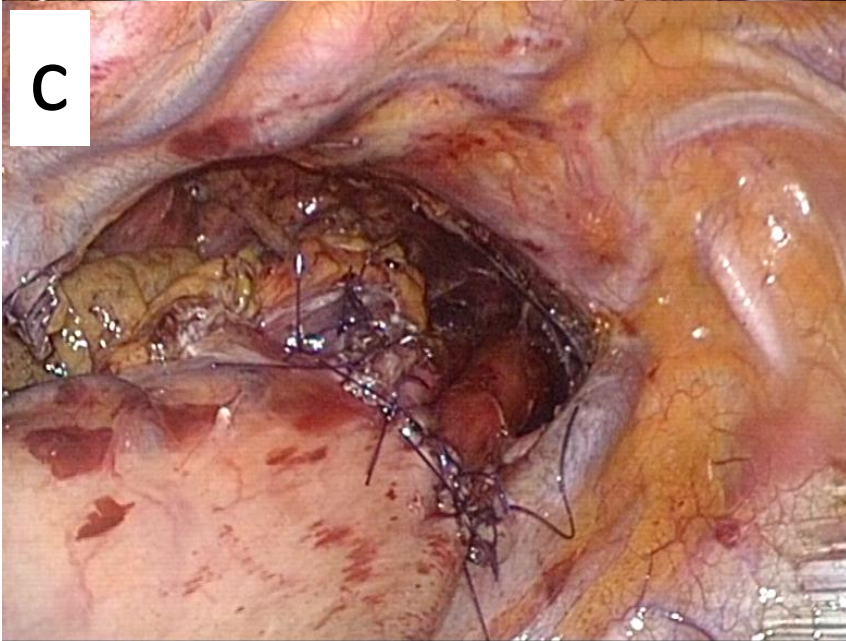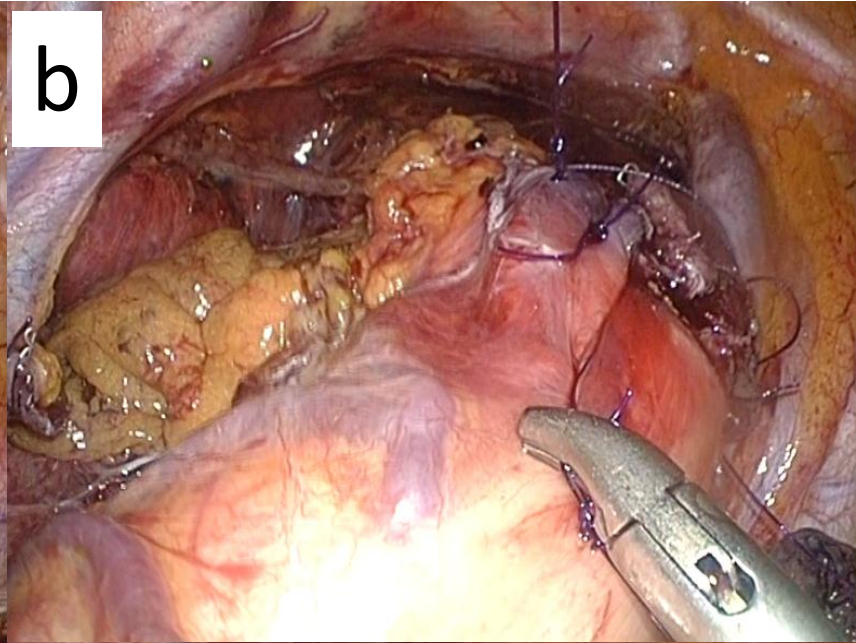
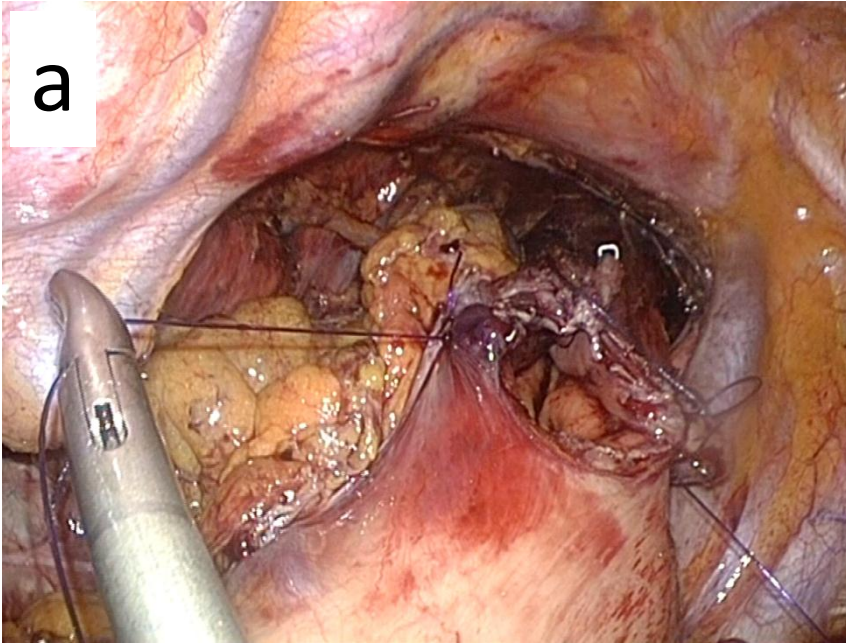


Fig. 6

