

Title	Living-donor single-lobe lung transplant in a 6-year-old girl after 7-month mechanical ventilator support.
Author(s)	Shoji, Tsuyoshi; Bando, Toru; Fujinaga, Takuji; Date, Hiroshi
Citation	The Journal of thoracic and cardiovascular surgery (2010), 139(5): e112-e113
Issue Date	2010-05
URL	http://hdl.handle.net/2433/128859
Right	© 2010 Elsevier B.V.
Type	Journal Article
Textversion	author

**Title: Living-donor single-lobe transplantation in a 6-year-old girl after 7-month
mechanical ventilator support**

Authors: Tsuyoshi Shoji, MD, Toru Bando, MD, Takuji Fujinaga, MD, Hiroshi Date, MD

Institution and Affiliations:

Department of Thoracic Surgery; Kyoto University, Kyoto 606-8507, Japan.

Word Count: 740 words (no more than 750 words)

Corresponding Author:

Tsuyoshi Shoji, MD

Department of Thoracic Surgery, Kyoto University, 54 Shogoin-Kawahara-cho, Sakyo-ku,
Kyoto 606-8507, Japan.

E-mail: hdate@kuhp.kyoto-u.ac.jp

Introduction

Living-donor single-lobe lung transplantation was performed in a 6-year-old girl with bronchiolitis obliterans after Stevens-Johnson syndrome (SJS) who had been ventilator-dependent for 7 months. To our knowledge, this case represents living-donor single-lobe lung transplantation with the longest preoperative mechanical ventilation period ever reported.

Clinical Summary

A 6-year-old girl was diagnosed with SJS after receiving oral medication for an upper respiratory tract infection and treated with corticosteroids, but required mechanical ventilation on July 7, 2007. Under intensive care, she was extubated on July 18. Although there was a gradual improvement of skin lesions, her respiratory status worsened again, and a diagnosis of BO was made. She was re-intubated on November 13, 2007.

The patient was transferred to Kyoto University Hospital on May 21, 2008. On admission, she was on a ventilator through a tracheostomy. The ventilator setting was SIMV mode, $f = 10/\text{min}$, pressure control was $26 \text{ cmH}_2\text{O}$, and pressure support was $26 \text{ cmH}_2\text{O}$. Arterial blood gas revealed a pH of 7.33, PaO_2 of 88.6 mmHg, and PaCO_2 of 62.3 mmHg with this setting (FiO_2 0.3). Her spontaneous respiratory rate was 30-35 /min, and her own respiratory effort was preserved.

Cadaveric lung transplantation was not a realistic option because brain death is accepted only for those older than 15 years old in Japan. Her mother, 35 years old, was the only available living-donor in her family. The surgical options were discussed with the family and they were willing to proceed with living-donor single-lobe transplantation, which they understood to still

be an experimental procedure. The respective heights and weights were 113 cm and 16.0 kg for the recipient, and 160 cm and 58.0 kg for the donor. The estimated FVC of the graft (mother's right lower lobe) was 73.3% of the recipient's predicted FVC. Three-dimensional CT volumetric evaluation indicated the recipient's right chest cavity to be 825 ml, and donor's right lower lobe to be 1,334 ml.

On June 5, 2008, after mechanical ventilation for 7 months, she underwent living-donor single-lobe lung transplantation through a right anterolateral thoracotomy using the donor's right lower lobe. After re-ventilation of the graft, it was clearly oversized macroscopically, and the graft was manually compressed into the chest cavity. However, closure of the chest did not cause hemodynamic instability and blood gas was satisfactory. Chest X-ray after transplantation revealed no obvious atelectasis in both lungs.

The postoperative course was relatively uneventful. The patient was completely weaned from the ventilator on postoperative day (POD) 47. She was discharged from the hospital on POD 81. Chest X-ray 6 months after transplant revealed good inflation of the right lung graft and satisfactory diaphragm movement (Figure 1). At that time, the 6-minute walk distance was 380 meters, and the lowest SpO₂ in room air was 95%. Arterial blood gas revealed a pH of 7.40, PaO₂ of 88.7 mmHg, and PaCO₂ of 33.9 mmHg. FVC was 1.08 L (75.1% predicted) and FEV1 was 0.72 L. Nine months postoperatively, she had returned to a normal life without oxygen inhalation and is able to perform daily activities.

Discussion

It is well known that patients receiving ventilation at the time of transplantation are at an increased risk of operative mortality, both after cadaveric¹ and living-donor lobar lung

transplantation². The present pediatric patient was dependent on a ventilator for 7 months, which we believe is the longest period ever reported on living-donor lobar lung transplantation.

Furthermore, she had only one available donor, and the lobe was clearly oversized. Shiraishi et al.³ reported successful living-donor single-lobe transplantation for a 4-year-old boy who was on a ventilator. However, the preoperative ventilator period was 4 weeks, and size mismatch (118%) was not as great as in our case (162%) on the bases of 3-D CT volumetric evaluation.

Disuse atrophy of the diaphragm caused by long-term mechanical ventilation was a marked concern. The oversized graft might further jeopardize the diaphragm movement. Although it took 47 days, weaning from ventilator was successful, indicating that disuse atrophy of the diaphragm was minimal in spite long-term ventilation. We would like to emphasize that her respiratory effort was well preserved preoperatively.

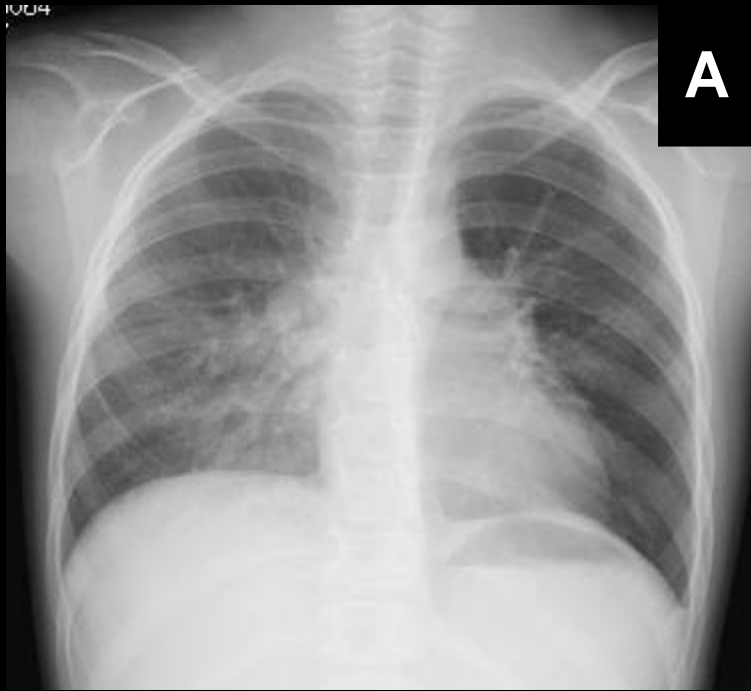
Most centers accept only very sick patients as candidates for living-donor lobar lung transplantation. However, if the recipient is too sick, it would not be justified to place healthy donors at risk. The present single-lobe transplantation was performed as a life-saving procedure. Although the short-term outcome was satisfactory, long-term follow-up is needed to assess if this procedure is justified.

Figure Legend

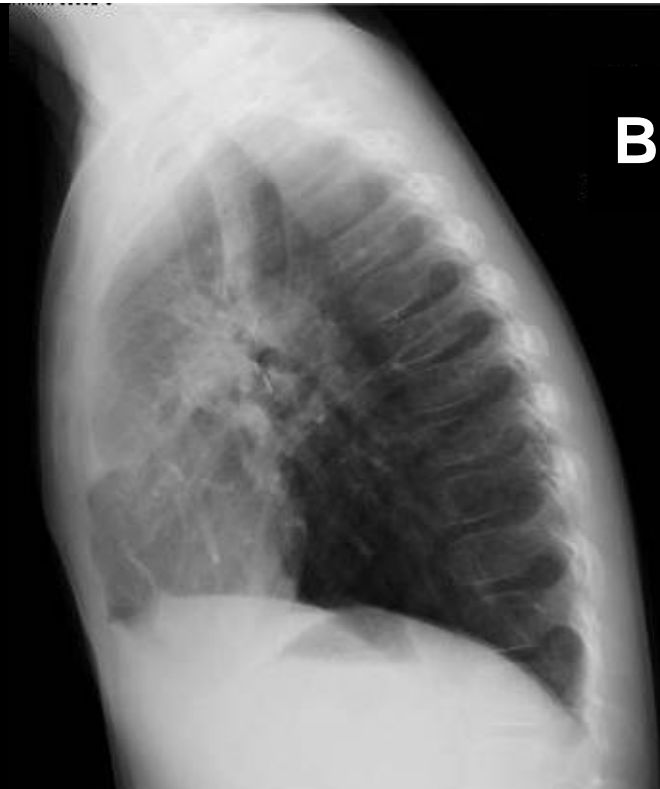Figure 1. Chest X-ray 6 months after transplantation in maximal inspiratory (A: frontal view, B: lateral view) and expiratory (C: frontal view, D: lateral view) states.

References

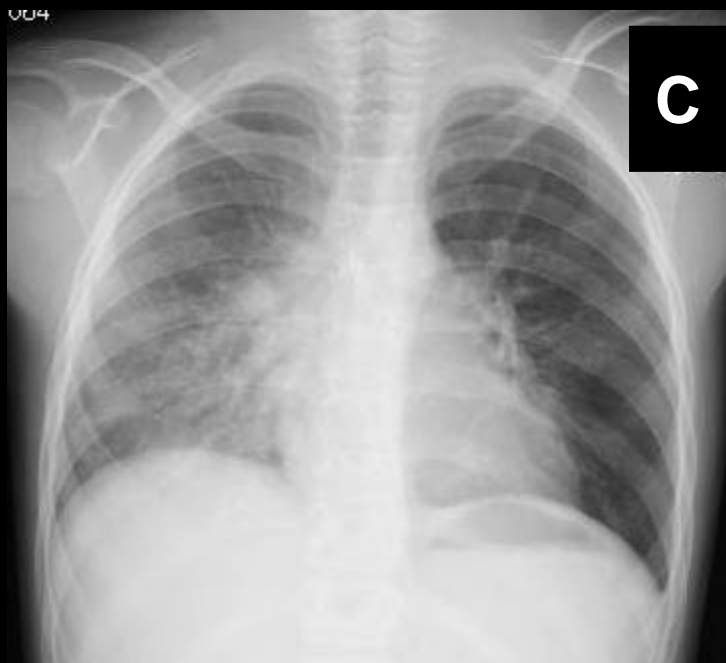1. Christie JD, Edwards LB, Aurora P, Dobbels F, Kirk R, Rahmel AO, et al. Registry of the International Society for Heart and Lung Transplantation: twenty-fifth official adult lung and heart/lung transplantation report--2008. *J Heart Lung Transplant*. 2008;27:957-69.
2. Starnes VA, Bowdish ME, Woo MS, Barbers RG, Schenkel FA, Horn MV, et al. A decade of living lobar lung transplantation: recipient outcomes. *J Thorac Cardiovasc Surg*. 2004;127:114-22.
3. Shiraishi T, Hiratsuka M, Munakata M, Higuchi T, Makihata S, Yoshinaga Y, et al. Living-donor single-lobe lung transplantation for bronchiolitis obliterans in a 4-year-old boy. *J Thorac Cardiovasc Surg*. 2007;134:1092-3.



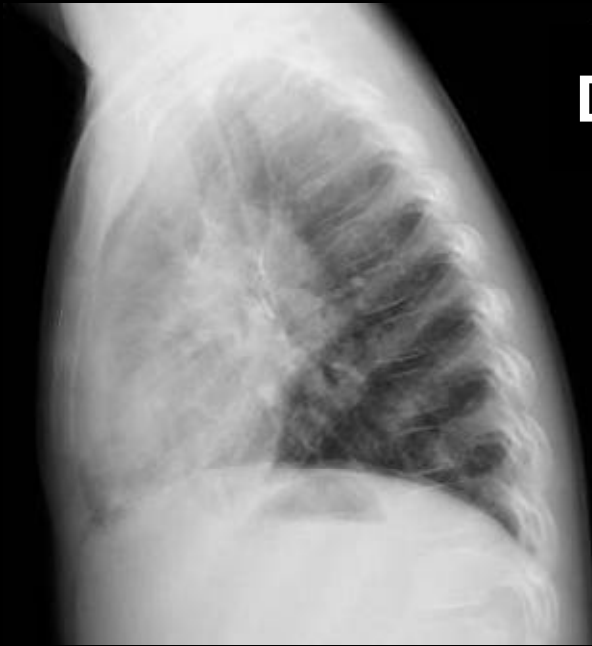
A



B



C



D