

|             |  |
|-------------|--|
| Title       | GONADAL FUNCTIONS IN SEVEN PATIENTS WITH PRADER-LABHART-WILLI SYNDROME   |
| Author(s)   | Okuyama, Akihiko; Koide, Takuo; Sonoda, Takao; Matsumoto, Keishi; Nishimoto, Naomitsu; Mizutani, Shutaro; Namiki, Mikio; Itatani, Hiroaki; Mitsubayashi, Shigeru; Yoshida, Takao |
| Citation    | 泌尿器科紀要 (1981), 27(4): 347-354  |
| Issue Date  | 1981-04  |
| URL         | <a href="http://hdl.handle.net/2433/122874">http://hdl.handle.net/2433/122874</a>  |
| Right       |  |
| Type        | Departmental Bulletin Paper  |
| Textversion | publisher  |

## GONADAL FUNCTIONS IN SEVEN PATIENTS WITH PRADER-LABHART-WILLI SYNDROME

Akihiko OKUYAMA, Takuo KOIDE and Takao SONODA

Keishi MATSUMOTO

*From the Department of Urology, Pathology, Osaka University Medical School, Osaka, Japan.*

Naomitsu NISHIMOTO and Shutaro MIZUTAMI

*From the Department of Urology, Osaka Labour-Injury Hospital, Osaka, Japan.*

Mikio NAMIKI and Hiroaki ITATANI

*From the Department of Urology, Sumitomo Hospital, Osaka, Japan.*

Shigeru MITSUBAYASHI and Takao YOSHIDA

*From the Department of Urology, Ashiya City Hospital, Hyogo Japan.*

### ABSTRACT

LH-RH test, HCG test and testicular biopsy were performed in 7 boys with Prader-Labhart-Willi syndrome (PLWS) in whom bilateral cryptorchidism was observed. The age of patients ranged 7-1/6 to 15-1/12 years. Six out of 7 patients had no pubertal signs and the basal levels of serum LH, FSH and testosterone were low. Furthermore, no significant responses of serum LH and FSH to LH-RH stimulation and of testosterone to HCG were observed. Histological examination of the testes in these six patients revealed the seminiferous tubules containing reduced numbers of immature germ cells in 6 cases and interstitial fibrosis in 3 cases. However, the basal values of LH, FSH and testosterone in 1 out of seven cases with pubertal signs were higher than those in remaining 6 cases and significant hormonal responses to LH-RH stimulations were demonstrated. In the seminiferous tubule of the last patient, spermatocytes and spermatids were found. These findings suggest that different patterns of disturbance of hypothalamo-pituitary-gonadal system are present in male patients with PLWS.

PLWS, originally described in 1956 by Prader, Labhart and Willi, is characterized by neonatal and early infancy hypotonia, mental deficiency, hypogonadism and early childhood onset of obesity. In these main symptoms, the cause of hypogonadism is still obscure. In male patients with PLWS, a high incidence of cryptorchidism has been reported (Hall & Smith, 1972). The present paper shows the pituitary-gonadal functions and histological findings of the testes in 7 patients with PLWS (1972).

### MATERIALS AND METHOD

Seven male patients were diagnosed as PLWS by past history and physical findings (Table 1, Figure 1). They were 15-1/12,

14-2/3, 12-11/12, 11-1/2, 11-1/12, 7-1/2 and 7-1/6 years old, respectively, and the cases 3 and 4 were brothers. In cases 2 and 5, bilateral orchiopexy and testicular biopsy had been performed at 6-1/2 and 7-1/6 years of age, respectively (Okuyama et al., 1976). The findings of external genitalia were stage P1 in all but the case 2 who was in the stage P2 (Marshall & Tanner, 1970).

The endocrinological examinations were made in the following way. Blood samples were taken at 9:00 a.m. in quiet and empty stomach, and then synthetic luteinizing hormone releasing hormone (LH-RH), 100  $\mu\text{g}/\text{m}^2$  body surface area was administered intravenously. Blood samples were taken 30, 60, 90 and 120 min. after the administ-

Table 1. Physical and endocrinological findings in seven patients with Prader-Labhart-Willi syndrome

| Case No. | Age      | P* stage | Height (cm) | Weight (kg) | Basal LH** | Peak LH | Basal FSH** | Peak FSH | Basal T*** | Peak T. |
|----------|----------|----------|-------------|-------------|------------|---------|-------------|----------|------------|---------|
| 1        | 15-1/12  | 1        | 148         | 60          | 1          | 1       | 2           | 3        | 0.4        | 0.5     |
| 2        | 14-2/3   | 2        | 152         | 49          | 5          | 14      | 4           | 12       | 1.5        | 4.4     |
| 3        | 12-11/12 | 1        | 134         | 45          | 2          | 3       | 2           | 2        | 0.3        | 0.4     |
| 4        | 11-1/2   | 1        | 130         | 43          | 1          | 3       | 1           | 2        | 0.4        | 0.4     |
| 5        | 11-1/12  | 1        | 126         | 42          | 2          | 2       | 1           | 2        | 0.3        | 0.4     |
| 6        | 7-1/2    | 1        | 114         | 32          | 1          | 2       | 1           | 1        | 0.3        | 0.3     |
| 7        | 7-1/6    | 1        | 111         | 28          | 1          | 2       | 1           | 1        | 0.3        | 0.4     |

\* P stage : pubertal stage (P1-P5), \*\* LH, FSH : serum LH, FSH (mIU/ml),  
 \*\*\* T. : serum testosterone (ng/ml)

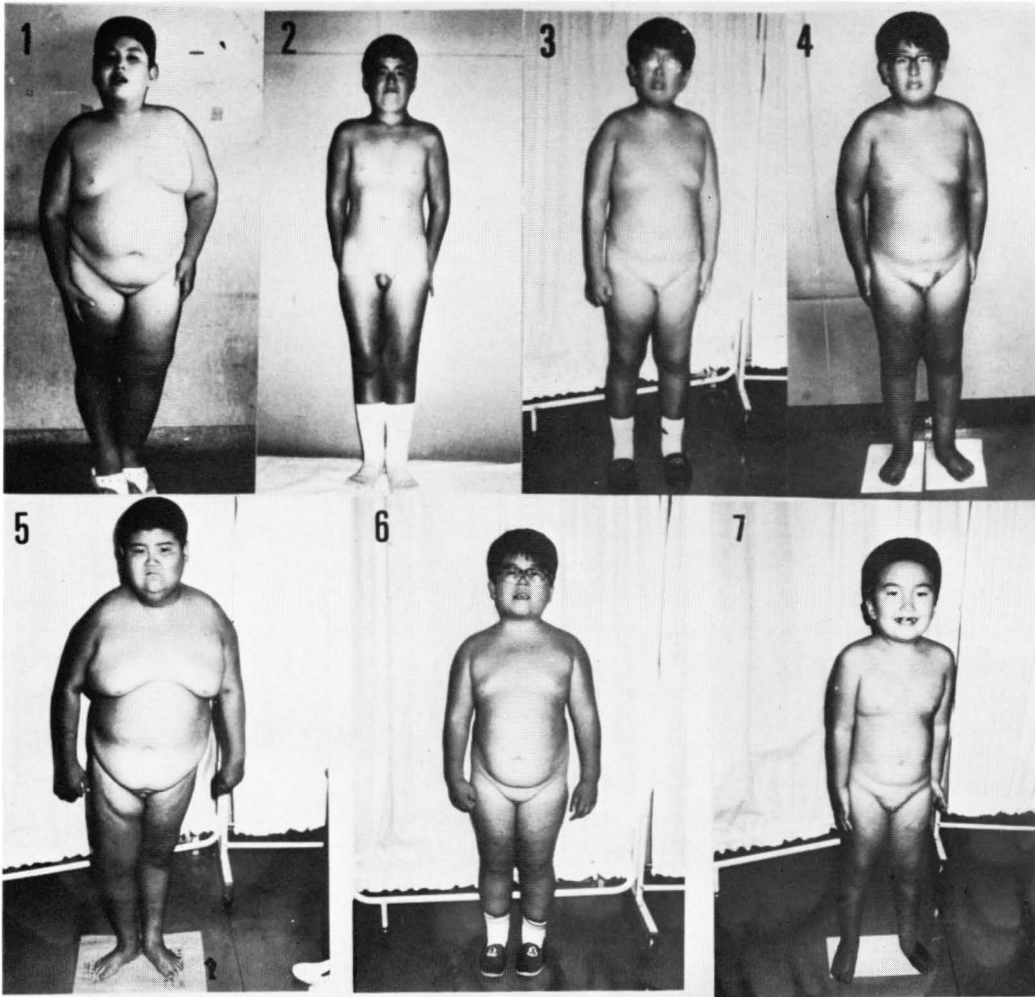


Fig. 1. Body statures of seven patients with Prader-Labhart-Willi syndrome

ration and LH and FSH levels in serum obtained before and after the administration were determined. One week after the LH-RH administration, blood samples were taken at 9:00 a.m. in quiet and empty stomach and then human chorionic gonadotropin (HCG) 3,000 IU/m<sup>2</sup> body surface area was administered intramuscularly for five consecutive days. Blood samples were taken 6 hours after the 5th administration and serum testosterone levels were determined. Within one week after the HCG administration, bilateral orchiopexy and right testicular biopsy were performed in five cases (cases 1, 3, 4, 6 and 7). The right testicular biopsy in the case 2 and 5 was made by scrotal incision. The specimens taken were fixed with Bouin's solution and stained with hematoxylin and eosin for microscopic examinations. For therapeutic purpose, 5,000 IU/m<sup>2</sup> body surface of HCG was injected intramuscularly twice a week for 15 weeks and 8 weeks in cases 1 and 3 and cases 4, 5, 6 and 7 respectively. Serum testosterone levels were measured immediately after every fifth injection.

Serum levels of LH and FSH were determined by double antibody radioimmunoassay as described previously (Aono et al., 1972). Human pituitary LH and FSH, which were obtained from Calbiochem., Jolla, Calif., U.S.A. were labeled <sup>125</sup>I. Antisera, also obtained from Calbiochem., were diluted with 0.01 M phosphate buffered saline (pH 7.6) containing 1% normal rabbit serum. Two IU of HCG was added per tube to enhance the specificity in FSH assay. The separation of bound from free was achieved by sheep antirabbit  $\gamma$ -globulin serum. The 2nd International Reference of Human Menopausal Gonadotropin was performed in duplicate using 0.1–0.4 ml of serum per tube. The minimal detectable dose was 0.5 mIU/ml in the LH assay and 1.0 mIU/ml in the FSH assay. The intra- and interassay coefficient of variation in the normal male range obtained from 8 assays were respectively, 9.0 and 14.1% in the LH assay and 13.3 and 19.4% in the FSH assay. Specificity study of the assay revealed less than 1% cross-reaction by weight for synthe-

tic human adrenocorticotropin (Richter, Bh<sup>1-39</sup>), human growth hormone (Wilhermi) and human FSH (Calbiochem.), and less 4% for human thyrotropin (Condliff). FSH assay was also specific for human FSH having less than 1% cross-reactivity by weight for human adrenocorticotropin, growth hormone, thyrotropin, LH (Calbiochem.) and HCG (Teizo).

The serum testosterone level was measured by radioimmunoassay (Yoshimi et al., 1972) with slight modifications. The antiserum was prepared in rabbit by immunization with testosterone-3-carboxymethyl-oxime-bovine serum albumin. The radioactive steroid used was [1.2-<sup>3</sup>H] testosterone (Daiichi Pure Chemical), 40 Ci/mmol. The separation of free from bound was achieved by the dextran-coated charcoal method. The assay was performed in duplicate using 0.1–0.5 ml of serum per tube. For the estimation of low basal levels of serum testosterone in the prepubertal boys a more diluted antiserum and 0.5 ml serum were used. The minimal detectable dose was 0.06 ng/ml. The intra- and interassay coefficient of variation in male serum range obtained from 10 assays were 8.2 and 9.9%, respectively. The antiserum used cross-reacts with 5 $\alpha$ -reduced androstane-5 $\alpha$ -dihydrotestosterone (65%), 5 $\alpha$ -androstane-3 $\alpha$ , 17 $\beta$ -diol (17%) and 5 $\alpha$ -androstane-3 $\beta$ , 17 $\beta$ -diol (7%) but not with estradiol-17 $\beta$ , progesterone, cortisol or corticosterone.

## RESULT

In six patients without pubertal signs (P1), serum LH and FSH levels were invariably low, and serum testosterone levels were less than 1.0 ng/ml in all cases. In addition, no significant response in the levels of LH, FSH and testosterone were found by the LH-RH and HCG tests in these six patients (Table 1). In case 2 with pubertal changes, on the other hand, serum LH, FSH and testosterone levels were higher than those in six patients without pubertal signs, and significant responses to both LH-RH and HCG stimulations were found (Table 1). The peak levels of serum testosterone in cases 1, 3, 4, 5, 6 and

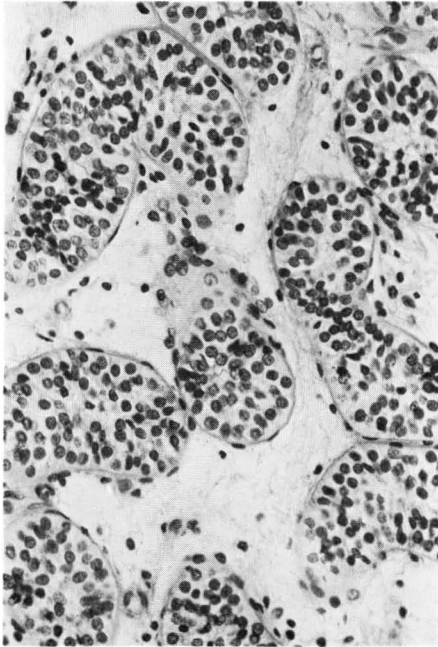


Fig. 2

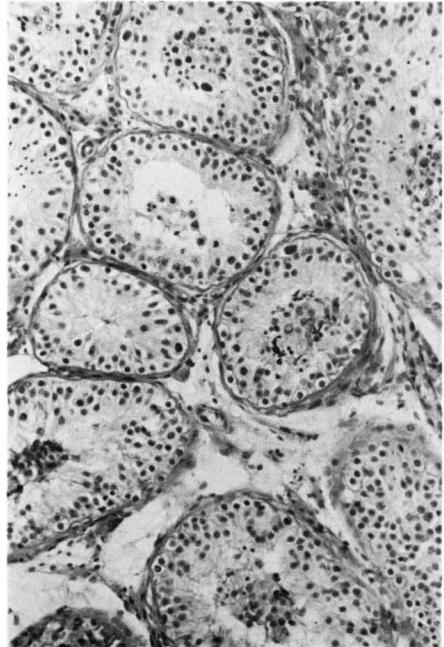


Fig. 3

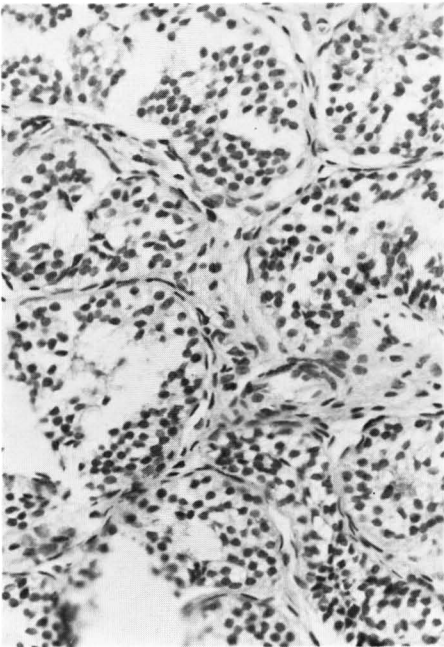


Fig. 4

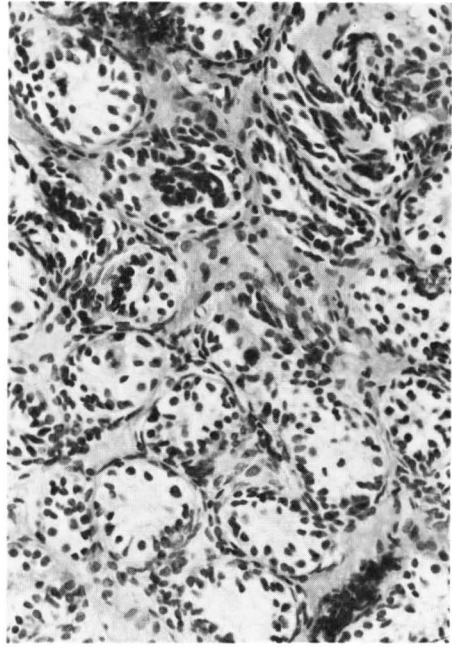


Fig. 5

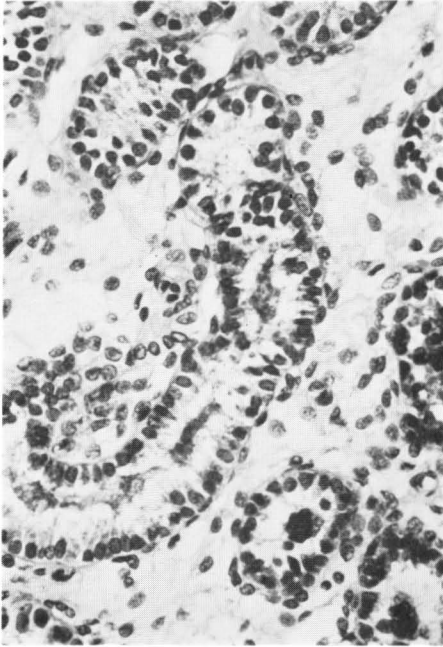


Fig. 6

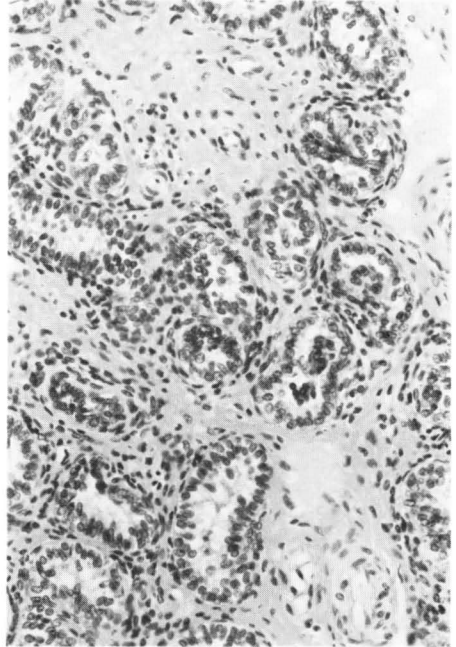


Fig. 7

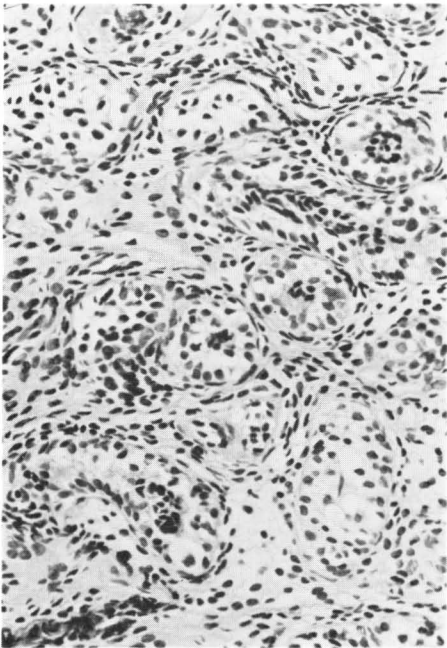


Fig. 8

## Legend for Fig. 2~8

Case 1. Magnification  $\times 200$ . The seminiferous tubules contain small numbers of immature Sertoli cells and spermatogonia. Interstitial fibrosis is moderate and clusters of mature Leydig cells are not found (prepubertal testis). Case 2. Magnification  $\times 100$ . The seminiferous tubules contain normal numbers of spermatocytes and spermatids. Clusters of mature Leydig cells are found in the right upper corner of the picture (pubertal testis). Case 3, 4 and 5. Magnifications  $\times 200$ ,  $\times 200$  and  $\times 400$ . The seminiferous tubules contain slightly small numbers of immature Sertoli cells and spermatogonia. Clusters of mature Leydig cells are not found (prepubertal testes). Case 6. Magnification  $\times 200$ . The seminiferous tubules are slightly thickened and contain small numbers of immature Sertoli cells and spermatogonia. Interstitial fibrosis is moderate and clusters of mature Leydig cells are not found (prepubertal testis). Case 7. Magnification  $\times 200$ . The seminiferous tubules contain small numbers of immature Sertoli cells and spermatogonia. Interstitial fibrosis is moderate and clusters of mature Leydig cells (prepubertal testis).

7 (without pubertal signs) during the therapeutic HCG injections were 0.6, 0.4, 0.5, 0.3, 0.5 and 0.5 ng/ml, respectively, showing no significant responses by repeated HCG stimulations.

Histological findings of testicular biopsy in case 1 showed atrophic prepubertal testis with reduced numbers of immature Sertoli cells and spermatogonias and moderate interstitial fibrosis (Figure 2). In case 2, the seminiferous tubules were filled with normal numbers of spermatocytes and spermatids and clusters of Leydig cells were found in the interstitial tissue (Figure 3). In cases 3, 4 and 5, the seminiferous tubules were composed solely of immature Sertoli cells and spermatogonias, showing a definite picture of prepubertal testis (Figure 4~6). Cases 6 and 7 showed the finding of prepubertal testis with reduced numbers of immature Sertoli cells and spermatogonias, and interstitial fibrosis (cases 6 and 7) and tubular thickening (case 6) were also found (Figure 7~8).

#### DISCUSSION

Hypogonadism is one of the commonly described clinical feature of PLWS (Zellweger & Schneider, 1968). In male patients, small phallus and testes, hypoplastic scrotum, and high frequency of abdominal or inguinal testicular retention are found, and the appearance of secondary sexual characteristics is generally delayed (Zellweger & Schneider, 1968; Hamilton et al., 1972; Hall & Smith, 1972; Wannarachue et al., 1975). Recent findings in PLWS have shown that patients without pubertal signs show low levels of serum and urinary gonadotropin (Laurence, 1967; Hamilton et al., 1972). However, patients with high gonadotropin levels have also been reported (Seyler et al., 1979). In patients with pubertal sign, gonadotropin levels have been reported to be invariably within the normal range (Hamilton et al., 1972; Wannarachue et al., 1975). The present findings shown in Table 1 confirm these observations. There are not many reports dealing with response of gonadotropin to LH-RH in PLWS, but significant responses

to LH-RH in some prepubertal patients have been reported (Morgner et al., 1974; Seyler et al., 1979). Although the above observation is inconsistent with our finding shown in Table 1, the patients examined by others were invariably older than those reported in this paper. In connection with the response of testosterone level to HCG stimulation in patients with PLWS, responsive (Tolis et al., 1974; Wannarachue et al., 1975) or nonresponsive (Seyler et al., 1979) findings have been reported. Our findings clearly demonstrated that patients without pubertal sign showed no responses to LH-RH as well as HCG stimulations, while those with pubertal signs responded significantly to both LH-RH and HCG stimulations.

In regard to the histological findings of testes in PLWS normal findings in some patients (Zellweger & Schneider, 1968), and abnormal findings such as decreased numbers of germ cells, small atrophic tubules, tubular thickening in the other patients (Hamilton et al., 1972; Wannarachue et al., 1975) have been reported. Our patient with pubertal signs showed normal testicular histology but those without pubertal signs showed the abnormal findings.

There are two possibilities for the pathogenesis of hypogonadism in PLWS: (1) Hypothalamic disorder from the fetal period causes irreversible change in pituitary gonadal axis. (2) Maturation in hypothalamo-pituitary system is only delayed. If the former is true, gonadotropin levels cannot be increased to LH-RH stimulation and long-term administration of HCG cannot be effective. If the latter is true, onset of puberty may possibly be induced by long-term administration of LH-RH or HCG. Since our patients without pubertal signs showed no response to both LH-RH and HCG administrations, it seems that irreversible change in pituitary and Leydig cell is induced by hypothalamic disorders in these patients. But from report of other authors investigating other type of hypogonadotropic hypogonadism, a longer HCG therapy than ours might be needed

for conclusion that irreversible changes in Leydig cells exist (Betend et al., 1977). The findings in many patients with PLWS reported by us and other investigators have shown that there are positive and negative responses to clomid, LH-RH and HCG administrations (Hamilton et al., 1972; Hall & Smith, 1972; Jeffcoate, 1980; Tolis et al., 1972; Wannarachue et al., 1975; Seyler et al., 1979). The pathogenesis of hypogonadism in PLWS is left unclarified.

#### REFERENCES

- 1) Aono T, Kurachi K., Mizutani S., Hamanaka Y., Uozumi T., Nakashima A. & Matsumoto K.: Influence of major surgical stress on plasma levels of testosterone, luteinizing hormone and follicle-stimulating hormone in male patients. *J. Clin. Endocrinol.*, **35** : 535~541, 1972.
- 2) Betend B., Lebacqz E. Jr., David L., Claustrat B. & Francois R.: Familial hypogonadotropic hypogonadism. *Acta Endocrinol. (kbh)*, **84** : 246~253, 1977.
- 3) Hall B. D. & Smith D. M.: Prader-Willi syndrome. *J. Pediatrics*, **81** : 286~293, 1972.
- 4) Hamilton C. R., Scully R. E. & Kliman B.: Hypogonadism in Prader-Willi syndrome. *Am. J. Med.*, **52** : 322~329, 1972.
- 5) Jeffcoate W. J., Laurence B. M., Edward C. R. M. & Besser G. M.: Endocrine function in the Prader-Willi syndrome. *Clin. Endocrinol.*, **12** : 81~89, 1980.
- 6) Laurence B. M.: Hypotonia, obesity, hypogonadism and mental retardation. *Arch. Dis. Child.*, **42** : 126~139, 1967.
- 7) Marshall W. A. & Tanner J. M.: Variation in the patterns of prepubertal change in boy. *Arch. Dis. Child.*, **42** : 126~139, 1970.
- 8) Morgner K. D., Geisthorel W., Niedergerker U. und Muhlen A. V. Z.: Hypogonadismus im folge mangels und Luteotropin-Releasing-Hormon (LHRH) bei Prader-Labhart-Willi Syndrome. *Deutsch. Med. Wochenschr.*, **99** : 1196~1198, 1974.
- 9) Okuyama A., Nagai N., Usami M., Itatani H. and Mizutani S.: Prader-Willi syndrome: Report of two cases. *Jap. J. Urol.*, **67** : 548~557, 1976.
- 10) Prader A., Labhart A. & Willi H.: Ein Syndrome von Adipositas, Kleinwuchs, Kryptorchidism und Oligophrenie nach myatonieartigen Zustand in Neugeborenenalter. *Schweiz. Med. Wochenschr.*, **86** : 1260~1261, 1956.
- 11) Seyler L. E. Jr., Arulanantham K. & O'Corner C. F.: Hypogonadotropic Hypogonadism in Prader-Labhart-Willi syndrome. *J. Pediatrics*, **94** : 435~436, 1979.
- 12) Tolis G., Lewis W., Verdy M., Friesen H. G., Solomon S., Pagalis G., Parlatos F., Fessas P. H. & Rochefort J. G.: Anterior-pituitary function in the Prader-Labhart-Willi (PLW) syndrome. *J. Clin. Endocrinol.*, **39** : 1060~1066, 1974.
- 13) Wannarachue T., Ruvalcaba R. H. A. & Kelly V.: Hypogonadism in Prader-Willi syndrome. *Am. J. Ment. Defic.*, **79** : 592~597, 1975.
- 14) Yoshimi T., Nakai Y., Endo J., Kono T. & Yoshimoto A.: Measurement of plasma testosterone and its clinical application. *Proceed Symp. Physiol. Pathol.*, **12** : 113~117, 1972.
- 15) Zellweger H. & Schneider H.: Syndrome of Hypotonia-Hypomentia-Hypogonadism-Obesity. (HHHO) or Prader-Willi syndrome. *Am. J. Dis. Child.*, **115** : 588~598, 1968.

(Accepted for publication, Nov. 19, 1980)



## Prader-Labhart-Willi 症候群を有する 7 例の性腺機能

大阪大学医学部泌尿器科学教室（主任：園田孝夫教授）

奥 山 明 彦

小 出 卓 生

園 田 孝 夫

大阪大学医学部第二病理学教室（主任：松本圭史教授）

松 本 圭 史

大阪労災病院泌尿器科（部長：水谷修太郎博士）

西 本 直 光

水 谷 修 太 郎

住友病院泌尿器科（部長：板谷宏彬博士）

並 木 幹 夫

板 谷 宏 彬

市立芦屋病院泌尿器科（部長：宮川光生博士）

光 林 茂

吉 田 隆 夫

両側停留睾丸を合併した 7 1/6～15 1/12 の Prader-Labhart-Willi 症候群 (PLWS) 7 例に対して LH-RH, HCG 両負荷試験および睾丸生検術を施行した。6 例には第二次性徴の発来は無く、血中 LH, FSH, testosterone は低値で、さらに LH-RH, HCG に対して有意の反応はみとめられなかった。以上 6 例の睾丸組織像において、精祖細胞の減少を全例に、また間

質の線維化を 3 例にみとめた。一方、他の 1 例には第二次性徴の発来をみており、血中 LH, FSH, testosterone は他のものより高値を呈し、LH-RH, HCG に対しても有意の反応をみ、加えて精細管中には精母細胞、精子細胞をみとめた。以上の所見から PLWS の中には、異った視床下部下垂体性腺系障害を有する症例が存在することが想定された。