

Title	UNILATERAL AND SOLITARY RENAL METASTASIS FROM WELL DIFFERENTIATED THYROID CARCINOMA INITIALLY TREATED 22 YEARS BEFORE : A CASE REPORT
Author(s)	Okada, Yusaku; Nonomura, Mitsuo; Terauchi, Toshiro; Kawamura, Juichi; Yoshida, Osamu
Citation	泌尿器科紀要 (1979), 25(10): 1043-1047
Issue Date	1979-10
URL	http://hdl.handle.net/2433/122517
Right	
Type	Departmental Bulletin Paper
Textversion	publisher

UNILATERAL AND SOLITARY RENAL METASTASIS FROM WELL DIFFERENTIATED THYROID CARCINOMA INITIALLY TREATED 22 YEARS BEFORE: A CASE REPORT

Yusaku OKADA, Mitsuo NONOMURA, Toshiro TERACHI,
Juichi KAWAMURA and Osamu YOSHIDA

From the Department of Urology, Faculty of Medicine, Kyoto University, Kyoto, Japan

ABSTRACT

A unilateral and solitary metastatic renal tumor from the papillary adenocarcinoma of the thyroid which was initially diagnosed 22 years ago was detected in a 52-year-old Japanese woman. In this case, the primary thyroid cancer had metastasized to the regional lymph nodes and to the bone. On the extremely slow course of the disease, the tumor remained active and developed metastases to the left kidney, to the liver and to the muscle. To our knowledge, this is the second case which was clinically evaluated. The literature was briefly reviewed.

Metastatic renal tumors from an initial thyroid cancer are extremely rare. Most of the cases reported concerned such findings at the time of autopsy. The first clinical case as reported by Takayasu in 1968 concerned bilateral metastatic renal tumors from the thyroid¹⁾. We encountered clinically a solitary and unilateral metastatic renal tumor following a primary thyroid cancer.

CASE REPORT

Case 71-472-018: an emaciated 52-year-old Japanese woman was admitted to the Department of Urology, Kyoto University Hospital on March 29, 1977 with severe gross hematuria. She had a past history of thyroid cancer which had been treated in 1955 by extirpation of metastatic cervical lymph nodes and subsequent radiotherapy of the unresectable thyroid carcinoma. She had also undergone an operation for a pathologic bone fracture of the left femur at another hospital in 1974. But information on pathological findings for the surgery was not available. Laboratory studies revealed anemia (hemoglobin 9.6 gm per cent), but electrolytes, blood urea nitrogen, crea-

tinine and liver function tests were normal. Chest x-ray was normal. An excretory urogram showed a space-occupying lesion at the upper half of the left kidney (Fig. 1A), which was confirmed by the retrograde pyelogram (Fig. 1B). The right kidney appeared normal. At cystoscopy massive bleeding from the left ureteral orifice was observed. A selective renal angiogram revealed abundant tumor vessels at the upper half of the left kidney (Fig. 2, A), and such were revealed even more clearly by a pharmaco-angiogram using 5 μ g of angiotensin II (Fig. 2, B). To induce a cessation of the renal bleeding, an artificial embolization using Oxycel emulsion was performed on the tumorous arteries by means of a superselective angiographic technique (Fig. 2, C). Left radical nephrectomy was performed transperitoneally 13 days later. Total amount of hemorrhage during the operation was small (185 ml), and such was attributed to the preoperative embolization of the tumor. During the operation, multiple pea-sized nodules were noted in the liver, and in addition, a bean-sized hard tumor was also evident in the rectus muscle. A few

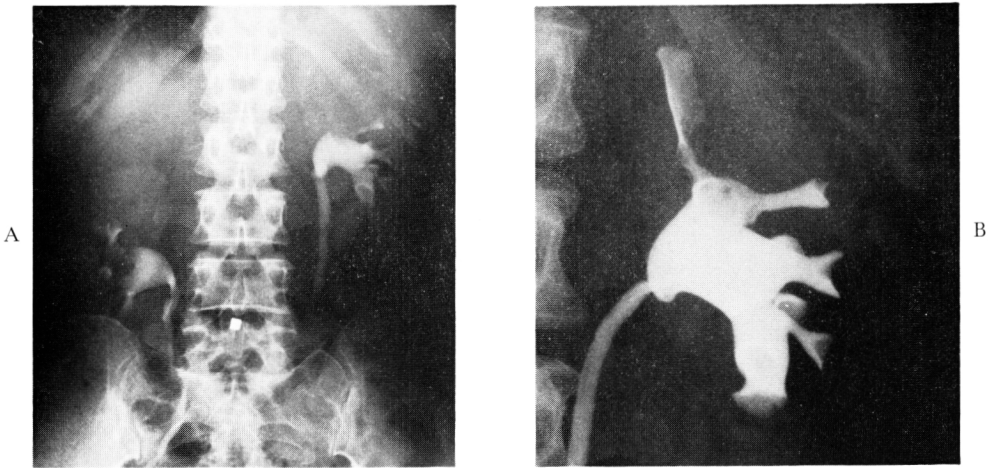


Fig. 1. A, Excretory urogram. Non-visualization of the upper calyx of the left kidney and compression shadow in the pelvis. The right kidney is ptotic. B, Left retrograde pyelogram. A space-occupying lesion at the upper half of the left kidney.

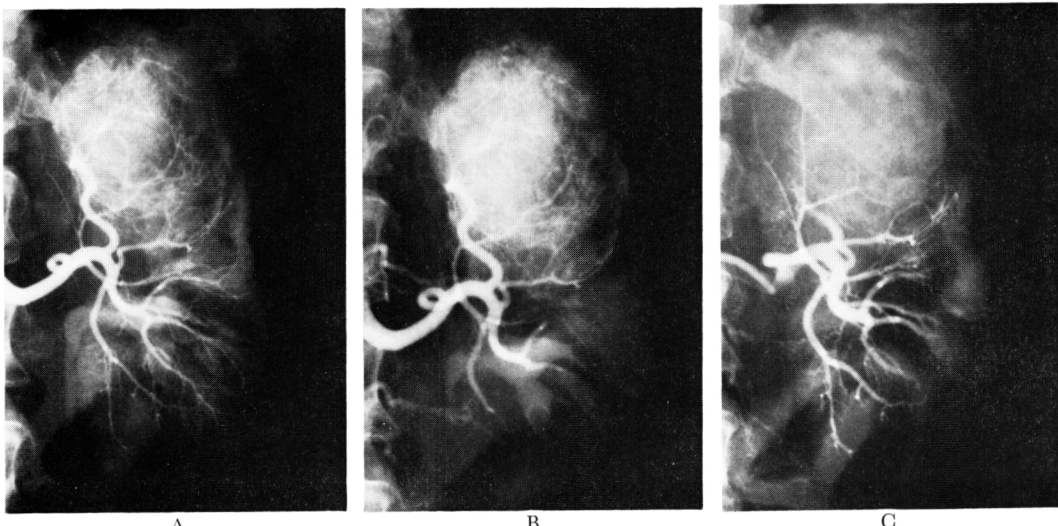


Fig. 2. A, Selective left renal angiogram. Highly vascular area in upper pole. No pooling, nor puddling is seen. B, Pharmaco-angiogram. Note healthy renal arteries constricted with application of angiotensin II. Intense opacification of tumor is demonstrated. C, After embolization. Complete block of the main tumor-feeding artery is seen.

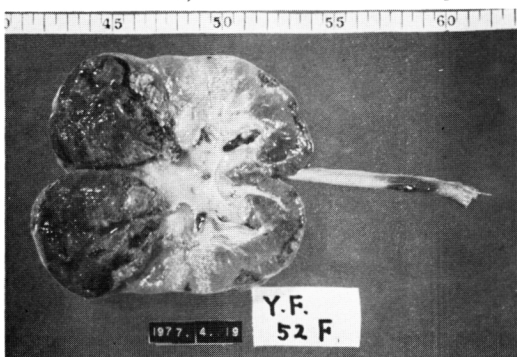

Fig. 3. Gross specimen. Most part of the tumor is necrotic due to preoperative embolization.

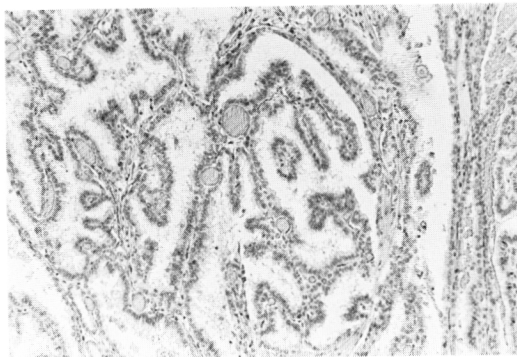


Fig. 4. Photomicrograph of the lesion. Papillary pattern and well-differentiation of tumor cells are noted. H&E, reduced from $\times 1001$.

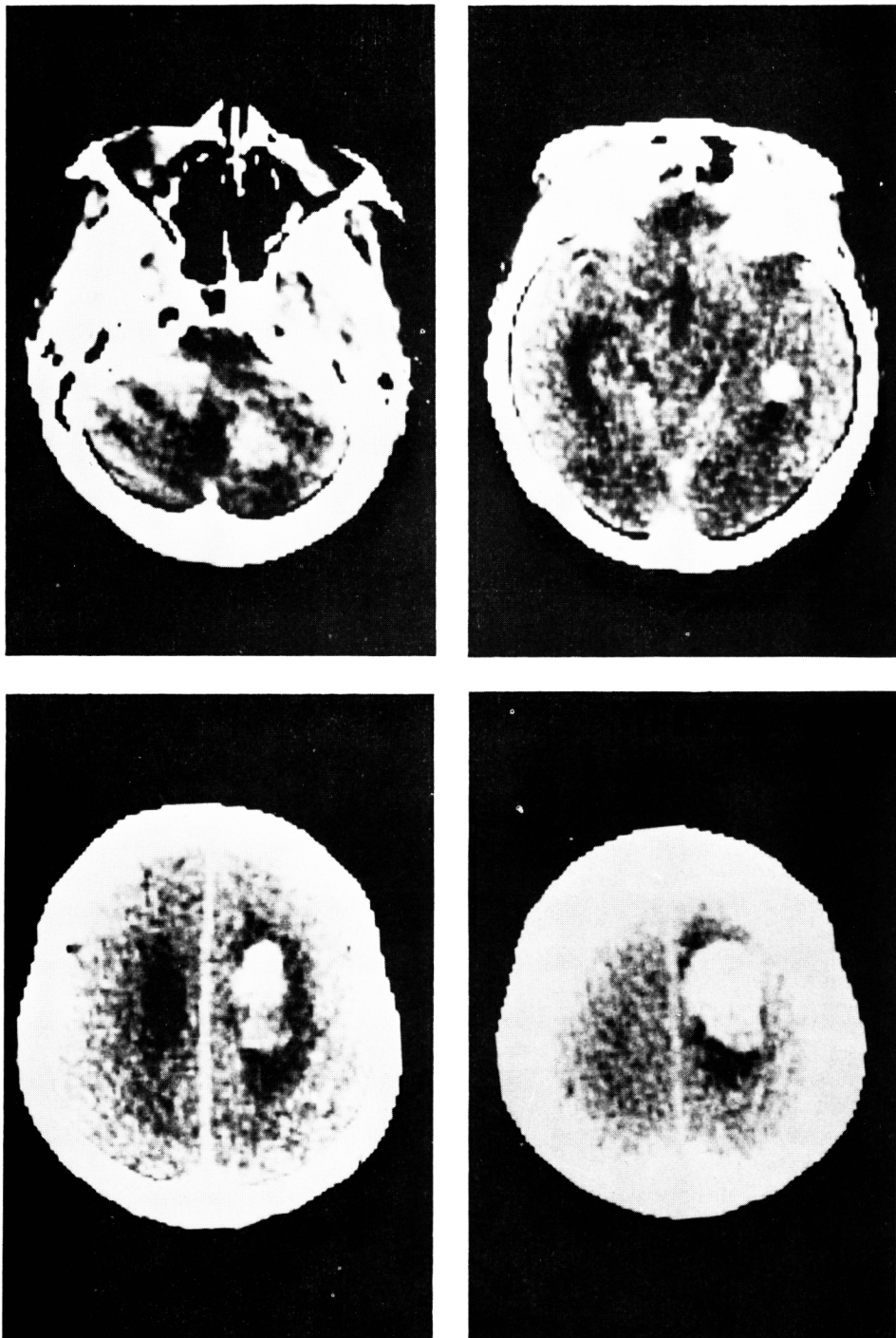


Fig. 5. Brain CT scan. Multiple metastases to right cerebellar (upper left), right temporal (upper right), and right frontal (lower left and right) regions are apparent.

nodules in the liver and the small tumor in the rectus muscle were biopsied at the same time. The resected kidney weighed 265 gm and the tumor was solitary, 6 cm in diameter. Most of the tumor was necrotic due to the preoperative embolization of the tumor feeding arteries (Fig. 3). Pathological studies revealed a metastasis of the papillary adenocarcinoma of the thyroid to the left kidney (Fig. 4), as well as to the liver and to the rectus muscle. Studies on thyroid function performed postoperatively showed normal basal metabolic rate, normal ^{123}I uptake by the remnant thyroid in 24 hours, normal Tetrasorb level, and high TSH level ($12.5 \mu\text{g}$ per millimeter), suggesting a slightly hypothyroid state. The metastatic hepatic tumors could not be evaluated whether they were functional or not, because the remnant thyroid could not be totally removed. The postoperative course was uneventful and the patient was discharged three weeks after and operation. She had been well with substitution of thyroid hormone to suppress TSH, which is thought to accelerate the tumor growth, until the end of 1977. But she developed local recurrence of the tumor and multiple metastases to the brain (Fig. 5), which caused generalized convulsions and tentorial herniation and death on Dec. 12, 1978. Autopsy was not performed.

DISCUSSION

Klinger reportedly found only one metastatic thyroid cancer out of 118 cases of secondary renal tumors among 5,000 autopsies²⁹. Wagle and associates reviewed 4,413 successive autopsy records and found 81 cases of secondary renal tumors, excluding lymphomas. Two of them originated from the thyroid. With regard to the metastatic renal tumors, primary lesions of the cancer were found in the lungs (19.8%), breast (12.3%), stomach (11.1%), and the opposite kidney (8.6%)³⁰ (Table 1). Papillary adenocarcinoma of the thyroid characteristically has a very favorable prognosis and a lower frequency of distant metastases than other forms of thyroid cancer. Reported mortality rates from the cancer

Table 1. Primary organ site in 81 cases of secondary renal metastases (D. G. Wagle et al, 1975)

Organ Site	No. of Pts.	per cent
Lung	16	19.8%
Stomach	9	11.1%
Breast	10	12.3%
Kidney	7	8.6%
Pancreas	3	3.7%
Ovary	2	2.5%
Esophagus	4	4.9%
Biliary tract	3	3.7%
Bone	2	2.5%
Rectum	1	1.2%
Cervix	2	2.5%
Testes	3	3.7%
Tongue	2	2.5%
Colon	3	3.7%
Ileum	2	2.5%
Bladder	2	2.5%
Uterus	1	1.2%
Thyroid	2	2.5%
Extremity	1	1.2%
Skin	1	1.2%
Mouth	2	2.5%
Parotid	1	1.2%
Adrenal	2	2.5%

ranged from 4.8% to 15.2%⁴¹. It is estimated that 4% to 20% of patients with papillary cancer develop distant metastases during the course of their disease³¹. Common sites of distant metastases at time of death were lungs (51.4%), bones (25.7%), brain (10.0%) in reviewing 70 fatal cases from papillary adenocarcinoma of the thyroid⁴². Renal metastases are relatively rare and were found only at autopsy. The histology of Takayasu's case was follicular adenocarcinoma of the thyroid¹³.

The prognosis of metastatic renal tumors depends largely on the clinical course of the primary malignancy and their treatments should be determined after a careful assessment of individual factors. The slow course of the papillary thyroid cancer and unilaterality of the renal metastasis made a nephrectomy feasible in our patient.

REFERENCES

- 1) Takayasu, H., Kumamoto, Y., Terasaki, Y. and Ueno, A.: A case of bilateral metastatic renal tumor originating from a thyroid carcinoma. *J. Urol.*, **100**: 717, 1968.
- 2) Klinger, M. E.: Secondary tumors of the genitourinary tract. *J. Urol.*, **65**: 144, 1951.
- 3) Wagle, D. G., Moore, R. H. and Murphy, G. P.: Secondary carcinomas of the kidney. *J. Urol.*, **114**: 30, 1975.
- 4) Tollefsen, H. R., DeCosse, J. J. and Hutter, R. V. P.: Papillary carcinoma of the thyroid. A clinical and pathological study of 70 fatal cases. *Cancer*, **17**: 1035, 1964.
- 5) Harness, J. K., Thompson, N. W., Sisson, J. C. and Beierwaltes, W. H.: Differentiated thyroid carcinomas. Treatment of distant metastases. *Arch. Surg.*, **108**: 410, 1974.

(Accepted for publication, May 5, 1979)

和文抄録

放射線治療後22年目に血尿をみた甲状腺癌の腎転移例

京都大学医学部泌尿器科学教室

岡田 裕作・野々村 光生・寺地 敏郎
川村 寿一・吉田 修

他臓器の悪性腫瘍が腎臓に転移する例は、剖検では比較的多いが、生存中に転移が発見され臨床的に問題となることは稀である。ことに甲状腺癌の腎転移は、1968年高安らによる報告1例のみである。最近われわれは、52歳の女子で、22年前に治療を受けた甲状腺乳

頭状癌が左腎に孤立性に転移を来し、左腎摘除術を施行した症例を経験したので報告する。尚、本症は左腎摘除術後約1.5年目に腫瘍死したが、24年間の全経過中、局所リンパ節、骨、左腎、肝、筋、脳への転移が認められた。