

Title	A SIMPLE CYST OF THE TESTIS
Author(s)	Ichikawa, Yasuji; Ihara, Hideari; Nagano, Shunsuke
Citation	泌尿器科紀要 (1979), 25(3): 295-298
Issue Date	1979-03
URL	http://hdl.handle.net/2433/122394
Right	
Type	Departmental Bulletin Paper
Textversion	publisher

A SIMPLE CYST OF THE TESTIS

Yasuji ICHIKAWA, Hideari IHARA and Shunsuke NAGANO

From the Department of Urology, Hyogo Prefectural Hospital, Nishinomiya, Japan

ABSTRACT—A case of the simple cyst of the testis is presented. The literature is reviewed and clinicopathological aspects of this benign cystic disease are discussed. We propose a conservative operation for this lesion.

Testicular enlargement is often due to malignant diseases, but is seldom due to a benign cystic disease such as an epidermoid cyst¹⁾, a cyst within the teratoma²⁾, or a simple cyst of the testis. The latter is a very rare disease. Only five such cases have been reported as far as reviewed by us. This paper aims to make clear the feature of simple cyst of the testis and to introduce our case.

CASE

A one-year-one-month-old boy was brought to our hospital on July 20, 1977, because of an enlargement of the right scrotal content. His mother was first aware of its swelling while taking a bath about one month before the first visit. There had been no previous history of genitourinary trauma or infection. A physical examination revealed no remarkable change except the right testis which was three times as large as the opposite one. It was palpable with elastic hardness and without pain, tenderness or transillumination. The border between the testis and epididymis was not clear. He was diagnosed as having a testicular tumor and a right high orchiectomy was performed immediately.

PATHOLOGY

The removed right testis was elastic, soft, pale and enlarged with a smooth surface where there was no cystic appearance. The sagittal section of the testis showed that there was a cyst within the parenchyma which contained a clear yellow

fluid (Fig. 1, Fig. 2). The cyst wall was white and lined with a single layer of flatted cuboidal epithelium (Fig. 3-A). Testis and epididymis were well developed as in children of this age (Fig. 3-B).

DISCUSSION

Five cases of a simple cyst of the testis have been reported since Schmidt³⁾ published the first case in 1966 which involved a five months old boy. Those clinical pictures are summarized in Table 1. We studied our case and reviewed all literature in detail to disclose the aspects of this disease. Histological properties were able to be characterized as follows;

1) The cyst is located within the parenchyma of the testis.

2) The cyst contains clear fluid.

3) The cyst is surrounded by a single or a few layers of cuboidal or flatted epithelium.

The etiology of this cyst remains somewhat obscure but is considered to be divided into two groups. One group, the congenital type which rises in younger children, is due to the rest of the Wolffian or Müllerian duct. Case 1, 2⁴⁾, and 6 belong to this type. The other group, the acquired type in adults, is thought to be associated with previous urogenital trauma or infection. The other three^{5~7)} cases in Table 1 are considered to be included in this group. However, according to the literature, all patients had neither a history of urogenital trauma, infection, nor evidence of infection upon histopathological examination. There-

Table 1. Summary of the six simple testicular cysts.

Case	Reporter	Age	History of urogenital trauma or infection	Trans-illumination
1	Schmidt	5M	None	Positive
2	Sasaki et al.	5M	None	Negative
3	Ishibashi et al.	60Y	None	Positive
4	Tosi and Richardson	58Y	None	Negative
5	Takahara and Tokuhara	80Y	None	Unknown
6	Our case	13M	None	Negative

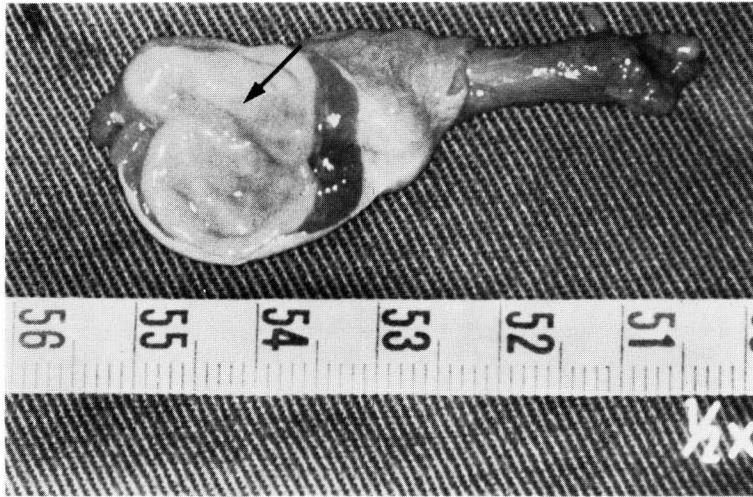


Fig. 1. The sagittal section of the right testis showed a cyst (the arrow) in the parenchyma of the testis containing a clear yellow fluid.

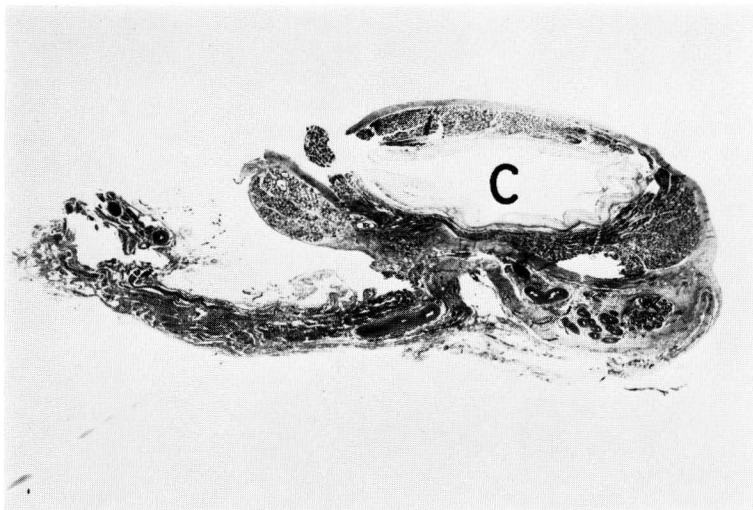


Fig. 2. Microphotography (H & E, $\times 1$)
A Cyst (C) was located within the parenchyma of the testis.

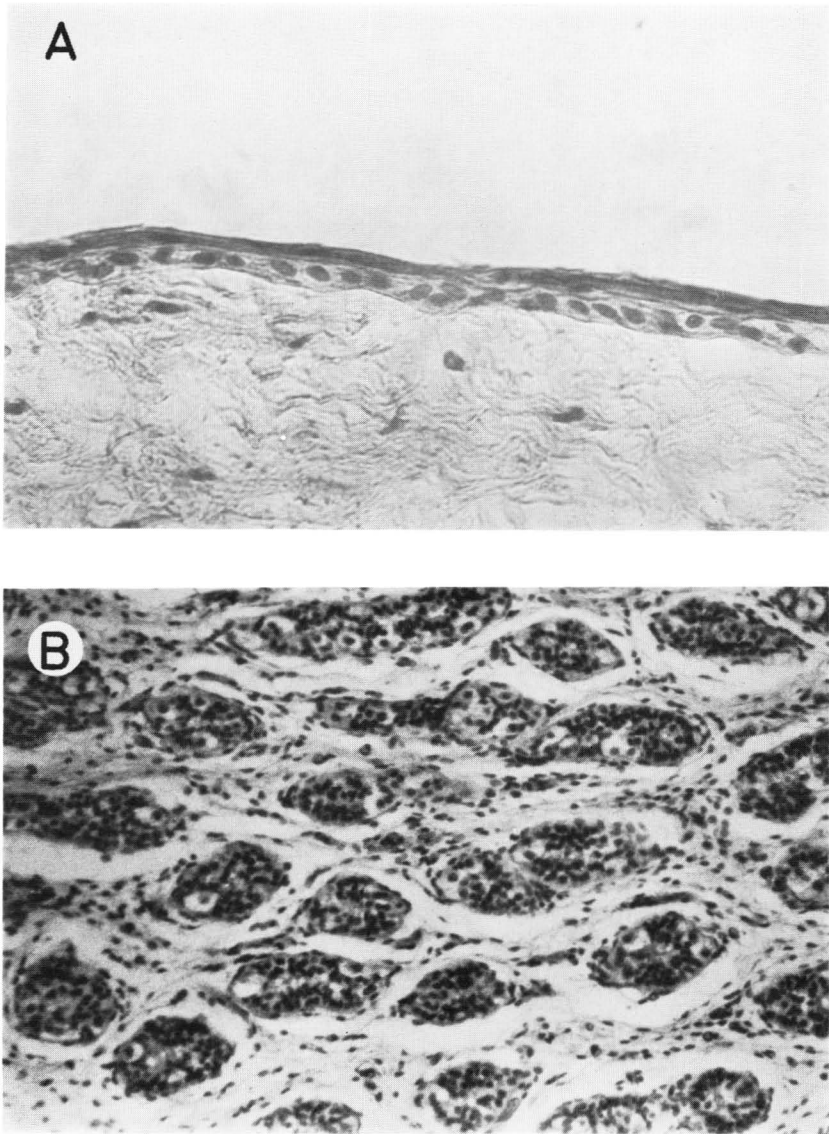


Fig. 3. High power microphotography
A, Microphotography (H & E, $\times 400$) showed that the inner layer of the cyst was covered with a single layer of flattened cuboidal epithelium and the outer layer eosinophilic connective tissue which separated the cyst from the parenchyma.
B, Microphotography (H & E, $\times 200$) showed that the seminiferous tubuli had developed normally as in males of this age where there is no infectious change.

fore, this may suggest the possibility of other causes which block the passage of the seminiferous tubuli to produce this lesion as the patient gets older.

The most important problem is clinical management. All six patients unfortunately underwent an orchiectomy in spite of this benign cystic disease. We propose a conservative operation on if one of the following findings which most likely suggest a benign cystic disease is present. They are as follows;

1) There is cystic appearance on the testis.

2) There is no contour of the tumor with transillumination.

4) The enlarged testis is palpable as a cyst.

In the procedure, simple resection of the cyst should be performed first and the resected tissue should be immediately examined pathologically. And then, even if the testis contained malignant neoplasm, an orchiectomy can be easily performed.

REFERENCES

- 1) Price, E. B., Jr.: Epidermoid cysts of the testis: A clinical and pathologic analysis of 69 cases from the testicular registry. *J. Urol.*, **102**: 708, 1969.
- 2) Ewing, J.: Teratoma testis and its derivatives. *Surg. Gynec & Obst.*, **12**: 230, 1911.
- 3) Schmidt, S. S.: Congenital simple cyst of the testis: A hitherto undescribed lesion. *J. Urol.*, **96**: 236, 1966.
- 4) Sasaki, S. and Nishio, A.: Congenital simple cyst of the testis: Report of a case. *Jap. J. Clin. Urol.*, **25**: 65, 1971.
- 5) Ishibashi, A., Hirata, N. and Mashimo, S.: Simple cyst of the testis: Report of a case. *Acta Urol. Jap.*, **19**: 607, 1973.
- 6) Tosi, E. S. and Richardson, R. J., Jr.: Simple cyst of the testis: Case report and review of the literature. *J. Urol.*, **114**: 473, 1975.
- 7) Takihara, H. and Tokuhara, M.: Simple cyst of the testis: Report of a case. *Nishinohon J. Urol.*, **40**: 65, 1978.

(Accepted for publication August 27, 1978)

和文抄録

Simple cyst of the Testis の 1 例

兵庫県立西宮病院・泌尿器科

市 川 靖 二
井 原 英 有
永 野 俊 介

左睾丸腫瘍を訴え来院した1歳1カ月の小児に、
睾丸腫瘍を疑い左除睾丸術を施行したが、病理学的に
simple cyst of the testis と診断された。本症は、現

在まで5例の報告を見るのみである。これら文献と自
験例をもとに、本症の特徴と治療法について若干の考
察を行なった。