

Title	ACUTE BILATERAL RENAL CORTICAL NECROSIS ASSOCIATED WITH ABRUPTIO PLACENTAE
Author(s)	Itatani, Hiroaki; Iguchi, Masanori; Koide, Takuo; Usami, Michiyuki; Mizutani, Shutaro; Kurita, Takashi
Citation	泌尿器科紀要 (1975), 21(3): 195-198
Issue Date	1975-03
URL	<a href="http://hdl.handle.net/2433/121799">http://hdl.handle.net/2433/121799</a>
Right	
Type	Departmental Bulletin Paper
Textversion	publisher

# ACUTE BILATERAL RENAL CORTICAL NECROSIS ASSOCIATED WITH ABRUPTIO PLACENTAE

Hiroaki ITATANI, Masanori IGUCHI, Takuo KOIDE,  
Michiyuki USAMI and Shūtarō MIZUTANI

*From the Department of Urology, Osaka University Hospital  
(Director: Prof. T. Sonoda, M. D.)*

Takashi KURITA

*From the Department of Urology, Kinki University Hospital  
(Director: Prof. T. Kurita, M. D.)*

## *Introduction*

Bilateral renal cortical necrosis is one of the rare and catastrophic diseases causing acute renal failure and occurring mainly after abruptio placentae, sepsis, trauma, burn or operation. The pathogenesis of this clinical entity has been obscure until it has become to be evident that disseminated intravascular coagulation (DIC) manifests coagulation disorders and intravascular fibrin thrombi which cause renal cortical necrosis with some other factors due to embolic interlobular arteries.

We presented a case of bilateral renal cortical necrosis resulting acute renal failure associated with abruptio placentae, of which diagnosis was made histologically at the time of renal transplantation 6 months later from the onset and commented on the etiology, diagnosis and treatment.

## *Case Report*

Case 1. U.Y., 39-year-old Japanese, primipara, was hospitalized in emergency to the Gynecology and Obstetrics Department for abnormal genital bleeding at the third trimester. She had been pointed out mild hypertension (150/90) since the first trimester when she was first seen in this clinic. A consultation to hypertension clinic had been made for evaluation to maintain

her pregnancy with laboratory results: RBC  $377 \times 10^4/\text{mm}^3$ , WBC  $7,200/\text{mm}^3$ , Hct 36% and PSP 34% at 15 min. Therefore decision had been made to maintain the pregnancy at that time. However, at the third trimester the blood pressure was elevated over 200 mmHg with occasional vomitings so that antihypertensive medications were administered with normal limits of laboratory data: BUN 6 mg/dl, creatinine 0.8 mg/dl, Na 138 mEq/L, K 4.1 mEq/L and Cl 103 mEq/L.

After she was admitted under the diagnosis of abruptio placentae emergency cesarean section was performed. The uterus appeared to be darkish red, especially from the cervix to the fundus and numerous petechiae with dead fetus unfortunately. It seemed to be evident of coagulation disorders at this time. Total blood loss was estimated to be 1,000 ml replaced 800 ml of whole blood without marked hypotension episode through all this procedure. However, except for only 25 ml of urinary volume in preoperative catheterization there was no further urinary output despite of Furosemide or Mannitol administrations. The patient was referred to Urological Department for further evaluation and possible hemodialysis therapy as acute renal failure.

Retrograde pyeloureterography was per-

formed showing normal size of kidney and normal appearance of ureter and pelvicaliceal system. Renal needle biopsy was attempted but in failure. Laboratory findings were as follows: BUN 135 mg/dl, creatinine 10.5 mg/dl, Na 128 mEq/L, Cl 97 mEq/L, K 5.4 mEq/L, RBC  $263 \times 10^4/\text{mm}^3$ , WBC  $47,300/\text{mm}^3$ . Platelet counts and fibrinogen level were significantly decreased to  $6.6 \times 10^4/\text{mm}^3$  and 31 mg/dl with markedly elevated FDP of 128  $\gamma/\text{ml}$ , respectively. Other coagulation systems such as PTT 29 second, prothrombin 80% or fibrinolysis (-) were in normal range.

Despite of hemodialysis the complete anuria had continued until discharge as a chronic hemodialysis patient on 50th postoperative day. The patient has received hemodialysis 3 times a week in local hemodialysis center during 6 months. Patient was readmitted for renal transplantation with bilateral nephrectomy. Postoperative course was uneventful in good renal function and patient has been followed as outpatient with normal renal function.

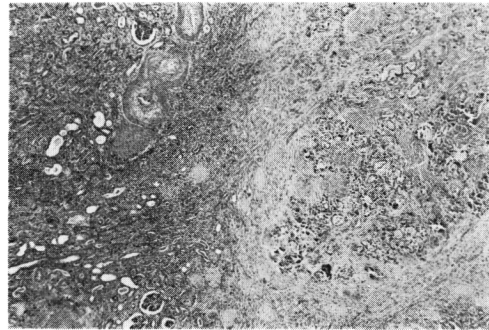
Renal angiography performed preoperatively because of doubtful cause for this acute renal failure demonstrated that renal size was markedly decreased, main renal artery and interlobular arteries were patent and interlobular arteries were almost not

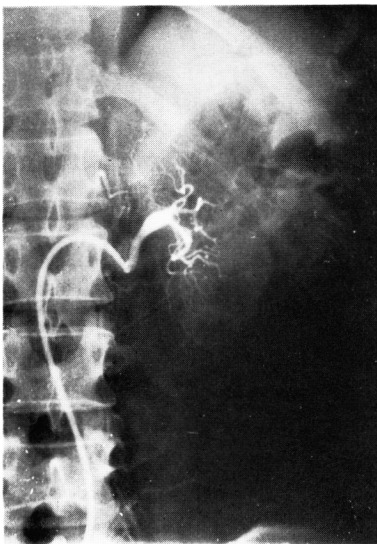

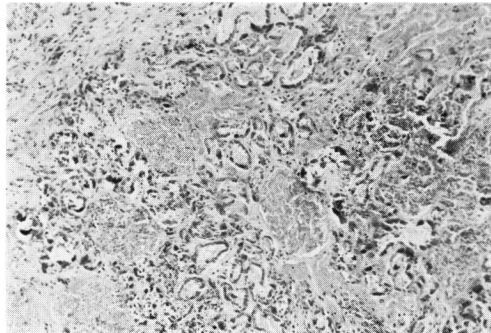
Fig. 1. Renal selective angiography before renal transplantation.

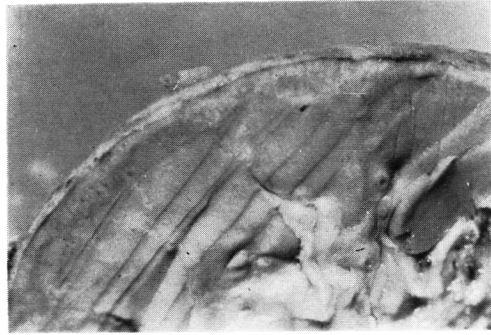

Fig. 2. Macroscopic findings of the removed original kidney. Cut surface shows marked atrophy of the renal cortex.



(a) Corticomedullary portion ( $\times 40$  H.E.)



(b) necrotic glomeruli ( $\times 100$  H.E.)

Fig. 3. Characteristic microscopic findings of renal cortical necrosis, namely necrotic renal cortex and obstructed interlobular arteries with non-involved medullary portion.

visualized probably due to embolization. The filling of the capsular arteries was, however, prominent (Fig. 1).

Macroscopic findings of the removed kidney were interesting. It was small and had slightly irregular surface and very thin or atrophic renal cortex with almost normal medulla in cut surface. Microscopic find-

Table 1

DIAGNOSTIC SIGNIFICANCE OF D.I.C.

- 1 PLATELET COUNT  $< 10 \times 10^4$
- 2 PLASMA FIBRINOGEN LEVEL ↓
- 3 P.T.T. : PROLONGED
- 4 PROTHROMBIN LEVEL  $< 60\%$
- 5 THROMBIN TIME : PROLONGED
- 6 NORMAL EUGLOBIN LYSIS TIME
- 7 RED BLOOD CELL FRAGMENTATION

by Conte et al. 1)

Comment

Since first description of bilateral renal cortical necrosis in 1886 four hundreds cases have been reported in literatures including only 24 cases of survival whose renal function recovered only less than 20 % during one or two years follow-up<sup>6)</sup>. Also the frequency of bilateral cortical necrosis causing acute renal failure was less than 2%<sup>5)</sup>. These aspects, namely mortality, recovery rate and frequency, are different from other forms of acute renal failure such as acute tubular necrosis.

In pathogenesis of this disease it had been obscure until it became to be evident that disseminated intravascular coagulation (DIC) resulted in fibrin thrombi of arterioles which caused obstruction of renal interlobular arteries coinciding with coagulation disorders such as decreased fibrinogens, platelet counts, elevated FDP (fibrinogen degradation products) particularly emphasized or prolonged PTT etc. as shown in Table 1<sup>1)</sup>. The presented case who had a history of hypertension probably have had nephrosclerosis which could increase the tendency of renal cortical necrosis secondarily to abruptio placentae (Table 2<sup>1)</sup>).

The definite diagnosis of bilateral renal cortical necrosis in early phase associated with DIC is difficult because of complicated clinical symptoms that were arisen from multiple fibrin thrombi of the many organs shown in Table 3<sup>7)</sup>. Clinically, however, it might be possible to make this diagnosis when coagulation disorders and acute renal failure occur at the same time with prolonged anuric phase or no diuretic phase characterized by no significant functional recovery even if enough urinary volume could be obtained.

Also renal angiographic findings such as non-visualized or reduced numbers of interlobular arteries in contrast with prominent filling of capsular arteries are helpful in diagnosis as demonstrated experimentally in renal cortical necrosis of animals<sup>2,4)</sup>. Although renal biopsy has been considered to be the only available diagnostic procedure in the early acute phase of cortical necrosis this may miss the diag-

Table 2. Late in pregnancy there are increased levels of certain coagulation elements and a repressed fibrinolytic mechanism. Associated with increasing age or hypertension is a relatively advanced degree of nephrosclerosis. These factors serve as the substrate for a trigger mechanism or procoagulant factor.

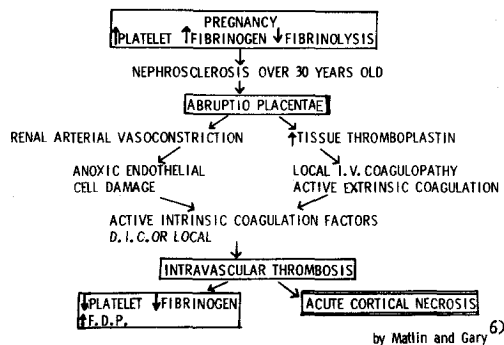


Table 3

DISTRIBUTION OF FIBRIN THROMBI DUE TO D.I.C.

100 %	LUNG
> 50 %	PANCREAS SPLEEN ADRENAL GLAND LIVER GASTROINTESTINAL TRACT
< 50 %	KIDNEY MYOCARDIUM BRAIN

by Conte et al. 1)

ings also demonstrated characteristic renal cortical necrosis with contained completely necrotic glomeruli and thickened or obstructed interlobular arteries in contrast to the well preserved medullary portion (Fig. 2, 3).

nosis<sup>3)</sup>. Furthermore, the lesions of necrotic nature, such as localized or total infarction of renal cortex, can hardly be differentiated by renal biopsy as such variable lesions may occur in cases of cortical necrosis without acute renal failure like patchy or focal lesions<sup>2)</sup>.

Although the clinical manifestations are progressive and ultimately reach irreversible renal failure, early use of heparin which causes cessation of fibrin and platelet deposition can avert the irreversible or thrombotic phase. However, this is probably of no value since the onset is so abrupt and the lesion is not slowly progressive. Furthermore the thromboses are in predominantly larger vessels and not in the microcirculation<sup>6)</sup>. Therefore the management of acute renal cortical necrosis associated with DIC should be performed with dialytic technics as having been documented twenty-one of the 24 patients with acute cortical necrosis known to be alive.

We presented a case of acute bilateral renal cortical necrosis associated with DIC and commented on its etiology, diagnosis

and treatment.

### References

- 1) Hamburger, J., Crosnier, J. and Maxwell, M. H.: *Advances in Nephrology*. Vol. 3, p. 197. Year Book Medical Publishers Inc., Chicago, 1974.
- 2) Deutsch, V., Frankl, O., Drory, Y., Eliahou, H. and Braf, Z. F.: Bilateral Renal Cortical Necrosis with Survival through the Acute Phase with a Note on the Value of Selective Nephroangiography. *Amer. J. Med.*, **50**: 828, 1971.
- 3) Wells, J. D., Margolin, G. and Gall, E. A.: Renal Cortical Necrosis. *Amer. J. Med.*, **29**: 257, 1960.
- 4) Schneider, B., Rosenheim, S. and Margarete, W.: Renal Angiography in the Generalized Schwartzman Reaction. *Invest. Radiol.*, **3**: 23, 1968.
- 5) Black, D.: *Renal Disease*, 3rd edit., p. 432, Blackwell Scientific Publications, London, 1972.
- 6) Matlin, R. A. and Gary, N. E.: Acute Cortical Necrosis: Case Report and Review of the Literature. *Amer. J. Med.*, **56**: 110, 1974.
- 7) Clinicopathologic Conference: Disseminated Intravascular Coagulation. *Amer. J. Med.*, **55** (6): 819, 1973.

(Accepted November 12, 1974)

### 抄 録

#### 胎盤早期剝離後に発生した急性両側性腎皮質壊死

大阪大学医学部泌尿器科学教室 (主任: 園田孝夫教授)

板谷 宏 彬, 井口 正 典, 小出 卓 生  
宇佐美 道 之, 水谷 修 太郎

近畿大学医学部泌尿器科学教室 (主任: 栗田孝教授)

栗 田 孝

急性腎不全をきたす疾患のうち、両側性腎皮質壊死は、妊娠後期における胎盤早期剝離、敗血症、外傷、および術後などに発生するまれ、かつきわめて予後不良な疾患である。1886年に最初の報告をみて以来、現在まで約400例の報告をみるが、生存しえたのは24例で、しかもそのほとんどが血液透析をうけたここ数年間の患者である。またその腎機能回復率は20%以下ときわめて不良である。

急性両側性腎皮質壊死の発生機序に関しては不明な点が多いが、その腎組織学的検索ではフィブリン析出による腎小葉間動脈の栓塞がおもにみられ、腎皮質の広

範な壊死を認める反面、腎髄質はほとんど正常に保たれている。同時に臨床的には出血傾向と全身臓器の小動脈の栓塞を認め、DIC (disseminated intravascular coagulation) との関連性が重要視されている。

今回、われわれは39歳の高齢初産婦にみられた胎盤早期剝離後、急性腎不全をきたし、6カ月間の血液透析ののち、同種腎移植を施行され成功したが、その際えられた腎組織は両側性腎皮質壊死と診断された症例を経験したのでその臨床経過を報告するとともに、急性両側性腎皮質壊死の発生機序、診断、予後などにつき考察を加えた。