

Title	Establishment of a cell line (TSUS-1) derived from a human squamous cell carcinoma of the penis
Author(s)	Ishikawa, Satoru; Kanoh, Shohri; Nemoto, Shinichi
Citation	泌尿器科紀要 (1983), 29(4): 373-376
Issue Date	1983-04
URL	http://hdl.handle.net/2433/120158
Right	
Type	Departmental Bulletin Paper
Textversion	publisher

ESTABLISHMENT OF A CELL LINE (TSUS-1) DERIVED FROM A HUMAN SQUAMOUS CELL CARCINOMA OF THE PENIS

Satoru ISHIKAWA, Shohri KANO and Shinichi NEMOTO

From the Department of Urology, Institute of Clinical Medicine, University of Tsukuba

(Director: Prof. K. Koiso)

We established a cell line (TSUS-1) derived from a relatively well-differentiated squamous cell carcinoma of the penis. The cells had been subcultured 60 times during two years and five months. The average doubling time of this cell line was 38 hours. Chromosomal analysis indicated that the modal chromosome number was 75; seven marker chromosomes and a male karyotype were present. The cultured cells were easily transplantable into BALB/c nude mice and the histological picture of the inoculated tumor was similar to that of the original tumor.

Key words: Human squamous cell carcinoma of the penis, Cell line (TSUS-1)

INTRODUCTION

Some papers have reported the establishment of permanent cell lines from human squamous cell carcinoma^{1,2)}, but not yet a cell line from a carcinoma of the penis. This paper deals with the establishment and preliminary characterization of a cell line referred to as TSUS-1, derived from a human squamous cell carcinoma of the penis.

MATERIALS AND METHODS

A 37-year-old Japanese male patient noticed induration and ulcer of the penis in January 1979. Under the diagnosis of squamous cell carcinoma of the penis without distant metastasis, amputation of the penis and bilateral inguinal lymph-nodes dissection were performed in August, 1979. In March, 1980, he was admitted to our University Hospital because of pulmonary and vertebral metastases. Massive pericardial effusion was detected. Tumor cells were obtained from pericardial fluid on March 21, 1980. At autopsy multiple hematogenous metastases were seen in the

lung, heart, liver, lumbar vertebrae, ribs and pancreas. Pleuritis carcinomatosa and pericarditis carcinomatosa were also seen. Histological diagnosis was relatively well-differentiated squamous cell carcinoma with occasional pearl formation. Rapid downhill clinical course and hematogenous metastatic spread in this case were compatible with that of the fulminating character of the metastatic penile cancer described by Ormond in 1940³⁾.

After centrifugation of the sample, the packed cells were resuspended in DM-160 medium (Kyokutoh. Co. Tokyo) supplemented with 20% fetal calf serum (GIBCO, N. Y.) without any antibiotics. All cultures were maintained at 37°C in a humidified atmosphere of 5% CO₂ in air. The medium was changed every week.

RESULTS AND DISCUSSION

The first subcultures were made by scraping the bottle with a rubber policeman on the 43rd day. Then second subcultures were made on the 73rd day after cultivation. Thereafter, the cells were successively transferred every 2 weeks. During these

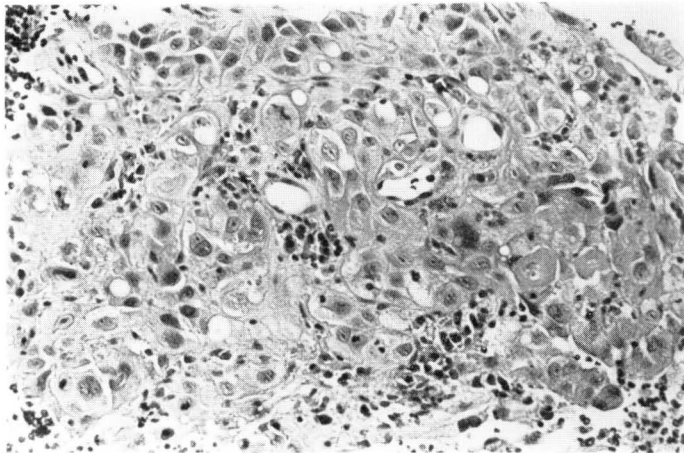


Fig. 1. Histology of the primary carcinoma of the penis, showing relatively well-differentiated squamous cell carcinoma. Hematoxylin-Eosin stain. $\times 300$

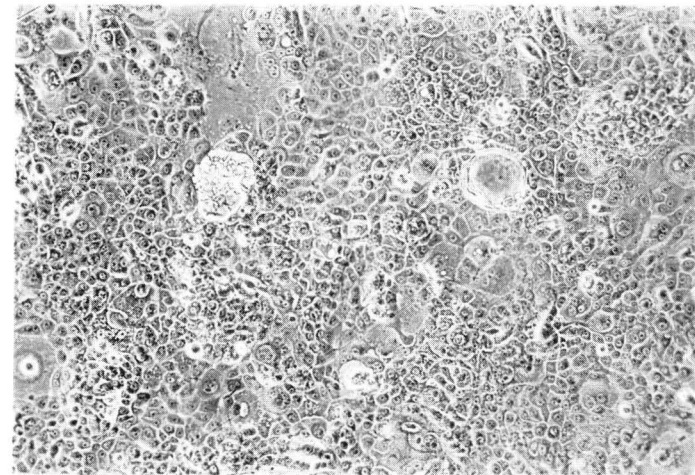


Fig. 2. Morphological features of the cultured TSUS-1 cells. Most of the cells were polygonal, slightly spindle-shaped and irregular in size. Phase-contrast microscopy. $\times 200$

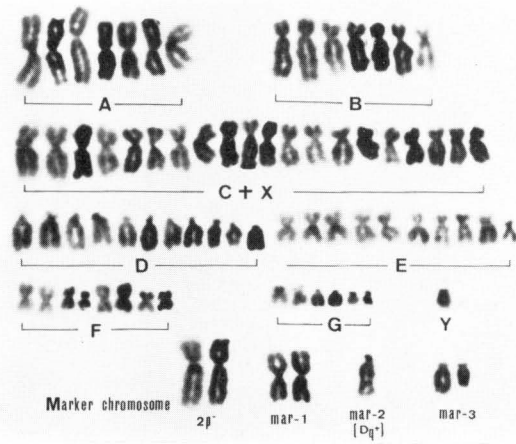


Fig. 4. Karyotype of TSUS-1 cells

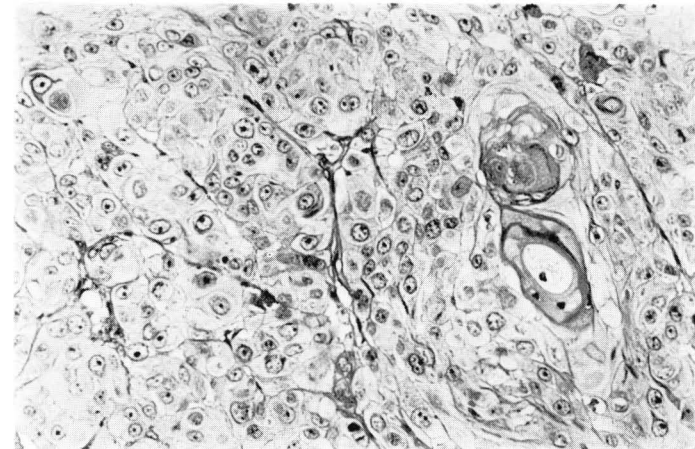


Fig. 5. Histology of the tumor of TSUS-1 cells grown on the flank of a nude mouse. Hematoxylin-Eosin stain. $\times 300$

serial subcultures, the intermingling fibroblasts gradually decreased in number and finally disappeared. At the time we submitted this paper, the cells had been subcultured to passage 60. Initially, the cells grew on the surface of the culture flask, then they piled up and proliferated freely. Most of the cells were polygonal, slightly spindle-shaped and irregular in size. Nuclei were large, bizarre and pleomorphic in shape with prominent nucleoli. Mono- or multi-nucleated giant cells were scattered through the culture (Fig. 2). The average doubling time of this cell line was 38 hours, when calculated from the growth curve of the cancer cells at the 40th passage.

Chromosomal analysis with conventional Giemsa staining indicated that the modal chromosome number was 75, with a range of 60 to 80 (Fig. 3). Seven marker chro-

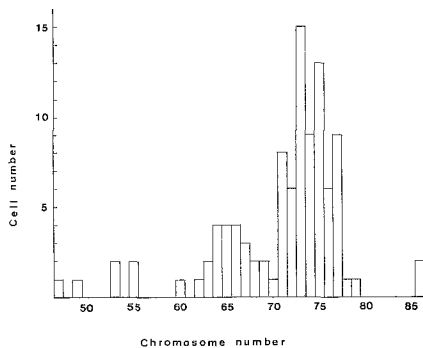


Fig. 3. Distribution of chromosome number of cultured TSUS-1 cells

mosome and a male karyotype were present (Fig. 4). The cell suspension containing 5×10^6 cells (43rd passage) in 0.2 to 0.3 ml of medium was inoculated into the subcutis on the flank of BALB/c nude

mice. Nodules were produced in all animals by 7 to 14 days after the transplation and grew to a size of 200 to 2000 cu mm by 3 to 4 weeks. This tumor was easily transplantable into other mice. The histological picture of the inoculated tumor was similar to that of the original tumor (Fig. 5).

Primary lesions of penile cancers are always contaminated with many kinds of bacteria, fungi, mycoplasmas and other microorganisms, so that it has been difficult to obtain an aseptic specimen for the establishment epithelial cell lines. Fortunately, we were able to obtain carcinoma cells from the pericardial fluid without contamination to isolate a cell line. The characteristics of this cell line are its marker chromosomes and the fact that it can be transferred easily by pipetting alone. The differences of biological characteristics between TSUS-1 and other lines from the genitourinary system, remain to be investigated in detail.

ACKNOWLEDGMENTS

We thank Dr. Harada, First Department of Pathology, Teikyo University, for valuable advice during the pathological study, Dr. R. Nemoto for his encouragement and suggestions, and Miss Arayama for her technical assistance.

REFERENCES

- 1) Nishihira T et al: *Gann* **70**: 575~584, 1979
- 2) Okabe T et al: *Cancer Res* **33**: 3910 ~3917, 1978
- 3) Yazaki T et al: *Jap J Clin Urology* **35**: 79 ~82, 1981

(Accepted for publication, December 8, 1982)

和文抄録

ヒト陰茎扁平上皮癌培養細胞株 TSUS-1 の樹立とその性状

筑波大学臨床医学系泌尿器科 (主任: 小磯謙吉教授)

石	川	悟
加	納	勝
根	本	真

われわれは37歳男性の電撃型陰茎癌患者の転移の認められた心嚢液よりヒト陰茎扁平上皮癌培養細胞株 TSUS-1 を樹立した。継代培養は60代におよび2年5カ月を経過した現在なお増殖を続けており、ヌードマウス皮下移植率は100%であった。継代培養40代の染色体分析でモード75の低四倍体であり、マーカー染

色体が7個認められた。ヌードマウス移植腫瘍は皮膚に浸潤し、角化傾向も著明で、原発巣の陰茎癌類似の肉眼的所見を示し、組織学的には癌真珠を含む角化傾向が散見される扁平上皮癌であり、原発陰茎癌に類似していた。