

Title	Adenomatoid tumor: report of two cases and some considerations
Author(s)	Kubo, Yasunori; Murata, Shohei
Citation	泌尿器科紀要 (1969), 15(11): 800-811
Issue Date	1969-11
URL	<a href="http://hdl.handle.net/2433/120064">http://hdl.handle.net/2433/120064</a>
Right	
Type	Departmental Bulletin Paper
Textversion	publisher

## ADENOMATOID TUMOR : REPORT OF TWO CASES AND SOME CONSIDERATIONS

Yasunori KUBO and Shohei MURATA

*From the Department of Urology, Kyoto Prefectural University of Medicine*

Among the tumors arising from the testicular appendage, a benign tumor which is classified under the name of "adenomatoid tumor" is present. This benign tumor is characteristically different from ordinary benign and malignant tumors.

Concerning the mother tissue from which this adenomatoid tumor arises, many theories have been advocated on the endothelial, epithelial and mesothelial origin but no one theory has been universally accepted. This appears to be the reason why Golden-Ash<sup>15)</sup> adopted such a vague descriptive term as "adenomatoid tumor".

In Japan, Harada<sup>19)</sup> was the first to use the name "adenomatoid tumor" in 1950 and 16 cases have been reported so far. With the addition of three cases reported by Sakaguchi (1917)<sup>43)</sup>, Nakamura (1942)<sup>89)</sup>, and Noma (1949)<sup>89)</sup> probably representing the same disease, a total of 19 cases is obtained.

We have recently experienced 2 cases of this disease and conducted histological and histochemical studies. The results of these studies with a review of the literature are reported in this paper.

### CASES

#### Case 1

Patient : K. M. 36-year-old male.

Initial examination : September 15, 1964.

Chief complaint : Tumor in the left scro-

tum and dull pain in the testicular area.

Family history : Non-contributory.

Previous history : At the age 24 years, the patient had pulmonary tuberculosis. The patient has no children after 10 years marriage.

History of the present illness : For approximately past one year, a small-finger tip sized painless tumor was palpated in the upper pole of the left testicle. The patient then complained of dull pain in the left lower abdomen and testicular area. He had received no particular treatment on these complaints. While he was admitted to the department of internal medicine because of acute hepatitis, he was thereby referred to the department of urology.

Local findings : The right testicle, epididymis, and vas deferens were all normal. No abnormality was noted in the left testicle. A small-finger tip sized, spherical, elastic firm tumor was palpated to be tightly attached to the head of epididymis. No tenderness was encountered.

From the above clinical findings, a diagnosis of left chronic epididymitis was made and a left epididymectomy was carried out since tuberculosis was suspected.

Operative findings : About 1/4 of the lower surface of the tumor was attached to the head of the epididymis and adjacent to the visceral surface of the tunica vaginalis, while a larger part of the remaining por-

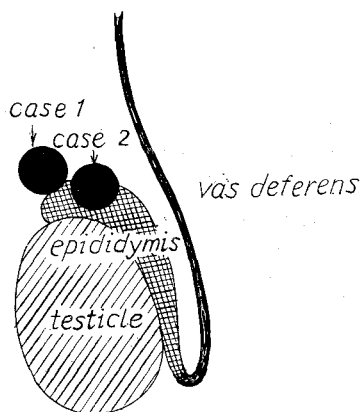


Fig. 1 Site of the tumors in our own cases.

tion appeared to be buried in the spermatic cord (Fig. 1). Although the attachment of the tumor to the epididymis was rather tight, that to the spermatic cord was rather loose and readily separated. The tumor was therefore removed along with epididymis.

**Gross findings:** The resected tumor measured approximately 8 mm in its diameter and the shape was spherical. The tumor was elastic firm, appearing yellowish white in color, while the cut surface was smooth and gray-white, giving the appearance of a fibroma. The tumor was covered by a fibrous capsule and was easily distinguishable from the epididymis (Fig. 2, 3).

**Histological findings:** Large light-colored cells resembling epithelial cells gave a gland-like appearance forming many glandular lumens (Fig. 4, 5). There were also cells with vacuoles scattered within the cytoplasm. A relatively abundant fibrous interstitium was present.

**Histochemical findings:** Pap, Sudan, mucicarmine, and PAS stains, and glycogen and acid mucopolysaccharide were studied. In the Pap stain, the reticular fibers were relatively coarse (Fig. 6). Staining for fat was negative in the Sudan stain. Bestcarmine staining revealed negative mucin.

PAS was negative except in the interstitium and part of the vacuoles. No glycogen was noted. Alcian blue staining demonstrated the presence of acid mucopolysaccharide as  $\beta$ -metachromasia in the vacuoles at various sites and in the glandular lumen (Fig. 7).

#### Case 2

**Patient:** S. K. 31-year-old male.

**Initial examination:** Jan. 23, 1967.

**Chief complaint:** Dull pain in the right scrotal area.

**Family history:** Non-contributory. One child.

**Previous history:** At the age of 16, the patient had pleurisy. Two years ago an appendectomy was performed.

**History of the present illness:** For 2 to 3 days the patient had pain in the right testicular area and also dull pain in the lumbar region. His home doctor examined him and referred him to us under the suspicion of epididymitis.

**Local findings:** The left testicle, epididymis, and deferent duct were all normal. No abnormality was noted in the right testicle. At the head of the right epididymis, a small-finger tip sized spherical firm tumor was palpable with marked tenderness.

Based on these clinical findings, a right epididymectomy was performed under the suspicion of right tuberculous epididymitis.

**Operative findings:** No abnormality was seen in the right testicle and tunica vaginalis. At the head of left epididymis a spherical and small-finger tip sized induration was noted (Fig. 1). The epididymis was completely free of adhesions to the surrounding tissues and dissection was readily accomplished. Resection was carried out including the healthy body and tail of the epididymis.

**Gross findings:** The resected tumor was

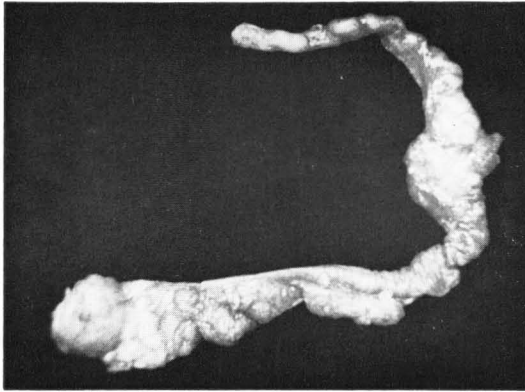


Fig. 2 Case 1: tumor and epididymis.

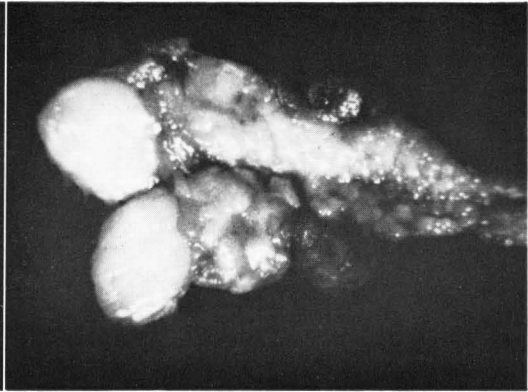


Fig. 3 Case 1: cut surface of the tumor.

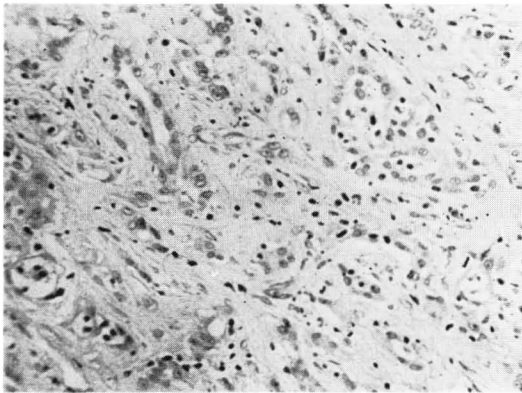


Fig. 4 H. E. by low power.

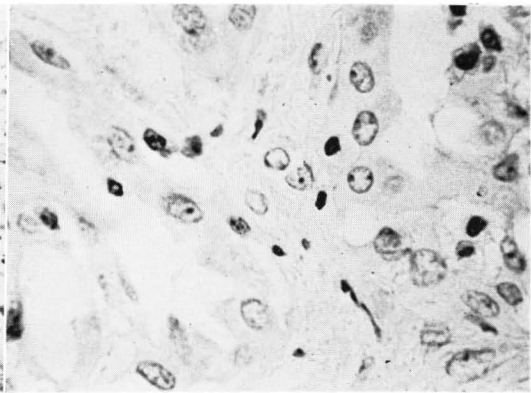


Fig. 5 H. E. by high power.



Fig. 6 Pap stain.

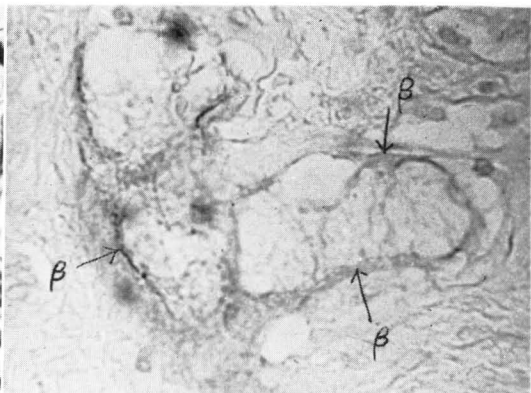


Fig. 7  $\beta$ -metachromasia ( $\beta$ ) by alcian blue stain.

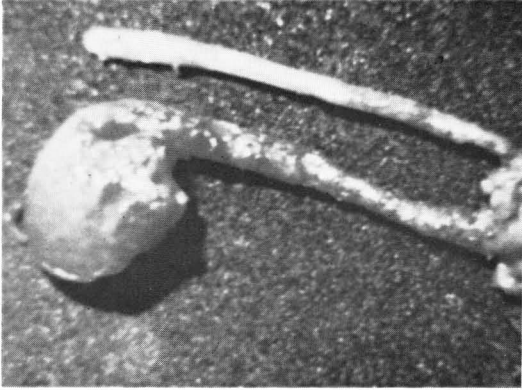


Fig. 8 Case 2: tumor and epididymis.

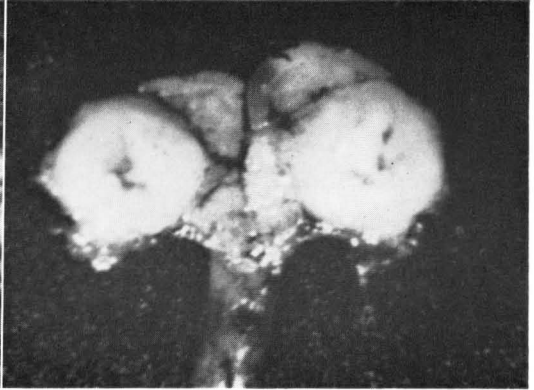


Fig. 9 Case 2: cut surface of the tumor.

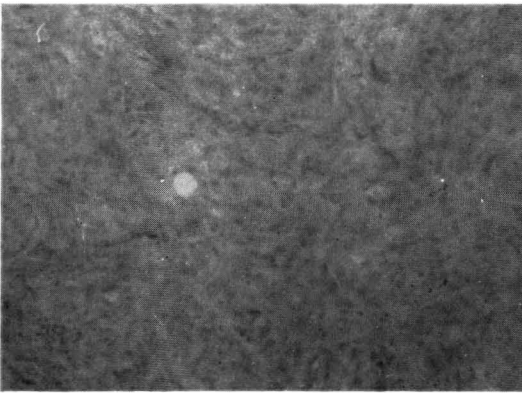


Fig. 10 H.E. by low power.

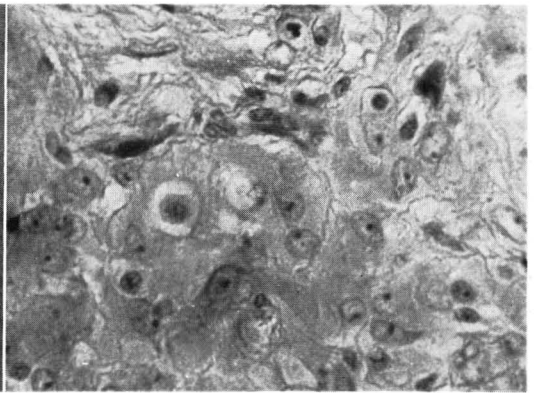


Fig. 11 H.E. by high power.

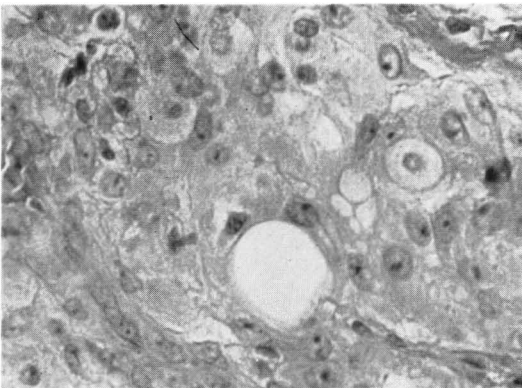


Fig. 12 H.E. by high power.

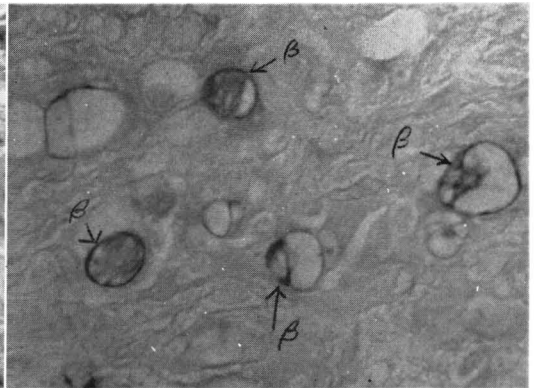


Fig. 13  $\beta$ -metachromasia ( $\beta$ ) by alcian blue stain.

almost spherical with a diameter of approximately 10 mm. The consistency resembled that of cartilage, the color was yellowish white, and the cut surface was smooth and gray-white with a slightly yellow-brown central portion. The general appearance resembled a fibroma, covered by a fibrous capsule and was distinguishable from the epididymal tissue (Fig. 8, 9).

Such macroscopic findings gave rise to the suspicion of the so-called "adenomatoid tumor", so that histological and histochemical studies were conducted.

**Histological findings:** The tumor consisted of a collection of rather light epithelium-like cells giving a cord-like or small honeycomb-like appearance. Vacuole formation was noted in cells at various sites but no adenomatous structure was present (Fig. 10, 11, 12). Although the stroma was scanty, the tumor was definitely distinguishable from the epididymal tissue because of the fibrous capsule. While the epididymal tissue was normal, in the area between the tumor and the testicle an increased amount of the stroma was noted. The tubular lumen was atrophied. On the visceral surface of the tunica vaginalis, a marked thickening of the fibrous capsule was noted. Part of this thickened area contained tumor tissue.

**Histochemical findings:** A Pap stain revealed rather poor reticular fiber formation and the PAS stain was mildly positive in the interstitium. Some of the vacuoles contained positive PAS material. This material appeared to be  $\beta$ -metachromasia in the alcian blue stain, probably representing acid mucopolysaccharide (Fig. 13). Mucin, glycogen and fat stains were negative.

## DISCUSSION

Adenomatoid tumor of the testicular appendage has been considered to be a considerably rare disease until recently. In Japan, before Harada's report, only 3 cases were reported; namely adenomyoma by Sakaguchi<sup>43)</sup>, and lymphangioma by Nakamura<sup>38)</sup> and Noma<sup>39)</sup>.

However, after two additional reports by Minami<sup>34)</sup>, many cases have been reported. By 1967, more than 20 cases were reported as shown in Table 1. This is probably not due to a sudden increase of this disease, but rather due to an increased interest in this disease.

The speed of development of this disease is rather slow and most of the patients are free of subjective complaints. No malignancy has been associated with this tumor. The age of the most frequent occurrence is between 20-40 years, and patients at this age are rather preoccupied with their livelihood. Due to these reasons, the tumor is usually detected incidentally. Even if a tumor is found, it is frequently left untreated as chronic or tuberculous epididymitis, or post-inflammatory induration. Even upon extirpation, histological examination is frequently neglected so that the tumor escapes proper attention and identification.

According to the report of Imamura<sup>24)</sup>, collecting and classifying 55 cases of epididymal tumors in Japan, 17 of 33 benign tumors were adenomatoid tumor. According to the series of 134 cases collected by Longo et al<sup>30)</sup>, 53 % of all epididymal tumor was adenomatoid tumors. The position that this disease holds among epididymal tumor thus appears to be rather important. As mentioned above, the most frequent occurrence is seen between 20-40 years of age. In the report of Burros et al<sup>5)</sup> an adeno-

Table 1. "Adenomatoid tumor" of the male sex organs in Japan (1917-1968).

No	Authors	Year	Age	Side	Site of tumor	Size of tumor (mm)	Diagnosis
1	Sakaguchi	1917	32	right	Head-body of ep.	20×15×23	adenomyoma
2	Nakamura	1942	37	„	„	23×15×7	lymphangioma
3	Noma	1949	37	„	tail of ep.	bean size	„
4	Harada	1950	38	left	head of ep.	pea size	adenomatoid tumor
5	Minami	1956	41	right	tail of ep.	10×8×7	„
6	„	„	29	„	„	25×18×15	„
7	Momose	1958	50	left	head of ep.	pea size	„
8	Hironaka	1959	20	„	„	small-finger tip size	„
9	Endo	1960	73	„	unknown	dacks egg size	adenomyo-fibroma
10	Sakatoku	1962	35	„	head of ep.	pea size	adenomatoid tumor
11	„	„	40	right	tail of ep.	12×8×8	„
12	Miki	„	30	left	„	6.5×4.5×4	„
13	Sakazume	1963	33	right	head of ep.	9×7×7	„
14	Sonoda	„	39	left	tail of ep.	pea size	„
15	Sakurane	„	48	„	„	small-finger tip size	„
16	Tsuchida	1964	33	„	„	14×10×8	„
17	*Nonaka	„	45	right	under pole of testicle	9×7×6	benign mesothelioma
18	Imamura	1965	31	left	tail of ep.	thumd tip size	adenomatoid tumor
19	Hamada	„	18	„	„	10×12×9	„
20	Horigome	1966	57	right	„	15×15×15	„
21	Kubo	1969	36	left	head of ep.	8×8×8	„
22	„	„	31	right	„	10×10×10	„

(\* Nonaka's case is not "adenomatoid tumor")

matoid tumor in a new born is included. The disease in Japan ranged in age between 18 and 73 years, but 12 cases which represent the majority of the cases fall in the fourth decade.

Lee et al<sup>28)</sup> found 58 % of the tumors on the right and 42 % on the left, while Jackson<sup>26)</sup> found 56 % on the right and 44 % on the left, suggesting a slight right sided preponderance. The cases in Japan occurred on the right in 10 and on the left in 12, suggesting a slight left preponderance.

Although this tumor has generally been

reported as a tumor of the epididymis, determination of the site of occurrence is rather difficult since the mother tissue of this tumor is involved. Consequently, it is almost impossible to describe any one case as typical. The sites of occurrence described in the literature are as follows. According to Jackson<sup>26)</sup>, the tail portion of the epididymis is frequently affected. However, in 20 cases we collected from the literature and two cases of our own experience (one case was excluded due to insufficient description) 7 were found in the

portion of epididymis, from the head to the corpus in 2, and the tail portion in 11. No special preponderance of occurrence in the tail portion was detected. In another case reported by Nonaka<sup>40)</sup>, the lower pole of the testicle was affected, although it was described by the name "benign mesothelioma".

The tumor is generally small and the majority were smaller than the small-finger tip. According to Campbell<sup>6)</sup>, 2 to 5 cm is the ordinary size, whereas in Japan, Endo<sup>10)</sup> reported a case in which the goose egg-size tumor was smooth and firm, being clearly demarkated by a capsule from the surrounding tissue. One case of Sakatoku & Takahashi<sup>46)</sup> had a direct communication with the epididymis, according to histological finding.

The histological findings are characterized by gland-like structure consisting of endothelial or mesothelial elements.

Cells contain vacuoles of various size. Occasionally, these cells are arranged in a cord-like and sometimes a gland-like fashion, with various transitional types between. Although the interstitial tissue is said to be relatively abundant, collagen fibers and elastic fibers are rather scanty. This tumor has been classified histologically into 3 to 4 types. Sakatoku<sup>46)</sup> classified 4 types, from a solid cell cord type to an angiomatoid type as shown in Table 2. Prior to this, Golden-Ash<sup>15)</sup> and Lee et al.<sup>28)</sup> independently classified it into 3 types (Table 2). The cases

of our experience in the present report were classified according to these standards. The first case probably represents the transitional type between type 2 and 3 according to Golden-Ash, or type 3, tubular type according to Lee et al. and Sakatoku. Case 2 probably belongs to the intermediate type between type 1 and 2 according to Golden-Ash and Lee et al., and type 2 or the cell cord type with slight vacuolation according to Sakatoku.

Histochemical studies have long been conducted on the contents of the vacuoles. Sudan and mucicarmine staining have all been negative. Glycogen was negative. However, PAS positive vacuoles have been said to be present. According to Stavrides<sup>50)</sup> this substance is acid mucopolysaccharide in view of the  $\beta$ -metachromasia by alcian blue.

Cocerning the mother tissue of the adenomatoid tumor, Leighton<sup>29)</sup> proposed an endothelial origin and Naegeli<sup>42)</sup> did an Wolffian duct origin both in 1912. Various theories have thereafter been advocated. However, classification would give four theories of origin, as shown in Table 3.

Some adhere to the theory of Leighton et al based on the finding simulating lymphangioma, but few have supported this theory in recent years.

According to Naegeli and some authors, this disease is not a neoplasma since no blood or lymphatic elements are present in

Table 2. Histological classification of the "adenomatoid tumor".

Golden & Ash (1945)	Lee et al (1950)	Sakatoku & Takahashi (1962)
a) solid cord-like type .....	a) plexiform type .....	a) solid cell cord type b) cell cord with slight vacuolation .....
b) microfollicular type .....	b) tubular type	c) tubular type
c) macrofollicular type	c) canalicular type	d) angiomatoid type



Table 3. Histogenesis of the "adenomatoid tumor".

	Epithelial Origin	Mesonephritic Origin	Müllerian Epithelium Origin	Mesothelial Origin
1910	Leigton (1912)	Naegeli (1912)		
1920	Ringano (1925)			
1930	Marcandier (1930) Nicod (1934) Scalfi (1936) Charache (1939)			
1940	Halpert (1941) Malisoff (1943) Morehead (1946)	Blumer (1941) Gordon (1941) Codnere (1946) Falconer (1947) Ragins (1948)		Masson (1942) Evans (1943) Fajer (1949)
1950	Bolche (1952)	Longo (1951) Teilum (1954)	Leach (1950) Sandrasivarao (1953) Rankin (1953) Jackson (1958)	Ambrose (1953)
1960		Sakatoku (1962)	Flickinger (1960) Tsuchida (1964) Steger (1965)	Stavrides (1960) Nonaka (1964) Kubo (1969)?

Ringano, Marcandier, Nicod, Scalfi : cited by Jackson<sup>26)</sup>  
Naegeli : cited by Rankin<sup>42)</sup>

tissue while cells provided with fibrous tissue and smooth muscle fibers are found. Since the most frequent site of occurrence is in the area of the Wolffian duct, hamartoma of the mesonephros appears to be the most likely diagnosis according to Naegeli. Sakatoku & Takahashi<sup>46)</sup> in Japan, considers that this originates from the ductus efferentes based on the histological findings of their clinical case. From an embryological standpoint, the possibility of mesonephric origin is suggested.

In view of the epithelial structure seen in areas of the tumor tissue and the site of occurrence which is in agreement with the course of Müllerian duct, Sundrasivarao<sup>52)</sup> proposed the theory of Müllerian epithelium origin. This theory has been supported by Rankin<sup>42)</sup>, Jackson<sup>26)</sup>, Steger<sup>51)</sup> and Flickinger et al<sup>14)</sup>.

Evans et al<sup>11)</sup> on the other hand, pointed out the intimate relationship between the origin of this disease and the serosal surface of the tunica vaginalis, suggesting the possibility of mesothelial cell origin. He therefore gave the disease the name of mesothelioma. However, Golden & Ash<sup>15)</sup> opposed this theory and pointed out a considerable histological difference between this tumor and mesothelioma of other part of the body. While, in recent years, Stavrides<sup>50)</sup> has strongly supported the mesothelial origin theory in view of the histological demonstration of hyaluronic acid which is probably formed by the mesothelial cells in the vacuoles and the ability of mesotheliomas to differentiate into fibroblast or mesonephric structures.

In most of reports from Japan, the papers cite from the literature on pathogenesis of

this disease, but few discuss it based on their own experience. Only Sakatoku & Takahashi<sup>46)</sup> has proposed the theory of mesonephric origin from embryological standpoint of the tissue as they found a direct connection of the tumor with epididymal tissue in one case.

Nonaka<sup>40)</sup> reported a case of so-called "benign mesothelioma" in which the origin was probably the tunica alba. Tsuchida<sup>55)</sup> pointed out the epithelial structures and the absence of any relationship with the serosa, suggesting the possibility of Müllerian duct origin (Table 3).

Two of our own cases must be then discussed. All part of both tumors appeared to be of epididymal tissue origin and was clearly distinguishable from the epididymis both macroscopically and histologically, so that it is rather difficult to state that the origin was the ductuli efferentes. Especially in the 2nd case, the epididymal tissue adjacent to the tumor tended to undergo atrophy due to compression. However, any relationship with the serosa such as the tunica vaginalis was not clearly demonstrable. Histochemically, mucopolysaccharide probably representing hyaluronic acid as pointed out by Burnting<sup>4)</sup> was found in the vacuoles in addition to positive PAS stain and glycogen content in agreement with the theory of Stavrides<sup>50)</sup>. In view of the above findings, the mesothelial origin according to Evans<sup>11)</sup> and Stavrides appears to be probable. However, many questions still remain as to whether this may be identified as a "benign mesothelioma". Recently, Takahashi et al<sup>56)</sup> gave the diagnosis of benign mesothelioma to a tumor with multiple points of origin on the tunica vaginalis. According to this author, histological finding of this tumor is entirely different from the so-called adenomatoid tumor.

From the histochemical findings of our own cases which we think important, evidence affirming the mesothelial origin theory was obtained. However, we do not insist on the theory that the tumor occurs from the serosa. Mesothelial origin presenting as a hamartoma appears to be most probable. In view of the opinion of Stavrides<sup>50)</sup> that "mesothelium has the ability to differentiate into mesonephric structures", the hamartoma theory of Naegeli<sup>42)</sup> might be understood without limiting the mother tissue to the mesonephros. From such a viewpoint, as Golden & Ash<sup>15)</sup> pointed out, it would be quite possible that an adenomatoid tumor presents histological findings entirely different from those of mesotheliomas occurring in other site. The absence of universal opinion on the origin of this disease might be due to the fact that "adenomatoid tumor" and "benign mesothelioma" have been treated as if they were the same disease. In order to clear such confusion, we consider that a "benign mesothelioma" developing in the tunica vaginalis is different from an adenomatoid tumor. We then suppose the presence of two types among the adenomatoid tumors, that is, some developed from the mesonephric tissue of the epididymis and lacked mesothelial characteristics with frequent continuity with the epididymal tissue, while others retained strong mesothelial characteristics without any continuity to the epididymal tissue and developed from the mesothelium or mesonephric tissue through differentiation.

#### SUMMARY

"Adenomatoid tumor,, appearing on the head of the left epididymis of a 36-year-old male and on the head of the right epididymis of a 31-year-old male were reported.

In both of them histologically found were

tubular type structure and cell cord with slight vacuolation. Both cases showed positive acid mucopolysaccharide, probably representing hyaluronic acid, in the vacuoles and the tubular lumens. The possibility that the disease has a mesothelial origin was thus histochemically demonstrated.

However, in view of the difference between adenomatoid tumors reported in the literature and mesotheliomas occurring in other sites, a relationship with the Wolffian duct cannot be completely denied. Anyway, this should be considered an entirely different disease from the so-called "testicular benign mesothelioma". Among various cases of this disease, subtypes with different pathogenesis might be present.

#### REFERENCES

- 1) Ambrose, S. S. : J. Urol., **70** : 110, 1953.
- 2) Blumer, C. E. M. & Edward, J. L. : Brit. J.Surg., **29** : 263, 1941.
- 3) Bolck, F. : Die Endotheliome G. Thime Verl., Leipzig, 1952.
- 4) Bunting, H. et al. : Arch. Path., **49** : 590, 1950.
- 5) Burros, H. M. et al. : J. Urol., **63** : 712, 1950.
- 6) Campbell, M. F. : Urology, Vol. 2 : 1301, 1963.
- 7) Charache, H. : Urol. & cutan. Rev., **43** : 663, 1939.
- 8) Codnere, J. T. & Flynn, J. E. : J. Urol., **56** : 448, 1946.
- 9) Dixon, F. J. & Moore, R. A. : Tumors of male sex organs., Armed Forces Inst. Path. Washington, 1952.
- 10) Endo, H. : Jap. J. Urol., **51** : 111, 1960.
- 11) Evans, N. : J. Urol., **50** : 249, 1943.
- 12) Fajers, C. M. : Acta Path. microbiol. scand., **26** : 1, 1949.
- 13) Falconer, B. : J. Path. & Bact., **59** : 320, 1947.
- 14) Flickinger, T. et al. : J. Urol., **83** : 857, 1960.
- 15) Golden, A. & Ash, J. E. : Am. J. Path., **21** : 63, 1945.
- 16) Gordon-Taylor, G. & Ommaney-Davis, C. : Brit. J. Surg., **29** : 260, 1941.
- 17) Halpert, B. : J. Urol., **45** : 536, 1941.
- 18) Hamada, K. : Acta Urol. Jap., **11** : 136, 1965.
- 19) Harada, A. : Jap. J. Urol., **41** : 150, 1950.
- 20) Herbut, P. A. : Urological Pathology, Vol. 2 : 1141, 1952.
- 21) Hinmann, F. & Gibson, T. E. : Arch. Surg., **8** : 100, 1924.
- 22) Hironaka, T. et al. : The Dermatology and Urology., **24** : 357, 1962.
- 23) Horigome, T. & Hikita, M. : Jap. J. Urol., **58** : 357, 1967.
- 24) Imamura, K. et al. : Jap. J. Urol., **56** : 223, 1965.
- 25) Ishigami, J. : Japanese Encyclopedia of Urology, **6** : 71, 1960.
- 26) Jackson, J. R. : Cancer, **11** : 337, 1958.
- 27) Leach, W. B. : Am. J. Clin. Path., **20** : 970, 1950.
- 28) Lee, M. et al. : Surg. Gynec. Obst., **91** : 221, 1950.
- 29) Leighton, A. : Am. J. Obst., **65** : 573, 1912.
- 30) Longo, V. J. et al. : J. A. M. A., **147** : 937, 1951.
- 31) Malisoff, S. & Helpern, M. : J. Urol., **50** : 104, 1943.
- 32) Masson, P. et al. : Rev. canad. de Biol., **1** : 720, 1942.
- 33) Miki, N. : Dermat. et Urol., **16** : 329, 1962.
- 34) Minami, T. et al. : Dermat. et Urol., **10** : 100, 1956.
- 35) Mizoguchi, S. et al. : Jap. J. Urol., **47** : 315, 1956.
- 36) Momose, G. et al. : Acta Urol. Jap., **5** : 1234, 1959.
- 37) Morehead, R. P. : Arch. Path., **42** : 56, 1946.
- 38) Nakamura, Y. : Mitt. Med. Akad. Kioto., **26** : 648, 1939.
- 39) Noma, Y. : Dermat. et Urol., **3** : 425, 1949.
- 40) Nonaka, H. & Oguchi, F. : Jap. J. Urol., **55** : 109, 1964.

- 41) Ragins, A. B. & Crane, R. D. : Am. J. Path., 24 : 933, 1948.
- 42) Rankin, N. E. : Brit. J. Urol., 28 : 187, 1956.
- 43) Sakaguchi, I. : Jap. J. Urol., 6 : 47, 1917.
- 44) Sakurane, T. & Songen, H. : Jap. J. Urol., 54 : 774, 1963.
- 45) Sakurane, T. et al. : Jap. J. Clin. Urol., 21 : 647, 1967.
- 46) Sakatoku, J. & Takahashi, I. : Acta Urol. Jap., 8 : 48, 1962.
- 47) Sakazume, M. & Ishibashi, A. : Jap. J. Urol., 54 : 596, 1963.
- 48) Shigematsu, T. : Japanese Encyclopedia of Urology., 6 : 121, 1960.
- 49) Sonoda, R. : Jap. J. Urol., 54 : 569, 1963.
- 50) Stavrides, A. et al. : J. Urol., 83 : 448, 1960.
- 51) Steger, C. : Urol. int., 20 : 91, 1965.
- 52) Sundrasivarao, D. : J. Path. & Bact., 66 : 417, 1953.
- 53) Takayasu, H. : Jap. J. Urol., 40 : 66, 1949.
- 54) Teilum, G. : Acta Path. Microbiol. Scand., 34 : 413, 1954.
- 55) Tsuchida, M. et al. : Dermat. et Urol., 18 : 13, 1964.
- 56) Takahashi, Y. et al. : Jap. J. Urol., 59 : 648, 1968.

## Adenomatoid tumor の2例

京都府立医科大学 泌尿器科学教室

久 保 泰 徳  
村 田 庄 平

睪丸附属器より発生する腫瘍には、支持組織より発生する通常の良、悪性腫瘍のほか、“adenomatoid tumor” の名のもとに総括される良性腫瘍の存在が知られている。

そしてこの腫瘍の発生母地については、古くから種々の説がとなえられてきたが、普遍的かつ確実な説がないまま今日に至っている。

本邦では原田 (1950) が最初に adenomatoid tumor の名を用いて報告し、それ以前の同一疾患とみられる坂口 (1917)、中村 (1942)、野間 (1949) などの例を加えて今日まで計19例に達する。

われわれは最近本症の2例 (Case 1: 36才, 左副睪丸頭部; Case 2: 31才, 右副睪丸頭部) を経験し、組織ならびに組織化学的検索を行なう機会を得たので、その成績を述べるとともに若干の文献的考察を行なった。

自験2例は組織学的に tubular type および cell cord with slight vacuolation とみられ、いずれも空胞内ないしは管腔様構造のなかに hyaluronic acid と思われる acid mucopolysaccharide を有していた。

組織化学的所見を重視する Stavrides らの説に従えば、これら2例はいずれも mesothelial origin の可能性を裏づけるものであるが、文献にみられる個々の例、または他の部の mesothelioma との相違点などを考慮すると Wolffian duct との関連を全く否定することも困難となる。いずれにせよ、いわゆる “testicular benign mesothelioma” とは別個の疾患と考えるべきであろうし、本腫瘍のなかにもその発生経路を異にする二・三の亜型が存在するのではなからうかと推論した。

(1969年9月10日受付)