

Title	Cineradiographic aspects of pyelonephritis in pregnancy by motion analyzer
Author(s)	Okamoto, Shujiro; Ueda, Iwao; Sasaki, Hisashi; Suzuki, Saburo
Citation	泌尿器科紀要 (1968), 14(4): 282-287
Issue Date	1968-04
URL	http://hdl.handle.net/2433/119854
Right	
Type	Departmental Bulletin Paper
Textversion	publisher

CINERADIOGRAPHIC ASPECT OF PYELONEPHRITIS IN PREGNANCY BY MOTION ANALYZER

Shūjirō OKAMOTO and Iwao UEDA
Department of Radiology

Hisashi SASAKI and Saburo SUZUKI
Department of Urology
Tokyo Medical College, Japan

I. Preface

Analysis of the physiodynamic activities of the upper urinary tract was attempted by means of the remote controlled television. For this purpose, so far observations were made on as many as 40 cases including healthy subjects and patients with various urological diseases (1966).

This report deals with the results in four cases of pyelonephritis in pregnancy.

II. Technique and instruments

Intravenous pyelography: Intravenous injection of 40 ml of 76% Urografin as a contrast medium was given to the patients lying on the back without ureteric compression device on the abdomen.

Fluoroscopy and cineradiography by x-ray television: The fluoroscopic table is shown in Fig. 1. This can be operated by remote control system, and is called "Model US-2" manufactured by Shimazu Company (1965).

X-ray apparatus: These apparatus are composed of the image intensifier and the visicon camera. They are fixed behind the fluoroscopic table. The diameter of the image tube is 9 inches.

Television apparatus: Figure 2 illustrates the controller table of x-ray television. The




Fig. 1 Fluoroscopic Table. "Model US-2"
 SHIMAZU, CO.




Fig. 2. ① Controller Table of X-ray Television.
 ② Video-tape-recording System.
 ③ 16 mm Cineradiographic Unit.

television monitors take the telefluoroscopic image and supervising image. This table is installed in the neighbouring room separated from the fluoroscopic table. Therefore, examining doctors are able to remotely control the fluoroscopic table entirely free from radiation hazard.

16 mm cineradiographic unit: Contained in this 16 m/m cineradiographic unit, is the Arriflex cine camera (lens of f. 2.5 mm). The recording speed of the cine camera is at 15 frames per second.

Cine film analysis: The motion analyzer designed by NAC was used. Analytical examinations were conducted by projecting the film on the screen 15 times larger with this analyzer.

The method of dynamoanalytical observations are as follows: Measurement of the inside diameters for each position was performed in every frame of the cineradiographic film as the same method that was designed by Suyama (1961).

The inside diameters included the transverse diameters of each calyx, fornix and pelvocalyceal junction*, the perpendicular and transverse diameters of the pelvis and then transverse diameter of ureteropelvic junction (Fig. 3).

The calyces were divided into three groups, the upper, middle and lower ones for the sake of observational convenience.

A coin 23.5 mm in diameter was mounted for a module at the time of photography exactly as high as the 2nd lumbar vertebra placing on the skin at one third of the body thickness from the back. By this technique the actual values of the movement was able to be obtained later by way of contrast to the coin applied on the flank.

III. Items of cine film analysis

The first item: "Beginning time of visualization" means the time takes after intravenous injection of the contrast medium until the initial visualization in the upper urinary tract.

The second item: "Excretory speed of the contrast medium in the proximal ureter" was measured by the mm per second.

The third item: "Vertical movement of the kidney" was measured at rest and deep respirations.

The fourth item: "Dynamics of the renal calyces, pelvis and ureteropelvic junction" corresponded to the measurement of the inside diameters of the fornix of calyces, the pelvocalyceal junction, the pelvis and ureteropelvic junction (Fig. 3).

IV. Healthy subjects

The outlines of the average results in the healthy subjects are as follows: First, visualization of the contrast medium in the upper urinary tract after intravenous injection initiated from the upper calyces, pelvis, middle and lower calyces, then extended to the proximal ureter. The initial visualization took 153 seconds in the right upper calyces and 169 seconds in the left upper calyces.

* Pelvocalyceal junction: It appears that the junction includes the corresponding position of the muscle sphincter called Narath or Disse's sphincter.

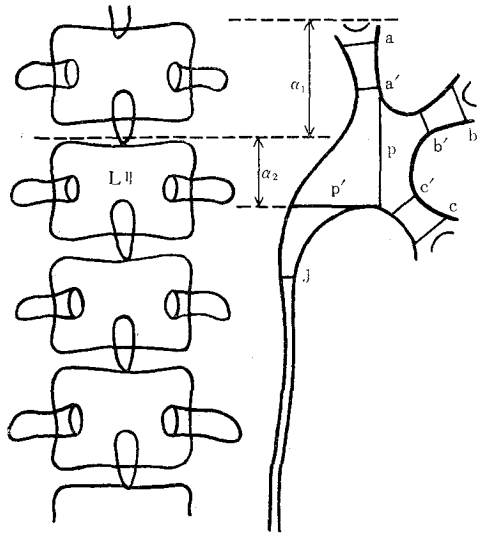


Fig. 3. Dynamoanalytical Diameter and Span figured by SUYAMA.

- a ...Fornix
- a'...Pelvocalyceal junction } upper calyx
- b ...Fornix
- b'...Pelvocalyceal junction } middle calyx
- c ...Fornix
- c'...Pelvocalyceal junction } lower calyx
- p ...Perpendicular diameter of pelvis
- p'...Transverse diameter of pelvis
- α_1 ...The distance from the superior margin of the II lumbar vertebral column to the tip of upper calyx.
- α_2 ...The distance from the superior margin of the II lumbar vertebra to the inferior line just below the pelvis.

As for excretory speed of the contrast medium in the proximal ureter, two different types of excretory movements were observed. One type was a slow and continuous excretion with a weak peristalsis of the ureter. The other was a rapid and intermittent excretion with an intensive contraction of the ureter. The excretory speed of the latter was 80 mm/sec on the right and 78 mm/sec on the left in the supine position. The extent of vertical movement of the kidneys at a rest respiration was about 10 mm.

Finally, referring to a dynamic movement of the upper urinary tract, an incessant peristalsis was observed in the calyces, namely fornix and pelvocalyceal junction. As for the dynamic relation between the fornix and pelvocalyceal junction, when the former contracted the latter dilated, and vice versa. In such a way, the contrast medium seemed to be excreted into the renal pelvis.

V. Results in pyelonephritis, especially in pregnancy

1) Beginning time of visualization

The results are given in Table 1.

Table 1

Case	Left	Right
Healthy subjects	169 sec	153 sec
Pyelonephritis	164	220
Pyelonephritis in pregnancy (Month of gestation)	VIII	225
	VII	200
	VI	430
	VI	270

In the pregnancy cases a remarkable retardation in visualization was proved as compared with the healthy subjects and plain pyelonephritis.

Table 2

Case	Supine position		Rhythm of rapid and intermittent excretion	
	Left	Right	Left	Right
Healthy subjects	78 mm/sec	80 mm/sec	26 mm/sec	21 mm/sec
Pyelonephritis	67	102	20	16
Pyelonephritis in pregnancy	VIII	—	46	continuous
	VII	81.0	38	25
	VI	—	continuous	13 (weak)
	VI	14.9	32	7 (weak)

2) Excretory speed of contrast medium in the proximal ureter

The results are given in Table 2.

In all the cases of pyelonephritis the excretory speed of the contrast medium retarded in proportion to the degree of impairment of function of the kidney. The same happened also in pyelonephritis in pregnancy. Some cases in pregnancy, however, showed continuous weak excretion.

3) Vertical movement of the kidneys at respiration measured at supine position

The results are given in Table 3.

The cases of pyelonephritis, both simple and in pregnancy, showed almost the same

Table 3

Case	Left	Right
Healthy subjects	9 mm	11 mm
Pyelonephritis	13	9
Pyelonephritis in pregnancy	VII	7.4
	VII	2.0
	VI	11.8
	VI	9.8

span of vertical movement of the kidneys at respiration as that in healthy subjects.

4) Dynamic of the upper urinary tract

The upper urinary tract in the cases of pyelonephritis in pregnancy showed a comparatively feeble dynamic movement, but there was no atony in it. On the other hand, no dynamic movement was observed in the affected calyces in the case of pyelonephritis both simple and in pregnancy.

5) Ureters

Stagnation of the contrast medium in the case of pyelonephritis in pregnancy was observed at the height of the 4th lumbar vertebra due to the pressure coming from the head of the fetus, which displaced the lower part of the ureter.

VI. Summary

This report describes our cineradiographic observations of the normal upper urinary tract and attempt of interpretation of the results in pyelonephritis, especially in pregnancy, made by motion analyzer.

It was proved that pyelonephritis in pregnancy exhibits a remarkable retardation of

visualization along with a retardation of the excretory speed of the contrast medium. In some cases, however, continuous excretion was observed. The vertical movement of the pyelonephritic kidneys showed almost same span as normal. Pyelonephritis in pregnancy indicated comparatively feeble dynamic movement, with loss of it in the affected calyces. In cases of pregnancy a stagnation of the contrast medium in the ureter at the level of the 4th lumbar vertebra due to the compression of fetus was evident, although its peristaltic activity sustained. It demonstrated no atony but weak continuous movement from proximal ureter to the bladder.

モーション・アナライザーによる 妊婦腎盂腎炎のX線映画の観察

東京医科大学放射線医学教室

岡 本 十 二 郎

上 田 巖

東京医科大学泌尿器科学教室

鈴 木 三 郎

佐 々 木 寿

われわれはX線テレビを応用した cineradiography により排泄性腎盂像，特に腎杯，腎盂尿管移行部および上部尿管の動的観察について，先の第54回日本泌尿器科学会総会において発表した（臨牀放射線第12巻，3号，1967年）。

本稿では妊娠性腎盂腎炎の4症例について述べる。その成績は，造影開始時間では健康者に比べて著しい遅延がみられる。尿管内造影剤の排泄速度は健康者に比べ，やや遅く，一部の症例では持続性の弱い排泄が認められた。腎の呼吸性移動は健康者とはほぼ同範囲であり，腎杯運動は明確な周期を認めなかったが，atony とはいい難い。尿管は第4腰椎の高さで造影の停滞を認め，胎児による下部尿管の変位が観察された。

（本論文要旨は1967年第55回日本泌尿器科学会総会において発表した）。

参 考 文 献

- 1) Eecker, J. A. and Pollack, H.: Cinefluorographic studies of the normal upper urinary tract. *Radiology*, **84**: 886-893, 1965.
- 2) Becker, J. A., Pollack, H. and Creekmore, S.: Further cinefluorographic observations on the upper urinary tract. *Radiology*, **87**: 12-15, 1966.
- 3) Benjamin, J. A.: The use of X-ray cinematography in urological studies. *J. Urol.*, **81**: 227-231, 1959.
- 4) Bodner, Henry, Howard, Allan H. and Kaplan, J. H.: Cinefluorography for the urologist. *J. Urol.*, **79**: 356-362, 1958.
- 5) Brown, M. L., Roney, P. L., Gitlin, J. G. and Moore, R. T.: X-ray experience during pregnancy. *J.A.M.A.*, **199**: 87-92, 1967.
- 6) Campbell, J. E.: Ureteral peristalsis in duplex renal collecting system. *Am. J. Roentgenology*, **99**: 577-584, 1967.
- 7) Deweed, J. H. and Holman, C. B.: Television subtraction techniques in urography. *J. Urol.*, **96**: 578-582, 1966.

- 8) Hanley, H. G.: A cine-pyelography study. *Brit. J. Urol.*, **31**: 377-384, 1959.
- 9) Hanley, H. G.: Pyelonephritis of pregnancy. *Brit. J. Urol.*, **37**: 53-57, 1965.
- 10) Kass, E. H.: Progress in pyelonephritis. p. 641-644, F. A. Davis, Philadelphia, 1965.
- 11) 松田 一・長岡 忠: X線テレビジョンをめぐって, 成人病: Vol. 1, No. 2, 1960.
- 12) Mitsuya, H., Asai, J., Suyama, K., Sai, E. and Hosoe, K.: Cinefluorography of the upper urinary tract. *Urol. Internat.*, **13**: 236-253, 1962.
- 13) 岡本十二郎・上田 巖・鈴木三郎・佐々木 寿: 泌尿器科領域における cineradiography の応用. 臨牀放射線, **12**: 233-247, 1967.
- 14) Stevenson, J.: The use of the image intensifier in urology. *Proc. Roy. Soc. Med.*, **54**: 649-655, 1961.
- 15) 須山敬二・レ線映画による上部尿路運動の研究. 日泌尿会誌, **52**: 463-524, 1961.

(1967年12月11日 受付)