

Title	Ureteral stenosis secondary to common iliac aneurysm: a case report and review of the literature in Japan
Author(s)	GOHJI, Kazuo; UEHARA, Hideki; TAKAGI, Shinsuke; ARAKAWA, Soichi; MATSUMOTO, Osamu; KAMIDONO, Sadao
Citation	泌尿器科紀要 (1988), 34(10): 1799-1803
Issue Date	1988-10
URL	http://hdl.handle.net/2433/119734
Right	
Type	Departmental Bulletin Paper
Textversion	publisher

URETERAL STENOSIS SECONDARY TO COMMON ILIAC ANEURYSM: A CASE REPORT AND REVIEW OF THE LITERATURE IN JAPAN

Kazuo GOHJI, Hideki UEHARA, Shinsuke TAKAGI,
Soichi ARAKAWA, Osamu MATSUMOTO and Sadao KAMIDONO

*From the Department of Urology, Kobe University School of Medicine
(Director: Prof. S. Kamidono)*

A case of right ureteral obstruction secondary to right common iliac aneurysm presenting as right hydronephrosis is reported and the literature is reviewed. A 66-year-old man was admitted to our hospital with lower abdominal pain and was treated by bypass operation with artificial vessel and uretero-ureterostomy of right ureter under the diagnosis of right ureteral stenosis secondary to right iliac aneurysm. Histological examination showed arteriosclerotic aneurysm and a fibrillary inflammatory change in peri-ureteral tissue without any hemosiderin-laden macrophages. Intravenous pyelography showed improvement of right hydronephrosis 45 days after operation.

To date 11 cases including our case have been reported in Japan, 10 in males and the other in female. Initial symptoms were either lumbago or an abdominal mass with palpitation in many cases. The treatment was by resection of aneurysm with bypass grafting or ureterolysis.

Key words: Ureteral stenosis, Aneurysm

INTRODUCTION

The iliac aneurysm is commonly complicated with abdominal aortic aneurysm, but solitary iliac aneurysm which tends to be ruptured is relatively rare^{1,2)}. The symptoms of iliac aneurysm were severe abdominal pain and shock following its rupture. Without rupture, it induced obstruction to adjacent organs³⁾. Ureteral obstruction, which is induced by iliac aneurysm, is rare. To date, only ten cases have been reported in the literature in Japan. We describe a 66-year-old man with right ureteral stenosis induced by right common iliac aneurysm. This is the 11th case documented in Japan.

CASE REPORT

A 66-year-old man was admitted to our hospital with lower abdominal pain. There was no evidence of hematuria, proteinuria, weight loss or fever up. Physical examinations and laboratory data were within the normal limits. Drip infusion pyelography

did not show any abnormal calcification in urinary tract and demonstrated right hydronephrosis (Fig. 1). Retrograde pyelography showed a right ureteral stenosis at the level of the fifth lumbar vertebra (Fig. 2). Abdominal computerized tomography showed a mass of peri-vascular area, which was enhanced as well as aorta

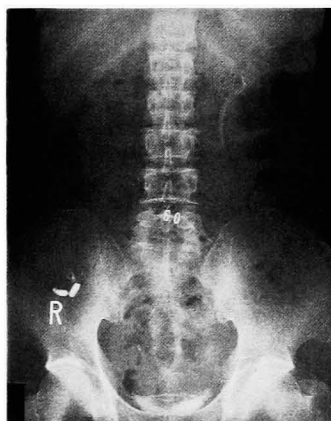

Fig. 1. Drip infusion pyelography showed moderately right hydronephrosis.

(Fig. 3). Digital subtraction angiography showed an aneurysm of right common iliac artery (Fig. 4). Replacement of the aneurysm by artificial vessel between aorta and right external iliac artery and resection of narrow segment and uretero-ureterostomy of right ureter were performed under the diagnosis of right ureteral stenosis induced by right common iliac aneurysm (Fig. 5, A, B). Intravenous

pyelogram showed improvement of right hydronephrosis 45 days after the operation (Fig. 6). Histological examination

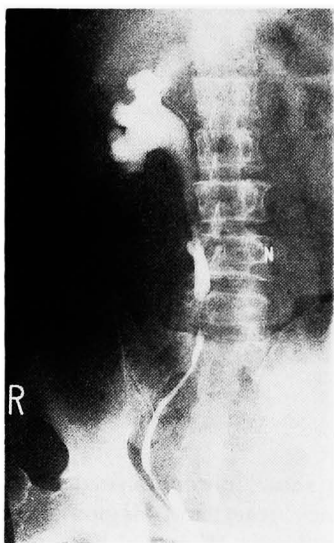

Fig. 2. Retrograde pyelography showed a right ureteral stenosis at 5th lumbar vertebra.

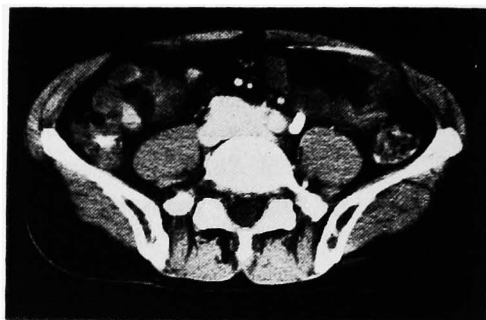


Fig. 3. Abdominal computerized tomography showed a mass of peri-vascular area.

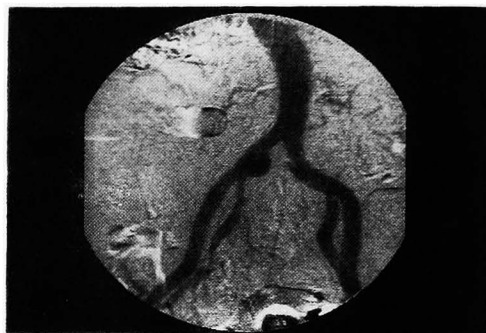

Fig. 4. Digital subtraction angiography showed a right common iliac aneurysm.

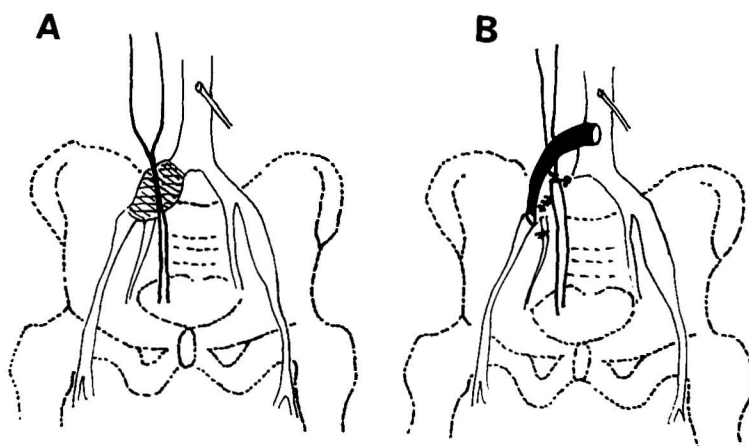


Fig. 5. Pre- and post-operative status of our case (schema). A; pre-operative schema. B; post-operative schema. Replacement of aneurysm by artificial vessel, 10 mm, Goatex, between aorta and right external iliac artery and resection of narrow segment and uretero-ureterostomy of right ureter were performed. Right internal iliac artery was ligated.

Table 1. Ureteral obstruction and stenosis secondary with common or internal iliac aneurysm reported in Japan

Case No.	Year	Authors	Age of patient (year)	Sex of patient	Site of Hydronephrosis	Site of Aneurysm	Initial Symptom	Treatment	Survival after diagnosis
1	1975	Hiekata et al ⁴⁾	22	M ^{a)}	rt ^{c)}	rt-IIA ^{f)}	lower abdominal pain	resection of aneurysm	alive
2	1978	Gotoh et al ⁵⁾	51	M	lt ^{d)}	lt-CIA ^{g)}	lt-lumbago	resection of aneurysm bypass grafting	alive
3	1982	Hayashi et al ⁶⁾	61	M	bil ^{e)}	Ao ^{h)} lt-CIA	abdominal mass with palpitation	bypass grafting ureterolysis	alive
4	1982	Nishida et al ⁷⁾	68	M	rt	Ao rt-CIA	abdominal pain appetite loss	resection of aneurysm bypass grafting	alive
5	1983	Yoshihara et al ⁸⁾	77	F ^{b)}	rt	rt-CIA	lumbago	no therapy	alive
6	1984	Nishimura et al ⁹⁾	69		lt	bil-CIA	lumbago	ureterolysis	alive
7	1985	Takahashi et al ¹⁰⁾	63	M	lt	lt-CIA	abdominal mass with palpitation	bypass grafting	—
8	1987	Tukamoto et al ¹¹⁾	62	M	lt	Ao	abdominal pain	bypass grafting	alive
9	1987	Yazawa et al ¹²⁾	78	M	rt	bil-CIA	none	bypass grafting rt-nephrectomy, TUR-Bt	alive
10	1987	Okabe et al ¹³⁾	73	M	bil	bil-CIA	lumbago	ureterolysis	—
11	1987	Gohji et al ¹⁴⁾	66	M	rt	rt-CIA	lower abdominal pain	bypass grafting uretero-ureterostomy	alive

a) M ; male, b) F ; female c) rt ; right d) lt ; left e) bil ; bilateral f) IIA ; internal iliac artery
g) CIA ; common iliac artery h) Ao ; aorta

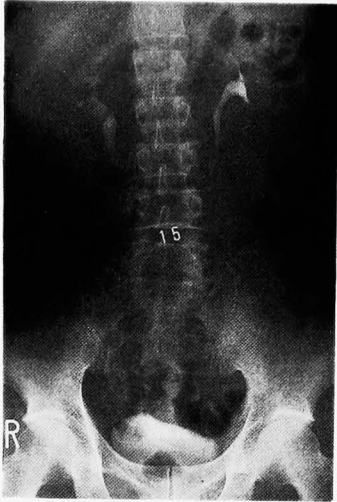


Fig. 6. Intravenous pyelography showed improvement of right hydronephrosis 45 days after operation.

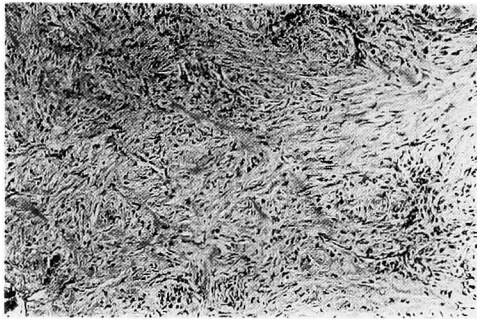

Fig. 7. Histological findings of peri-ureteral tissue was fibrillary inflammatory change (H & E, $\times 40$).

showed an arteriosclerotic aneurysm and fibrillary inflammatory changes in peri-ureteral tissue without any hemosiderin-laden macrophages (Fig. 7).

DISCUSSION

Ureteral obstruction or stenosis induced by common or internal iliac aneurysm is rare. Eleven cases including our case have been reported in the literature in Japan (Table 1)⁴⁻¹³⁾. The patients ranged in age from 22 to 78 years and there were 10 males and one female. Initial symptoms were either lumbago or abdominal mass with palpitation in ten cases. In the other one case, intravenous pyelography showed hydronephrosis without symptoms. In 8

cases, resection of the aneurysm or bypass grafting with artificial vessel was performed. Among the 7 cases treated by bypass grafting, one patient underwent nephrectomy and transurethral resection of bladder tumor in addition, because ureter and bladder tumors were suspected. Only ureterolysis was performed in two cases. The other one case was not treated. In our case, resection of aneurysm, bypass operation with artificial vessel and uretero-ureterostomy of right ureter were performed. Rather than a function of the size of the aneurysm in itself, obstruction usually is caused by retroperitoneal fibrosis which encases the ureters^{14,15)}. In formation of fibrous tissue, two different ways have thus far been described¹⁵⁻¹⁷⁾. First, microscopic perforations of the arteriosclerotic plaques allow blood to leak into the retroperitoneum resulting in an inflammatory process. Second, inflammatory changes usually seen in the wall of aneurysm may extend to the adventitia and perivascular structure. Although in our case, periaortic fibrosis and chronic inflammatory change were seen, we could not detect any hemosiderin-laden macrophages. Therefore, the etiology of our case suggested the above second process.

REFERENCES

- 1) Markowitz AW and Norman JC: Aneurysms of the iliac artery. *Ann Surg* **154**: 777-787 1961
- 2) Silver D, Anderson EE and Porter, JM: Isolated hypogastric artery aneurysm. *Arch Surg* **95**: 308-312, 1967
- 3) Short DW: Aneurysms of the internal iliac artery. *Brit J Surg* **53**: 17-20, 1966
- 4) Hiekata T, Okada T, Kawata T and Noguchi T: Aneurysm of the internal iliac artery. *Surg* **38**: 1139-1143, 1976
- 5) Gotoh T, Kaneta T, Hashimoto M and Sugie S: Ureteral obstruction secondary to common iliac artery aneurysm. *Nishi Nippon Urol* **40**: 687-691, 1978
- 6) Hayashi T, Ikeda N, Maeda T and Watanabe T: Bilateral ureteral obstruction secondary to abdominal aortic aneurysm. *Acta Urol Jpn* **28**: 203-207, 1982
- 7) Nishida T, Kusakai Y, Inoke T and Yasuda K: A case of ureteral obstruction secondary to common iliac artery aneurysm. *Kyosai*

- Ihou 32: 334-340, 1982
- 8) Yoshihara H, Yamamoto K and Matsumura T: A case of ureteral obstruction secondary to common iliac aneurysm. Jpn J Urol 74: 1488, 1983
 - 9) Nishimura T, Okumura S, Abe H, Hirasawa S, Akimoto M and Kawamura N: Ureteral obstruction secondary to abdominal aortic and common iliac artery aneurysm. A case report. Rinshou Hinyouki 38: 337-339, 1984
 - 10) Takahashi A, Shirakata S, Hashimoto T, Murayama Y, Neshiyama K, Kitamura K, Kanki Y, Sato S, Nakaji S and Oka T: A rare case of ureteral obstruction caused by a left common iliac artery aneurysm. Kyoto Huru Idai-shi 94: 69-74, 1985
 - 11) Tukamoto T, Oda K, Katamoto K and Shinbori T: A case of hydronephrosis complicated with abdominal aneurysm. Jpn J Urol 78: 381, 1987
 - 12) Yazawa A: A case of right hydronephrosis secondary to right common iliac aneurysm. Jpn J Urol 78: 382, 1987
 - 13) Okabe S, Hori N, Sugimura Y, Tajima K, Tochigi H and Kawamura J: A case of ureteral stenosis due to common iliac artery aneurysm. Rinshou Hinyouki 41: 517-519, 1987
 - 14) Culp OS and Bernatz PE: Urologic aspects of lesions in the abdominal aorta. J Urol 86: 189-195, 1961
 - 15) Labardini MM and Ratliff RK: The abdominal aortic aneurysm and the ureter. J Urol 98: 590-596, 1967
 - 16) Wagenknecht LV and Madsen PO: Bilateral ureteral obstruction secondary to aortic aneurysm. J Urol 103: 732-736, 1970
 - 17) Cerny JC and Scott T: Non-idiopathic retroperitoneal fibrosis. J Urol 105: 49-55, 1971
- (Accepted for publication October, 23, 1987)

和文抄録

総腸骨動脈瘤による尿管狭窄の1例：本邦報告例の臨床病理学的検討

神戸大学医学部泌尿器科学教室（主任：守殿貞夫教授）

郷司 和男, 上原 秀規, 高木 伸介, 荒川 創一
松本 修, 守殿 貞夫

右総腸骨動脈瘤による右尿管狭窄をきたした1例を報告するとともに本邦報告例につき検討を加えた。

患者は66歳男性で下腹部痛を主訴として当科受診した。右総腸骨動脈瘤による尿管狭窄の診断のもとに、人工血管を用いたバイパス手術と、尿管狭窄部を切除後、尿管端々吻合術を施行した。組織学的に粥状動脈瘤と、尿管周囲に炎症性線維性組織をみとめたが、ヘモジデリンを貪食した大食細胞を認めなかった。術後45日目のIVPで右水腎症の著明な改善が認められ

た。

動脈瘤による尿管狭窄症の本邦報告例は自験例も含め11例認められる。その性別は、男性10例、女性1例と圧倒的に男性に多い。初発症状は、多くは腰痛あるいは拍動を有する腰部腫瘤触知であった。治療は多くの例で、人工血管を用いたバイパス手術および尿管剥離が施行されていた。

(泌尿紀要 34: 1799-1803, 1988)